

Letter to the Editor

Mini titanium plates and screws for cranial bone flap fixation; an experience from Pakistan

Syed Sarmad Bukhari, Muhammad Junaid¹

Medical E Unit, Khyber Teaching Hospital, ¹Department of Neurosurgery, Combined Military Hospital, Peshawar, Pakistan

E-mail: *Syed Sarmad Bukhari - sarmadbukhari@gmail.com; Muhammad Junaid - jkneuro@hotmail.com

*Corresponding author

Received: 16 December 14 Accepted: 14 January 15 Published: 08 May 15

This article may be cited as:

Bukhari SS, Junaid M. Mini titanium plates and screws for cranial bone flap fixation; an experience from Pakistan. *Surg Neurol Int* 2015;6:75.

Available FREE in open access from: <http://www.surgicalneurologyint.com/text.asp?2015/6/1/75/156774>

Copyright: © 2015 Bukhari SS. This is an open-access article distributed under the terms of the Creative Commons Attribution License, which permits unrestricted use, distribution, and reproduction in any medium, provided the original author and source are credited.

Dear Editor,

The biocompatibility and osseointegrative qualities of the element titanium have allowed its extensive use medical science especially Orthopedics and Neurosurgery, effectively replacing its predecessor, steel. Historically, nonabsorbable sutures were used to anchor the bone flap following a craniotomy but have been associated with functional and cosmetic defects as well as nonunion and failure postoperatively.^[1] The craniofacial region is the most important part of the body with regard to harmony and symmetry and associated with self-image of the patient, but unfortunately, maintenance of preoperative appearance has not been a priority among neurosurgeons.^[2] Improper fixation of a bone flap following craniotomies has also been known to affect overall surgical outcome.^[3] Titanium miniplates have been employed for cranial bone flap fixation with excellent results for several years^[4] and we are pleased to report that working in a developing health care system; our experience has proved to be cost effective and yielding excellent cosmesis.

We have been using titanium miniplates at our department since 2011. A total of 71 patients (42 male and 29 female) underwent a craniotomy for supratentorial access for a variety of causes including tumor excision and aneurysm clipping followed by a cranial bone flap fixation with titanium miniplates till March 2014 by one surgeon. Craniotomies for posterior fossa approaches are not performed in our unit for lack of specialized equipment and craniotomies for head trauma were not included in this group of patients. Postoperatively the patients were followed up for a period of 3–12 months and the results were objectively assessed with visual inspection, computed

tomography/magnetic resonance imaging (CT/MRI) to assess for appearance, physical deformity, subsidence, or displacement of the bone flap. Subjective data from the patients was not obtained. The age range was 2–77 years with a mean age of 40.07 years and a standard deviation of +/- 18.753 years. Intracranial lesion size ranged from 3 × 2 cm to 7 × 5 cm. The changes of local incision and general condition were observed.

Minor complications were reported in three patients with a subcutaneous effusion occurring in two patients who were treated with needle aspiration on day 10 and one patient developing a mild postoperative wound infection, which was treated with dressings and oral antibiotics. CT scan showed good repositioning of the flap and edge to edge apposition at 2 weeks after operation. During follow up, the skull had good appearance without any discharge, local deformity or effusion. Repeat CT/MRI showed no subsidence or displacement of cranial flap or artifacts. Titanium plates, however, can cause a small distortion in the image, up to 0.5 cm, on CT and MRI scans.

Titanium miniplates were introduced for rigid fixation of cranial bone flaps following craniotomies. They are currently available in 0.3-mm thickness, which does not require indentation of the bone to hide

Access this article online

Quick Response Code:



Website:

www.surgicalneurologyint.com

DOI:

10.4103/2152-7806.156774

the surface thickness. This has resulted in excellent functional and cosmetic outcomes [Figure 1] and faster operating times, reducing the tediousness and uncertainty associated with nonresorbable sutures.^[1] Improper closure of a craniotomy has been known to cause physical disfigurement that is a source of patient distress and cosmetic damage and is usually attributed to temporalis muscle asymmetry, bone flap depression, or a combination of both.^[5-7] Physical disfigurement is not the only complication that should preclude an improper closure because neurological deficits such as constructional apraxia have been known to develop in patients associated with sinking of a flap that is not securely anchored.^[8] Titanium miniplates have been shown to be superior to stainless steel wires for fixation with a reduced operating time by 40% and less mobility on digital pressure with none of the patients having suboptimal results.^[9] During closure, the space left between the skull and the bone flap can be filled with bone powder mixed with the patient's own blood. Bone cementum can give a near perfect result, although this is the more expensive option. The importance of cosmetic outcome can be gleaned by the fact that more and more surgeons are using keyhole approaches for major neurosurgical procedures.^[10,11] Based on these observations, Frati *et al.*

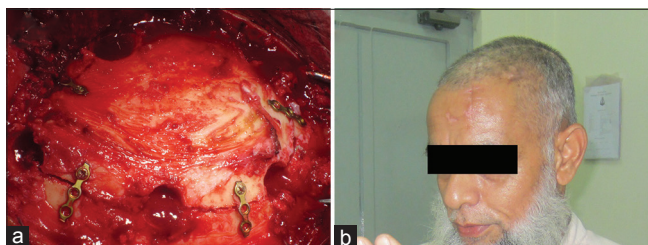


Figure 1: (a) Intraoperative photograph showing edge to edge apposition using titanium miniplates (b) Postoperative photograph of patient showing excellent head symmetry and aesthetics

have described an excellent protocol that minimizes scarring, reduces tissue loss, and maintains symmetry following craniotomies that we believe should be learnt by young neurosurgeons.^[2] Another option currently available is bioresorbable plates (Bonamates®), which are similar to titanium miniplates, although significantly more expensive and essentially similar outcomes. They should be preferred when the patient requires follow up radiotherapy to avoid dosing adjustments and problems. They do not cause any artifacts either.^[12]

REFERENCES

1. Badie B. Cosmetic reconstruction of temporal defect following pterional craniotomy. *Surg Neurol* 1996;45:383-4.
2. Broaddus WC, Holloway KL, Winters CJ, Bullock MR, Graham RS, Mathern BE, *et al.* Titanium miniplates or stainless steel wire for cranial fixation: A prospective randomized comparison. *J Neurosurg* 2002;96:244-7.
3. Couldwell WT, Fukushima T. Cosmetic mastoidectomy for the combined supra/infratentorial transtemporal approach. Technical note. *J Neurosurg* 1993;79:460-1.
4. Cusimano MD, Suhardja AS. Craniotomy revisited: Techniques for improved access and reconstruction. *Can J Neurol Sci* 2000;27:44-8.
5. Frati A, Pichierri A, Esposito V, Frati R, Delfini R, Cantore G, *et al.* Aesthetic issues in neurosurgery: A protocol to improve cosmetic outcome in cranial surgery. *Neurosurg Rev* 2007;30:69-76.
6. Lacey M, Antonyshyn O, MacGregor JH. Temporal contour deformity after coronal flap elevation: An anatomical study. *J Craniofac Surg* 1994;5:223-7.
7. Lin J, Lin C, Chiu W, Yang Y, Chen C, Lee S, *et al.* Clinical experience with bioresorbable plates for skull flap fixation. *J Dent Sci* 2006;1:187-94.
8. Marcus HJ, Cundy TP, Hughes-Hallett A, Yang GZ, Darzi A, Nandi D. Endoscopic and keyhole endoscope-assisted neurosurgical approaches: A qualitative survey on technical challenges and technological solutions. *Br J Neurosurg* 2014;28:606-10.
9. O'Malley BW Jr, Janecka IP. Evolution of outcomes in cranial base surgery. *Semin Surg Oncol* 1995;11:221-7.
10. Persing JA, Mayer PL, Spinelli HM, Miller L, Criscuolo GR. Prevention of "temporal hollowing" after fronto-orbital advancement for craniosynostosis. *J Craniofac Surg* 1994;5:271-4.
11. Rajappa P, Krass J, Parakh S, Spinelli HM, Greenfield JP. An aesthetic approach to the anterior cranial fossa: The endoscopic transadnexal transorbital roof method. *Aesthetic Plast Surg* 2014;38:399-403.
12. Rengachary SS, Amini J, Batnitzky S. Reversible constructional apraxia from a floating bone flap. *Neurosurgery* 1979;5:365-7.