

Original Article

Efficacy of arachnoid plasty with collagen sheets and fibrin glue: An *in vitro* experiment and a case review

Junya Abe, Tsutomu Ichinose¹, Yuzo Terakawa, Naohiro Tsuyuguchi, Takashi Tsuruno¹, Kenji OhataDepartment of Neurosurgery, Osaka City University Graduate School of Medicine, 1-4-3 Asahi-machi, Abeno-ku, Osaka 545 - 8585, ¹Department of Neurosurgery, Yao Tokushukai General Hospital, 1-11 Wakakusa-cho, Yao city, Osaka, 581 - 0011, JapanE-mail: *Junya Abe - abe0801@gmail.com; Tsutomu Ichinose - ichinosestutomu@gmail.com; Yuzo Terakawa - terakawa@med.osaka-cu.ac.jp; Naohiro Tsuyuguchi - nao@med.osaka-cu.ac.jp; Takashi Tsuruno - tsuruno-0745@nike.eonet.ne.jp; Kenji Ohata - kohata@med.osaka-cu.ac.jp

*Corresponding author

Received: 29 October 14 Accepted: 29 January 15 Published: 28 May 15

This article may be cited as:Abe J, Ichinose T, Terakawa Y, Tsuyuguchi N, Tsuruno T, Ohata K. Efficacy of arachnoid plasty with collagen sheets and fibrin glue: An *in vitro* experiment and a case review. *Surg Neurol Int* 2015;6:90.Available FREE in open access from: <http://www.surgicalneurologyint.com/text.asp?2015/6/1/90/157792>

Copyright: © 2015 Abe J. This is an open-access article distributed under the terms of the Creative Commons Attribution License, which permits unrestricted use, distribution, and reproduction in any medium, provided the original author and source are credited.

Abstract

Background: Postoperative subdural fluid collection sometimes occurs after clipping of cerebral aneurysms. Arachnoid plasty is used to prevent such postoperative complications; however, the optimal materials for arachnoid plasty remain unclear. In this study, we aimed to clarify the optimal materials for arachnoid plasty and report our experience of arachnoid plasty after clipping of unruptured aneurysms.

Methods: In an *in vitro* experiment, adhesive strengths of three materials permitted for use in the intradural space, such as collagen sheets, gelatin sponge, and oxidized cellulose sheets, were measured by assessing their water pressure resistance. Then, 80 consecutive cases surgically treated unruptured cerebral aneurysms were retrospectively reviewed to examine the occurrence rate of postoperative subdural fluid collection.

Results: The collagen sheet exhibited the greatest adhesive strength, so we used collagen sheets for the arachnoid plasty procedures. In all of these cases, arachnoid plasty was performed with fibrin glue-soaked collagen sheets. No postoperative subdural fluid collection, inflammation, or allergic reactions occurred in any case.

Conclusions: The present study suggests that collagen sheet might be one of the optimal materials for arachnoid plasty. This technique is simple and may be effective to prevent subdural fluid collection after clipping.

Key Words: Arachnoid plasty, collagen sheets, water pressure resistance

Access this article online**Website:**www.surgicalneurologyint.com**DOI:**

10.4103/2152-7806.157792

Quick Response Code:

INTRODUCTION

Postoperative subdural fluid collection (SFC) is a complication of craniotomy and incidence of 6–51% is reported.^[12,13,17,20,23] Most SFC eventually disappears or is clinically asymptomatic, and therefore SFC does not receive much attention. However, some SFCs enlarge, leading to chronic subdural hematomas or hygromas, which require surgical treatment.^[7,11,19] Arachnoid plasty

is reported to be useful for preventing postoperative SFC.^[9,23] There are several ways of arachnoid plasty. In recent reports, most arachnoid plasty procedures have involved a combination of covering materials and fibrin glue. However, no previous reports have assessed the adhesive strength of different covering materials. In the present study, we assessed the adhesive strength of three such materials by evaluating their resistance to water pressure. In addition, we examined the efficacy

of arachnoid plasty performed with collagen sheets and fibrin glue after clipping of unruptured aneurysms.

MATERIALS AND METHODS

In vitro experiment of water pressure resistant

The following three materials, which are often used in neurosurgery to achieve hemostasis or strengthen suture points and are permitted for use in the intradural space, had their water pressure resistance assessed in the present study: Collagen sheets (INTEGRAN press sheet-type, Nippon Zoki Pharmaceutical Co., Ltd., Tokyo), oxidized cellulose sheets (SURGICEL NU-KNIT, Johnson and Johnson K.K., Tokyo), and gelatin sponge (Gelfoam, Pfizer Inc., Tokyo).

The experimental protocol is as follows and the scheme of experiment is shown in [Figure 1]. First, the epidermis of a rabbit was placed over the opening of a bottle (20 mm in diameter), and a small hole was made in the center of the epidermis using an aorta/vein punch (5.0 mm in diameter; ACP JAPAN Co., Ltd., Tokyo). The bottom of the bottle was connected to a 10-ml syringe and a manometer using a 3-way tube. Then, each material was cut into a circle with a diameter of 15 mm. After being soaked in fibrin glue, the material was then placed over the epidermis. The fibrin glue (Bolheal; Kaketsuken, Kumamoto, Kumamoto) consisted of solutions A and B; solution A contained fibrinogen (80 mg/ml), blood coagulation factor VIII (75 units/ml), and aprotinin (1000 KEI/ml), and solution B contained thrombin (250 units/ml) and calcium chloride (5.9 mg/ml). In this experiment, each test material was soaked in solution A (0.3 ml) in a laboratory dish, and then solution B (0.3 ml) was dripped onto it. At 3 min after solution B had been dripped onto

the test material, water was introduced into the bottle via the syringe, and the bursting pressure of the material was measured by the manometer. Bursting was defined as the presence of an air bubble between the material and epidermis. The experiment was performed 11 times for each material. Statistical analysis was performed with a computer software package (StatMate IV for Windows; Atoms, Tokyo, Japan). The bursting pressures were analyzed by using the Kruskal–Wallis test followed by Dunn's multiple comparison test. In all statistical analyses, significance was defined as a *P* value less than 0.05.

Patient population of arachnoid plasty

Between September 2009 and March 2013, there were 80 consecutive cases in which clipping surgery of unruptured cerebral aneurysms of the anterior circulation was performed at the Department of Neurosurgery, Yao Tokushukai General Hospital. There were 25 male and 55 female, mean age was 65.8 ± 9.4 years (mean \pm SD).

Regarding the locations of the aneurysms, 32 aneurysms originated from the internal carotid artery (ICA), 30 from middle cerebral artery (MCA), and 18 from anterior communicating artery (A-Com) or anterior cerebral artery (ACA). Most of the clipping procedures were performed via a transsylvian approach. An interhemispheric approach was selected in four cases in which the aneurysms were located in the A-Com or distal ACAs. In all cases, the arachnoid plasty was performed with fibrin glue-soaked collagen sheets.

Surgical technique

In the transsylvian approach, the Sylvian fissure was dissected, and the arachnoid trabeculae were cut between the frontal and temporal lobes from deep within the Sylvian fissure to its surface. To minimize brain retraction, the interhemispheric fissure and contralateral cistern were opened in some cases. After the clipping had been performed, arachnoid plasty was conducted. Collagen sheets that had been soaked with fibrin glue were used to cover the exposed arachnoid space extended to anterior skull base, and then solution B was dripped onto them. Collagen sheets were shaped rectangular and covered both the Sylvian fissure and anterior skull base. Artificial cerebrospinal fluid (CSF) was then injected into the Sylvian fissure through a drainage tube. As a result, the brain, which shrank during clipping surgery, gradually expanded. Subsequently, we removed the drainage tube and covered the hole with the collagen sheets. Lastly, we closed the dura in a water tight fashion.

In the interhemispheric approach, the arachnoid plasty is performed after clipping in the same fashion. The exposed arachnoid space and anterior skull base were covered with the collagen sheets soaked fibrin glue, and the artificial CSF was injected into the interhemispheric fissure.

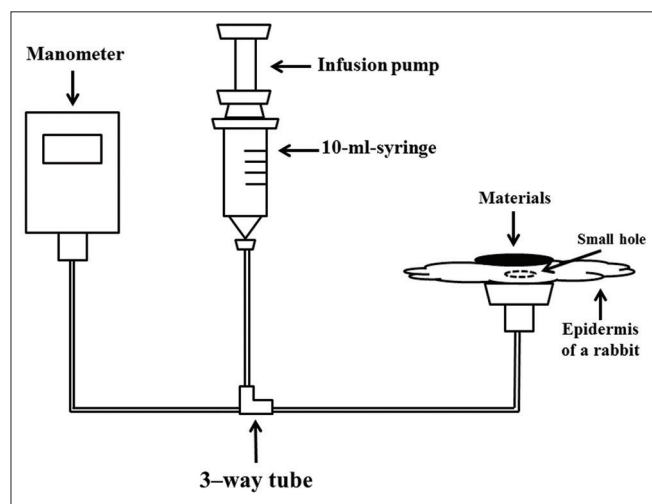


Figure 1: The scheme of an *in vitro* experiment of measurement water pressure resistance. The bottom of bottle was connected to a 10 ml syringe and a manometer using a 3-way tube. The examined material was placed over the epidermis of a rabbit

RESULTS

In vitro experiment of water pressure resistant

The results of the water pressure resistance experiment are shown in [Figure 2]. The bursting pressures of the materials in 11 repeated experiments were as follows: Collagen sheet: 169 ± 37.7 mmHg (mean \pm SD), oxidized cellulose sheet: 45 ± 23.4 mmHg, and gelatin sponge: 31 ± 7.7 mmHg. The above-mentioned experiment showed that the collagen sheet exhibited the greatest adhesive strength ($P < 0.05$). There was no significant difference in the adhesive strength between the oxidized cellulose sheets and the gelatin sponge ($P = 0.24$). On the basis of these results, we selected collagen sheets in the subsequent arachnoid plasty procedures.

Results of arachnoid plasty

The median follow-up period was 21 months (range, 1–42 months). SFC was diagnosed based on brain computed tomography (CT) scans obtained about 1 month after surgery. Subdural spaces of less than 5 mm in diameter were not considered to be indicative of SFC. In this study, SFC did not occur in any case, nor did infections or allergic reactions. The illustrative case is shown in Figure 3. One of the 80 patients, who had an aneurysm in the MCA (the M1-2 bifurcation) clipped, suffered an epileptic seizure (a nonconvulsive seizure) just after the operation. The patient was soon started on antiepileptic drugs, and no seizures have occurred since.

DISCUSSION

Arachnoid plasty has been demonstrated to be effective for preventing postoperative SFC.^[9,23] Several arachnoid plasty methods have been reported, for example, suturing the arachnoid membrane,^[2,26] sealing it using fibrin glue,^[2,5,9,22] or covering it using appropriate materials and fibrin glue.^[5,17,23] Each method seems to be able to reduce the postoperative

SFC.^[1,3,4,8,18,26] As for the covering materials, gelatin sponge or collagen sheets are usually used for arachnoid plasty.^[17,23] However, no reports have examined the optimal covering materials for the procedure. To the best of our knowledge, this is the first study that assessed the adhesive strength of different materials that are frequently used in neurosurgical procedures by evaluating their resistance to water pressure. In this study, we compared three materials permitted for use in the intradural space and found that the collagen sheets exhibited significantly greater water pressure resistance than the other two materials. Although the bursting pressure of all the materials exceeded the normal CSF pressures in our experiment, the adhesive force of materials should be over the injection pressure of artificial CSF in arachnoid plasty. Thus it is believed that adhesive strength of materials are demanded to be stronger. Therefore, we used collagen sheets for the arachnoid plasty procedures. In the present study, we used sheet-type of collagen sheet (Integran® press 100×50 mm; thickness 0.2 mm), which is thin and easy to shape. This sheet is shaped a paper-like thin form and possesses a natural cotton-fiber structure, which makes them strongly adhesive. Moreover soaking collagen sheets in fibrin glue reinforces their fiber structure, and consequently makes them stronger. These characteristics of collagen sheets seem to be an advantage for arachnoid plasty.

The efficacy of arachnoid plasty with collagen sheet and fibrin glue after the clipping of unruptured aneurysms was examined. As a result, we found that the procedure achieved good outcomes, and there were no incidence of SFC or complications such as surgical infection. The leakage of CSF and brain shrinkage is considered to be the main causes of SFC after the opening of the arachnoid space.^[6,20,21,23-25] Aneurysm clipping and surgery involving elderly patients might be particularly associated with SFC.^[6,9,12,17,20] In the case of the clipping of unruptured aneurysms, the incidence of SFC is reported to range from 6% to 14%.^[13,27] In a prospective study of the treatment of SAH patients, it was reported that the arachnoid plasty with fibrin glue could reduce postoperative SFC but the incidence was 6%.^[9] Recent advancement in medical technology and surgical

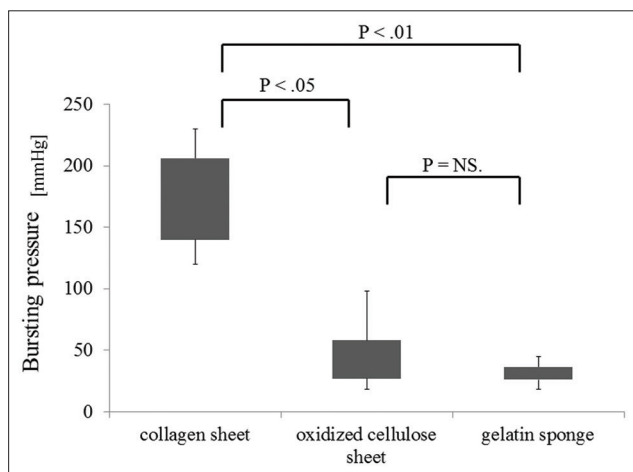


Figure 2: Water pressure resistance. The collagen sheet demonstrated significantly greater adhesive strength than the other two materials

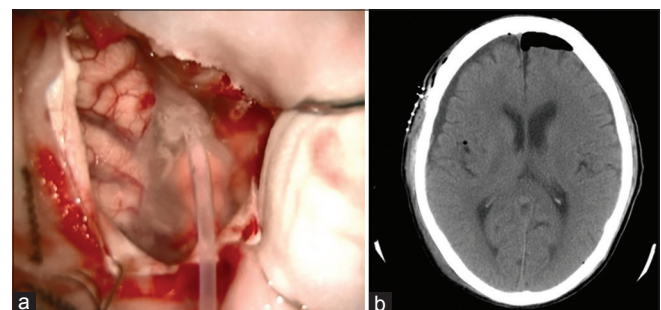


Figure 3: Arachnoid plasty in the transylvian approach (a) Artificial cerebrospinal fluid was injected into the Sylvian fissure through a drainage tube. (b) Brain CT taken a day after operation showing little subdural fluid collection

instruments has led to better treatment outcome of craniotomy. Morbidity of clipping surgery of unruptured aneurysm has been reported to range 2.2–10.9%;^[10,14,15] therefore, safer and less invasive surgical procedures are required. In addition, the number of surgical procedures involving elderly patients is gradually increasing and so the prevention of postoperative SFC deserves attention.

Collagen sheets demonstrated strong adhesiveness in our *in vitro* experiment, and, in fact, were found to be useful for preventing postoperative SFC after clipping surgery of unruptured aneurysms. Additionally, precise manipulation is required due to the limited surgical field in neurosurgical procedures. Therefore, the materials for arachnoid plasty must not only display resistance to water pressure but also be easy to manipulate. This feature allowed us to cover even deep parts of the brain such as the anterior skull base. Accordingly, we consider that a combination of collagen sheets and fibrin glue might be one of the suitable techniques for arachnoid plasty and feasible for preventing postoperative SFC.

Limitations

In this study, arachnoid plasty performed with collagen sheets and fibrin glue achieved favorable results. However, we assessed the water pressure resistance of the examined materials just 3 min after the fibrin glue had been applied. It is possible that the water resistance of the materials changes gradually over time. Another limitation is that the fibrin glue mixing ratio was not examined in this experiment. A previous *in vitro* study reported that a fibrin glue mixing ratio of A/B 5:1 resulted in significantly greater pressure resistance than a ratio of A/B 1:1.^[16] Further studies using collagen sheets might be necessary to examine water pressure resistance after different periods and/or the use of fibrin glue with different mixing ratios.

CONCLUSIONS

Collagen sheets soaked with fibrin glue, which display strong adhesiveness and water pressure resistance, are useful covering materials for arachnoid plasty. Arachnoid plasty with collagen sheets and fibrin glue is a safe technique and appears to be effective for preventing SFC after clipping of unruptured aneurysms.

ACKNOWLEDGMENTS

The authors thank Mr. Kenichiro Hirahashi, Kaketsuken, for his assistance in preparing our study. There was no financial support from Kaketsuken.

REFERENCES

- Al-Yamany M, Del Maestro RF. Prevention of subdural fluid collections following transcortical intraventricular and/or paraventricular procedures by using fibrin adhesive. *J Neurosurg* 2000;92:406-12.
- Blauwblomme T, Harkness W. Corticotomy closure avoids subdural collections after hemispherotomy. *Neurosurgery* 2010;67:485-8.
- Boyd MC, Steinbok P. Choroid plexus tumors: Problems in diagnosis and management. *J Neurosurg* 1987;66:800-5.
- Hirsch JF, Sainte-Rose C. A new surgical approach to subcortical lesions: Balloon inflation and cortical gluing. Technical note. *J Neurosurg* 1991;74:1014-7.
- Jung TY, Jung S, Jin SG, Jin YH, Kim IY, Kang SS, et al. Prevention of postoperative subdural fluid collections following transcortical transventricular approach. *Surg Neurol* 2007;68:172-6.
- Koizumi H, Fukamachi A, Nukui H. Postoperative subdural fluid collections in neurosurgery. *Surg Neurol* 1987;27:147-53.
- Mervart M. Extracerebral fluid collection in infancy. *J Neurosurg* 1995;82:148-9.
- Milhorat TH. Closure of cerebral incisions following intraventricular operations. Technical note. *J Neurosurg* 1971;35:108-11.
- Mino Y, Hirashima Y, Hamada H, Masuoka T, Yamatani K, Takeda S, et al. Effect of arachnoid plasty using fibrin glue membrane after clipping of ruptured aneurysm on the occurrence of complications and outcome in the elderly patients. *Acta Neurochir (Wien)* 2006;148:627-31.
- Moroj J, Hadeishi H, Suzuki A, Yasui N. Morbidity and mortality from surgical treatment of unruptured cerebral aneurysms at Research Institute for Brain and Blood Vessels-Akita. *Neurosurgery* 2005;56:224-31.
- Murata K. Chronic subdural hematoma may be preceded by persistent traumatic subdural effusion. *Neurol Med Chir (Tokyo)* 1993;33:691-6.
- Nishimura S, Fujita T, Sakata H, Hori E, Mino M, Nishijima M. Chronic subdural hematoma and remote cerebellar hemorrhage developing after unruptured aneurysmal surgery. *Surg Cereb Stroke* 2009;37:350-6.
- Nozaki K, Kikuta K, Takagi Y, Nishimura M. Surgical outcomes and complications of open surgery for unruptured cerebral aneurysms in anterior circulation. *Surg Cereb Stroke* 2009;37:40-5.
- Orz YI, Hongo K, Tanaka Y, Nagashima H, Osawa M, Kyoshima K, et al. Risks of surgery for patients with unruptured intracranial aneurysms. *Surg Neurol* 2000;53:21-9.
- Raaymakers TW, Rinkel GJ, Limburg M, Algra A. Mortality and morbidity of surgery for unruptured intracranial aneurysms: A meta-analysis. *Stroke* 1998;29:1531-8.
- Saitoh Y, Oshino S. Enhancement of withstanding pressure of fibrin sealant by modified mixing ratio of fibrin sealant components for skull base reconstruction: Technical note. *Neurol Med Chir (Tokyo)* 2013;53:65-8.
- Sawamura A, Kamiyama H, Kobayashi N, Makino K, Takizawa K, Yasuda H, et al. A new technique for the prevention of brain collapse using fibrin glue and "Floating bypass" technique. *Surg Cereb Stroke* 1999;27:479-82.
- Sawamura Y, Asaoka K, Terasaka S, Tada M, Uchida T. Evaluation of application techniques of fibrin sealant to prevent cerebrospinal fluid leakage: A new device for the application of aerosolized fibrin glue. *Neurosurgery* 1999;44:332-7.
- Shaskey DJ, Mijer JF, Williams HJ, Sawitzke AD. Subdural fluid collections: An unusual manifestation of CNS disease in a connective tissue disorder. *Clin Rheumatol* 1995;14:108-11.
- Tanaka Y, Mizuno M, Kobayashi S, Sugita K. Subdural fluid collection following craniotomy. *Surg Neurol* 1987;27:353-6.
- Tanaka Y, Sugita K, Kobayashi S, Takemae T, Hegde AS. Subdural fluid collections following transcortical approach to intra- or paraventricular tumours. *Acta Neurochir (Wien)* 1989;99:20-5.
- Tashiro H, Morikawa A, Yamanaka M, Kuraishi K. Arachnoid closure making use of the fibrin membrane. *Jpn J Neurosurg* 2000;9:775-7.
- Tsuruno T, Matsuoka Y, Hakuba A. An arachnoid plasty technique using a collagen seat and fibrin glue. *Jpn J Neurosurg* 1995;4:193-5.
- Watanabe S, Shimada H, Ishii S. Production of clinical form of chronic subdural hematoma in experimental animals. *J Neurosurg* 1972;37:552-61.
- Yamada H, Watanabe T, Murata S, Shibui S, Nihei H, Kohno T, et al. Developmental process of chronic subdural collections of fluid based on CT scan findings. *Surg Neurol* 1980;13:441-8.
- Yoshimoto T, Houkin K, Ishikawa T, Abe H. Arachnoid membrane closure. Prevention of postoperative cerebrospinal fluid leakage. *Surg Neurol* 1999;52:68-72.
- Yoshimoto Y, Wakai S, Hamano M. External hydrocephalus after aneurysm surgery: Paradoxical response to ventricular shunting. *J Neurosurg* 1998;88:485-9.