

CSF hydrothorax without intrathoracic catheter migration in children with ventriculoperitoneal shunt

Joon-Hyung Kim, David W. Roberts, David F. Bauer

Section of Neurosurgery, Dartmouth-Hitchcock Medical Center, Lebanon, NH, USA

E-mail: *Joon-Hyung Kim - Joon-Hyung.Kim@hitchcock.org; David W. Roberts - David.W.Roberts@hitchcock.org;

David F. Bauer - David.F.Bauer@hitchcock.org

*Corresponding author

Received: 20 December 14 Accepted: 05 March 15 Published: 23 July 15

This article may be cited as:

Kim JH, Roberts DW, Bauer DF. CSF hydrothorax without intrathoracic catheter migration in children with ventriculoperitoneal shunt. *Surg Neurol Int* 2015;6:S330-3.

http://surgicalneurologyint.com/surgicalint_articles/CSF-hydrothorax-without-intrathoracic-catheter-migration-in-children-with-ventriculoperitoneal-shunt/

Copyright: © 2015 Kim JH. This is an open-access article distributed under the terms of the Creative Commons Attribution License, which permits unrestricted use, distribution, and reproduction in any medium, provided the original author and source are credited.

Abstract

Background: Thoracic complications of ventriculoperitoneal (VP) shunts have been extensively reported in the literature. Cerebrospinal fluid (CSF) hydrothorax without catheter migration, however, has been rarely described and poorly understood.

Case Description: We describe development of pleural effusion and respiratory distress in a 3-year-old boy with no evidence of VP shunt catheter displacement on plain radiograph and stable ventricle size on rapid sequence magnetic resonance imaging (MRI) brain. Chest X-ray revealed complete opacity of right hemithorax. Pleural effusion was consistent with transudate. Beta-2 transferrin returned positive. The patient underwent externalization of VP shunt, and upon resolution of effusion, re-internalization with new distal shunt catheter. A literature review of CSF hydrothorax in children without intrathoracic shunt migration was performed. Eleven cases were identified in the English literature. Age at VP shunt placement ranged from birth to 8 years of age. Interval from VP shunt placement to CSF hydrothorax ranged from 1.5 months to 5 years. History of shunt revision was reported in two cases. Presenting symptoms also included ascites and inguinal hernia or hydrocele. Reported diagnostic studies consist of CSF culture, radionuclide shuntogram, beta-2 transferrin, and beta-trace protein. Laterality of the VP shunt and development of pleural effusion were predominantly right sided. Definitive surgical treatment included VA shunt, repositioning of the peritoneal catheter, and endoscopic choroid plexus coagulation.

Conclusion: CSF hydrothorax is a rare thoracic complication of VP shunt placement with no radiographic evidence of shunt migration or malfunction. Postulated mechanisms include limited peritoneal capacity to resorb CSF in children and microscopic communications present in congenital diaphragmatic hiatuses.

Key Words: Cerebrospinal fluid hydrothorax, shunt malfunction, ventriculoperitoneal shunt

Access this article online

Website:

www.surgicalneurologyint.com

DOI:

10.4103/2152-7806.161408

Quick Response Code:



INTRODUCTION

Complications of ventriculoperitoneal (VP) shunt have been reported extensively in the literature.

Thoracic manifestations include pleural effusion, bronchial perforation, pneumothorax, and pneumonia. Cerebrospinal fluid (CSF) pleural effusion in the absence of migration of distal VP shunt catheter in

children, however, has been rarely described and poorly understood.^[11] We report a case of CSF hydrothorax in a child with no radiographic evidence of VP shunt migration and review the literature on associated clinical findings.

CASE HISTORY

History and Examination

The patient is a 3-year-old boy born at 40 weeks by Cesarean section who initially presented with congenital hydrocephalus. He had right VP shunt placement at birth, with subsequent revisions at 13 and 23 months of age. He became symptomatic 10 days prior to presentation with progressive viral-like upper respiratory symptoms, including poor oral intake, intermittent fever, cough, irritability, and an ill appearance. Patient's co-morbidities include intractable epilepsy and craniosynostosis.

On examination, he was somnolent, but he would open his eyes spontaneously. He had full strength in all extremities. His shunt incisions and shunt track were nonerythematous and nontender. No swelling was seen along the track. He demonstrated intermittent cough with mild desaturations to 89%. Laboratory studies were within normal limits aside from mild thrombocytopenia ($79 \times 10^3/\text{mcL}$) and elevated valproic acid level (183 mg/L; reference therapeutic range 50–100 mg/L).

Imaging

Chest radiograph revealed complete opacification of the right hemithorax with mediastinal displacement [Figure 1]. Radiographic shunt series revealed radiographically intact VP shunt without migration into the thorax [Figure 2]. Quick-brain magnetic resonance imaging (MRI) revealed stable appearance of the ventricles without change in ventricular

size or new extra-axial fluid collections. Ultrasound of the abdomen and the thorax confirmed right sided pleural effusion, underlying atelectatic lung, and a small amount of ascites.

Hospital course

A chest tube was inserted on the right side with drainage of 800 ml of straw colored fluid under pressure. The fluid profile was that of a transudate without infection. The patient's mental status immediately improved. Chest tube output was brisk with 500 ml over the initial 24 h, and increasing to an output of approximately 50 ml/h. The valproic acid dose was decreased given the supratherapeutic level.

Beta-2 transferrin was sent from the chest tube drainage, resulting in a positive study. The final CSF culture was negative for infection. A decision was made to externalize the VP shunt at the abdomen, following which the chest tube output decreased considerably. The chest tube was placed to water seal with no re-accumulation of pleural fluid. The patient returned to the operating room for replacement and internalization of distal peritoneal tubing.

Postoperatively, the chest tube was maintained on water seal for 48 h without an increase in output. Serial ultrasound exam demonstrated no re-accumulation of pleural fluid, and the chest tube was subsequently removed. At 1 year follow-up, he has no re-accumulation of pleural fluid, and no signs or symptoms of shunt malfunction.

DISCUSSION

Upon initial presentation, the right chest opacity on chest radiograph was initially thought to be related to valproate toxicity resulting in an eosinophilic effusion. Consistent with this diagnosis was the patient's depressed mental state and thrombocytopenia. When the chest tube was

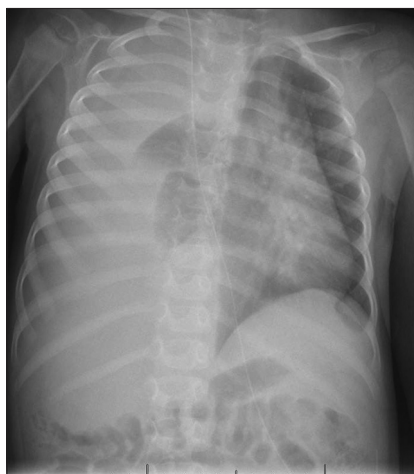


Figure 1: Chest radiograph demonstrates pleural effusion in right hemithorax

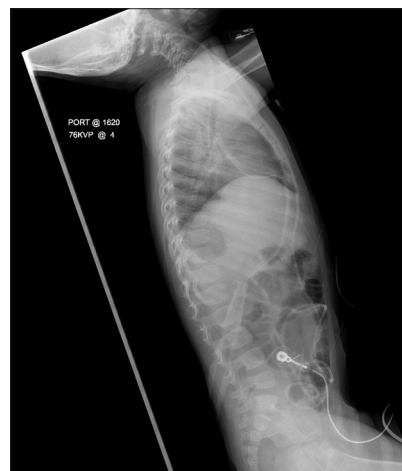


Figure 2: X-ray shunt series show no evidence of shunt disconnect

inserted, however, pleural fluid analysis was negative for eosinophils. Pleural fluid was transudative with mostly macrophage predominant cellularity and no evidence of malignant cells. The patient did not have symptoms of common etiologies for transudative effusions, such as congestive heart failure (no cardiomegaly on chest X-ray, no S3 on auscultation, no hepatomegaly, normal pulses and blood pressure), nephrotic syndrome (normal urine output, normal serum albumin, no peripheral edema), and liver failure (normal hepatic function tests, normal coagulation tests). Despite improved respiratory status following pleural drainage, the patient continued to have persistent clear fluid drainage from his chest tube at approximately 50 ml/h. Beta-2 transferrin was sent, and its positive result confirmed the diagnosis of CSF hydrothorax.

Thoracic complications of VP shunts have been previously outlined into three categories:^[11] intrathoracic trauma during placement of a shunt, migration of the peritoneal catheter into the chest, or pleural effusion accompanying CSF ascites. In the absence of iatrogenic injury or migration of the peritoneal catheter, symptomatic CSF hydrothorax may infrequently result with and without concomitant CSF ascites.^[12] Absence of radiographic signs of shunt malfunction, disconnect, or intrathoracic migration of the catheter, however, raises a diagnostic challenge. Radionuclide shuntogram and beta-2 transferrin assays of pleural fluid are of significant diagnostic utility in suspected cases of CSF hydrothorax.

The mechanism of CSF hydrothorax in children without VP shunt catheter displacement remains less clear. Migration of CSF from the peritoneal to the pleural cavity depends on two factors: Malabsorption of CSF in the peritoneal cavity and open communication between the peritoneal and the pleural cavities to enable intraperitoneal CSF to pass into the pleural cavity.^[6] A theoretical risk factor is the limited peritoneal capacity to resorb CSF in children, resulting in CSF ascites and associated pleural effusion. Possible contributory factors also include history of abdominal infection, abdominal surgery, and formation of pseudocysts.^[5] Another possibility is mechanical leakage of CSF from the shunt valve, the catheter, or between their connection, which is most likely suspected to be the case in our patient.

Conduits for intrathoracic catheter migration traditionally have been suggested to involve congenital diaphragmatic hiatuses, such as the anterior foramen of Morgagni and the posterior foramen of Bochdalek.^[7] In children, these areas in the diaphragm are also easily eroded or can harbor microscopic communications undetectable by thoracoscopy or nuclear imaging studies.^[9] Chronic inflammation can further facilitate transudation of CSF fluid via capillary and lymphatic channels in the diaphragm. A cyclic pressure gradient, created by negative

intrathoracic pressure during inspiration and positive abdominal pressure during expiration, is presumed to allow unidirectional flow of CSF.^[3]

In view of these mechanistic factors, a literature review of CSF hydrothorax in children without intrathoracic catheter migration was performed. A total of 11 pediatric cases of CSF hydrothorax without intrathoracic catheter migration were identified in the English literature [Table 1]. Age at VP shunt placement ranged from birth to 8 years. Interval time to CSF hydrothorax ranged from 1.5 months to 5 years. Clinical risk factors for poor abdominal re-absorption of CSF were identified in two cases (18%), including one patient who had a prior abdominal surgery (Nissen fundoplication)^[3] and another who previously had been diagnosed with necrotizing enterocolitis.^[4] Interestingly, both resulted in shunt revision. By contrast, our patient underwent two prior shunt revisions in the absence of apparent abdominal risk factors.

Common presenting symptoms included ascites (N = 4) and inguinal hernia or hydrocele (N = 3). None of the patients with these symptoms had a history of shunt revision. It is widely accepted that very young children with poor abdominal re-absorptive capacity are susceptible to development of hydrocele or inguinal hernia following placement of VP shunt. While relatively little is known whether these presenting abdominal symptoms have any relation to CSF hydrothorax development, ascites appeared to occur mutually independent from inguinal hernia or hydrocele [Table 1]. Consistent with this trend, findings in our patient included mild ascites but no inguinal hernia or hydrocele.

As reported in Table 1, diagnostic studies reported in the literature, in descending order of frequency, consisted of CSF culture, radionuclide shuntogram, beta-2 transferrin, and beta-trace protein. CSF culture was documented in eight cases (73%). Radionuclide shunt study was obtained in five cases (45%). Beta-2 transferrin was sent in four cases (36%), all of which returned positive. One report utilized beta-trace protein, which was positive. Variability in diagnostic methods may be related to diagnostic preference or institutional availability of these tests as reflected by the wide geographic origin of the report series.^[1]

A chest tube was placed in 5 of 11 cases (45%) for management of pleural effusion. Laterality of VP shunt was right-sided (82%), left-sided (9%), and not reported (9%). Pleural effusion developed in the right lung (82%), left lung (9%), and bilateral lungs (9%). While most VP shunts and resultant hydrothorax were right-sided, laterality of VP shunt did not overlap with concomitant hydrothorax when it occurred in the left.^[2] There was one case of right-sided VP shunt resulting in bilateral involvement of the lungs.^[4]

Table 1: Series of CSF hydrothorax in children without intrathoracic catheter migration

Series	Origin	Prior shunt revision	Prior abdominal surgery	Ascites	Inguinal hernia or hydrocele	CSF culture	Beta-2 transferrin	Radionuclide shuntogram	Chest tube	Laterality of VP shunt	Laterality of pleural effusion
Globl and Kaufman (1978) ^[5]	Philadelphia, PA, USA	No	No	Yes	No	Sterile	NR	No	No	Right	Right
Faillace and Garrison (1998) ^[4]	Jacksonville, FL, USA	Yes	No	No	No	Sterile	NR	Yes	No	Right	Bilateral
Hadzikaric <i>et al.</i> (2002) ^[6]	Al-Khobar, Saudi Arabia	No	No	No	Yes	Sterile	NR	No	Yes	Right	Left
Adeolu <i>et al.</i> (2006) ^[1]	Osun state, Nigeria	No	No	No	No	NR	NR	No	No	Right	Right
Born <i>et al.</i> (2008) ^[2]	Bonn, Germany	No	No	Yes	No	Sterile	NR*	No	No	Left	Right
Smith and Cohen (2009) ^[10]	Toronto, Canada	No	No	Yes	No	Sterile	Positive	No	Yes	Right	Right
Chuen-im <i>et al.</i> (2011) ^[3]	St. Louis, MO, USA	Yes	Yes	No	No	Sterile	Positive	Yes	Yes	NR	Right
Kocaogullar <i>et al.</i> (2011) ^[7]	Konya, Turkey	No	No	No	Yes	NR	NR	Yes	Yes	Right	Right
Patel <i>et al.</i> (2011) ^[9]	Little Rock, AR, USA	No	No	No	Yes	Sterile	Positive	Yes	No	Right	Right
Ulus <i>et al.</i> (2012) ^[12]	Samsun, Turkey	No	No	No	No	NR	Positive	Yes	Yes	Right	Right
O'Halloran <i>et al.</i> (2013) ^[8]	Dublin, Ireland	No	No	Yes	No	Sterile	NR	No	No	Right	Right

*Beta-trace protein. †Abbreviation NR (Not Reported)

Final surgical treatment modalities ranged from ventriculo-atrial (VA) shunt placement (73%), reposition of peritoneal catheter (18%), and endoscopic choroid plexus coagulation (9%). Of eight patients in whom VA shunt was eventually placed, the catheter was externalized prior to VA shunt placement in two cases, and the peritoneal catheter was repositioned prior to VA shunt placement in one case. Externalization of a distal catheter may guide subsequent strategy for treatment, whether it is conversion to a VA shunt or replacement of the distal VP shunt catheter. Ventriculo-pleural shunt was attempted in one patient but subsequently had to be revised to a VA shunt. Further follow-up data may be useful for determination of long-term efficacy of various surgical revision modalities.

CONCLUSION

CSF hydrothorax is a rare but important complication of VP shunt placement in children without evidence of shunt migration or malfunction. Postulated mechanisms include limited peritoneal capacity to resorb CSF in children and microscopic communications present in congenital diaphragmatic hiatuses. In suspected cases, beta-2 transferrin assay and radionuclide tracer shunt series are useful diagnostic studies. CSF culture is commonly obtained to exclude infection. Thoracocentesis of pleural fluid or chest tube placement facilitates management of persistent pleural effusion. Externalization of the distal shunt catheter may resolve the hydrothorax and may guide subsequent treatment strategy.

REFERENCES

1. Adeolu AA, Komolafe EO, Abiodun AA, Adetiloye VA. Symptomatic pleural effusion without intrathoracic migration of ventriculoperitoneal shunt catheter. *Childs Nerv Syst* 2006;22:186-8.
2. Born M, Reichling S, Schirrmeyer J. Pleural effusion: Beta-trace protein in diagnosing ventriculoperitoneal shunt complications. *J Child Neurol* 2008;23:810-2.
3. Chuen-im P, Smyth MD, Segura B, Ferkol T, Rivera-Spoljaric K. Recurrent pleural effusion without intrathoracic migration of ventriculoperitoneal shunt catheter: A case report. *Pediatr Pulmonol* 2012;47:91-5.
4. Faillace WJ, Garrison RD. Hydrothorax after ventriculoperitoneal shunt placement in a premature infant: An iatrogenic postoperative complication. Case report. *J Neurosurg* 1998;88:594-7.
5. Glöbl HJ, Kaufmann HJ. Shunts and complications. *Prog Pediatr Radiol* 1978;6:231-71.
6. Hadzikaric N, Nasser M, Mashani A, Ammar A. CSF hydrothorax-VP shunt complication without displacement of a peritoneal catheter. *Childs Nerv Syst* 2002;18:179-82.
7. Kocaogullar Y, Guney O, Kaya B, Erdi F. CSF hydrothorax after ventriculoperitoneal shunt without catheter migration: A case report. *Neurol Sci* 2011;32:949-52.
8. O'Halloran PJ, Kaliaperumal C, Caird J. Chemotherapy-induced cerebrospinal fluid malabsorption in a shunted child: Case report and review of the literature. *BMJ Case Rep* 2013;2013:pil: bcr2012008255.
9. Patel AP, Dorantes-Argandar A, Raja AI. Cerebrospinal fluid hydrothorax without ventriculoperitoneal shunt migration in an infant. *Pediatr Neurosurg* 2011;47:74-7.
10. Smith JC, Cohen E. Beta-2-transferrin to detect cerebrospinal fluid pleural effusion: A case report. *J Med Case Rep* 2009;3:6495.
11. Taub E, Lavyne MH. Thoracic complications of ventriculoperitoneal shunts: Case report and review of the literature. *Neurosurgery* 1994;34:181-3.
12. Ulus A, Kuruoglu E, Ozdemir SM, Yapici O, Sensoy G, Yazar E, *et al.* CSF hydrothorax: Neither migration of peritoneal catheter into the chest nor ascites. Case report and review of the literature. *Childs Nerv Syst* 2012;28:1843-8.