Intracranial Dural Arteriovenous Fistulas

Characteristics, Treatment and Long-Term outcome

Anna Piippo

Department of Neurosurgery
Helsinki University Central Hospital
University of Helsinki
Helsinki, Finland

and

KUH NeuroCenter, Kuopio University Hospital
University of Kuopio
Kuopio, Finland

ACADEMIC DISSERTATION

To be publicly discussed,
with the permission of the Faculty of Medicine of the University of Helsinki
in Lecture Hall 1 of Töölö Hospital
on June 7th, 2013 at 12 o'clock noon.

Helsinki 2013

Supervisors

Professor **Juha Hernesniemi**
Department of Neurosurgery
Helsinki University Central Hospital
Helsinki, Finland

Associate Professor **Mika Niemelä**
Department of Neurosurgery
Helsinki University Central Hospital
Helsinki, Finland

Reviewers

Associate Professor **Ville Vuorinen**
Department of Neurosurgery
Turku University Hospital
Turku, Finland

Associate Professor **Arto Haapanen**
Department of Radiology
University of Turku
Turku, Finland

Opponent

Professor **Ali F. Krisht**
Director, Arkansas Neuroscience Institute
University of Arkansas for Medical Sciences
Little Rock, Arkansas

© Anna Piippo 2013
Cover and illustrations © Anna Piippo 2013

ISBN 978-952-10-8816-2 (Paperback.)
ISBN 978-952-10-8817-9 (PDF)

Helsinki University Printing House
Helsinki 2013
Finland

Author's contact information:

Anna Piippo
Department of Neurosurgery
Helsinki University Central Hospital
Topeliuksenkatu 5
00260 Helsinki
Finland
mobile: +358 50 4270386
fax: +358 9 471 87560
e-mail: anna.piippo@hus.fi

Table of contents

Abstract 10

Abbreviations 12

List of original publications 13

1 Introduction 15

2 Review of the literature 17

2.1 Intracranial dural arteriovenous fistulas 17
2.1.1 Definition 17
2.1.2 Epidemiology 17
2.1.3 Historical aspects 17
2.1.4 Pathophysiology 17
2.1.4.1 Sinus thrombosis 17
2.1.5 Anatomic features 18
2.1.5.1 Classification 18
2.1.6 Imaging 19
2.1.6.1 Digital subtraction angiography (DSA) 19
2.1.6.2 Magnetic resonance imaging (MRI) and angiography (MRA) 20
2.1.6.3 Computed tomography (CT) and angiography (CTA) 21
2.1.8 Natural history 22

2.2 Treatment of intracranial dural arteriovenous fistulas 22
2.2.1 Historical aspects 22
2.2.1.1 Surgical treatment 22
2.2.1.2 Embolization 22
2.2.1.3 Radiosurgery 23
2.2.1.4 DAVF treatment in Helsinki and Kuopio 23
2.2.2 Treatment options 24
2.2.2.1 Observation 24
2.2.2.2 Selective disconnection of cortical venous drainage 24
2.2.2.3 Multimodality treatment 25

3 Aims of the Study 27

4 Materials and Methods 29

4.1 Publication I: Clinical characteristics and long-term outcome 29
4.1.1 Patients 29
4.1.2 Data collection 29
4.1.3 Follow-up 29
4.1.4 Statistical analysis 30

4.2 Publication II: Long-term excess mortality 30
4.2.1 Patients 30
4.2.2 Data collection during follow-up 30
4.2.3 Statistical analysis 30

4.3 Publication III: Microneurosurgical management of DAVFs 31
4.3.1 Patients 31
4.3.2 Follow-up 31
4.3.3 Statistical analysis 31

5 Results 33

5.1 Incidence of dural arteriovenous fistulas 33

5.2 Clinical characteristics and outcome of DAVF patients (Publication I) 33
5.2.1 Patient characteristics 33
5.2.2 DAVF characteristics 34
5.2.3 Long-term occlusion rates 36
5.2.4 Complications of treatment 39
5.2.5 Neurological long-term outcome 39

5.3 Long-term mortality and excess-mortality (Publication II) 40
5.3.1 Long-term mortality 40
5.3.2 Short-term excess mortality 40
5.3.3 Long-term excess mortality among one-year survivors 41

5.4 Microneurosurgery of DAVFs (Publication III) 43
5.4.1 Special considerations in the microneurosurgery of DAVFs 44
5.4.2 Transverse and sigmoid sinus DAVFs 44
5.4.2.1 Approach and positioning 44
5.4.2.2 Craniotomy and dural opening 45
5.4.2.3 Occlusion of the fistula 46
5.4.3 Cavernous sinus DAVFs 46
5.4.3.1 Approach and positioning 46
5.4.3.2 Craniotomy 46
5.4.3.3 Occlusion of the fistula 46
5.4.4 Tentorial DAVFs 46
5.4.4.1 Approach and positioning 46
5.4.4.2 Craniotomy 46
5.4.4.3 Dural opening and occlusion of the fistula 47
5.4.5 Frontobasal DAVFs 47
5.4.5.1 Approach and positioning 47
5.4.5.2 Craniotomy 47
5.4.5.3 Occlusion of the fistula 48
5.4.6 Pitfalls of microneurosurgery 49
5.4.7 Verification of complete occlusion 50
5.4.7.1 Intraoperative imaging 50
5.4.7.2 Postoperative imaging 50

6 Discussion 53

7 Conclusions and recommendations 57

7.1 The role of microneurosurgery in management of DAVFs 57

List of 6 supplementary videos on microneurosurgery of DAVFs 59

Acknowledgements 61

References 65

Abstract

Background and purpose: Dural arteriovenous fistulas (DAVFs) represent 10-15% of all intracranial AVM's. Population-based long-term outcome studies of DAVFs are scarce due to the rarity of DAVFs. Increased knowledge of their pathophysiology and natural history, and advances in treatment modalities have changed the management of the DAVFs during the last decades. In this study we assessed the epidemiology, special characteristics and long-term outcome of DAVF patients. In addition, we presented the evolution of management and results of different treatment modalities, focusing on the current and future role of microsurgery in DAVF treatment.

Patients and methods: We analyzed 283 patients with 293 intracranial DAVFs, admitted in two the of five Departments of Neurosurgery in Finland (Helsinki and Kuopio), between 1944 and 2010. Clinical data and radiological examinations of 251 consecutive patients from 1944 to 2006 were reviewed to assess the overall long-term clinical outcome. In a subgroup of 227 patients, long-term excess mortality was estimated using the relative survival ratio (RSR), which provides a measure of the excess mortality experienced by the patients compared with the general Finnish population matched by age, sex and calendar time. The results of microsurgical treatment of DAVFs were analyzed in 116 consecutive patients treated between 1980 and 2010.

Results: The detection rate of DAVFs increased markedly in the 1970's and again in the 1990's when the digital subtraction angiography (DSA) was introduced. The incidence of DAVFs in a defined Southern Finnish population was 0.51 per 100,000 per year, and they represented 32% of all the brain arteriovenous malformations (AVMs). There was a slight female predominance among the patients (55%). The most common locations of DAVF in the patients admitted between 1944 and 2006 were transverse and sigmoid sinus (61%) and cavernous sinus (10%). Cortical venous drainage (CVD) was present more often in men (46%) than in women (24%). The overall occlusion success of the DAVFs treated since 1944 was 59%. Total occlusion rate improved from 53% by feeding artery ligation in the early series to 87% achieved with embolization and craniotomy. Endovascular treatment resulted in complete obliteration in 51% of the cases, whereas occlusion success after microsurgery was 86%. Particularly in tentorial, cavernous sinus and transverse-sigmoid sinus DAVFs, total occlusion was achieved more often by microsurgical means than by endovascular technique. After mean follow-up time of 3.1 years (greatest duration 40.2 years), 87% of the patients had a good outcome (GOS 4-5).

The occlusion success was 89% in microsurgically treated DAVFs between 1980 and 2010. Complete occlusion was achieved in all cavernous sinus, torcular, anterior fossa, foramen magnum and superior sagittal sinus DAVFs, and in 91% of tentorial, 87% of transverse-sigmoid sinus, 86% of convexity DAVFs. Severe bleeding occurred in 7.8% of the procedures, and major hemorrhagic or ischemic complications were seen in 12% of the patients. At the end of the follow-up, 95% of the patients had a good outcome (GOS 4-5).

During the first 12 months, there was excess mortality among the patients, mainly due to treatment complications. Thereafter, their overall long-term survival became similar to that of matched general population. DAVFs with CVD and those located elswhere than transverse and sigmoid sinuses were associated with marked long-term excess mortality after surviving the first year. The patients had more cardiovascular and cerebrovascular deaths than would be expected in the general Finnish population, for an unknown reason.

Conclusions: The advances in diagnostic methods (DSA, CT, MRI) have increased the detection rate of DAVFs. The results of treatment and outcome of patients have markedly improved with the introduction of endovascular techniques and stereotactic radiosurgery (SRS). Currently, microsurgery is of limited use in those DAVFs where endovascular treatment and radiosurgery have failed to reduce the high risk of hemorrhage especially in tentorial and ethmoidal DAVFs. Also, even patients with Borden type I DAVFs with intolerable symptoms could be considered for microsurgical treatment. Treatment of these challenging lesions should be performed in dedicated neurovascular centers with all treatment modalities available. Treatment complications cause excess mortality to DAVF patients during the first 12 months. Thereafter, long-term excess mortality exists in the patients harboring DAVFs with CVD and in the patients with DAVFs in locations other than transverse and sigmoid sinuses.

Abbreviations

AVM	Arteriovenous malformation
bFGF	Basic fibroblast growth factor
CCA	Common carotid artery
CCF	Carotid cavernous fistula
CT	Computed tomography
CVD	Cortical venous drainage
DAVF	Dural arteriovenous fistula
DMSO	Dimethyl sulfoxide
DSA	Digital subtraction angiography
ECA	External carotid artery
EDH	Epidural hematoma
EVOH	Ethylene vinyl alcohol
GOS	Glasgow outcome scale
ICA	Internal carotid artery
ICG-VA	Indocyanine green video angiography
ICH	Intracerebral hemorrhage
IVH	Intraventricular hemorrhage
LSO	Lateral suboccipital approach
MRA	Magnetic resonance angiography
MRI	Magnetic resonance imaging
NBCA	N-butyl cyanoacrylate
NHND	Non-hemorrhagic neurological deficit
PVA	Polyvinyl alcohol
RSR	Relative survival ratio
SAH	Subarachnoid hemorrhage
SDH	Subdural hematoma
SRS	Stereotactic radiosurgery
SSS	Superior sagittal sinus
TOF MRA	Time-of-flight magnetic resonance angiography
TRICKS	Time-resolved imaging of contrast kinetics
VA	Vertebral artery
VEGF	Vascular endothelial growth factor

List of original publications

This thesis is based on the following publications referred to in the text by their roman numerals:

I Piippo A, Niemelä M, van Popta J, Kangasniemi M, Rinne J, Jääskeläinen J, Hernesniemi J. Characteristics and long-term outcome of 251 patients with dural arteriovenous fistulas in a defined population. *J Neurosurg*: 2013 May;18(5):923-934. Epub 2012 Dec 21.

II Piippo A, Laakso A, Seppä K, Rinne J, Jääskeläinen J, Hernesniemi J, Niemelä M. Early and long-term excess mortality in 227 patients with intracranial dural arteriovenous fistulas. *J Neurosurg*: 2013 April 19. [Epub ahead of print].

III Piippo A, Niemelä M, Elsharkawy A, van Popta J, Kivisaari R, Rinne J, Jääskeläinen J, Hernesniemi J. Microsurgery of dural arteriovenous fistulas – Basics and tricks: Lessons learned from 116 cases. *J Neurosurg*: 2013 Submitted.

The original publications are reproduced with permission of the copyright holders.

1 Introduction

Dural arteriovenous fistulas (DAVFs) are abnormal fistulous connections between the dural arteries and venous sinuses and/or cortical veins. They account for 10-15% of all intracranial arteriovenous malformations (AVMs).[163] Their detection rate in adults is 0.16 per 100,000 per year.[2]

The majority of DAVFs are acquired lesions with no obvious predisposing factor.[26,94,152] However, studies have shown association between sinus thrombosis and DAVF formation.[26,94,163] Patients with thrombophilic abnormalities (APC resistance, mutations in factor V Leiden and factor II G20210A) are reported to be at a higher risk for DAVFs.[116,117,216] Other possible causes are trauma,[53,160,223] intracranial surgery,[160,223] sinus infection and association with meningiomas.[47,212,232]

Patients most commonly present with intolerable pulsatile tinnitus. Other symptoms include exophthalmos, chemosis, headache, progressive dementia, seizures, or neurological deficits often caused by intraparenchymal hemorrhage.[59,63,125,165]

DAVFs are most frequently located in the region of transverse, sigmoid and cavernous sinuses.[125] However, they can occur anywhere within the dura. The classification of DAVFs is based on the venous drainage known to predict their clinical behavior. Nowadays, the most commonly used are Borden and Cognard classifications.[16,32] Borden type I and Cognard type I and IIa, commonly referred to as benign DAVFs, drain directly into venous sinuses, whereas in Borden type II and III, and Cognard types IIb, IIa+b, III and IV, there is a direct or indirect drainage to cortical veins. Cortical venous drainage (CVD) is known to predict more aggressive clinical behavior including hemorrhage and nonhemorrhagic neurological deficits (NHND).[5,16,19,32,93,125] Cognard type V DAVFs drain into spinal perimedullary veins.

The cavernous sinus DAVFs are classified according to Barrow classification.[11] Barrow type A fistulas are direct high flow shunts between internal carotid artery (ICA) and cavernous sinus. They are usually caused by trauma or rupture of an intracavernous ICA aneurysm. They are often referred to as carotid cavernous fistulas (CCF) and form a different entity from Barrow types B, C and D, which are true DAVFs with indirect low flow from meningeal branches of ICA or external carotid artery (ECA), or from both into cavernous sinus.

During the past decades, advances in neuroradiology have led to a better understanding of these lesions, and as microsurgical, endovascular and radiosurgical techniques have simultaneously developed, treatment strategy of DAVFs has also changed. As DAVFs are relatively rare, only a few large series have been published and there are still no reports on how the evolution of the treatment strategies of DAVFs has actually affected the results of treatment.

Population-based long-term outcome studies of DAVFs are scarce due to the rarity of the lesions. Finland is well suited for population-based epidemiological studies due to its high-quality public health care system, comprehensive and accessible hospital records and vital statistics, and relatively stable and homogeneous population. Treatment of all DAVFs is centralized to public university hospitals with population responsibility.

This study presents the 66-year experience in the treatment of 283 consecutive patients with 293 intracranial DAVFs, in two Departments of Neurosurgery in Finland (Helsinki and Kuopio), between 1944 and 2010. To our knowledge, this is one of the largest series published with the longest follow-up period. Special characteristics and long-term outcome of the patients were assessed. The results of different treatment modalities in relation to the DAVF location were compared with special emphasis on mircrosurgical treatment.

2 Review of the literature

2.1 Intracranial dural arteriovenous fistulas

2.1.1 Definition

Intracranial dural arteriovenous fistulas (DAVFs) are acquired lesions characterized by a focal area of abnormal arteriovenous fistulous connections within the dura.[26,71,94,203] They usually occur in the proximity of venous sinuses, but may develop anywhere within the dura. Their arterial supply arises from any of the dural branches[154] of internal carotid artery (ICA), external carotid artery (ECA) and vertebral artery (VA), and sometimes from small pial branches. The venous drainage occurs into dural veins and sinuses, cortical or pedimedullary veins, or into a combination of them.

2.1.2 Epidemiology

DAVFs represent 10-15% of all intracranial AVM's according to the study by Newton et al from 1969.[163] In a Scottish population-based study, the approximated detection rate of DAVFs in adults was 0.16 per 100,000 per year.[2] In the same population, the detection rate of cerebral AVMs was 1.12 per 100,000 per year, giving the DAVFs a proportion of 12.5% of all intracranial AVMs. Brown et al. reported the detection rate of 0.15 per 100,000 per year among residents of Olmsted County, Minnesota over a 27-year period.[20] A recent Japanese epidemiological survey showed a higher detection rate, 0.29 per 100,000 per year.[192]

The mean age of DAVF patients is between 50 and 60 years,[32,48] but DAVFs can occur at any age. Contrary to adults, the DAVFs in children are usually congenital.

2.1.3 Historical aspects

The earliest report on recorded cases of abnormal communication between artery and vein was by Hunter in 1757.[166] In 1873 Rizzoli described the presence of a dural-based arteriovenous aneurysm causing pulsatile tinnitus and seizures in a 9-year-old girl.[24,176] Autopsy revealed fistulous connection between the occipital artery and transverse sinus. The earliest observations of fistulas occurring in the brain substance were reported by Steinheil in 1895, Hoffman in 1898, and Isenschmid in 1912, followed by clinico-pathological report by Cushing and Bailey in 1928.[166] Angiographic appearance of intracranial dural arteriovenous fistulas was first described by Sachs in 1931, followed by Tönnis in 1936.[24,54,70,190] In 1951, Verbiest and Fincher introduced the concept of spontaneous dural arteriovenous fistula.[54,190] The first cases of congenital high-flow dural arteriovenous fistulas in children were reported in 1964.[54,190]

2.1.4 Pathophysiology

Most of the DAVFs are believed to develop after sinus thrombosis.[12,26,55,93,94,177] Other initiating events include intracranial surgery[223] and head trauma, often with skull fracture.[15,30,64] DAVFs are also associated with meningiomas, hormonal alterations during pregnancy and menopause, sinus infections and otitis. Nevertheless, the pathophysiology of these lesions has remained uncertain.

2.1.4.1 Sinus thrombosis

Some DAVFs are clearly associated with sinus thrombosis. However, there is no association between the presence of sinus thrombosis and the gender of the patient, or the location or type of DAVF.[211] According to the first theory,[94] DAVFs are caused by angiogenic factors released from organizing thrombus leading to

Table 1. *The Borden classification of DAVFs.*

Lesion type	Definition
I	drains directly antegrade into major venous sinus
II	drains into venous sinus with retrograde drainage into subarachnoid veins
III	drains directly into subarachnoid veins (CVD only)

Table 2. *The Cognard classification of DAVFs.*

Lesion type	Definition
I	drains into dural venous sinus with antegrade flow
IIa	drains into dural venous sinus with retrograde flow
IIb	drains into dural venous sinus with antegrade flow + CVD
IIa + b	drains into dural venous sinus with retrograde flow + CVD
III	drains directly into subarachnoid veins (CVD only)
IV	drains directly into subarachnoid veins with ectasia of the draining vein
V	drains directly into spinal perimedullary veins

invasion of small dural arteries and formation of small dural arteriovenous shunts. Another theory suggests that DAVFs arise from naturally occurring dormant channels between dural arteries and sinuses, which open when the sinus is occluded and venous pressure is increased.[159,180] Venous hypertension may also increase angiogenic activity[114,126] or lead to local tissue hypoxia that initiates neoangiogenesis and endothelial proliferation,[208] thus leading to DAVF formation. Histological study suggests that microscopic thrombosis is always present and plays an important role in the release of growth factors and the formation of DAVFs.[213] In immunohistochemical studies, expression of basic fibroblast growth factor (bFGF) and vascular endothelial growth factor (VEGF) has been identified in the wall of the dural sinuses in patients with DAVFs.[206,213]

Patients with thrombophilic abnormalities (APC resistance, antithrombin III deficiency, mutations in factor V Leiden and factor II G20210A) are reported to be at a higher risk for DAVFs.[69,68,116,118,117,189,216] However, not all patients with sinus thrombosis will develop a fistula. Therefore, sinus thrombosis per se can be considered as one of the multiple possible factors ultimately leading to DAVF formation.

2.1.5 Anatomic features

DAVFs can occur anywhere within the dura. Most frequently they are located in the region of transverse, sigmoid and cavernous sinuses.[125] In transverse-sigmoid sinus DAVFs, there is a slight left-sided predominance.[83] Most of the DAVFs are single lesions, but multiplicity of the lesions has also been reported.[9,214]

2.1.5.1 Classification

In the reports from 1960, DAVFs were grouped by their location into cavernous sinus,[82] transverse-sigmoid sinus,[123,171] and anterior fossa lesions.[125,132] In 1973, Aminoff proposed a classification based on their topography.[3] The fistulas were divided into anteroinferior and superior posterior groups. The first classification distinguishing the DAVFs draining into cortical veins was by Castaigne in 1976.[21,54]

In 1977 Djindjian proposed the first comprehensive classification of intracranial DAVFs based on angioarchitecture.[55] The present classification of DAVFs is based on the venous drainage, which is known to predict their clinical behavior.[5] The most commonly used ones are the Cognard classification, which is a modification of Djindjian classification, and a simplified version of Borden (Tables 1 and 2, Figures 1-3), validated by Davies.[16,32,48]

Table 3. *The Barrow classification of cavernous sinus DAVFs*

Lesion type	Definition
A	direct high-flow shunt between ICA and cavernous sinus
B	indirect low-flow dural shunts between meningeal branches of ICA and cavernous sinus
C	indirect low-flow dural shunts between meningeal branches of ECA and cavernous sinus
D	indirect low-flow dural shunts between meningeal branches of both ICA and ECA and cavernous sinus

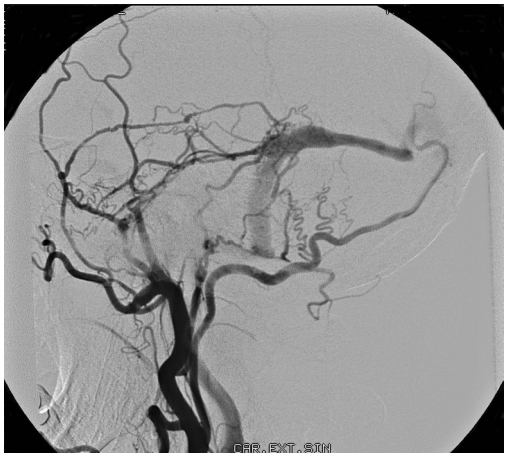

Figure 1. *Borden type I transverse-sigmoid sinus DAVF with antegrade flow into the sinus.*

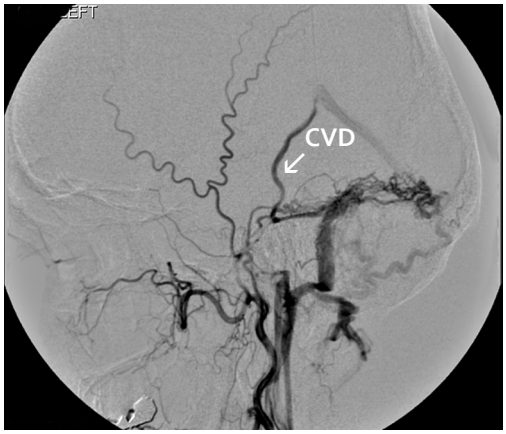

Figure 2. *Borden type II transverse-sigmoid sinus DAVF with CVD and antegrade flow into the sinus.*

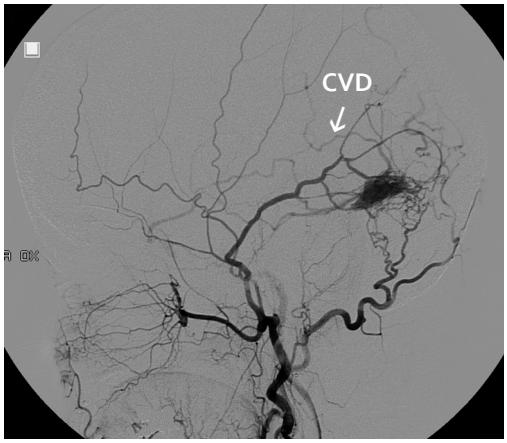

Figure 3. *Borden type III transverse-sigmoid sinus DAVF with CVD only.*

Borden type I and Cognard type I and IIa drain directly into venous sinuses, whereas in Borden type II and III, and Cognard types IIb, IIa+b, III and IV there is direct or indirect reflux to cortical veins, causing more aggressive presentation, including hemorrhage and neurological deficits. Cognard type V DAVFs drain into spinal perimedullary veins.

Barrow classification is used for cavernous sinus DAVFs (Table 3).[11] Barrow type A fistulas are direct high-flow shunts between internal carotid artery (ICA) and cavernous sinus, usually caused by trauma or rupture of an intracavernous ICA aneurysm. They form a separate entity, referred to as direct carotid cavernous fistulas (CCF), and should not be considered as true DAVFs. Barrow types B, C and D are true DAVFs with indirect low flow from meningeal branches of ICA or external carotid artery (ECA), or from both to cavernous sinus.

2.1.6 Imaging

2.1.6.1 Digital subtraction angiography (DSA)

Digital subtraction angiography (DSA) was introduced for clinical use in 1980.[41,157,201] This major advance increased the detection

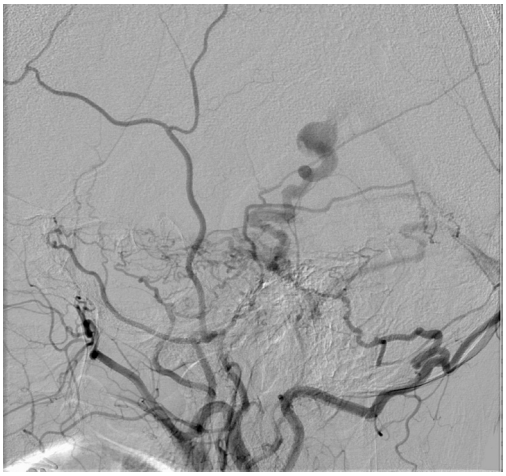

Figure 4. *External carotid artery DSA showing Borden type III tentorial DAVF with direct cortical venous drainage and venous pouch in the area of the vein of Galen.*

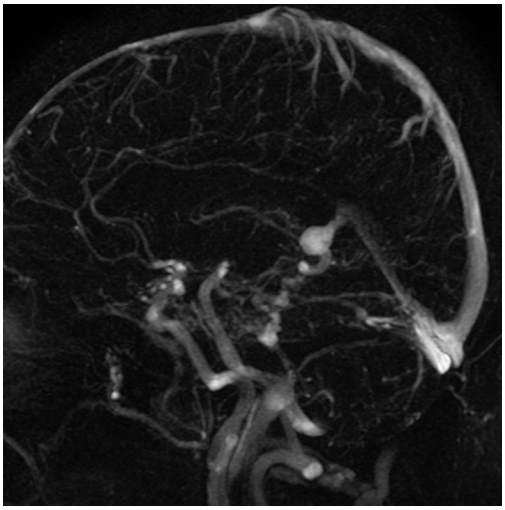

Figure 5. *MRI (TRICKS sequence) of the same patient as in Figure 1 showing pathological flow through the fistula.*

rate of DAVFs. The computerized processing of the images improved the quality of angiographies, thus leading to more accurate diagnosis in vascular pathologies with reduced time necessary for performing the examination and amount of contrast medium required.[17,66,72,137,138,158,174,224] Despite recent advancement of imaging technology, DSA remains to this day the gold standard in diagnosing DAVFs. DSA accurately illustrates the flow dynamics of the fistula and of the circulation of the normal brain. This information is critical both for treatment planning and for assessing the result after treatment (Figure 4). Advances in hardware and software have improved DSA capability enabling imaging in 2D and rotational 3D formats.[60-62,72]

Figure 6. *CT of the same patient as in Figures 1 and 2. An abnormal vascular structure can be seen in the region of the vein of Galen.*

2.1.6.2 Magnetic resonance imaging (MRI) and angiography (MRA)

In case of Borden type I DAVF without CVD, the MRI is usually normal.[121] It may show vein dilatation, venous occlusion, or after contrast enhancement, increased vascularity around the involved sinus.[52] Venous congestion may be seen on MRI as diffuse T2 hyperintensity in the white matter of cerebral or cerebellar hemispheres in DAVFs with CVD.[130,228,227]

In the late 1980's, methods for time resolved MR angiography were developed. Time-of-flight MRA (TOF MRA) is now widely available and usually the primary screening tool

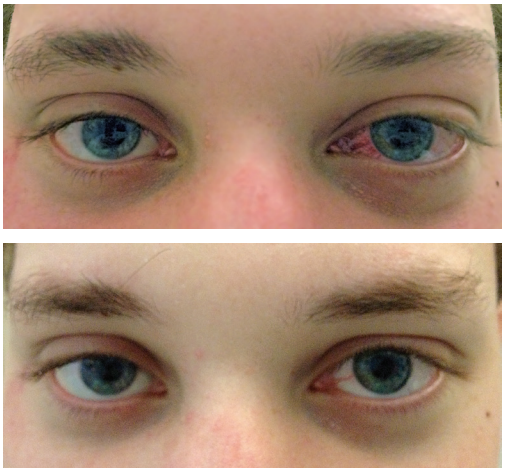

Figure 7. *Slight chemosis and exophthalmos of the left eye in a patient with left cavernous sinus DAVF before and after embolization.*

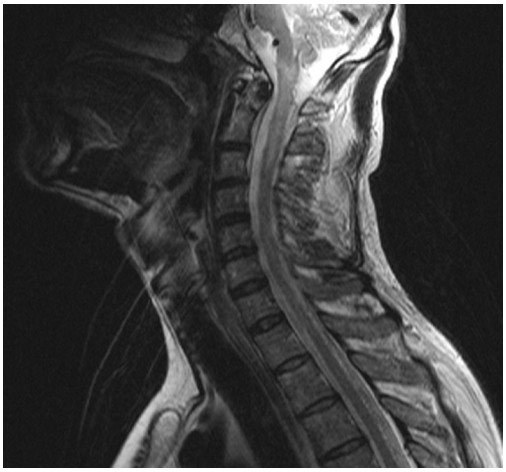

Figure 8. *MRI showing increased T2 signal in cervical spinal cord caused by a tentorial DAVF. The patient presented with progressive tetraparesis, which did not resolve after successful obliteration of the fistula.*

when DAVF is suspected.[27,90,112,194,219] With time-resolved imaging of contrast kinetics (TRICKS) technique introduced in 1996,[115] arterial and venous phases of contrast passage through the brain can be separated, showing the flow dynamics of the DAVF (Figure 5). It is more sensitive than TOF MRA in detecting DAVFs,[173] and a useful non-invasive follow-up tool during the treatment.[181] TRICKS has less accurate spatial resolution than DSA, and therefore DSA is still needed for studying the detailed anatomy of DAVFs.

2.1.6.3 Computed tomography (CT) and angiography (CTA)

Computed tomography (CT) is the primary imaging method in ruptured DAVFs showing intracerebral hemorrhage (ICH), sometimes subarachnoid hemorrhage (SAH), subdural hematoma (SDH) epidural hematoma (EDH) or intraventricular hemorrhage (IVH). CT and conventional CTA may show abnormal vasculature, venous ectasy and pouches related to DAVF (Figure 6).[161] The drawback is its lack of temporal resolution. Dynamic CTA can show pathologic flow dynamics in intracranial vessels indicating the presence of DAVF.[172,226]

2.1.7 Presentation

The clinical presentation of DAVFs is determined by their location and the pattern of the venous drainage.[5,16,59,93,97,110,125,140,165,221] Majority of the patients with transverse-sigmoid sinus DAVFs suffer from various degrees of pulsatile tinnitus, whereas DAVFs in the region of cavernous sinus usually cause exophthalmos and chemosis, and sometimes blindness due to increased intraocular pressure (Figure 7).[202] In transverse-sigmoid sinus DAVFs, the high-flow, low pressure shunt in close proximity to the auditory apparatus causes the pulse-synchronous bruit, which can often be extremely disturbing and prevent sleep. Cavernous sinus DAVFs usually drain into ophthalmic veins and therefore cause ocular symptoms. DAVFs with CVD may present with progressive dementia, seizures, parkinsonism, ataxia, hemorrhage and neurological deficits due to local venous congestion, brain edema and/or ischemia.[34,81,91,97,100,125,129,227] Particularly superior sagittal sinus DAVFs and fistulas that drain into the deep venous system cause these symptoms. These symptoms may be re-

versible after treatment.[100,101,104] DAVFs draining into perimedullary veins may cause myelopathy and progressive tetraplegia (Figure 8).[67,88,98,149,186,220]

2.1.8 Natural history

Most DAVFs are considered relatively benign lesions.[49,63,191,197] Overall, the reported annual risk of hemorrhage is only 1.8%.[19] In patients treated conservatively, spontaneous occlusion of the fistula may occur.[108,124,143,151,188] However, benign DAVFs carry a risk of spontaneous conversion into an aggressive type.[33,108,167,191]

DAVFs with cortical venous drainage (Borden type II-III) behave more aggressively, causing nonhemorrhagic neurological deficits (NHND), ICH and/or SAH.[16,120,125,153,191,195,197,217,218] The Toronto Brain Vascular Malformation Group analyzed a subgroup of 20 DAVFs with CVD out of their 118 patients. DAVFs with CVD had an annual hemorrhage rate of 8.1%, NHND rate of 6.9%, and a combined annual event rate of 15%. The annual mortality rate during 87 person-year follow-up period was 10.4%.[218] Söderman et al. reported lower incidence rates with shorter follow-up time.[197]

Male gender, posterior fossa location, older age at presentation, and focal neurological deficits are associated with hemorrhagic presentation of DAVFs.[162,195] Tentorial and anterior fossa DAVFs are reported to have a risk of hemorrhage as high as 75-95%.[6,32,111,153] Ruptured Borden type II and III carry a high risk of early rebleeding (35% within 2 weeks after the first hemorrhage).[56]

In a series of benign (Borden type I) fistulas reported by Satomi J et al. from the Toronto group, no mortality was reported during a mean follow-up time of 27.9 months.[191] In most of the studies, the mortality of patients with DAVFs and CVD was mainly related to hemorrhage or progressive neurological deterioration.[3,6,8,15,50,53,65] In a study on the natural history of DAVFs by Brown et al, annual mortality rate of 2.3% was detected during a mean follow-up period of 6.6 years.[19]

2.2 Treatment of intracranial dural arteriovenous fistulas

2.2.1 Historical aspects

2.2.1.1 Surgical treatment

The first report on surgical treatment of carotid cavernous fistulas (CCFs) was already published in the 1930's,[44,57] describing the intracranial or extracranial closure of carotid artery with silver clips. Later, various occlusion methods were reported: ligation of the common carotid artery (CCA), ligation of ICA, ligation of both ICA and ECA, ligation of CCA and ICA, ligation of CCA and ECA, and ligation of ICA intracranially and extracranially.[57] Pieces of muscle were also introduced into the circulation from the feeding artery to obliterate the fistula.[18,57,75] These techniques were used in the treatment of intracranial arteriovenous fistulas also in other locations and represented early, rudimentary attempts at "flow-directed" embolization.[93] Hugosson was the first to describe microsugical occlusion of transverse-sigmoid sinus DAVF.[96] In 1983, Sundt and Piepgras further developed the technique.[203]

2.2.1.2 Embolization

Introduction of DSA led to the development of endovascular techniques in treatment of intracranial vascular malformations, including DAVF. At first, polyvinyl alcohol (PVA) particles were used,[204] followed by N-butylcyanoacrylate (NBCA).[10,73,78,109] NBCA was injected to occlude feeding arteries and PVA particles to reduce flow from smaller feeders and to occlude small fistulas.

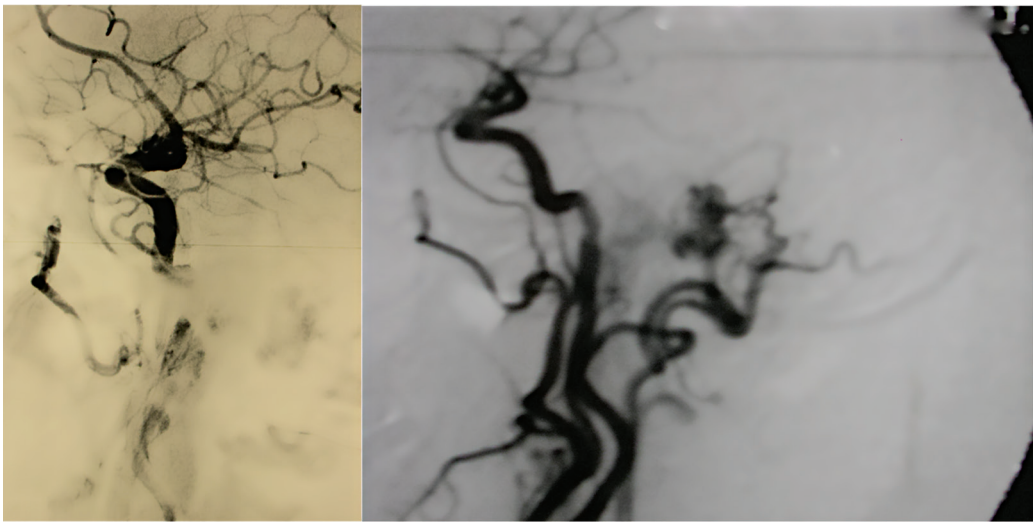

Figure 9. *The first DAVF was microsurgically occluded in Finland in 1987. Carotid angiography shows a left transverse-sigmoid sinus DAVF in a 63-year-old man presenting with severe pulsating bruit.*

Onyx (ev3, Irvine, Calif) has been the greatest advancement in endovascular treatment of DAVFs.[4,35,164,185,210] It is a nonadhesive liquid agent comprised of ethylene vinyl alcohol (EVOH) dissolved in dimethyl sulfoxide (DMSO) that becomes solid when in contact with blood. The solidification occurs more slowly than that of NBCA, and Onyx is nonadherent to the walls of the microcatheter and the vessel walls, thus allowing slower and longer injections with better control. It was first used for cerebral AVM embolization,[102,179] but soon the first reports on its use in the treatment of intracranial DAVFs were published.[4,185,210] Since the introduction of Onyx, the total occlusion rates of DAVFs, especially those with exclusive cortical venous drainage, have markedly increased according to the literature.[4,28,35,95,103,135,141,148,145-147,150,162,164,200,205]

2.2.1.3 Radiosurgery

Leksell introduced radiosurgery already in 1951. In 1972, Steiner and Leksell described its use in the treatment of the cerebral AVMs.[198,199] In the mid 1980's, Colombo, Betti and Derechinsky reported the use of linear accelerator.[13,14,40,38,39] It was not until 1990's that radiosurgical treatment of DAVFs began,[7,25] and since then, its use has rapidly increas ed.[31,65,74,113,136,144,155,168,196,229]

2.2.1.4 DAVF treatment in Helsinki and Kuopio

Surgical treatment

In Finland, the first DAVFs were diagnosed at the Department of Neurosurgery in Helsinki in 1944. The first admitted patients had cavernous sinus DAVFs presenting with pulsating exophthalmos, and they were only observed. In 1952, the first cavernous sinus DAVF was treated by proximal occlusion of common carotid artery with silk ligature. The symptoms were reduced but the DAVF remained partially open. In 1950's and 1960's nearly exclusively cavernous sinus lesions (3 DAVFs and 11 CCFs) with severe symptoms were surgically treated. The others were managed conservatively, as ligation of the feeding artery carried relatively high risk of developing neurological symptoms. In 1962, successful obliteration of anterior fossa DAVF was achieved by proximal ligation of ECA.

The first transverse-sigmoid sinus DAVF was treated by proximal ligation of ECA in 1971. Partial obliteration of the fistula was achieved and the symptoms relieved. Since 1970's increasing number of DAVFs in different locations were treated by proximal ligation of ECA, ICA or both with silk ligature or Crutchfield™ clamp.[42] However, the total occlusion rate was low. Some of the patients did not tolerate the closure of the feeding artery and the DAVF was left partly open. On the other hand, the ones that were totally occluded had a tendency to create new fistulous connections.

As a young surgeon, Juha Hernesniemi was working in Uppsala, Sweden and observing Hugosson who had previously published a report on microsurgical excision of five transverse-sigmoid sinus DAVFs (Hernesniemi, personal communication). At the Mayo clinic, Sundt was the first to perform microsurgical occlusion of DAVFs. Hernesniemi operated on his first transverse-sigmoid sinus DAVF in 1980 by injecting gelatin sponge particles mixed with saline into the external carotid artery resulting in complete occlusion of the fistula. Following the footsteps of Hugosson and Sundt, he performed the first microsurgical occlusion of transverse-sigmoid sinus DAVF in 1987 in Kuopio (Figure 9).[83] Since then, he has operated on altogether 123 DAVFs. He published his first paper concerning the treatment of transverse-sigmoid sinus DAVFs in 1994.[83]

Endovascular treatment and radiosurgery

The first endovascular procedures on DAVFs were performed in 1989 in Kuopio. Two transverse-sigmoid sinus DAVFs were preoperatively embolized. In Helsinki, the endovascular management of intracranial lesions was started with balloon occlusion of a traumatic CCF in 1991. In the same year, two cavernous sinus DAVFs were successfully embolized. The use of Onyx in the treatment of cerebral AVMs and DAVFs began in 2006. Since then, Onyx embolization has been the primary treatment method for intracranial DAVFs.

Radiosurgery using stereotactic linear accelerator with micromultileaf collimator (LINAC 8) started in Helsinki in 2003. The first DAVF patients were treated with LINAC in Kuopio in 2003, and in Helsinki in 2005.

2.2.2 Treatment options

2.2.2.1 Observation

DAVFs with direct flow into the sinus without CVD have a very low risk of bleeding.[16,19,32,49,191,197] If the patient tolerates the symptoms, these lesions can be observed. Although Borden type I DAVFs have benign behavior, they carry a 2% potential for conversion into a lesion with CVD.[19] In reports by Satomi et al. and Cognard et al. CVD developed after incomplete occlusion of DAVF in all but three of the patients without treatment.[33,191] Therefore, close clinical follow-up and radiological evaluation in case of change in symptoms is needed.[19]

2.2.2.2 Selective disconnection of cortical venous drainage

Borden type II and III carry a rather high risk of hemorrhage necessitating treatment to prevent bleeding.[16,47,56] DAVFs that have already presented with hemorrhage, should be treated early due to their high risk of rebleeding.[19,51]

Understanding that DAVFs are venous-based rather than arterial-based lesions raised the thought of focusing treatment on the venous side of the fistula.[159] Selective disconnection, described by Collice et al. and further proposed by others, results in complete obliteration of Borden type III DAVFs and turns the Borden type II DAVFs into benign ones.[26,30,37,92,153] Thereafter, these lesions may be only observed. Due to risks related to interfering the venous outflow of DAVFs by completely occluding them, selective disconnection of the CVD microsurgically or endovascularly is recommended as the first-line treatment of

the Borden type II DAVFs, instead of aiming at complete obliteration of the fistula.[43,92,215]

2.2.2.3 Multimodality treatment

Combining different treatment modalities has proven to be the most efficient way to achieve symptom relief and complete occlusion of DAVFs especially in cases refractory to one therapeutic modality alo ne.[8,23,65,105,113,133,162,178,184,193]

Transarterial embolization with Onyx is the primary treatment method of many DAVFs. In Borden type III DAVFs also NBCA in lower concentrations is proved to be still safe and effective treatment option.[73,109] Transvenous coil embolization might be preferred in DAVFs with small feeders originating from the ICA or VA, and in many indirect cavernous sinus DAVFs. However, it carries the risk of venous infarction.

In Borden type I DAVFs with intolerable symptoms, radiosurgery by linear accelerator (Linac) or gamma-knife alone or as adjuvant therapy to embolization can be used.[31,113,196,230,231] In Borden type II and III DAVFs with significant risk of hemorrhage, radiosurgery is rarely an option because of the slowly occurring occlusion process. If complete occlusion of the fistula or at least obliteration of CVD by embolization is not achieved, microsurgical obliteration of the CVD or the entire fistula is required.[50,105,162,190,218]

3 Aims of the Study

1. To analyze the characteristics of intracranial dural arteriovenous fistulas and the results of their treatment.

2. To assess the long-term excess mortality in patients with intracranial dural arteriovenous fistulas and to evaluate factors affecting mortality.

3. To analyze the results of microneurosurgical management of intracranial dural arteriovenous fistulas, and describe the techniques and the role of microneurosurgery in the management of intracranial dural arteriovenous fistulas at different locations.

4 Materials and Methods

The study is based on the retrospective data of 283 patients with 293 intracranial DAVFs, admitted to two of the five Departments of Neurosurgery in Finland (Helsinki and Kuopio) (Table 4). The catchment area of these departments is approximately 2.5 million inhabitants.

4.1 Publication I: Clinical characteristics and long-term outcome

4.1.1 Patients

In publication I, we identified 251 patients with 261 intracranial true DAVFs (Borden type I-III[16] and Barrow type B-D fistulas[11]) from the 330 intracranial arteriovenous fistulas diagnosed at two of the five neurosurgical centers in Finland (population 5.3 million), Helsinki and Kuopio, between January 1944 and December 2006. The remaining 69 patients with Barrow type A high-flow carotid cavernous fistulas were excluded from this study. We identified a subgroup of 44 patients admitted to the Department of Neurosurgery in Helsinki University Hospital between 2001 and 2005 to determine the incidence of DAVFs.

4.1.2 Data collection

The patient files and radiological images were retrospectively reviewed. Clinical variables including age, sex, medical history, presenting symptoms, DAVF location and the Borden or Barrow classification were collected. In all cases the diagnosis of DAVF was confirmed by carotid angiography by direct needle puncture, or from 1989 onwards by digital subtraction angiography (DSA). Computerized tomography (CT) was performed since 1980 for patients with ruptured DAVFs. Preoperative magnetic resonance angiography (MRA) images were available in 23 patients. We collected the radiological data directly from the images obtained between 1988 and 2010 and from the chart description for patients treated before 1987. We compared radiological features with clinical features and results of treatment by different modalities and techniques according to DAVF location.

4.1.3 Follow-up

Follow-up data were retrospectively collected from the day of admission until death, last follow-up visit or December 31, 2010. In the early series, only clinical symptoms were fol-

Table 4. *Characteristics of the patients in publications I-III.*

Characteristic	Publication I	Publication II	Publication III
Time period	1944-2006	1944-2006	1980-2010
No. patients	251	227	116
No. DAVFs	261	234	118
Gender			
Women (%)	139 (55%)	137 (60%)	66 (56%)
Men (%)	112 (45%)	90 (40%)	50 (44%)
Age (yrs) : median (range)	55.6 (0-82)	56.2 (0-82)	56.8 (22-78)
Women	56.7 (0-82)	56.7 (0-82)	56.5 (22-78)
Men	51.6 (0-78)	54.5 (0-78)	58.6 (35-77)

lowed up and a follow-up angiography was performed only in a few cases with persisting symptoms. Since 1980's, follow-up angiography was performed in all treated patients before discharge. There was sufficient clinical data in 236/251 patients with 246 fistulas to evaluate the complete occlusion of the DAVF. Thirteen patients with traumatic middle meningeal artery lesions and two with conservatively treated other traumatic DAVFs were lost to follow-up. If patients with completely occluded DAVFs did not contact the departments after the discharge for recurred symptoms, they were considered to be cured in the analysis. Repeated angiography was performed only if recurrent symptoms occurred. Patients who received SRS were followed up with DSA or MRA or both annually up to at least three years. Outcomes were clinically graded at the first follow-up at three months and at the last follow-up. Glasgow Outcome Scale (GOS) score was used to measure outcome. Good outcomes were defined as normal life or moderate disabilities (GOS score 4-5). Fair outcomes were defined as severe disabilities, with dependence of the care of others (GOS score 3). Poor outcomes were defined as persistent vegetative state (GOS score 2) or death (GOS score 1).

4.1.4 Statistical analysis

Statistical analyses were performed using commercially available statistical software package (SPSS for Windows, version 17.0 2008; SPSS, Inc., Chicago, IL). Clinical characteristics were presented as percentages for categorical variables and as medians for continuous variables. The incidence rate was calculated cumulatively from 2001 to 2005 as the proportion of patients diagnosed with DAVF in the catchment area of the Department of Neurosurgery in Helsinki, Finland (range 1 720,068 to 1 760,743 between 2001 and 2005).

4.2 Publication II: Long-term excess mortality

4.2.1 Patients

In contrast to publication I, the 24 patients with traumatic cortical artery lesions were excluded from the study in publication II. The data collection was in concordance with publication I.

4.2.2 Data collection during follow-up

Patients were followed up from the time of admission to the Department of Neurosurgery until death or December 31, 2009. Vital status at the end of 2009 was obtained from the Population Register Center, which contains information on all Finnish residents. The dates and causes of death were provided by Statistics Finland. They also provided comparable data on the causes of death for the entire population of Finland during the study period. Death was considered DAVF-related if it was attributable to the DAVF or its treatment, or late sequelae of DAVF-associated morbidity, for example pneumonia in a bedridden patient.

4.2.3 Statistical analysis

The relative survival ratio (RSR) provided a measure of the excess mortality for patients diagnosed with DAVF, irrespective of whether this excess mortality was directly or indirectly attributable to the illness. The RSR was calculated by dividing the observed survival proportion by the expected survival proportion in a comparable reference population.[58] The expected survival was derived, using the Hakulinen method, from that of the compa-

rable general population of Finland matched with respect to age, gender, and calendar time based on data from Statistics Finland.[76,77] The 95% confidence intervals (CI) for annual RSR and cumulative relative survival estimates were calculated by assuming normal distribution. Student's t-test and Pearson's $\chi 2$ test were used for comparing patient and DAVF characteristics between groups. Statistical analysis was carried out using SPSS 17.0 software (SPSS, Inc., Chicago, IL).

4.3 Publication III: Microneurosurgical management of DAVFs

4.3.1 Patients

The data presented in publication III represents 116 consecutive patients with 118 DAVFs treated microsurgically in Helsinki and Kuopio neurosurgical units between 1980 and 2010.

4.3.2 Follow-up

Follow-up data were retrospectively collected from the day of admission until death, the last follow-up visit or December 31, 2012. The clinical status of the patients was followed up. Repeated angiographies (DSA or MRA) were performed only in cases of recurrent symptoms. In addition, the patients who received SRS were followed up with digital subtraction angiography (DSA) or/and magnetic resonance angiography (MRA) annually up to three years. The outcomes were assessed at the first follow-up at three months and at the last follow-up according to the Glasgow Outcome Scale (GOS) score. GOS scores of 4-5 were considered good outcomes, and GOS scores of 1-3 were considered poor outcomes.

4.3.3 Statistical analysis

Statistical analysis was performed using commercially available statistical software package (SPSS for Windows, version 19.0 2008; SPSS, Inc., Chicago, IL). The Pearson chi-square test was used. Clinical characteristics were presented as percentages for categorical variables and as medians for continuous variables.

5 Results

5.1 Incidence of dural arteriovenous fistulas

Until 1970s only very few DAVFs were diagnosed. The patients were admitted to the hospital due to severe exophthalmos or bruit. Majority (82%) of the admitted patients had transverse-sigmoid sinus, torcular or cavernous sinus DAVFs, typically causing these symptoms. The number of patients increased during the 1970's due to the increased number of trauma patients, and again in the 1990's after the introduction of DSA. Twenty-two of the 38 patients from the 1970's had traumatic cortical artery lesions seen in diagnostic angiographies performed due to severe head trauma, and in only 16 patients the angiography was performed due to symptoms caused by DAVF. In 1980, CT became the primary screening method for trauma patients, decreasing the number of DAVFs (Tables 5 and 6).

Between 2001 and 2005, 5-14 new DAVF patients per year were admitted to the Department of Neurosurgery in Helsinki. The calculated crude incidence of DAVFs in the catchment area (range 1 720,068 to 1 760,743 between 2001 and 2005) was 0.51 per 100,000 per year. We compared it with the incidence of brain AVMs in the same population and the same period of time.[122] The incidence of brain AVMs was 1.09 per 100,000 per year, which is comparable to their current estimated detection rate.[29] Thus DAVFs accounted for 32% of all intracranial AVMs in this defined population.

5.2 Clinical characteristics and outcome of DAVF patients (Publication I)

5.2.1 Patient characteristics

Of the 251 patients, 139 (55%) were women and 112 (45%) were men. The median age of the adults was 55 years (range 18-82 yrs). Multiple fistulas (range 2-4) were found in eight patients, four women and four men. Before the 1980's the majority (69%) of the patients were men.

Only in one fourth (25%) of the patients there was a clear potential etiological factor available. Trauma was the underlying cause in 51 (20%) patients in the whole series. Before the 1980's 71% of the DAVFs were traumatic in origin. Four DAVFs were diagnosed after sinus thrombosis, one with mastoiditis, four developed after surgery, and three were obviously congenital.

The patients with DAVF found in diagnostic angiographies in 1960's and 1970's had had severe head trauma and had been initially unconscious, thereafter most patients with

Table 5. *Detection rates of DAVFs between 1944 and 2006, excluding traumatic cortical artery lesions.*

TIme period	Admitted patients (n=227)
1944-1949	1
1950-1959	3
1960-1969	6
1970-1979	16
1980-1989	20
1990-1999	94
2000-2006	87

Table 6. *Characteristics and detection rates of DAVFs between 1944 and 2006.*

Characteristic	1944-1949	1950-1959	1960-1969	1970-1979	1980-1989	1990-1999	2000-2006
	n=1 (%)	n=3 (%)	n=7 (%)	n=38 (%)	n=20 (%)	n=94(%)	n=88 (%)
Gender							
Women	1 (100)	1 (33)	2 (29)	11 (29)	10 (50)	60 (64)	54 (61)
Men	0 (0)	2 (67)	5 (71)	27 (71)	10 (50)	34 (36)	34 (39)
Median age in yrs							
Women	38	56	52 (46-57)	47 (35-64)	65 (25-78)	57 (0-76)	58 (22-82)
Men		23 (17-29)	36 (25-51)	42 (4-69)	55 (32-70)	60 (2-78)	52 (0-72)
DAVF location							
Transv-sigm	0 (0)	1 (33)	4 (57)	12 (32)	15 (71)	73 (76)	61 (64)
Cavernous	1 (100)	2 (67)	1 (14)	1 (2.6)	1 (4.8)	10 (10)	11 (12)
Other	0 (0)	0 (0)	2 (29)	25 (66)	5 (23)	13 (14)	23 (24)
CVD present	0 (0)	0 (0)	2 (29)	25 (66)	6 (29)	24 (25)	31 (33)
Treatment							
Ligation		2 (67)	1 (29)	6 (16)	7 (33)	1 (1.0)	6 (6.3)
Craniotomy				1 (2.6)	6 (29)	10 (10)	33 (35)
Embolization						45 (47)	4 (4.2)
SRS							43 (45)
Other/combined				6 (16)	4 (19)	37 (39)	9 (9.5)
Conservative	1 (100)	1 (33)	5 (71)	25 (66)	4 (19)	3 (3.1)	
Total occlusion rate	0 (0)	0 (0)	1 (14)	1 (37)	13 (62)	59 (61)	7 (71)

traumatic DAVFs had had mild head trauma without unconsciousness.

5.2.2 DAVF characteristics

DAVFs

The most common location of the 261 DAVFs was transverse and sigmoid sinuses (61%), followed by cavernous sinus (10%) (Table 7). Left-sided predominance was seen in transverse and sigmoid sinus DAVFs, 103 (65%) on the left, 52 (33%) on the right and three (1.9%) bilateral or midline lesions.

Twenty-seven (3.8%) of the 261 DAVFs were traumatic cortical artery lesions, most commonly in the middle meningeal artery, seen in diagnostic angiographies of head trauma patients during 1960's and 1970's. On one patient DSA was performed after trauma due to heavy epistaxis. Four convexity DAVFs were found. All except two of the 24 trauma patients were men.

Classification

Cortical venous drainage (CVD) was present in 88 (34%) fistulas. Men had CVD significantly more often than women. It was present in 54 (46%) men and in 34 (24%) women. The CVD cases included 23 traumatic cortical artery lesions and 65 (28%) of the 234 other fistulas. Fifteen (5.7%) DAVFs included venous pouches. Women had more Borden type I DAVFs than men, whereas men had more type III lesions (Table 7).

Presentation

Pulsating bruit was the most common symptom in 65% of the patients, severe in most of them (Table 8). Of the patients having DAVFs without CVD, 83% presented with bruit, and only 23% of those with CVD. Other symptoms

Table 7. *Characteristics of 261 DAVFs*

Characteristic	Women n=143 (%)	Men n=118 (%)	All n=261 (%)
DAVF Location (n=261)			
Transverse and sigmoid sinus	101 (71)	57 (48)	158 (61)
Torcula	5 (3.5)	3 (2.5)	8 (3.1)
Cavernous sinus	17 (13)	8 (6.8)	27 (10)
Middle fossa	2 (1.4)	18 (15)	20 (7.7)
Convexity	4 (2.8)	13 (11)	17 (6.5)
Frontobasal	3 (2.1)	5 (4.2)	8 (3.1)
Tentorium	2 (1.4)	5 (4.2)	7 (2.7)
Superior sagittal sinus	1 (0.7)	5 (4.2)	6 (2.3)
Foramen magnum	2 (1.4)	3 (2.5)	5 (1.9)
Other	4 (2.8)	1 (0.8)	5 (1.9)
DAVF side (n=261)			
Left	48 (34)	63 (53)	138 (53)
Right	75 (52)	40 (34)	88 (34)
Midline or bilateral	20 (14)	15 (13)	35 (13)
Borden classification (n=234)			
I	87 (69)	52 (47)	139 (59)
II	14 (11)	9 (8.2)	23 (9.8)
III	16 (13)	46 (42)	62 (26)
not available	7 (5.5)	3 (2.7)	10 (4.3)
Barrow classification (n=27)			
B	4 (22)	5 (56)	9 (33)
C	3 (17)	1 (11)	4 (15)
D	11 (61)	1 (11)	12 (44)
not available		2 (22)	2 (7.4)
Hemorrhage from DAVF (n=261)			
Yes	11 (7.7)	23 (19)	34 (13)
No	132 (92)	95 (81)	227 (87)

Table 8. *Clinical symptoms of DAVF patients by Borden classification.*

	Type I n=139 (%)	Type II n=23 (%)	Type III n=62 (%)	Type n/a n=10 (%)	All n=224 (%)
Bruit					
mild	37 (27)	6 (26)	3 (4.8)	5 (50)	51 (23)
severe	89 (64)	9 (39)	1 (1.6)	1 (10)	100 /45)
Headache	36 (26)	7 (30)	20 (32)	4 (40)	67 (30)
Hemiparesis	1 (0.7)	2 (8.7)	14 (23)	1 (10)	18 (8.0)
Seizure	1 (0.7)	4 (17)	11 (18)	2 (20)	18 (8.0)
Mental deterioration	1 (0.7)	1 (4.3)	5 (8.1)		7 (3.1)
Hemorrhage	3 (2.2)	7 (30)	22 (35)	2 (20)	34 (15)
No symptoms	2 (1.4)				2 (0.9)

were headache 82 (33%), chemosis and exophtalmos 22 (8.8%), hemiparesis 20 (8.0%) and seizures 19 (7.6%).

In 34 (14%) patients, the DAVF presented initially with a hemorrhage (13 transverse and sigmoid sinus, 2 torcula, 4 middle fossa, 4

Table 9. *Total occlusion and complication rates of 261 DAVFs in 489 procedures by occlusive technique.*

Treatment	Total occlusion rate n (%)	Complication rate n (%)
No. DAVFs / procedures /patients	261	489
Ligation (n=18 / 35)	9 (50)	3 (9)
Craniotomy, resection (n=23 / 116)	20 (87)	24 (21)
Embolization (n=78 / 313)	40 (51)	16 (5)
SRS (n=4 / 17)	3 (75)	1 (6)
Combination / other op (n=90 / 8)	70 (78)	2 (25)
Conservative (n=48)	12 (25)	
Total	154 (59)	46 (9)

convexity, 5 SSS, 2 tentorium, 2 frontobasal, 1 foramen magnum, 1 other). Hemorrhagic presentation was more common in men than in women: 23/112 (21%) vs. 11/139 (7.9%). CVD or venous pouches were present in 29 (85%) of the 34 patients with hemorrhage, CVD in 21 (62%), venous pouch in two (5.9%), and both in six (18%). Seven of these 34 fistulas were Borden type III and 22 were type II. Also three Borden type I DAVFs presented with bleeding. Bleeding from DAVF did not lead to a deeply comatose state in any of the patients. The patients presented with headache and/or neurological deficits.

5.2.3 Long-term occlusion rates

Of the 261 DAVFs, 48 were observed and 213 received treatment. The conservatively treated group included 21 traumatic DAVFs. Observation instead of treatment was chosen because of mild symptoms in 45 patients, and 3 DAVFs occluded spontaneously before treatment.

Overall, 59% of the DAVFs that were admitted and 67% of those that received treatment since 1944 were successfully occluded (Table 9): 100% with craniotomy and glue injection into the affected sinus; 87% with embolization and craniotomy; 87% with craniotomy and resection of the fistula or cutting the feeding arteries; 75% with SRS; 60% with embolization and other operation (glue injection); 51% with embolization; 50% with embolization and SRS, and 50% with ligation of the feeding artery. Two of the six (33%) DAVFs embolized with Onyx® became completely occluded. The four partially occluded ones were very complex in which previous embolizations with PVA, NBCA and coils had failed.

Three of the 261 DAVFs have appeared to be incurable: one in the area of transverse and sigmoid sinuses, repeatedly developed new fistulous connections, and transformed from Borden type I to type II; another one in the area of transverse and sigmoid sinuses and torcula has remained open with CVD in spite of numerous NBCA, Onyx and coil embolizations (Figure 10); the third one with several fistulous connections in the sagittal, transverse and sigmoid sinuses has resisted any therapy (Figure 11).

Surgical treatment

Ligation of feeding arteries resulted most often in residual filling of the fistula. These DAVFs often developed numerous new fistulous connections, which were even more difficult to treat. Twenty of the 53 surgically treated DAVFs required repeated treatment. All of these patients underwent two procedures: 12 repeated craniotomies, five proximal ligations of feeding arteries, and three proximal ligations followed by a craniotomy, and to-

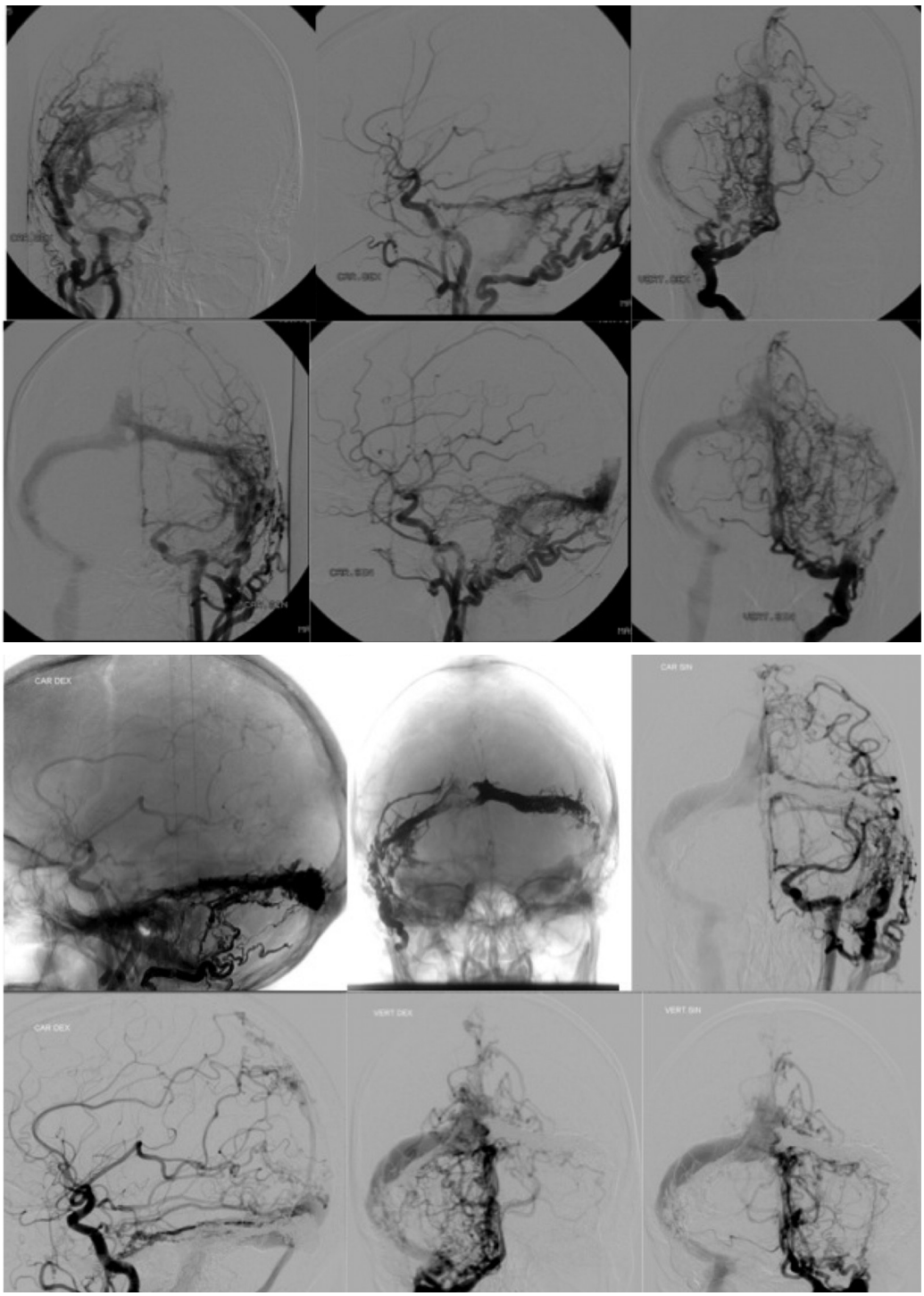

Figure 10. *DSA revealed a Borden type II DAVF in the area of both transverse-sigmoid sinuses and torcula with multiple feeders from both ICAs, ECAs and VAs in a 59-year-old woman presenting with headache and visual disturbance. Despite several embolizations with NBCA, Onyx and coils, this inoperable DAVF has remained open.*

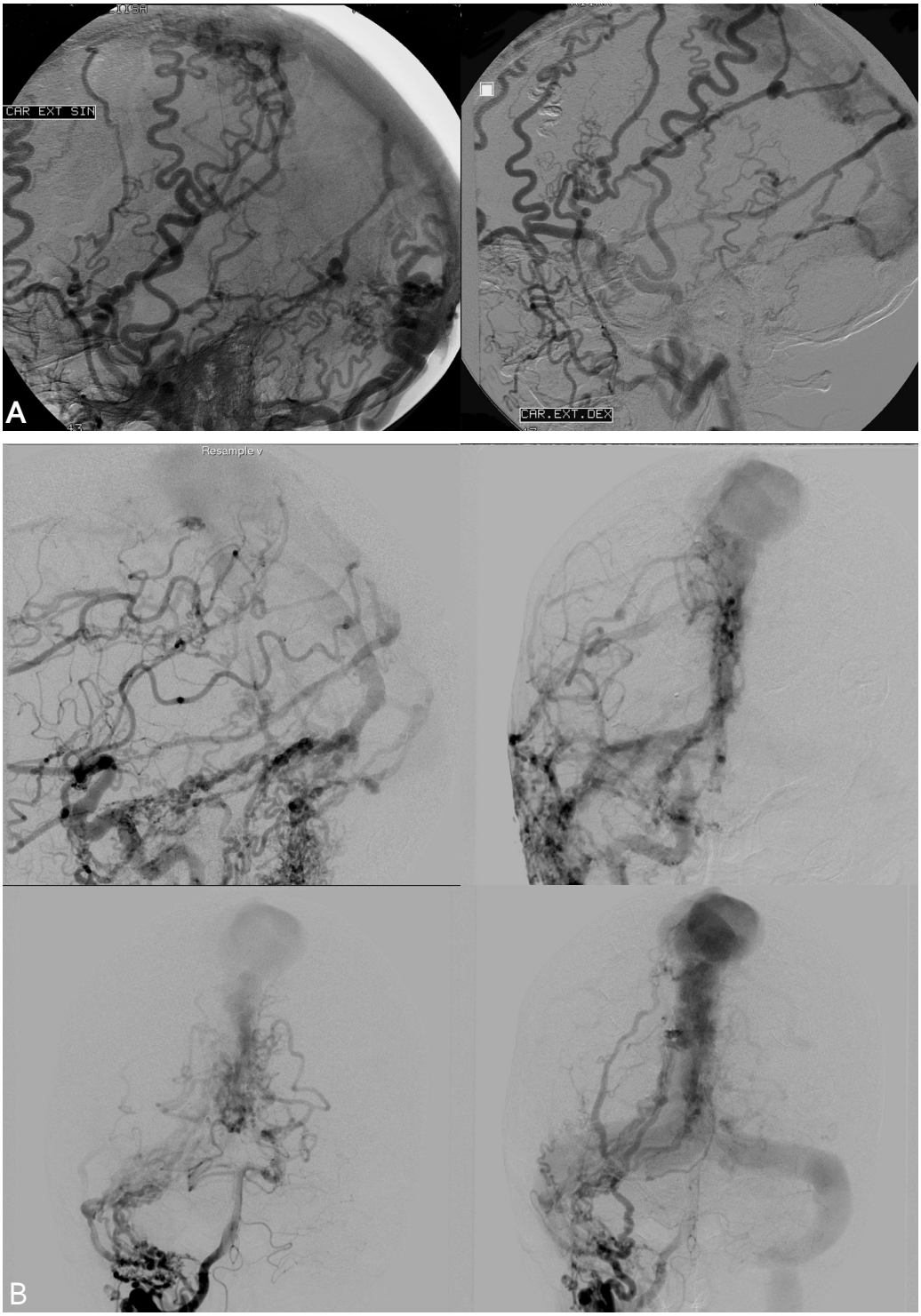

Figure 11. a, b *DSA showed several fistulous connections in superior sagittal, transverse and sigmoid sinuses in a 22-year-old woman with severe headache. After several embolizations, microsurgical occlusions and SRS even more fistulous connections have developed.*

tal occlusion was achieved in 10 (50%) cases (eight, one and one, respectively).

Endovascular treatment

Advances in endovascular techniques (particularly Onyx) and increasing experience improved the occlusion rates of endovascular and combined treatment improved from 47% and 74% in the 1990's to 58% and 81% between 2000 and 2006.

The average number of embolizations performed before total occlusion or proceeding with surgery or SRS was 1.96 (range 1-9). Forty-three (55.1%) of the 78 endovascularly treated fistulas required more than one embolization. In sixty-two DAVFs, only main feeders were embolized and patients underwent microsurgical resection of the fistula. Endovascular therapy failed in 16 cases, and it was followed by craniotomy and/or SRS.

Observation

Of the 48 fistulas that were only observed, 12 (25%) occluded spontaneously. Eight of them were located in the convexity and traumatic in origin, three in the area of transverse and sigmoid sinuses, and one in the cavernous sinus. The median interval between the initial diagnosis and angiography showing occlusion was 5.1 weeks (range 0.7-73 weeks).

5.2.4 Complications of treatment

Overall, there were complications in 46 (18%) procedures (Table 9). There were 21 (8.4%) severe complications (large infarction, ICH, EDH, SDH, brain swelling), of which ten occurred after craniotomy, 10 after embolization and one after SRS. Other complications were postoperative meningitis despite prophylactic antibiotics, deep venous thrombosis, pneumonia, wound infection, severe sepsis, and pulmonary embolism.

Severe bleeding (>1000 ml) occurred in 16 of the 116 (14%) craniotomies performed on 93 patients (17%). There were complications in 24 of the 116 (21%) surgical procedures, of which 9 (7.6%) were severe. The most complications were seen after microsurgical occlusion of the transverse and sigmoid sinus DAVFs, 24% in overall (9.3% severe), and after craniotomy and glue injection into the cavernous sinus (29%).

In 313 endovascular procedures performed in the treatment of 156 DAVFs, altogether 16 (5.1%) complications, of which 10 (3.2%) severe, were seen. The complications were hemorrhagic or ischemic in 11 (7.1%) patients and in 13 (4.2%) procedures. All except two patients developed symptoms immediately after the procedure. Two fistulas bled 16 days after the embolization.

The only complication related to SRS was an ICH due to puncture of a stereotactic frame pin through a burr hole from a previous craniotomy and necessitated evacuation.

Treatment mortality

Ten patients died within 30 days after a procedure, but only five (2.0%) were related to the procedure itself. Three deaths occurred after embolization (SAH, infarction, sinus thrombosis) and two patients had sudden severe edema during the operation ultimately leading to death (one after microsurgical occlusion and another after embolization followed by microsurgical occlusion of the DAVF). Other causes of death were pulmonary embolism, cardiac infarction and purulent meningitis.

5.2.5 Neurological long-term outcome

The median clinical follow-up time was 1.1 years (mean 3.1 yrs, up to 40.2yrs). Follow-up data at three months was available in 157 patients. At three months, 141 (56%) patients

Table 10. *Long-term outcome of 251 DAVF patients (patients with good recovery: GOS 4-5).*

Location	No. patients n (%)
Transverse-sigmoid sinus	141 (92)
Confluence sinuum	6 (75)
Cavernous sinus	20 (87)
Middle fossa	11 (65)
Convexity	12 (71)
Frontobasal	3 (75)
Tentorium	5 (83)
Superior sagittal sinus	5 (83)
Foramen magnum	4 (100)
Other	11 (85)
All	218 (87)

had a good outcome (GOS 4-5), 6 (2.4%) had a fair outcome, and 10 (4.0%) had died. At the end of the follow-up period, 218 (87%) had a good outcome and 12 (4.8%) a fair outcome (Table 10). The patients with transverse-sigmoid sinus and cavernous sinus DAVFs had the best outcome, good recovery (GOS 4-5) in 92% and 87%, respectively.

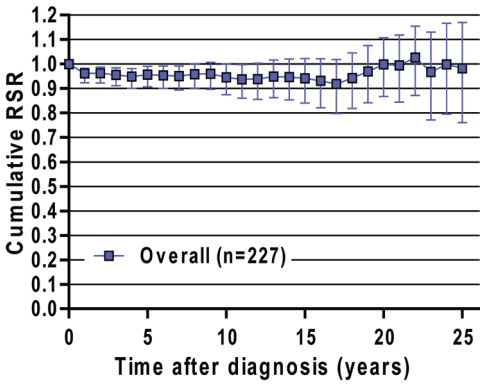

Figure 12. *Cumulative relative survival ratios (RSR) with 95% confidence intervals (CI) of 227 patients with dural arteriovenous fistulas (DAVF) as a function of follow-up period in years.*

5.3 Long-term mortality and excess mortality (Publication II)

5.3.1 Long-term mortality

Of the 227 patients, 61 (27%) had died by the end of the follow-up period. Within the first 12 months, the overall mortality was 4.8%. Annual RSR was lowest (0.95, 95% CI 0.92-0.98) during the first year after admission. After the first 12 months, cumulative RSR declined only slightly showing no significant excess mortality among all DAVF patients (Figure 12).

Altogether 50 (23%) of the 216 one-year survivors died later during the follow-up. Cancer (10/50, 20%), cardiovascular disease (9/50, 18%) and cerebrovascular disease (6/50, 12%) were the most frequent causes of death (Table 11). Only two patients died due to DAVF-related causes: one that was treated three years after initial admission died due to surgical complications, another had a bleeding from the partially occluded DAVF leading to death nine years after admission. Both of these DAVFs presented with CVD. Another two patients with partially occluded transverse-sigmoid sinus and cavernous sinus DAVFs were diagnosed with SAH by lumbar puncture 24 and 37 years after admission. Eventually, both of them died but autopsies were not performed. Other causes of death were pulmonary embolism, pneumonia, trauma, unrelated suicide and status epilepticus. In six patients the causes of death were unknown.

5.3.2 Short-term excess mortality

During the first 12 months, excess mortality was observed and it was mainly due to treatment complications (45% of the 11 deaths). Two (18%) of the deaths were cerebrovascular (massive sinus thrombosis and ICH not

Table 11. *Causes of death of the 61 patients who died by the end of the follow-up period.*

Cause of death	Age (yr) at death (mean ± SD)	Time from admission to death, years [n(%)]					
		0-1	1-5	5-10	10-20	> 20	Total
DAVF related	64.5 ± 17.8	5 (45)	1 (9)	1 (8)	0	0	7 (11)
Cardiovascular	70.0 ± 15.9	1 (9)	2 (18)	3 (23)	3 (21)	1 (8)	10 (16)
Cerebrovascular	69.1 ± 7.6	2 (18)	1 (9)	2 (15)	1 (7)	2 (17)	8 (13)
Cancer	74.6 ± 8.4	0	3 (27)	3 (23)	3 (21)	1 (8)	10 (16)
Other disease	75.1 ± 13.2	1 (9)	2 (18)	3 (23)	4 (29)	2 (17)	12 (20)
Trauma	62.6 ± 12.8	2 (18)	2 (18)	1 (8)	3 (21)	0	8 (13)
Not known	74.7 ± 16.3	0	0	0	0	6 (50)	6 (10)
All	70.5 ± 13.5	11	11	13	14	12	61

related to DAVF), one (9%) cardiovascular death, and another one (9%) due to pulmonary embolism. Two (18%) of the patients had had severe head trauma and DAVF was an incidental finding in diagnostic angiography performed. Eventually, the head trauma resulted in death. CVD was present in only one of the patients that died early due to treatment complication.

5.3.3 Long-term excess mortality among one-year survivors

Effect of CVD on survival

Of the 216 one-year survivors, 60 (28%) presented with CVD; 15 (30%) of those died later during the follow-up period and 45 (27%) were alive at the end of the follow-up period. The presence of CVD was unknown in 13 patients (including two cavernous sinus fistulas) because the images were lacking and the radiology reports did not contain enough data for definite conclusions. The majority (58%) of the DAVFs with CVD were Borden type III.

DAVF patients with CVD had continuous excess mortality during the follow-up time (Figure 13). The cause of death was DAVF-related in two (13%) of the 15 patients having DAVF with CVD, and in none of the 27 patients without CVD, cardiovascular disease in 4/15 (27%) and 4/27 (15%), cerebrovascular disease in 2/15 (13%) and 4/27 (15%), respectively. The patients presenting with hemorrhage had a tendency to have excess mortality only until seven years after admission. Thereafter, there was only one death. The causes of death after hemorrhage were cancer (2/6, 33%), cardiovascular (1/6, 17%), trauma (1/6, 17%), suicide (1/6, 17%) and unknown (1/6, 17%).

Effect of DAVF location on survival

The majority (71%) of the DAVFs in one-year survivors were located in the region of the transverse and sigmoid sinuses. DAVFs in the region of transverse and sigmoid sinuses were more common in women (78%) than in men (62%). CVD was present more often in DAVFs in other locations than transverse and sigmoid (42% vs. 18%) and they were more prone to bleed (27% vs. 8%). The survival rates of the patients with transverse-sigmoid sinus DAVFs were similar to those of a matched general population. However, excess mortality was observed in patients with DAVFs in other locations (Figure 13).

Although the proportion of men with DAVFs in other locations than transverse and sigmoid sinuses and presenting with CVD and hemorrhage was higher, their survival rates were similar to those of women.

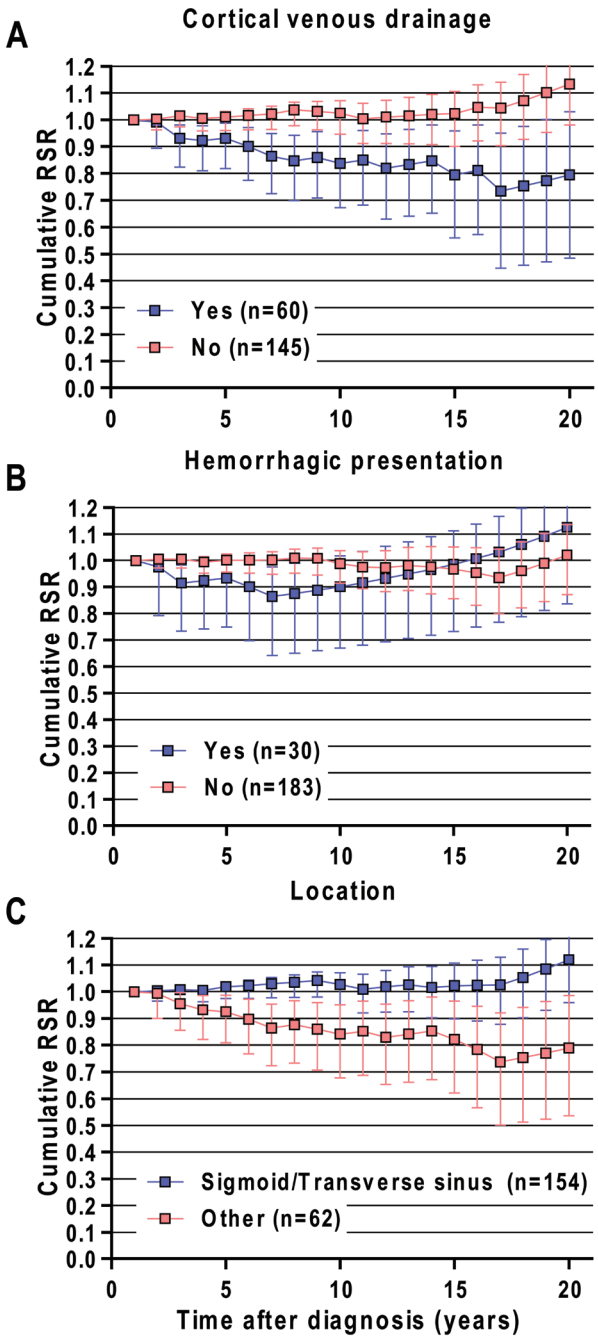

Figure 13. *Cumulative relative survival ratios (RSR) of the 216 patients with dural arteriovenous fistulas (DAVF) who survived the first year after admission; 60 patients presenting with cortical venous drainage (CVD) and 145 without (A), 30 patients with ruptured and 183 patients with unruptured DAVFs (B), 154 patients with DAVFs in the area of transverse-sigmoid sinuses and 62 patients with DAVFs in other locations, as a function of follow-up period in years with 95% confidence intervals (CI).*

5.4 Microneurosurgery of DAVFs (Publication III)

Of the 116 microsurgically treated patients, 57% were women and 43% were men (Table 12). Transverse and sigmoid sinuses were the most common location of DAVFs. Altogether 25 (21%) patients presented with hemorrhage, 15 (29%) men and 10 (15%) women.

Of the 118 DAVFs, 83 (70%) received multimodality treatment or required more than one surgical procedure. Preoperative embolization was performed in 48 DAVFs . Complete occlusion of the DAVF was achieved in 89% of the cases: 87% in transverse-sigmoid sinus; 100% in cavernous sinus, torcula, anterior fossa, foramen magnum and superior sagittal sinuses; 91% in tentorium; 86% in convexity; and 71% in other locations (Table 13).

Major hemorrhagic or ischemic complications were seen in 14 (12%) patients. Two deaths were due to severe brain swelling during surgery. Major bleeding (>1000ml) occurred in 7.8% of the procedures. Of the 116 patients, 110 (95%) had good outcome (GOS 4-5).

Table 12. *Characteristics of 116 microneurosurgically treated patients with 118 DAVFs.*

	Women	Men	All
No. patients	67	51	118
Location	n (%)	n (%)	n (%)
Transverse-sigmoid sinus	46 (69)	21 (41)	67 (56.8)
Cavernous sinus	7 (10)	6 (12)	13 (11.0)
Tentorium	2 (3.0)	9 (18)	11 (9.3)
Torcula	5 (7.5)	2 (3.9)	7 (5.9)
Convexity	2 (3.0)	5 (9.8)	7 (5.9)
Foramen magnum	1 (1.5)	2 (3.9)	3 (2.5)
Anterior fossa		2 (3.9)	2 (1.7)
Superior sagittal sinus		1 (2.0)	1 (0.8)
Other	4 (6.0)	3 (5.9)	7 (5.9)
Side			
Left	32 (48)	24 (47)	56 (47)
Right	24 (36)	20 (39)	44 (37)
Midline	11 (16)	7 (14)	18 (15)
Borden classification (n=105)			
I	37 (62)	16 (36)	53 (50)
II	9 (15)	4 (8.9)	13 (12)
III	12 (20)	24 (53)	36 (34)
not known	2 (3.3)	1 (2.2)	3 (2.9)
Hemorrhage from DAVF			
Yes	10 (15)	15 (29)	25 (21)
No	57 (85)	36 (71)	93 (79)
Symptoms			
Bruit	46 (73)	20 (41)	66 (57)
Headache	25 (38)	15 (30)	40 (34)
Seizure	4 (6)	6 (12)	10 (8.6)
Chemosis	3 (4.5)	4 (8.0)	7 (6.0)
Hemiparesis	1 (1.5)	6 (12)	7 (6.0)
Mental deterioration	1 (1.5)	2 (4.0)	3 (2.8)

Table 13. *Total occlusion rates of 118 microsurgically treated DAVFs by their location and combination of treatment modalities.*

	Operation	Embolization +operation	Operation +SRS	Embolization +operation +SRS	All n (%)
No. cases	40	72	3	3	118
Transverse-sigmoid sinus (n=67)	10	47	1		58 (87)
Cavernous sinus (n=13)	6	5	2		13 (100)
Tentorium (n=11)	9	1			10 (91)
Torcula (n=7)	2	5			7 (100)
Convexity (n=7)	2	4			6 (86)
Foramen magnum (n=3)	1	2			3 (100)
Anterior fossa (n=2)	2				2 (100)
Superior sagittal sinus (n=1)		1			1 (100)
Other (n=7)	4	1			5 (71)
All n (%)	36 (90)	66 (92)	3 (100)	0	105 (89)

5.4.1 Special considerations in the microneurosurgery of DAVFs

Careful analysis of the angiographic images and angioarchitecture of DAVF when planning the surgery is crucial for achieving complete eradication of the fistula, preserving normal vasculature and avoiding the pitfalls of the surgery. In MRA and CTA the gross anatomy of DAVFs can be studied, but the precise flow dynamics in the fistula and in the normal brain circulation can only be seen in DSA. Preoperative embolization of the DAVF can reduce the bleeding during operation.

Bleeding can also be reduced by sustaining moderate hypotension (systolic blood pressure around 100 mmHg) during the operation. The patient is placed in supine, semi-sitting or park bench position, and always head about 20cm above the heart level. Neuroanesthesiological principles are followed to gain extra room intracranially,[131,183] and in the park bench position, lumbar drainage is placed.

Heavy arterial bleeding from the enlarged extracranial feeding arteries with high flow through the bone into the fistula can make the microsurgery a great challenge already from the skin incision. The vessels are coagulated with heavy bipolar coagulation. Bleeding from the bone is treated by monopolar coagulation, fibrine glue or bone wax. To achieve a good control of all the fistulous connections, large craniotomies with 3 to 4 burr holes are used to expose the lesion. The bone flap is quickly elevated and a wet cloth is placed over the often highly vascularized dura. The bleeding from the bone margins is managed by using the heat produced by drilling the bone with a large diamond drill without irrigation ("hot drilling").

The operating microscope is used when inspecting the dura. Bleedings are treated by bipolar coagulation and several tacking sutures are placed to prevent bleeding under the bone margin. In case of heavy bleeding from the affected sinus, Surgicel™, fibrin glue and muscle are packed over the sinus.

5.4.2 Transverse and sigmoid sinus DAVFs

5.4.2.1 Approach and positioning

Lateral suboccipital approach described by Hugosson and Sundt is used in the treatment

Figure 14. *Park bench position.*

of transverse-sigmoid sinus DAVFs.[22,83,87,96,203] The patient is positioned in a park bench position head elevated above the heart level and a lumbar drainage is applied (Figure 14). The head is tilted laterally to the opposite side, and shoulder is retracted caudally with tape to achieve a correct trajectory to the approach. To prevent compression of jugular veins, too heavy lateral tilt of the head should be avoided.

5.4.2.2 Craniotomy and dural opening

A question mark or slightly curved incision is placed about one inch behind the mastoid process (Figure 15). Enlarged occipital and posterior auricular arteries are coagulated with heavy bipolar coagulation to prevent excessive bleeding. Several (3-4) burr holes are placed and a large lateral suboccipital bone flap is removed by cutting the medial part with craniotome, and the lateral margin by drilling and cracking the bone. The lateral margin of the opening is further drilled as far laterally as possible to achieve a good visibility and control around the sigmoid sinus. If mastoid air cells are opened, they are meticulously sealed

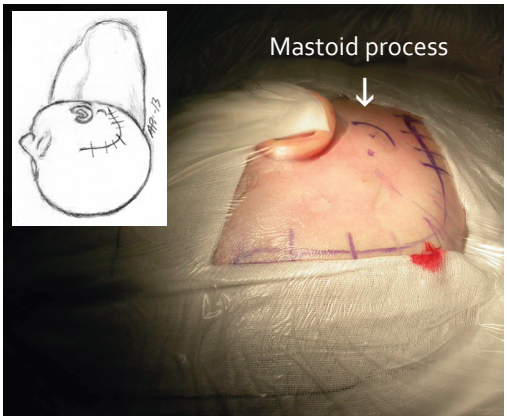

Figure 15. *Lateral suboccipital approach*

with bone wax, fat or muscle graft and fibrin glue to prevent CSF leak.

5.4.2.3 Occlusion of the fistula

The surgical strategy after the removal of the bone flap depends on the angioarchitecture of the lesion. If the sinus is open and serves as a major route for venous drainage, the feeding arteries are coagulated and cut. In case the sinus is occluded or non-functional, or there is a retrograde flow into the cortical veins, it is removed.[37,83] The medial part of the sinus is ligated first. Then the lateral part of the sinus is resected, and the remaining part of the proximal sinus is packed with oxidized cellulose (Surgicel™, Ethicon Inc., Somerville, NJ) and/or muscle and ligated. The vein of Labbé should be preserved to prevent venous infarctions.

5.4.3 Cavernous sinus DAVFs

5.4.3.1 Approach and positioning

Lateral supraorbital (LSO) approach from the side of the lesion is used for operating on cavernous sinus fistulas.[86,131] The patient is in a supine position. The head is elevated above the heart level, rotated 30 degrees to the contralateral side and tilted slightly.

5.4.3.2 Craniotomy

After minimal shaving of the hairline, a frontotemporal incision extending about an inch above the zygomatic arch is performed (Figure 16). Only superior and anterior part of the temporal muscle is split to prevent late atrophy, and the musculocutaneous flap is elevated anteriorly to expose the margin of the orbital rim and anterior zygomatic arch. A single burr hole is placed in the superior insertion of the temporal muscle and a small bone flap (3x5 cm) is elevated. Dura along the sphenoid ridge and the anterior clinoid process is separated from the bone, and the lateral part of the sphenoid ridge is drilled with a diamond drill. Medial part of the sphenoid ridge, roof of the optic canal and the anterior clinoid process are further removed by Sonopet™ ultrasonic aspirator.[187] Thereafter, dura over the temporal lobe is separated from the outer cavernous membrane.

5.4.3.3 Occlusion of the fistula

After exposing the wall of the cavernous sinus, it is opened with a very small incision. From this opening, fibrin glue is injected with a blunt needle,[119] and a pack of Surgicel™ is applied on top of it. This procedure is repeated in different points of the cavernous sinus wall until the fistula is completely occluded. During injections, extreme attention is paid to preserve flow in the carotid artery. To verify the occlusion of the fistula and the patency of the carotid artery, intraoperative Indocyanine Green Video Angiography (ICG-VA) or conventional angiography is performed.

5.4.4 Tentorial DAVFs

5.4.4.1 Approach and positioning

Subtemporal or suboccipital (supracerebellar-infratentorial) approaches are typically used to operate on the tentorial DAVFs (Figure 17). For reaching the lesions in the area of tentorial incisura, we prefer subtemporal approach rather than orbitozygomatic, pterional, or extensive skullbase approaches presented in the literature.[51,85,105-107,128,131,134] Presigmoid approach might be preferred in the DAVFs at the petrous apex (Figure 18). DAVFs in the posterior aspect of tentorium are operated on by suboccipital approach in park bench or prone position.

5.4.4.2 Craniotomy

In subtemporal approach, a small horseshoe-like incision from above the zygomatic arch curving posteriorly just above the earlobe is placed (Figure 17). Two burr holes are placed, one close to the origin of zygomatic

arch where the dura is often tightly attached to the bone, and another at the cranial border, to elevate a small bone flap. The temporobasal bone is drilled until the origin of the floor of the middle fossa to widen the craniotomy.[85,131]

5.4.4.3 Dural opening and occlusion of the fistula

The dura is opened its base caudally to expose the subtemporal space. The tentorial edge is then quickly reached and cisterns opened to relax the brain with minimal retraction of the temporal lobe. The temporal lobe is elevated gradually starting anteriorly from the temporal pole, and moving posteriorly. The retraction should be increased gradually. Finally, a rather wide retractor is placed to retain space. To get a better visualization to the fistulous site, the tentorial edge is divided posterior to the insertion of the IV nerve and lifted upwards with a small Aesculap® clip.[84,85,131] The feeding arteries along the dura are coagulated and cut. The occlusion of the fistula can be verified by using intraoperative ICG-VA or DSA (Figure 19a and 19b).

5.4.5 Frontobasal DAVFs

5.4.5.1 Approach and positioning

Superior sagittal sinus (SSS) and frontobasal DAVFs are treated through the midline approach in a semi-sitting or supine position.

5.4.5.2 Craniotomy

A curved skin incision is placed behind the hairline, crossing the midline. Two burr holes are placed in the midline over SSS. The bone flap is cut with a craniotome extending to both sides of the sinus. If the frontal sinus opens during the approach for frontobasal DAVFs, the endonasal mucosa is stripped of and the sinus is packed with fat and covered with pericranium and fibrin glue.

Figure 16. *Lateral supraorbital approach*

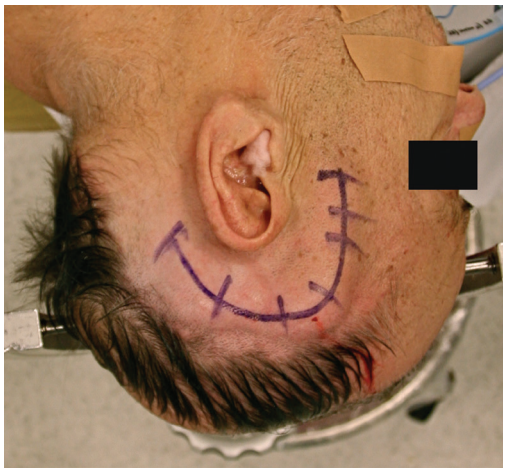

Figure 17. *Subtemporal approach*

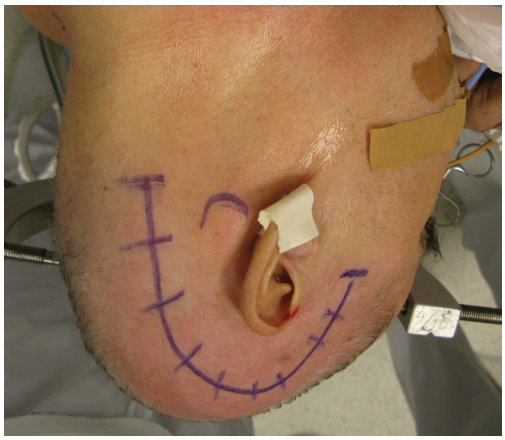

Figure 18. *Presigmoid approach*

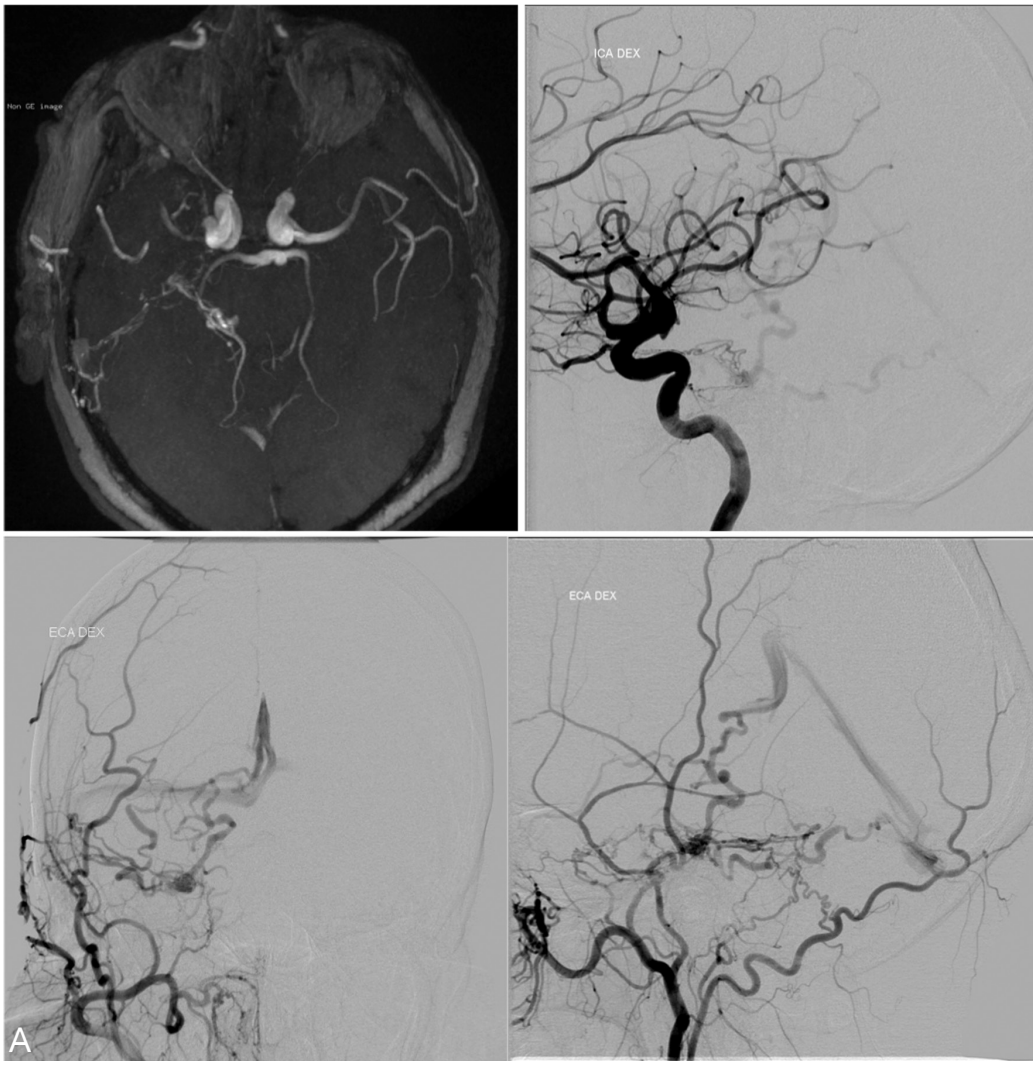

Figure 19. a *Right tentorial incisura DAVF was suspected in TOF MRA in a 62-year-old man suffering from headache after head trauma. DSA revealed a Borden type III DAVF that was fed from right ICA and branches of middle meningeal, occipital and posterior auricular arteries, and drained through cortical veins into vein of Galen and straight sinus, and into torcula.*

5.4.5.3 Occlusion of the fistula

Frontobasal and superior sagittal sinus DAVFs often have feeding arteries from both sides. In frontobasal DAVFs, the falx is coagulated and divided close to crista galli to reach the feeders from the opposite side. In superior sagittal sinus DAVFs, the feeding arteries within the dura and draining cortical veins are coagulated and cut from both sides of the SSS and falx. Tack-up sutures are used to lift the dura and prevent excessive bleeding and formation of epidural hematoma. Preserving the SSS is extremely important in the lesions of

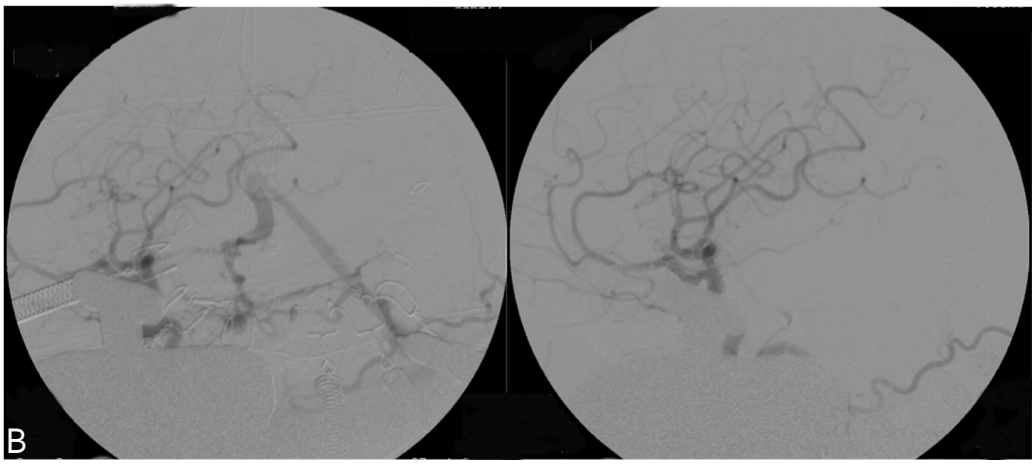

Figure 19. b *The DAVF was operated on through a subtemporal approach. Intraoperative DSA was performed in the beginning of the procedure to visualize the exact location of the fistula, and at the end of the procedure to verify the complete obliteration*

the posterior part of the SSS because it serves as the major route for venous outflow of the cerebral hemispheres. If the DAVF is located in the anterior third of the SSS, the sinus can be resected. The dura is left open to prevent recurrence of the fistulous connections.

5.4.6 Pitfalls of microneurosurgery

The most dangerous complications of DAVF treatment, whether it was microsurgical or endovascular, are severe brain swelling and hemorrhagic infarction due to sudden momentaneous occlusion of the DAVF (Figure 20). The best way to avoid these complications is to carefully study the angioarchitecture and flow dynamics of the DAVF before treatment. Identification and preservation of the vein of Labbé during the microsurgery of the transverse and sigmoid sinus DAVFs is crucial. Overall, the main goals in treatment are preserving normal functional vasculature, venous structures in particular, and identifying pathologic structures. To prevent the highly vascularized DAVFs from bleeding extensively, hemostasis should be done carefully in every phase of the surgery. Using operative microscope from the early stages of surgery is crucial to visualize and control the bleeding. A slight hypotension (systolic pressure 100 mmHg) is recommended during the surgery and 1-2 days after it to prevent postoperative hematomas, and a postoperative CT scan within a couple of hours after microsurgery is also recommended to exclude the hematomas.

Surgical approaches to the anterior part of the tentorial incisura have potential risks, including injuries to the facial, acoustic and trochlear nerves. Other potential complications include iatrogenic cerebellar or vascular damage, infections and CSF fistula. In the subtemporal and lateral occipital approach the air cells of the temporal bone often open. They must be sealed carefully using fat, bone wax and fibrin glue, or a part of the temporal muscle turned over the bone and sutured to dura to prevent CSF leak.[131]

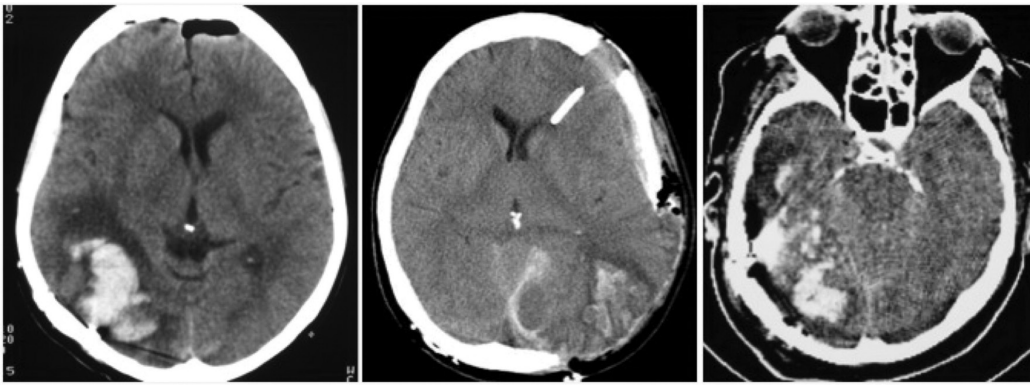

Figure 20. *Large postoperative hemorrhagic infarctions (left and right) and severe brain swelling during the microsurgical occlusion of transverse-sigmoid sinus DAVFs.*

5.4.7 Verification of complete occlusion

5.4.7.1 Intraoperative imaging

Indocyanine Green Video Angiography (ICG-VA) is a helpful tool for intraoperative imaging in cerebrovascular microsurgery, also in deep-seated DAVFs.[46,45,80,182] The fistulous site can be detected during the opening, and the occlusion of the fistula can be verified intraoperatively. This can reduce the time needed for surgery and the need of reoperation due to residual filling of the fistula, particularly in complex or deep-seated lesions. It is non-invasive, fast, easy to use, safe, reliable and repeatable. Alternatively, DSA can be used,[89] if ICG-VA does not reliably show the occlusion of the fistula.

5.4.7.2 Postoperative imaging

The primary method for verification of DAVF occlusion postoperatively is DSA, because all the small feeding arteries may not show in the ICG-VA or CTA. In this series it was carried out in 106 patients. In eight DAVFs with simple fistulous connection and intraoperative verification of occlusion only CTA was performed postoperatively, and four were not verified postoperatively at all. Later during follow-up, MRA and/or TRICKS were used to verify the occlusion of the fistula.

6 Discussion

This is the first consecutive large population-based series to report the evolution of the treatment of DAVFs, from the ligation of feeding arteries in 1940's to the present Onyx® era. Microsurgery was the treatment of choice in the early series, but nowadays it is seldom used, and only in selected cases, due to relatively high morbidity and mortality. Endovascular therapy and radiosurgery (SRS) have become more widely used, being effective and safe.[169,170,196] Onyx® embolization with adjuvant radiosurgery, or microsurgery if necessary, is the first-line treatment of DAVFs.[31,35,65,113,136,142,162]

Incidence of DAVFs

The Department of Neurosurgery in Helsinki serves a population of nearly 1.8 million in Southern Finland and receives all the patients with vascular pathologies from the whole catchment area. In this population, the incidence of DAVFs was 0.51 per 100,000 per year between 2001 and 2005. During the same period of time, the incidence of brain AVMs was 1.09. Thus DAVFs represented 32% of all detected intracranial AVMs. These numbers are twice or three times higher than in the previous few epidemiological studies of DAVFs. In the study by Newton et al, commonly referred to when discussing the frequency of DAVFs, they represented 10-15% of all brain AVMs.[163] Al-Shahi et al reported the detection rate of 0.16 per 100,000 per year in their population-based study.[2] The detection rate of 0.15 per 100,000 per year was reported by Brown et al.20 In Japan, detection rate was higher, 0.29 per 100,000 per year.[192] This is interesting because also the incidence of SAH is higher in Finland and Japan in comparison with other European and American populations, although the prevalence of intracranial aneurysms is similar to that of other countries.[222,225]

Microsurgical management of DAVFs

The treatment of DAVFs is primarily aimed at preventing the aggressive lesions from bleeding and reducing intolerable symptoms caused by all types of DAVFs. The first-line treatment methods are endovascular occlusion combined with radiosurgery if needed,[21,25,48,79,95,99,114] or disconnection of the CVD by microsurgical or endovascular means.[36,50,190,215] In selected cases, microsurgical occlusion of the fistula is still an applicable treatment option.[162]

Prevention of bleeding

DAVFs with CVD carry rather high a risk of hemorrhagic presentation, especially if associated with tentorial and ethmoidal location.[5,32,79,99,127,128] Therefore they require prompt occlusion to prevent bleeding.[1,50,190,218] Radiosurgery is rarely the first-line option in their treatment.[31,169,193,196,209] Particularly Borden type II and III DAVFs presenting with hemorrhage should be treated early due to their high risk of rebleeding.[56,197]

Selective surgical disconnection of CVD as the treatment for DAVFs with cortical venous reflux to prevent aggressive course has been described.[36,43,50,207] In the report of The Toronto Brain Vascular Malformation Study Group, surgical disconnection of the CVD was the definitive treatment for all 23 patients, and there were no hemorrhages or worsening of neurological deficits during a 4.9-year follow-up.[43] Similar results were achieved by Liu et al. in 23 patients treated by selective disconnection of CVD with no recurrences or further clinical events (new hemorrhages or NHNDs) during a 3.8-year follow-up.[139] Disruption of CVD can also be performed by endovascular means.[156] It is practical especially in DAVFs with only a single cortical venous outflow. In case complete obliteration of CVD is not achieved by

endovascular means, the remaining connections should be microsurgically occluded.

Relief of intolerable symptoms

Overall, Borden type I DAVFs are objects for conservative management due to their benign clinical course. However, 81% of the patients with Borden type I DAVFs present with bruit, and it is disturbing for majority of them. In some of the cases the very bothersome noise has led to despair and even attempts of suicide. If the patient simply does not tolerate the symptom, occlusion of the DAVF is justified primarily by endovascular means and/or radiosurgery. In absence of CVD, particulate transarterial embolization with or without radiosurgery is a very safe and effective treatment for Borden type I DAVFs of the transverse and sigmoid sinus.[136] Another group of patients that may be considered for treatment are those with cavernous sinus DAVFs with severe exophtalmos and chemosis leading to blindness. These DAVFs require prompt endovascular or microsurgical occlusion.

Treatment strategy

Potential risk of intracranial hemorrhage, severity of the symptoms and anatomical features of the DAVF, as well as risks related to different treatment options should be considered while planning the treatment strategy of the DAVF. The risks and benefits should be outweighed individually. If the DAVF requires treatment, the first-line method in most cases is endovascular occlusion. Most DAVFs can be at least partially treated by endovascular techniques. If successful occlusion is not achieved, the patient can receive adjuvant radiosurgery. The results of Onyx® embolization seem promising, but long-term patency of the embolization is yet to be seen, as in patients treated with PVA and NBCA embolization recurrences after several years have been detected. Radiosurgery is indicated in benign (Borden type I) fistulas with moderate symptoms and seldom in high-risk fistulas (Borden type II-III) refractory to endovascular treatment and microsurgery. The occlusion of the fistula occurs slowly, and for that reason, it cannot be recommended as the first-line treatment in DAVFs with a high risk of hemorrhage. Disconnection of CVD should be performed first. Microsurgical treatment of DAVFs has a relative high morbidity and mortality, and therefore it should be used in only carefully selected patients resistant to other treatment modalities.

Based on our and other series the treatment of benign (Borden type I) DAVFs is indicated if the patient suffers from intolerable symptoms (bruit, exophtalmos) and the goal is complete occlusion. In our experience incomplete obliteration of the DAVF may result in redirection of the flow via new fistulous connections and even more complex anatomy, and thereby induce the risk of further treatments. It may also lead to development of CVD and risk of hemorrhage. Cortical venous drainage in Borden type II and III DAVFs causing a high risk of hemorrhage is a strong indication for treatment. Simple disconnection of CVD has been recommended as the treatment of choice in Borden type III DAVFs but also type II DAVFs.[43,50,139,175]

Long-term excess mortality caused by DAVFs

In the series of 20 untreated or partially treated DAVFs with persistent CVD (mean follow-up time 4.3 yrs) by van Dijk et al., the hemorrhage or non-hemorrhagic neurological deficits (NHND) were the main causes of mortality. In their study, six of the nine deaths were due to hemorrhage and three due to progressive neurological deterioration.[218] However, Söderman et al. detected only one death after hemorrhage among their group of 85 patients (mean follow-up time 11.7 patient-years / patient).[197] Our series showed a tendency to excess mortality after hemorrhage but only during the first seven years. Thereafter, only one death was detected among patients presenting with hemorrhage. However, aggressive behavior of DAVFs with

CVD seems not to be the only cause for mortality. Patients having DAVF with CVD continued to have excess mortality also after the first seven years. Surprisingly, success in DAVF occlusion did not cause any difference in survival.

Patients with transverse and sigmoid sinus DAVFs rarely present with CVD whereas in other locations CVD is significantly more frequent. This may partly explain why the patients with DAVFs in other locations than transverse and sigmoid sinus experienced excess mortality. Interestingly, there was no significant difference between the relative survival of men and women despite the fact that men have significantly more DAVFs in other locations and with CVD.[195]

Causes of death

After surviving the first year, most of the mortality of the DAVF patients was due to cancer (10/50, 20%) and cardiovascular events (9/50, 18%), trauma (6/50, 12%), cerebrovascular events (6/50, 12%) and DAVF-related causes (2/50, 4%). One third (18/50, 36%) of the deaths were due to vascular (16/50, 32% cardiovascular, cerebrovascular) or DAVF-related causes. Eight (16%) were occlusive events (cerebral/myocardial infarction, pulmonary embolism). None of the patients had a known congenital prothrombotic disease. The number of deaths caused by vascular events was more than expected in the general Finnish population, suggesting a correlation between general vascular pathology and CVD due to unknown mechanisms.

7 Conclusions and recommendations

The advances in diagnostic methods (DSA, CT, MRI) have increased the detection rate of DAVFs. Simultaneously, endovascular treatment has improved with the major advance being the introduction of Onyx. The increasing numbers of patients and the experience gained in Onyx embolization, together with promising results of radiosurgery have improved the results of DAVF treatment and patients' outcomes.

During the first 12 months after diagnosis, patients experienced excess mortality, mainly caused by treatment complications. After surviving 12 months from the diagnosis, the overall survival rates of patients with DAVFs were similar to those of a matched general Finnish population. However, in patients harboring DAVFs with CVD, as well as in patients with DAVFs in locations other than transverse and sigmoid sinuses, continuous excess mortality was observed.

7.1 The role of microneurosurgery in management of DAVFs

Nowadays, the treatment of choice for intracranial DAVFs is Onyx embolization with adjuvant radiosurgery or microsurgery when necessary. Only few lesions, mainly Borden type II or III DAVFs, require microneurosurgery. They are either simple cortical fistulas or extremely challenging deep-seated fistulas with multiple small feeders that cannot be treated endovascularly, and usually present with bleeding. The sudden occlusion of the venous outflow, which occurs at surgery, may result in bleeding, large infarction or severe brain swelling during or after surgery. Therefore, occlusion of the CVD alone to change the aggressive course of Borden type II and III DAVFs into benign one is preferred.

Nevertheless, if endovascular treatment and radiosurgery have failed to occlude the fistula, particularly in tentorial and ethmoidal Borden type III DAVFs, microsurgical occlusion is justified. The treatment should be centralized in dedicated neurovascular centers with all treatment modalities available.

List of 6 supplementary videos on microneurosurgery of DAVFs

1. Surgery of right middle fossa DAVF through pterional approach (DAVF video 1)
2. Surgery of parietal superior sagittal sinus DAVF through midline approach (DAVF video 2)
3. Surgery of left anterior fossa DAVF through midline approach (DAVF video 3)
4. Surgery of right tentorial DAVF through suboccipital approach (DAVF video 4)
5. Surgery of right tentorial incisura DAVF through subtemporal approach (DAVF video 5)
6. Surgery of left tentoral incisura DAVF through presigmoid approach (DAVF video 6)

The videos are in Quick Time® format and require a Quicktime® player to be installed. The operations were performed by Professor Juha Hernesniemi at the Department of Neurosurgery, Helsinki University Central Hospital, Finland, between 2008 and 2013.

Acknowledgements

This thesis was carried out at the Department of Neurosurgery at the Helsinki University Central Hospital, in close collaboration with the Department of Neurosurgery at Kuopio University Hospital. I am sincerely thankful to all the people who have helped, guided and encouraged me in both departments during these years.

I wish to express my gratitude especially to:

Juha Hernesniemi, my supervisor, for supporting me and inspiring me to work with your own everlasting enthusiasm and curiosity for cerebrovascular lesions. I have been privileged to be able to follow your uniquely skillful surgery and to be taught by you from the very first years of my studies at the medical school.

Mika Niemelä, my other supervisor, for your patient guidance and support throughout this work. Your encouraging attitude helped me through the moments of despair. Thank you for pushing me forward to finish this work.

Juha Jääskeläinen and **Jaakko Rinne,** for great collaboration in Kuopio. Juha, I am grateful for your innovative thoughts and invaluable comments when planning the study and preparing the manuscripts.

Ville Vuorinen and **Arto Haapaniemi,** the official reviewers of this work, for valuable comments and suggestions, which helped me to improve this work.

Marko Kangasniemi and **Matti Porras,** for help with analyzing the radiological images and providing information about the history of endovascular procedures.

My co-authors, for your valuable contribution to this work. **Aki Laakso,** for sharing your strong expertise in scientific work. **Riku Kivisaari,** for analyzing radiological images and giving helping hand when needed. With your common sense and positive attitude you have helped me to find a solution to many problems.

Ahmed Elsharkawy, Ferzat Hijazy, Hugo Andrade and **Jouke van Popta,** for your invaluable help with video editing.

Karri Seppä from the Cancer Registry, for performing the excellent data analysis on long-term mortality.

Mari Harve for excellent language revision of this thesis.

My neurosurgical, neuroanesthesiological and neuroradiological colleagues and co-workers, for creating a pleasant working environment. I am grateful for your daily friendship and support. Especially, I want to thank **Emilia** and **Päivi,** for helping me by sharing your experience in preparing your recent thesis. **Minna,** it was now my turn to make a mess of our office. Thank you for tolerating it. **Tarja,** for your guidance and helpful hints, from preparing the thesis to arranging the Karonkka. **Teemu,** for your support on numerous scientific and non-scientific sessions over brunch/lunch/dinner.

My colleagues at the Department of Oral and Maxillofacial Surgery, for enjoyable collaboration at clinical work, and for your support and understanding during the hours I spent at your hospital finishing the manuscripts and the thesis.

All my family and friends, for your understanding, support and love. Dear friends, thank you for taking care of my social well being during this process. I am grateful for your company in different activities both below and above the surface throughout these years.

My Mother, for your unwavering support. You have taught me the importance of setting the goal so high that even if not completely reached, the result will still be excellent.

This study was financially supported by Finnish government funding for clinical research at Helsinki University Central Hospital (EVO), Maire Taponen Foundation and the Finnish Medical Foundation.

In Helsinki, May 2013

Anna

References

1. Abrahams JM, Bagley LJ, Flamm ES, Hurst RW, Sinson GP. Alternative management considerations for ethmoidal dural arteriovenous fistulas. Surgical neurology. Dec 2002;58(6):410-416; discussion 416.

2. Al-Shahi R, Bhattacharya JJ, Currie DG, et al. Prospective, population-based detection of intracranial vascular malformations in adults: the Scottish Intracranial Vascular Malformation Study (SIVMS). Stroke; a journal of cerebral circulation. May 2003;34(5):1163-1169.

3. Aminoff MJ. Vascular anomalies in the intracranial dura mater. Brain : a journal of neurology. Sep 1973;96(3):601-612.

4. Arat A, Inci S. Treatment of a superior sagittal sinus dural arteriovenous fistula with Onyx: technical case report. Neurosurgery. Jul 2006;59(1 Suppl 1):ONSE169-170; discussion ONSE169-170.

5. Awad IA, Little JR, Akrawi WP, Ahl J. Intracranial dural arteriovenous malformations: factors predisposing to an aggressive neurological course. Journal of neurosurgery. 1990;72:839-850.

6. Awad IA. Dural Arteriovenous Malformations with Aggressive Course. In: Awad IA, Barrow DL, eds. Dural Arteriovenous Malformations. Park Ridge, IL: AANS Publishers; 1993:93-104.

7. Barcia-Salorio JL, Soler F, Barcia JA, Hernandez G. Stereotactic radiosurgery for the treatment of low-flow carotid-cavernous fistulae: results in a series of 25 cases. Stereotactic and functional neurosurgery. 1994;63(1-4):266-270.

8. Barnwell SL, Halbach VV, Higashida RT, Hieshima G, Wilson CB. Complex dural arteriovenous fistulas. Results of combined endovascular and neurosurgical treatment in 16 patients. Journal of neurosurgery. Sep 1989;71(3):352-358.

9. Barnwell SL, Halbach VV, Dowd CF, Higashida RT, Hieshima GB, Wilson CB. Multiple dural arteriovenous fistulas of the cranium and spine. AJNR. American journal of neuroradiology. May-Jun 1991;12(3):441-445.

10. Barnwell SL. Endovascular Therapy of Dural Arteriovenous Malformations. In: Awad IA, Barrow DL, eds. Dural Arteriovenous Malformations. Park Ridge, IL: AANS Publishers; 1993:193-212.

11. Barrow DL, Spector RH, Braun IF, Landman JA, Tindall SC, Tindall GT. Classification and treatment of spontaneous carotid-cavernous sinus fistulas. Journal of neurosurgery. Feb 1985;62(2):248-256.

12. Bederson JB. Pathophysiology and Animal Models of Dural Arteriovenous Malformations. In: Awad IA, Barrow DL, eds. Dural Arteriovenous Malformations. Park Ridge, IL: AANS Publishers; 1993:23-34.

13. Betti O, Derechinsky V. [Multiple-beam stereotaxic irradiation]. Neuro-Chirurgie. 1983;29(4):295-298.

14. Betti OO. Treatment of arteriovenous malformations with the linear accelerator. Applied neurophysiology. 1987;50(1-6):262.

15. Bitoh S, Hasegawa H, Fujiwara M, Nakata M. Traumatic arteriovenous fistula between the middle meningeal artery and cortical vein. Surgical neurology. Nov 1980;14(5):355-358.

16. Borden JA, Wu JK, Shucart WA. A proposed classification for spinal and cranial dural arteriovenous fistulous malformations and implications for treatment. Journal of neurosurgery. 1995;82:166-179.

17. Brant-Zawadzki M, Gould R, Norman D, Newton TH, Lane B. Digital subtraction cerebral angiography by intraarterial injection: comparison with conventional angiography. AJR. American journal of roentgenology. Feb 1983;140(2):347-353.

18. Browder J. Treatment of carotid artery-cavernous sinus fistula. Report of a case. Arch Ophthal. 1937;18:95-102.

19. Brown RDJ, Wiebers DO, Nichols DA. Intracranial dural arteriovenous fistulae: angiographic predictors of intracranial hemorrhage and clinical outcome in nonsurgical patients. Journal of neurosurgery. 1994;81:531-538.

20. Brown RDJ, Wiebers DO, Torner JC, O'Fallon WM. Incidence and prevalence of intracranial vascular malformations in Olmsted County, Minnesota, 1965 to 1992. Neurology. 1996;46:949-952.

21. Castaigne P, Bories J, Brunet P, Merland JJ, Meininger V. [Meningeal arterio-venous fistulas with cortical venous drainage]. Revue neurologique. Mar 1976;132(3):169-181.

22. Celik O, Piippo A, Romani R, et al. Management of dural arteriovenous fistulas - Helsinki and Kuopio experience. Acta neurochirurgica. Supplement. 2010;107:77-82.

23. Cha KC, Yeon JY, Kim GH, Jeon P, Kim JS, Hong SC. Clinical and angiographic results of patients with dural arteriovenous fistula. Journal of clinical neuroscience : official journal of the Neurosurgical Society of Australasia. Feb 7 2013.

24. Chaichana KL, Coon AL, Tamargo RJ, Huang J. Dural arteriovenous fistulas: Epidemiology and clinical presentation. In: Tamargo RJ, Huang J, eds. Cranial arteriovenous malformations (AVMs) and cranial dural arteriovenous fistulas (DAVFs). Philadelphia, PA: Saunders; 2012:7-13.

25. Chandler HC, Jr., Friedman WA. Successful radiosurgical treatment of a dural arteriovenous malformation: case report. Neurosurgery. Jul 1993;33(1):139-141; discussion 141-132.

26. Chaudhary MY, Sachdev VP, Cho SH, Weitzner I, Jr., Puljic S, Huang YP. Dural arteriovenous malformation of the major venous sinuses: an acquired lesion. AJNR. American journal of neuroradiology. Jan-Feb 1982;3(1):13-19.

27. Chen JC, Tsuruda JS, Halbach VV. Suspected dural arteriovenous fistula: results with screening MR angiography in seven patients. Radiology. Apr 1992;183(1):265-271.

28. Chew J, Weill A, Guilbert F, Raymond J, Audet ME, Roy D. Arterial Onyx embolisation of intracranial DAVFs with cortical venous drainage. The Canadian journal of neurological sciences. Le journal canadien des sciences neurologiques. Mar 2009;36(2):168-175.

29. Choi JH, Mohr JP. Brain arteriovenous malformations in adults. Lancet neurology. May 2005;4(5):299-308.

30. Chung SJ, Kim JS, Kim JC, et al. Intracranial dural arteriovenous fistulas: analysis of 60 patients. Cerebrovasc Dis. 2002;13(2):79-88.

31. Cifarelli CP, Kaptain G, Yen CP, Schlesinger D, Sheehan JP. Gamma knife radiosurgery for dural arteriovenous fistulas. Neurosurgery. Nov 2010;67(5):1230-1235; discussion 1235.

32. Cognard C, Gobin YP, Pierot L, et al. Cerebral dural arteriovenous fistulas: clinical and angiographic correlation with a revised classification of venous drainage. Radiology. Mar 1995;194(3):671-680.

33. Cognard C, Houdart E, Casasco A, Gabrillargues J, Chiras J, Merland JJ. Long-term changes in intracranial dural arteriovenous fistulae leading to worsening in the type of venous drainage. Neuroradiology. Jan 1997;39(1):59-66.

34. Cognard C, Casasco A, Toevi M, Houdart E, Chiras J, Merland JJ. Dural arteriovenous fistulas as a cause of intracranial hypertension due to impairment of cranial venous outflow. J Neurol Neurosurg Psychiatry. 1998;65:308-316.

35. Cognard C, Januel AC, Silva NA, Jr., Tall P. Endovascular treatment of intracranial dural arteriovenous fistulas with cortical venous drainage: new management using Onyx. AJNR. American journal of neuroradiology. Feb 2008;29(2):235-241.

36. Collice M, D'Aliberti G, Talamonti G, et al. Surgical interruption of leptomeningeal drainage as treatment for intracranial dural arteriovenous fistulas without dural sinus drainage. Journal of neurosurgery. May 1996;84(5):810-817.

37. Collice M, D'Aliberti G, Arena O, Solaini C, Fontana RA, Talamonti G. Surgical treatment of intracranial dural arteriovenous fistulae: Role of venous drainage. Neurosurgery. 2000;47(1):56-66.

38. Colombo F, Benedetti A, Pozza F, et al. External stereotactic irradiation by linear accelerator. Neurosurgery. Feb 1985;16(2):154-160.

39. Colombo F, Benedetti A, Pozza F, et al. Stereotactic radiosurgery utilizing a linear accelerator. Applied neurophysiology. 1985;48(1-6):133-145.

40. Colombo F, Benedetti A, Casentini L, Zanusso M, Pozza F. Linear accelerator radiosurgery of arteriovenous malformations. Applied neurophysiology. 1987;50(1-6):257-261.

41. Crummy AB, Strother CM, Sackett JF, et al. Computerized fluoroscopy: digital subtraction for intravenous angiocardiography and arteriography. AJR. American journal of roentgenology. Dec 1980;135(6):1131-1140.

42. Crutchfield WG. Instruments for use in the treatment of certain intracranial vascular lesions. Journal of neurosurgery. Jul 1959;16(4):471-474.

43. da Costa LB, Terbrugge K, Farb R, Wallace MC. Surgical disconnection of cortical venous reflux as a treatment for Borden type II dural arteriovenous fistulae. Acta neurochirurgica. Nov 2007;149(11):1103-1108; discussion 1108.

44. Dandy WE. The Treatment of Carotid Cavernous Arteriovenous Aneurysms. Annals of surgery. Nov 1935;102(5):916-926.

45. Dashti R, Laakso A, Niemela M, Porras M, Hernesniemi J. Microscope-integrated near-infrared indocyanine green videoangiography during surgery of intracranial aneurysms: the Helsinki experience. Surgical neurology. May 2009;71(5):543-550; discussion 550.

46. Dashti R, Laakso A, Niemela M, et al. Application of microscope integrated indocyanine green video-angiography during microneurosurgical treatment of intracranial aneurysms: a review. Acta neurochirurgica. Supplement. 2010;107:107-109.

47. Davie JC, Hodges F. Arteriovenous fistula after removal of meningioma. Case report. Journal of neurosurgery. Oct 1967;27(4):364-369.

48. Davies MA, Terbrugge K, Willinsky R, Coyne T, Saleh J, Wallace MC. The validity of classification for the clinical presentation of intracranial dural arteriovenous fistulas. Journal of neurosurgery. 1996;85:830-837.

49. Davies MA, Saleh J, Ter Brugge K, Willinsky R, Wallace MC. The natural history and management of intracranial dural arteriovenous fistulae. Part 1: benign lesions. Interventional neuroradiology : journal of peritherapeutic neuroradiology, surgical procedures and related neurosciences. Dec 20 1997;3(4):295-302.

50. Davies MA, Ter Brugge K, Willinsky R, Wallace MC. The natural history and management of intracranial dural arteriovenous fistulae. Part 2: aggressive lesions. Interventional neuroradiology : journal of peritherapeutic neuroradiology, surgical procedures and related neurosciences. Dec 20 1997;3(4):303-311.

51. De Jesus O, Rosado JE. Tentorial dural arteriovenous fistula obliterated using the petrosal approach. Surgical neurology. Feb 1999;51(2):164-167.

52. De Marco JK, Dillon WP, Halback VV, Tsuruda JS. Dural arteriovenous fistulas: evaluation with MR imaging. Radiology. Apr 1990;175(1):193-199.

53. Dennery JM, Ignacio BS. Post-traumatic arteriovenous fistula between the external carotid arteries and the superior longitudinal sinus: report of a case. Canadian journal of surgery. Journal canadien de chirurgie. Jul 1967;10(3):333-336.

54. Dion J. Dural Arteriovenous Malformations: Definition, Classification, and Diagnostic Imaging. In: Awad IA, Barrow DL, eds. Dural Arteriovenous Malformations. Park Ridge, IL: AANS Publishers; 1993:1-22.

55. Djindjian R, Merland JJ, Theron J. Superselective arteriography of the external carotid artery. New York: Springer; 1977.

56. Duffau H, Lopes M, Janosevic V, et al. Early rebleeding from intracranial dural arteriovenous fistulas: report of 20 cases and review of the literature. Journal of neurosurgery. Jan 1999;90(1):78-84.

57. Echols DH, Jackson JD. Carotid-cavernous fistula: a perplexing surgical problem. Journal of neurosurgery. Nov 1959;16:619-627.

58. Ederer F, Axtell LM, Cutler SJ. The relative survival rate: a statistical methodology. National Cancer Institute monograph. Sep 1961;6:101-121.

59. Edwards MS, Connolly ES. Cavernous sinus syndrome produced by communication between the external carotid artery and cavernous sinus. Journal of neurosurgery. Jan 1977;46(1):92-96.

60. Fahrig R, Fox AJ, Lownie S, Holdsworth DW. Use of a C-arm system to generate true three-dimensional computed rotational angiograms: preliminary in vitro and in vivo results. AJNR. American journal of neuroradiology. Sep 1997;18(8):1507-1514.

61. Fahrig R, Moreau M, Holdsworth DW. Three-dimensional computed tomographic reconstruction using a C-arm mounted XRII: correction of image intensifier distortion. Medical physics. Jul 1997;24(7):1097-1106.

62. Fahrig R, Nikolov H, Fox AJ, Holdsworth DW. A three-dimensional cerebrovascular flow phantom. Medical physics. Aug 1999;26(8):1589-1599.

63. Fermand M, Reizine D, Melki JP, Riche MC, Merland JJ. Long term follow-up of 43 pure dural arteriovenous fistulae (AVF) of the lateral sinus. Neuroradiology. 1987;29(4):348-353.

64. Freckmann N, Sartor K, Herrmann HD. Traumatic arteriovenous fistulae of the middle meningeal artery and neighbouring veins or dural sinuses. Acta neurochirurgica. 1981;55(3-4):273-281.

65. Friedman JA, Pollock BE, Nichols DA, Gorman DA, Foote RL, Stafford SL. Results of combined stereotactic radiosurgery and transarterial embolization for dural arteriovenous fistulas of the transverse and sigmoid sinuses. Journal of neurosurgery. Jun 2001;94(6):886-891.

66. Furlan AJ, Weinstein MA, Little JR, Modic MT. Digital subtraction angiography in the evaluation of cerebrovascular disease. Neurologic clinics. Feb 1983;1(1):55-72.

67. Gaensler EH, Jackson DE, Jr., Halbach VV. Arteriovenous fistulas of the cervicomedullary junction as a cause of myelopathy: radiographic findings in two cases. AJNR. American journal of neuroradiology. May 1990;11(3):518-521.

68. Gerlach R, Yahya H, Rohde S, et al. Increased incidence of thrombophilic abnormalities in patients with cranial dural arteriovenous fistulae. Neurological research. Oct 2003;25(7):745-748.

69. Gerlach R, Boehm-Weigert M, Berkefeld J, et al. Thrombophilic risk factors in patients with cranial and spinal dural arteriovenous fistulae. Neurosurgery. Oct 2008;63(4):693-698; discussion 698-699.

70. Grady MS, Pobereskin L. Arteriovenous malformations of the dura mater. Surgical neurology. Aug 1987;28(2):135-140.

71. Graeb DA, Dolman CL. Radiological and pathological aspects of dural arteriovenous fistulas. Case report. Journal of neurosurgery. Jun 1986;64(6):962-967.

72. Grist TM, Mistretta CA, Strother CM, Turski PA. Time-resolved angiography: Past, present, and future. Journal of magnetic resonance imaging : JMRI. Dec 2012;36(6):1273-1286.

73. Guedin P, Gaillard S, Boulin A, et al. Therapeutic management of intracranial dural arteriovenous shunts with leptomeningeal venous drainage: report of 53 consecutive patients with emphasis on transarterial embolization with acrylic glue. Journal of neurosurgery. Mar 2010;112(3):603-610.

74. Guo WY, Pan DH, Wu HM, et al. Radiosurgery as a treatment alternative for dural arteriovenous fistulas of the cavernous sinus. AJNR. American journal of neuroradiology. Jun-Jul 1998;19(6):1081-1087.

75. Gurdjian ES. Packing of internal carotid artery with muscle in treatment of carotid-cavernous arteriovenous aneurysm. Arch Ophthal. 1938;19:936-940.

76. Hakulinen T. Cancer survival corrected for heterogeneity in patient withdrawal. Biometrics. Dec 1982;38(4):933-942.

77. Hakulinen T, Seppa K, Lambert PC. Choosing the relative survival method for cancer survival estimation. European journal of cancer (Oxford, England : 1990). Sep 2011;47(14):2202-2210.

78. Halbach VV, Higashida RT, Hieshima GB, Goto K, Norman D, Newton TH. Dural fistulas involving the transverse and sigmoid sinuses: results of treatment in 28 patients. Radiology. May 1987;163(2):443-447.

79. Halbach VV, Higashida RT, Hieshima GB, Wilson CB, Barnwell SL, Dowd CF. Dural arteriovenous fistulas supplied by ethmoidal arteries. Neurosurgery. May 1990;26(5):816-823.

80. Hanggi D, Etminan N, Steiger HJ. The impact of microscope-integrated intraoperative near-infrared indocyanine green videoangiography on surgery of arteriovenous malformations and dural arteriovenous fistulae. Neurosurgery. Oct 2010;67(4):1094-1103; discussion 1103-1094.

81. Hasumi T, Fukushima T, Haisa T, Yonemitsu T, Waragai M. Focal dural arteriovenous fistula (DAVF) presenting with progressive cognitive impairment including amnesia and alexia. Intern Med. 2007;46(16):1317-1320.

82. Hayes GJ. External Carotid-Cavernous Sinus Fistulas. Journal of neurosurgery. Aug 1963;20:692-700.

83. Hernesniemi J, Saari T, Puranen M. Treatment of 23 dural AVMs located at the transverse and sigmoid sinuses. In: Pasqualin A, Da Pian A, eds. New Trends in Management of Cerebro-Vascular Malformations. Austria: Springer-Verlag; 1994:566-569.

84. Hernesniemi J, Ishii K, Karatas A, et al. Surgical technique to retract the tentorial edge during subtemporal approach: technical note. Neurosurgery. Oct 2005;57(4 Suppl):E408; discussion E408.

85. Hernesniemi J, Ishii K, Niemela M, Kivipelto L, Fujiki M, Shen H. Subtemporal approach to basilar bifurcation aneurysms: advanced technique and clinical experience. Acta neurochirurgica. Supplement. 2005;94:31-38.

86. Hernesniemi J, Ishii K, Niemela M, et al. Lateral supraorbital approach as an alternative to the classical pterional approach. Acta neurochirurgica. Supplement. 2005;94:17-21.

87. Heros RC. Lateral suboccipital approach for vertebral and vertebrobasilar artery lesions. Journal of neurosurgery. Apr 1986;64(4):559-562.

88. Heros RC. Cranial arteriovenous fistulas and myelopathy. Journal of neurosurgery. Mar 2011;114(3):828-829; discussion 829.

89. Hieshima GB, Reicher MA, Higashida RT, et al. Intraoperative digital subtraction neuroangiography: a diagnostic and therapeutic tool. AJNR. American journal of neuroradiology. Sep-Oct 1987;8(5):759-767.

90. Hirai T, Korogi Y, Ikushima I, Shigematsu Y, Morishita S, Yamashita Y. Usefulness of source images from three-dimensional time-of-flight MR angiography after treatment of cavernous dural arteriovenous fistulas. Radiation medicine. Sep-Oct 2003;21(5):205-209.

91. Hirono N, Yamadori A, Komiyama M. Dural arteriovenous fistula: a cause of hypoperfusion-induced intellectual impairment. European neurology. 1993;33(1):5-8.

92. Hoh BL, Choudhri TF, Connolly ES, Jr., Solomon RA. Surgical management of high-grade intracranial dural arteriovenous fistulas: leptomeningeal venous disruption without nidus excision. Neurosurgery. Apr 1998;42(4):796-804; discussion 804-795.

93. Houser OW, Baker HL, Jr., Rhoton AL, Jr., Okazaki H. Intracranial dural arteriovenous malformations. Radiology. Oct 1972;105(1):55-64.

94. Houser OW, Campbell JK, Campbell RJ, Sundt TM, Jr. Arteriovenous malformation affecting the transverse dural venous sinus--an acquired lesion. Mayo Clinic proceedings. Mayo Clinic. Oct 1979;54(10):651-661.

95. Huang Q, Xu Y, Hong B, Li Q, Zhao W, Liu J. Use of onyx in the management of tentorial dural arteriovenous fistulae. Neurosurgery. Aug 2009;65(2):287-292; discussion 292-283.

96. Hugosson R, Bergström K. Surgical treatment of dural arteriovenous malformation in the region of the sigmoid sinus. J Neurol Neurosurg Psychiatry. 1974;37:97-101.

97. Hurst RW, Bagley LJ, Galetta S, et al. Dementia resulting from dural arteriovenous fistulas: the pathologic findings of venous hypertensive encephalopathy. AJNR. American journal of neuroradiology. Aug 1998;19(7):1267-1273.

98. Hurst RW, Bagley LJ, Scanlon M, Flamm ES. Dural arteriovenous fistulas of the craniocervical junction. Skull base surgery. 1999;9(1):1-7.

99. Im SH, Oh CW, Han DH. Surgical management of an unruptured dural arteriovenous fistula of the anterior cranial fossa: natural history for 7 years. Surgical neurology. Jul 2004;62(1):72-75; discussion 75.

100. Ishii K, Goto K, Ihara K, et al. High-risk dural arteriovenous fistulae of the transverse and sigmoid sinuses. AJNR. American journal of neuroradiology. Nov-Dec 1987;8(6):1113-1120.

101. Ito M, Sonokawa T, Mishina H, Sato K. Reversible dural arteriovenous malformation-induced venous ischemia as a cause of dementia: treatment by surgical occlusion of draining dural sinus: case report. Neurosurgery. Dec 1995;37(6):1187-1191; discussion 1191-1182.

102. Jahan R, Murayama Y, Gobin YP, Duckwiler GR, Vinters HV, Vinuela F. Embolization of arteriovenous malformations with Onyx: clinicopathological experience in 23 patients. Neurosurgery. May 2001;48(5):984-995; discussion 995-987.

103. Jiang C, Lv X, Li Y, Wu Z. Transarterial Onyx packing of the transverse-sigmoid sinus for dural arteriovenous fistulas. European journal of radiology. Dec 2011;80(3):767-770.

104. Kai Y, Ito K, Kinjo T, et al. Reversibility of cognitive disorder after treatment of dural arteriovenous fistulae. Neuroradiology. Nov 2009;51(11):731-739.

105. Kakarla UK, Deshmukh VR, Zabramski JM, Albuquerque FC, McDougall CG, Spetzler RF. Surgical treatment of high-risk intracranial dural arteriovenous fistulae: Clinical outcomes and avoidance of complications. Neurosurgery. 2007;61:447-459.

106. Kattner KA, Roth TC, Giannotta SL. Cranial base approaches for the surgical treatment of aggressive posterior fossa dural arteriovenous fistulae with leptomeningeal drainage: report of four technical cases. Neurosurgery. May 2002;50(5):1156-1160; discussion 1160-1151.

107. Kattner KA, Roth TC, Nardone EM, Giannotta SL. The treatment of complex dural arteriovenous fistulae through cranial base techniques. Neurology India. Sep 2004;52(3):325-331.

108. Kim DJ, terBrugge K, Krings T, Willinsky R, Wallace C. Spontaneous angiographic conversion of intracranial dural arteriovenous shunt: long-term follow-up in nontreated patients. Stroke; a journal of cerebral circulation. Jul 2010;41(7):1489-1494.

109. Kim DJ, Willinsky RA, Krings T, Agid R, Terbrugge K. Intracranial dural arteriovenous shunts: transarterial glue embolization--experience in 115 consecutive patients. Radiology. Feb 2011;258(2):554-561.

110. Kim MS, Han DH, Kwon OK, Oh CW, Han MH. Clinical characteristics of dural arteriovenous fistula. Journal of clinical neuroscience : official journal of the Neurosurgical Society of Australasia. Mar 2002;9(2):147-155.

111. King WA, Martin NA. Intracerebral hemorrhage due to dural arteriovenous malformations and fistulae. Neurosurgery clinics of North America. Jul 1992;3(3):577-590.

112. Kitajima M, Hirai T, Korogi Y, et al. Retrograde cortical and deep venous drainage in patients with intracranial dural arteriovenous fistulas: comparison of MR imaging and angiographic findings. AJNR. American journal of neuroradiology. Jun-Jul 2005;26(6):1532-1538.

113. Koebbe CJ, Singhal D, Sheehan J, et al. Radiosurgery for dural arteriovenous fistulas. Surgical neurology. Nov 2005;64(5):392-398; discussion 398-399.

114. Kojima T, Miyachi S, Sahara Y, et al. The relationship between venous hypertension and expression of vascular endothelial growth factor: hemodynamic and immunohistochemical examinations in a rat venous hypertension model. Surgical neurology. Sep 2007;68(3):277-284; discussion 284.

115. Korosec FR, Frayne R, Grist TM, Mistretta CA. Time-resolved contrast-enhanced 3D MR angiography. Magnetic resonance in medicine : official journal of the Society of Magnetic Resonance in Medicine / Society of Magnetic Resonance in Medicine. Sep 1996;36(3):345-351.

116. Kraus JA, Stuper BK, Berlit P. Association of resistance to activated protein C and dural arteriovenous fistulas. Journal of neurology. Nov 1998;245(11):731-733.

117. Kraus JA, Stuper BK, Nahser HC, Klockgether T, Berlit P. Significantly increased prevalence of factor V Leiden in patients with dural arteriovenous fistulas. Journal of neurology. Jul 2000;247(7):521-523.

118. Kraus JA, Stuper BK, Muller J, et al. Molecular analysis of thrombophilic risk factors in patients with dural arteriovenous fistulas. Journal of neurology. Jun 2002;249(6):680-682.

119. Krayenbuhl N, Hafez A, Hernesniemi JA, Krisht AF. Taming the cavernous sinus: technique of hemostasis using fibrin glue. Neurosurgery. Sep 2007;61(3 Suppl):E52; discussion E52.

120. Kubalek R, Moghtaderi A, Klisch J, Berlis A, Quiske A, Schumacher M. Cerebral arteriovenous malformations: influence of angioarchitecture on bleeding risk. Acta neurochirurgica. Dec 2003;145(12):1045-1052; discussion 1052.

121. Kwon BJ, Han MH, Kang HS, Chang KH. MR imaging findings of intracranial dural arteriovenous fistulas: relations with venous drainage patterns. AJNR. American journal of neuroradiology. Nov-Dec 2005;26(10):2500-2507.

122. Laakso A, Dashti R, Seppanen J, et al. Long-term excess mortality in 623 patients with brain arteriovenous malformations. Neurosurgery. Aug 2008;63(2):244-253; discussion 253-245.

123. Laine E, Galibert P, Lopez C, Delahousse J, Delandtsheer JM, Christiaens JL. [Intradural Arteriovenous Aneurysms (Developed within the Thickness of the Dura Mater) of the Posterior Fossa]. Neuro-Chirurgie. Apr-Jun 1963;9:147-158.

124. Landman JA, Braun IF. Spontaneous closure of a dural arteriovenous fistula associated with acute hearing loss. AJNR. American journal of neuroradiology. May-Jun 1985;6(3):448-449.

125. Lasjaunias P, Chiu M, ter Brugge K, Tolia A, Hurth M, Bernstein M. Neurological manifestations of intracranial dural arteriovenous malformations. Journal of neurosurgery. May 1986;64(5):724-730.

126. Lawton MT, Jacobowitz R, Spetzler RF. Redefined role of angiogenesis in the pathogenesis of dural arteriovenous malformations. Journal of neurosurgery. Aug 1997;87(2):267-274.

127. Lawton MT, Chun J, Wilson CB, Halbach VV. Ethmoidal dural arteriovenous fistulae: an assessment of surgical and endovascular management. Neurosurgery. Oct 1999;45(4):805-810; discussion 810-801.

128. Lawton MT, Sanchez-Mejia RO, Pham D, Tan J, Halbach VV. Tentorial dural arteriovenous fistulae: operative strategies and microsurgical results for six types. Neurosurgery. Mar 2008;62(3 Suppl 1):110-124; discussion 124-115.

129. Lee PH, Lee JS, Shin DH, Kim BM, Huh K. Parkinsonism as an initial manifestation of dural arteriovenous fistula. European journal of neurology : the official journal of the European Federation of Neurological Societies. May 2005;12(5):403-406.

130. Lee SK, Willinsky RA, Montanera W, ter-Brugge KG. MR imaging of dural arteriovenous fistulas draining into cerebellar cortical veins. AJNR. American journal of neuroradiology. Sep 2003;24(8):1602-1606.

131. Lehecka M, Laakso A, Hernesniemi J. Helsinki Microneurosurgery: Basics and Tricks. 1 ed. Germany: Druckerei Hohl Gmbh & Co.; 2011.

132. Lepoire J, Montaut J, Bouchot M, Laxenaire M. [Intrafrontal Arteriovenous Aneurysms Vascularized by the Anterior Ethmoidal Artery. Apropos of 3 Cases]. Neuro-Chirurgie. Apr-Jun 1963;9:159-166.

133. Lewis AI, Tomsick TA, Tew JM, Jr. Management of tentorial dural arteriovenous malformations: transarterial embolization combined with stereotactic radiation or surgery. Journal of neurosurgery. Dec 1994;81(6):851-859.

134. Lewis AI, Rosenblatt SS, Tew JM, Jr. Surgical management of deep-seated dural arteriovenous malformations. Journal of neurosurgery. Aug 1997;87(2):198-206.

135. Li Q, Fang YB, Huang QH, et al. Transarterial embolization of dural arteriovenous fistulas of the anterior cranial fossa with Onyx. Journal of clinical neuroscience : official journal of the Neurosurgical Society of Australasia. Feb 2013;20(2):287-291.

136. Link MJ, Coffey RJ, Nichols DA, Gorman DA. The role of radiosurgery and particulate embolization in the treatment of dural arteriovenous fistulas. Journal of neurosurgery. 1996;84:804-809.

137. Little JR, Furlan AJ, Modic MT, Bryerton B, Weinstein MA. Intravenous digital subtraction angiography: application to cerebrovascular surgery. Neurosurgery. Aug 1981;9(2):129-136.

138. Little JR, Furlan AJ, Modic MT, Weinstein MA. Digital subtraction angiography in cerebrovascular disease. Stroke; a journal of cerebral circulation. Sep-Oct 1982;13(5):557-566.

139. Liu JK, Dogan A, Ellegala DB, et al. The role of surgery for high-grade intracranial dural arteriovenous fistulas: importance of obliteration of venous outflow. Journal of neurosurgery. May 2009;110(5):913-920.

140. Lucas Cde P, Caldas JG, Prandini MN. Do leptomeningeal venous drainage and dysplastic venous dilation predict hemorrhage in dural arteriovenous fistula? Surgical neurology. 2006;66 Suppl 3:S2-5; discussion S5-6.

141. Lucas Cde P, Mounayer C, Spelle L, Piotin M, Rezende MT, Moret J. Endoarterial management of dural arteriovenous malformations with isolated sinus using Onyx-18: technical case report. Neurosurgery. Nov 2007;61(5 Suppl 2):E293-294; discussion E294.

142. Lucas CP, Zabramski JM, Spetzler RF, Jacobowitz R. Treatment for intracranial dural arteriovenous malformations: A meta-analysis from the English language literature. Neurosurgery. 1997;40(6):1119-1130.

143. Luciani A, Houdart E, Mounayer C, Saint Maurice JP, Merland JJ. Spontaneous closure of dural arteriovenous fistulas: report of three cases and review of the literature. AJNR. American journal of neuroradiology. May 2001;22(5):992-996.

144. Lunsford LD, Kondziolka D, Flickinger JC, et al. Stereotactic radiosurgery for arteriovenous malformations of the brain. Journal of neurosurgery. Oct 1991;75(4):512-524.

145. Lv X, Jiang C, Li Y, Wu Z. Results and complications of transarterial embolization of intracranial dural arteriovenous fistulas using Onyx-18. Journal of neurosurgery. Dec 2008;109(6):1083-1090.

146. Lv X, Jiang C, Li Y, Wu Z. Percutaneous transvenous packing of cavernous sinus with Onyx for cavernous dural arteriovenous fistula. European journal of radiology. Aug 2009;71(2):356-362.

147. Lv X, Jiang C, Li Y, Wu Z. Embolization of intracranial dural arteriovenous fistulas with Onyx-18. European journal of radiology. Mar 2010;73(3):664-671.

148. Lv X, Jiang C, Li Y, Liu L, Liu J, Wu Z. The limitations and risks of transarterial Onyx injections in the treatment of grade I and II DAVFs. European journal of radiology. Dec 2011;80(3):e385-388.

149. Lv X, Yang X, Li Y, Jiang C, Wu Z. Dural arteriovenous fistula with spinal perimedullary venous drainage. Neurology India. Nov-Dec 2011;59(6):899-902.

150. Macdonald JH, Millar JS, Barker CS. Endovascular treatment of cranial dural arteriovenous fistulae: a single-centre, 14-year experience and the impact of Onyx on local practise. Neuroradiology. May 2010;52(5):387-395.

151. Magidson MA, Weinberg PE. Spontaneous closure of a dural arteriovenous malformation. Surgical neurology. Aug 1976;6(2):107-110.

152. Malek AM, Halbach VV, Dowd CF, Higashida RT. Diagnosis and treatment of dural arteriovenous fistulas. Neuroimaging clinics of North America. May 1998;8(2):445-468.

153. Malik GM, Pearce JE, Ausman JI, Mehta B. Dural arteriovenous malformations and intracranial hemorrhage. Neurosurgery. Sep 1984;15(3):332-339.

154. Martins C, Yasuda A, Campero A, Ulm AJ, Tanriover N, Rhoton A, Jr. Microsurgical anatomy of the dural arteries. Neurosurgery. Apr 2005;56(2 Suppl):211-251; discussion 211-251.

155. Maruyama K, Shin M, Kurita H, Tago M, Kirino T. Stereotactic radiosurgery for dural arteriovenous fistula involving the superior sagittal sinus. Case report. Journal of neurosurgery. Dec 2002;97(5 Suppl):481-483.

156. Mironov A. Selective transvenous embolization of dural fistulas without occlusion of the dural sinus. AJNR. American journal of neuroradiology. Feb 1998;19(2):389-391.

157. Mistretta CA, Crummy AB, Strother CM. Digital angiography: a perspective. Radiology. May 1981;139(2):273-276.

158. Modic MT, Weinstein MA, Chilcote WA, et al. Digital subtraction angiography of the intracranial vascular system: comparative study in 55 patients. AJR. American journal of roentgenology. Feb 1982;138(2):299-306.

159. Mullan S. Reflections upon the nature and management of intracranial and intraspinal vascular malformations and fistulae. Journal of neurosurgery. Apr 1994;80(4):606-616.

160. Nabors MW, Azzam CJ, Albanna FJ, Gulya AJ, Davis DO, Kobrine AI. Delayed postoperative dural arteriovenous malformations. Report of two cases. Journal of neurosurgery. May 1987;66(5):768-772.

161. Narvid J, Do HM, Blevins NH, Fischbein NJ. CT angiography as a screening tool for dural arteriovenous fistula in patients with pulsatile tinnitus: feasibility and test characteristics. AJNR. American journal of neuroradiology. Mar 2011;32(3):446-453.

162. Natarajan SK, Ghodke B, Kim LJ, Hallam DK, Britz GW, Sekhar LN. Multimodality treatment of intracranial dural arteriovenous fistulas in the Onyx era: a single center experience. World neurosurgery. Apr 2010;73(4):365-379.

163. Newton TH, Cronqvist S. Involvement of dural arteries in intracranial arteriovenous malformations. Radiology. Nov 1969;93(5):1071-1078.

164. Nogueira RG, Dabus G, Rabinov JD, et al. Preliminary experience with onyx embolization for the treatment of intracranial dural arteriovenous fistulas. AJNR. American journal of neuroradiology. Jan 2008;29(1):91-97.

165. Obrador S, Soto M, Silvela J. Clinical syndromes of arteriovenous malformations of the transverse-sigmoid sinus. J Neurol Neurosurg Psychiatry. May 1975;38(5):436-451.

166. Olivecrona H, Ladenheim J. Congenital Arteriovenous Aneurysms of the Carotid and Vertebral Arterial Systems. Berlin: Springer-Verlag; 1957.

167. Olutola PS, Eliam M, Molot M, Talalla A. Spontaneous regression of a dural arteriovenous malformation. Neurosurgery. Jun 1983;12(6):687-690.

168. Onizuka M, Mori K, Takahashi N, et al. Gamma knife surgery for the treatment of spontaneous dural carotid-cavernous fistulas. Neurologia medico-chirurgica. Oct 2003;43(10):477-482; discussion 482-473.

169. Pan DH, Chung WY, Guo WY, et al. Stereotactic radiosurgery for the treatment of dural arteriovenous fistulas involving the transverse-sigmoid sinus. Journal of neurosurgery. May 2002;96(5):823-829.

170. Pan DH, Wu HM, Kuo YH, Chung WY, Lee CC, Guo WY. Intracranial dural arteriovenous fistulas: natural history and rationale for treatment with stereotactic radiosurgery. Progress in neurological surgery. 2013;27:176-194.

171. Pecker J, Bonnal J, Javalet A. [2 new cases of intradural arteriovenous aneurysm of the posterior fossa fed by the external carotid]. Neuro-Chirurgie. Jul-Aug 1965;11(4):327-332.

172. Pekkola J, Kangasniemi M. Imaging of blood flow in cerebral arteries with dynamic helical computed tomography angiography (DHCTA) using a 64-row CT scanner. Acta Radiol. Sep 2009;50(7):798-805.

173. Pekkola J, Kangasniemi M. Posterior fossa dural arteriovenous fistulas: diagnosis and follow-up with time-resolved imaging of contrast kinetics (TRICKS) at 1.5T. Acta Radiol. May 1 2011;52(4):442-447.

174. Pelz DM, Fox AJ, Vinuela F. Digital subtraction angiography: current clinical applications. Stroke; a journal of cerebral circulation. May-Jun 1985;16(3):528-536.

175. Perrini P, Di Lorenzo N. Surgical occlusion of the leptomeningeal drainage is a safe and effective treatment for intracranial dural arteriovenous fistulas without dural sinus drainage. Acta neurochirurgica. Nov 2004;146(11):1279-1280.

176. Perrini P, Nannini T, Di Lorenzo N. Francesco Rizzoli (1809-1880) and the elusive case of Giulia: the description of an "arteriovenous aneurysm passing through the wall of the skull". Acta neurochirurgica. Feb 2007;149(2):191-196; discussion 196.

177. Pierot L, Chiras J, Duyckaerts C, Jason M, Martin N. Intracranial dural arteriovenous fistulas and sinus thrombosis. Report of five cases. Journal of neuroradiology. Journal de neuroradiologie. Mar 1993;20(1):9-18.

178. Pierot L, Visot A, Boulin A, Dupuy M. Combined neurosurgical and neuroradiological treatment of a complex superior sagittal sinus dural fistula: technical note. Neurosurgery. Jan 1998;42(1):194-197.

179. Pierot L, Januel AC, Herbreteau D, et al. Endovascular treatment of brain arteriovenous malformations using onyx: preliminary results of a prospective multicenter study. Interventional neuroradiology : journal of peritherapeutic neuroradiology, surgical procedures and related neurosciences. Oct 5 2005;11(Suppl 1):159-164.

180. Piton J, Guilleux MH, Guibert-Tranier F, Caille JM. Fistulae of the lateral sinus. Journal of neuroradiology. Journal de neuroradiologie. 1984;11(3):143-159.

181. Pollock BE, Kondziolka D, Flickinger JC, Patel AK, Bissonette DJ, Lunsford LD. Magnetic resonance imaging: an accurate method to evaluate arteriovenous malformations after stereotactic radiosurgery. Journal of neurosurgery. Dec 1996;85(6):1044-1049.

182. Raabe A, Beck J, Gerlach R, Zimmermann M, Seifert V. Near-infrared indocyanine green video angiography: A new method for intraoperative assessment of vascular flow. Neurosurgery. 2003;52:132-139.

183. Randell T, Niemela M, Kytta J, et al. Principles of neuroanesthesia in aneurysmal subarachnoid hemorrhage: The Helsinki experience. Surgical neurology. Oct 2006;66(4):382-388; discussion 388.

184. Rath SA, Derakshani S. Concepts of combined endovascular and surgical treatment for dural arteriovenous fistulae: concepts derived from experience in treating three unusual lesions. Acta neurochirurgica. Mar 2004;146(3):229-235; discussion 235.

185. Rezende MT, Piotin M, Mounayer C, Spelle L, Abud DG, Moret J. Dural arteriovenous fistula of the lesser sphenoid wing region treated with Onyx: technical note. Neuroradiology. Feb 2006;48(2):130-134.

186. Ricolfi F, Manelfe C, Meder JF, et al. Intracranial dural arteriovenous fistulae with perimedullary venous drainage. Anatomical, clinical and therapeutic considerations. Neuroradiology. Nov 1999;41(11):803-812.

187. Romani R, Elsharkawy A, Laakso A, Kangasniemi M, Hernesniemi J. Tailored anterior clinoidectomy through the lateral supraorbital approach: experience with 82 consecutive patients. World neurosurgery. Mar-Apr 2012;77(3-4):512-517.

188. Saito A, Furuno Y, Nishimura S, Kamiyama H, Nishijima M. Spontaneous closure of transverse sinus dural arteriovenous fistula: case report. Neurologia medico-chirurgica. Dec 2008;48(12):564-568.

189. Saito A, Takahashi N, Furuno Y, et al. Multiple isolated sinus dural arteriovenous fistulas associated with antithrombin III deficiency--case report. Neurologia medico-chirurgica. Oct 2008;48(10):455-459.

190. Sarma D, ter Brugge K. Management of intracranial dural arteriovenous shunts in adults. European journal of radiology. Jun 2003;46(3):206-220.

191. Satomi J, van Dijk JM, TerBrugge KG, Willinsky RA, Wallace MC. Benign cranial dural arteriovenous fistulas: outcome of conservative management based on the natural history of the lesion. Journal of neurosurgery. 2002;97:767-770.

192. Satomi J, Satoh K. [Epidemiology and etiology of dural arteriovenous fistula]. Brain and nerve = Shinkei kenkyu no shinpo. Aug 2008;60(8):883-886.

193. Sheehan J. Gamma knife surgery for dural arteriovenous fistula. Journal of neurosurgery. Jun 2006;104(6):864-865; discussion 865-866.

194. Shin EJ, Lalwani AK, Dowd CF. Role of angiography in the evaluation of patients with pulsatile tinnitus. The Laryngoscope. Nov 2000;110(11):1916-1920.

195. Singh V, Smith WS, Lawton MT, Halbach VV, Young WL. Risk factors for hemorrhagic presentation in patients with dural arteriovenous fistulae. Neurosurgery. Mar 2008;62(3):628-635; discussion 628-635.

196. Soderman M, Edner G, Ericson K, et al. Gamma knife surgery for dural arteriovenous shunts: 25 years of experience. Journal of neurosurgery. Jun 2006;104(6):867-875.

197. Soderman M, Pavic L, Edner G, Holmin S, Andersson T. Natural history of dural arteriovenous shunts. Stroke; a journal of cerebral circulation. Jun 2008;39(6):1735-1739.

198. Steiner L, Leksell L, Greitz T, Forster DM, Backlund EO. Stereotaxic radiosurgery for cerebral arteriovenous malformations. Report of a case. Acta chirurgica Scandinavica. 1972;138(5):459-464.

199. Steiner L, Leksell L, Forster DM, Greitz T, Backlund EO. Stereotactic radiosurgery in intracranial arterio-venous malformations. Acta neurochirurgica. 1974;Suppl 21:195-209.

200. Stiefel MF, Albuquerque FC, Park MS, Dashti SR, McDougall CG. Endovascular treatment of intracranial dural arteriovenous fistulae using Onyx: a case series. Neurosurgery. Dec 2009;65(6 Suppl):132-139; discussion 139-140.

201. Strother CM, Sackett JF, Crummy AB, et al. Intravenous video arteriography of the intracranial vasculature: early experience. AJNR. American journal of neuroradiology. May-Jun 1981;2(3):215-218.

202. Suh DC, Lee JH, Kim SJ, et al. New concept in cavernous sinus dural arteriovenous fistula: correlation with presenting symptom and venous drainage patterns. Stroke; a journal of cerebral circulation. Jun 2005;36(6):1134-1139.

203. Sundt TM, Jr., Piepgras DG. The surgical approach to arteriovenous malformations of the lateral and sigmoid dural sinuses. Journal of neurosurgery. Jul 1983;59(1):32-39.

204. Tadavarthy SM, Moller JH, Amplatz K. Polyvinyl alcohol (Ivalon)--a new embolic material. The American journal of roentgenology, radium therapy, and nuclear medicine. Nov 1975;125(3):609-616.

205. Tahon F, Salkine F, Amsalem Y, Aguettaz P, Lamy B, Turjman F. Dural arteriovenous fistula of the anterior fossa treated with the Onyx liquid embolic system and the Sonic microcatheter. Neuroradiology. May 2008;50(5):429-432.

206. Terada T, Tsuura M, Komai N, et al. The role of angiogenic factor bFGF in the development of dural AVFs. Acta neurochirurgica. 1996;138(7):877-883.

207. Thompson BG, Doppman JL, Oldfield EH. Treatment of cranial dural arteriovenous fistulae by interruption of leptomeningeal venous drainage. Journal of neurosurgery. Apr 1994;80(4):617-623.

208. Tirakotai W, Bian LG, Bertalanffy H, Siegfried B, Sure U. Immunohistochemical study in dural arteriovenous fistula and possible role of ephrin-B2 for development of dural arteriovenous fistula. Chinese medical journal. Dec 2004;117(12):1815-1820.

209. Tomak PR, Cloft HJ, Kaga A, Cawley CM, Dion J, Barrow DL. Evolution of the Management of Tentorial Dural Arteriovenous Malformations. Neurosurgery. 2003;52(4):750-762.

210. Toulgoat F, Mounayer C, Tulio Salles Rezende M, et al. [Transarterial embolisation of intracranial dural arteriovenous malformations with ethylene vinyl alcohol copolymer (Onyx18)]. Journal of neuroradiology. Journal de neuroradiologie. Apr 2006;33(2):105-114.

211. Tsai LK, Jeng JS, Liu HM, Wang HJ, Yip PK. Intracranial dural arteriovenous fistulas with or without cerebral sinus thrombosis: analysis of 69 patients. J Neurol Neurosurg Psychiatry. Nov 2004;75(11):1639-1641.

212. Ugrinovski J, Vrcakovski M, Lozance K. Dural arteriovenous malformation secondary to meningioma removal. British journal of neurosurgery. 1989;3(5):603-607.

213. Uranishi R, Nakase H, Sakaki T. Expression of angiogenic growth factors in dural arteriovenous fistula. Journal of neurosurgery. Nov 1999;91(5):781-786.

214. van Dijk JM, TerBrugge KG, Willinsky RA, Wallace MC. Multiplicity of dural arteriovenous fistulas. Journal of neurosurgery. 2002;96:76-78.

215. van Dijk JM, TerBrugge KG, Willinsky RA, Wallace MC. Selective disconnection of cortical venous reflux as treatment for cranial dural arteriovenous fistulas. Journal of neurosurgery. 2004;101:31-35.

216. van Dijk JM, TerBrugge KG, Van der Meer FJ, Wallace MC, Rosendaal FR. Thrombophilic factors and the formation of dural arteriovenous fistulas. Journal of neurosurgery. Jul 2007;107(1):56-59.

217. van Dijk JM, Terbrugge KG, Willinsky RA, Wallace MC. The natural history of dural arteriovenous shunts: the toronto experience. Stroke; a journal of cerebral circulation. May 2009;40(5):e412; author reply e413-414.

218. van Dijk JMC. Clinical Course of Cranial Dural Arteriovenous Fistulas With Long-Term Persistent Cortical Venous Reflux. Stroke; a journal of cerebral circulation. 2002;33(5):1233-1236.

219. van Vaals JJ, Brummer ME, Dixon WT, et al. "Keyhole" method for accelerating imaging of contrast agent uptake. Journal of magnetic resonance imaging : JMRI. Jul-Aug 1993;3(4):671-675.

220. Versari PP, D'Aliberti G, Talamonti G, Branca V, Boccardi E, Collice M. Progressive myelopathy caused by intracranial dural arteriovenous fistula: report of two cases and review of the literature. Neurosurgery. Nov 1993;33(5):914-918; discussion 918-919.

221. Vinuela F, Fox AJ, Pelz DM, Drake CG. Unusual clinical manifestations of dural arteriovenous malformations. Journal of neurosurgery. Apr 1986;64(4):554-558.

222. Vlak MH, Algra A, Brandenburg R, Rinkel GJ. Prevalence of unruptured intracranial aneurysms, with emphasis on sex, age, comorbidity, country, and time period: a systematic review and meta-analysis. Lancet neurology. Jul 2011;10(7):626-636.

223. Watanabe A, Takahara Y, Ibuchi Y, Mizukami K. Two cases of dural arteriovenous malformation occurring after intracranial surgery. Neuroradiology. 1984;26(5):375-380.

224. Weinstein MA, Modic MT, Furlan AJ, Pavlicek W, Little JR. Digital subtraction angiography in the evaluation of intracranial and extracranial vascular disease. Cardiovascular and interventional radiology. 1983;6(4-6):187-196.

225. Wermer MJ, van der Schaaf IC, Algra A, Rinkel GJ. Risk of rupture of unruptured intracranial aneurysms in relation to patient and aneurysm characteristics: an updated meta-analysis. Stroke; a journal of cerebral circulation. Apr 2007;38(4):1404-1410.

226. Willems PW, Brouwer PA, Barfett JJ, terBrugge KG, Krings T. Detection and classification of cranial dural arteriovenous fistulas using 4D-CT angiography: initial experience. AJNR. American journal of neuroradiology. Jan 2011;32(1):49-53.

227. Willinsky R, Terbrugge K, Montanera W, Mikulis D, Wallace MC. Venous congestion: an MR finding in dural arteriovenous malformations with cortical venous drainage. AJNR. American journal of neuroradiology. Sep 1994;15(8):1501-1507.

228. Willinsky R, Goyal M, terBrugge K, Montanera W. Tortuous, engorged pial veins in intracranial dural arteriovenous fistulas: correlations with presentation, location, and MR findings in 122 patients. AJNR. American journal of neuroradiology. Jun-Jul 1999;20(6):1031-1036.

229. Wu HM, Pan DH, Chung WY, et al. Gamma Knife surgery for the management of intracranial dural arteriovenous fistulas. Journal of neurosurgery. Dec 2006;105 Suppl:43-51.

230. Yang H, Kano H, Kondziolka D, et al. Stereotactic radiosurgery with or without embolization for intracranial dural arteriovenous fistulas. Progress in neurological surgery. 2013;27:195-204.

231. Yang HC, Kano H, Kondziolka D, et al. Stereotactic radiosurgery with or without embolization for intracranial dural arteriovenous fistulas. Neurosurgery. Nov 2010;67(5):1276-1283; discussion 1284-1275.

232. Yokota M, Tani E, Maeda Y, Yamaura I. Meningioma in sigmoid sinus groove associated with dural arteriovenous malformation: case report. Neurosurgery. Aug 1993;33(2):316-319; discussion 319.