

## Case Report

# Multiple cerebral hydatid cysts in 8-year-old boy: A case report and literature review of a rare presentation

Muhammad Babar Khan, Muhammad Riaz, Muhammad Ehsan Bari

Department of Surgery, Section of Neurosurgery, Aga Khan University Hospital, Karachi, Pakistan

E-mail: Muhammad Babar Khan - babarkhan08@gmail.com; Muhammad Riaz - muhammad.riyaz@aku.edu; \*Muhammad Ehsan Bari - ehsan.bari@aku.edu

\*Corresponding Author

Received: 08 February 15 Accepted: 09 June 15 Published: 29 July 15

**This article may be cited as:**Khan MB, Riaz M, Bari ME. Multiple cerebral hydatid cysts in 8-year-old boy: A case report and literature review of a rare presentation. Surg Neurol Int 2015;6:125. [http://surgicalneurologyint.com/surgicalint\\_articles/Multiple-cerebral-hydatid-cysts-in-8-year-old-boy-A-case-report-and-literature-review-of-a-rare-presentation/](http://surgicalneurologyint.com/surgicalint_articles/Multiple-cerebral-hydatid-cysts-in-8-year-old-boy-A-case-report-and-literature-review-of-a-rare-presentation/)

Copyright: © 2015 Khan MB. This is an open-access article distributed under the terms of the Creative Commons Attribution License, which permits unrestricted use, distribution, and reproduction in any medium, provided the original author and source are credited.


## Abstract

**Background:** Multiple cerebral hydatid cysts are very rare with only a few reports in the literature detailing diagnostic workup, medical management, surgical techniques, possible complications, and outcomes.

**Case Description:** We present the case of an 8-year-old boy who presented with progressively worsening headaches, vomiting, and intermittent fever since 20 days. Diagnostic workup was performed, and magnetic resonance imaging revealed multiple intracranial cysts predominantly in the right frontal region with significant mass effect. A total of 19 intracranial cysts were removed surgically, and the child recovered uneventfully.

**Conclusions:** Neurosurgeons should keep hydatidosis in the list of differentials when evaluating patients with cystic diseases of the brain. Although the removal of such cysts is challenging, outcomes are excellent when cysts are evacuated without rupture and patients show complete resolution of symptoms.

**Key Words:** Albendazole, *Echinococcus*, hydatid cysts, intracranial, surgical excision

|   |
|---|
| <b>Access this article online</b>   |
| <b>Website:</b><br><a href="http://www.surgicalneurologyint.com">www.surgicalneurologyint.com</a> |
| <b>DOI:</b><br>10.4103/2152-7806.161785   |
| <b>Quick Response Code:</b>   |
|              |

## INTRODUCTION

Infection with *Echinococcus* larvae causes hydatid disease in humans.<sup>[5,13]</sup> Hydatid cysts occur most commonly in the lung and liver with intracranial involvement reported in 0.5–3% of all hydatid disease.<sup>[2,5]</sup> Cerebral hydatidosis is thus a rare disease entity and represents 0.05% of all intracranial mass lesions in the developed world.<sup>[3,6,9,13,14]</sup> Primary cysts are often solitary, spherical, unilocular lesions, and can be surgically excised.<sup>[13]</sup> Multiple cysts are very rare with only a few reports in the current literature.<sup>[2,3,6,8-10,13,14]</sup> Surgical excision of multiple cysts can be very challenging as these are often disseminated and involve vital structures.<sup>[13]</sup>

Here, we report the case of an 8-year-old boy with 19 intracranial cysts, which were successfully removed surgically and also review the literature with an emphasis on diagnosis and management of patients with multiple cerebral cysts.

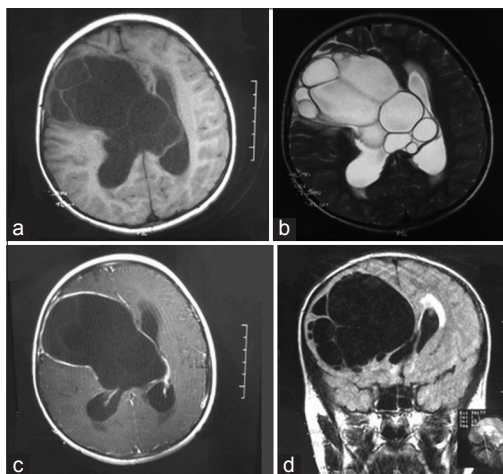
## CASE REPORT

This 8-year-old boy presented with complaints of progressively worsening headaches along with vomiting and intermittent fever since 20 days. There were no significant findings on general physical and neurological examination. The patient's routine laboratory investigations were normal. A magnetic resonance imaging (MRI) brain was performed which showed

multiple intracranial cysts predominantly in the right frontal region with significant mass effect [Figure 1]. The patient's chest X-ray, ultrasound abdomen, and eosinophil counts were normal. The patient was started on dexamethasone, levetiracetam, and albendazole and scheduled for surgery.

A frontoparietal craniotomy was performed. There was significant dural tension, and a c-shaped durotomy was done which revealed a huge hydatid cyst extending toward the lateral ventricle [Figure 2a]. A soft rubber catheter was inserted between the brain parenchyma and the cyst capsule (Dowling's technique); a cleavage plane was established using warm hypertonic saline and the cyst was delivered unruptured [Figure 2d]. Numerous daughter cysts were then identified which were carefully delivered unruptured using the same technique [Figure 2b and c]. We were able to remove all of the 19 cysts without rupturing the cyst capsule this way. An endoscope was used after removing all the cysts to make sure that none of the daughter cysts was left behind. The cavity was copiously irrigated with hypertonic saline and hydrogen peroxide. Histopathological examination confirmed hydatid cyst and no bacterial agent was isolated.

The patient continued taking albendazole (200 mg, BID), dexamethasone, cefazolin, and levetiracetam postoperatively and had an uneventful postoperative course. The patient was seen in clinic on 3 months postoperative visit and his complaints of headache and vomiting had completely resolved. His neurological examination was completely normal and considering financial constraints a follow-up computed tomography (CT) scan was thus not performed.



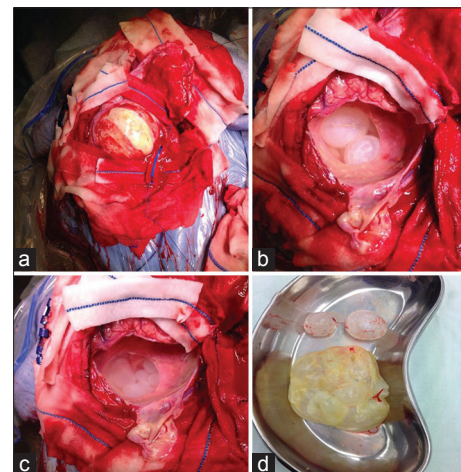
**Figure 1:** (a) T1-weighted magnetic resonance imaging axial section demonstration multiple cysts generating a hypointense signal. Multiple septations can be appreciated significant mass effect can be appreciated. (b) T2-weighted magnetic resonance imaging axial section representing multiple cysts with a hyperintense signal and the cyst walls generating a hypointense signal. (c) T1-contrast enhanced magnetic resonance imaging axial cut showing contrast enhancement of the cyst wall in some regions. (d) Fluid attenuated inversion recovery sequence coronal section showing multiple cysts as hypointense signals and significant mass effect

## DISCUSSION

Hydatid disease is a potentially fatal parasitic infection that can affect wildlife animals, commercial stock, and humans.<sup>[2,5]</sup> Humans act as intermediate hosts in the tapeworm lifecycle and become infected either due to direct contact with an infected animal or ingestion of food contaminated with the feces of an infected animal.<sup>[2,5]</sup> The most common infecting larvae are of *Echinococcus multilocularis* and *Echinococcus granulosus*.<sup>[2,5,13]</sup> Most of the cases have been reported in the pediatric age group.<sup>[13]</sup> Hydatid cysts are generally located in the territory of the middle cerebral artery and posterior fossa, or infratentorial lesions are very rare.<sup>[2,6]</sup> These cysts are benign in nature, and symptoms depend on the size and location of the cyst. The first signs of cranial involvement are usually an increase in intracranial pressure secondary to the mass effect of the cysts.<sup>[13]</sup> Other commonly reported symptoms include speech disorders, urinary incontinence motor weakness, and seizures.<sup>[3,9,14]</sup>

A viable primary lesion could rupture spontaneously or due to trauma or surgery. The spillage of the scolices in the brain parenchyma results in multiple secondary hydatid cysts.<sup>[1,6,14]</sup> Multiple cysts could also occur as a result of rupture of a cyst located in the left atrium or ventricle and in the great arterial vessels.<sup>[1,14]</sup> Another rarely reported possibility is ingestion of multiple larvae and their arterial embolism causing multiple cerebral cysts.<sup>[1,14]</sup> Such rare multiple secondary cysts are infertile as they lack brood capsules and scolices.<sup>[1,6,14]</sup>

Both CT and MRI scan have been reported to be useful in the correct preoperative diagnosis of cerebral hydatid cysts.<sup>[4,6,9,13]</sup> The lesions appear as hypodense, intraparenchymal circular lesions without perifocal edema, and a hyperdense rim on noncontrast CT



**Figure 2:** (a) Intraoperative photograph demonstrating the durotomy incision and the capsule of a huge hydatid cyst. (b and c) Photograph of daughter/secondary cysts in the brain parenchyma after the first cyst was removed. (d) The main cyst and two daughter cysts after excision with intact capsules

scans.<sup>[1,13,14]</sup> However, MRI is superior to CT scan as it shows greater soft tissue detail and can define the anatomical location of the lesion relative to sulci and ventricles, which aid in operative planning.<sup>[13,14]</sup> On MRI, the cyst gives hypointense signals on T1-weighted images, and hyperintense signals on T2-weighted images, and the cyst wall gives hypointense signals on both T1- and T2-weighted images.<sup>[5]</sup> Calcification of the cyst wall is rare and reported in about 1% of the cases.<sup>[2]</sup> The presence of daughter cysts is considered pathognomonic.<sup>[2]</sup> Other differentials for cystic lesions include cystic tumors, pyogenic brain abscess, and cystic lesions such as porencephalic cysts or arachnoid cyst.<sup>[6,11]</sup> These can be differentiated from hydatid cysts as cystic tumors have an enhancing mural nodule and tumor edges, and the central necrosis of pyogenic abscess is almost always accompanied by peripheral edema with contrast enhancing margins. Similarly, unlike hydatid cysts, porencephalic and arachnoid cysts are not spherical and are not surrounded by brain parenchyma.<sup>[2]</sup> Moreover, arachnoid cysts are always extra-axial, and porencephalic cysts have a rim of gliotic white matter that is, easily observable on MRI.<sup>[2]</sup>

Serological tests have traditionally had low sensitivity and specificity in diagnosing intracerebral hydatid cysts.<sup>[2,5]</sup> Serological tests were normal in our patient as well, and thus we believe that serology has limited use in the diagnosis and postoperative follow-up of intracerebral cysts. However, serological tests and especially the newer enzyme-linked immunosorbent assays maybe more useful in diagnosing hydatid disease involving multiple organs.<sup>[5]</sup>

Successful medical treatment of liver and abdominal hydatid cysts with albendazole, mebendazole, and praziquantel has been well reported in the literature.<sup>[14]</sup> However, there is only scarce literature on the successful use of these drugs as the sole treatment of cerebral hydatidosis and there are concerns about the penetration of these drugs across the blood-brain barrier and the cyst capsule.<sup>[5,7,10,13,14]</sup> There is no uniform consensus on the normal rate of growth of these cysts intracranially and growth rates of 1–10 cm/year have been reported.<sup>[5,8,9,12,13]</sup> It may thus be difficult to assess objectively the effect of medical therapy alone on these cysts. Moreover, albendazole has been reported ineffective in cases of large cerebral hydatid cysts.<sup>[14]</sup> We believe that surgical excision of the cyst is always warranted in cases of elevated intracranial pressure with no other contraindications to surgery. Two surgical techniques have been described for the excision of these cysts in literature. The Dowling-Orlando technique is the preferred option and involves inserting a rubber catheter between the cyst wall and parenchyma and irrigation with normal saline in order to establish a cleavage plane and deliver the cyst intact.<sup>[5,9]</sup> Alternatively, deeply seated cysts can be

punctured and aspirated, however, this technique has an increased risk of cyst rupture.<sup>[5]</sup> Cyst rupture can result in local recurrence and secondary cysts, meningitis, and anaphylaxis. It is recommended that the whole cyst cavity be copiously irrigated with hypertonic saline after the surgery and especially if a cyst has ruptured. In the later case, all the cyst contents should also be carefully sucked out. Albendazole therapy maybe continued after excision to prevent any recurrences.<sup>[13]</sup> However, at present there are no evidence based guidelines on the efficacy or duration of treatment with albendazole postoperatively.<sup>[5]</sup> Known surgical complications are rare but include subdural effusion, hemorrhage, and hydrocephalus.<sup>[5]</sup> These might require a second procedure and ventriculoperitoneal shunting.

## CONCLUSION

Neurosurgeons should keep hydatidosis in the list of differentials when evaluating patients with cystic diseases of the brain. An MRI can greatly aid in diagnosis and surgical planning. The goal of surgery should be total excision of intact cyst which should be followed by antibiotic and antihelminthic treatment to avoid recurrence. Surgical outcomes are excellent, and patients show complete resolution of symptoms after complete excision of the cyst.

## REFERENCES

- Boles DM. Cerebral echinococcosis. *Surg Neurol* 1981;16:280-2.
- Bükte Y, Kemaloglu S, Nazaroglu H, Ozkan U, Ceviz A, Simsek M. Cerebral hydatid disease: CT and MR imaging findings. *Swiss Med Wkly* 2004;134:459-67.
- Cavusoglu H, Tuncer C, Ozdilmaç A, Aydın Y. Multiple intracranial hydatid cysts in a boy. *Turk Neurosurg* 2009;19:203-7.
- Diren HB, Ozcanli H, Boluk M, Kilic C. Unilocular orbital, cerebral and intraventricular hydatid cysts: CT diagnosis. *Neuroradiology* 1993;35:149-50.
- Duishanbai S, Jiafu D, Guo H, Liu C, Liu B, Aishalong M, et al. Intracranial hydatid cyst in children: Report of 30 cases. *Childs Nerv Syst* 2010;26:821-7.
- Gana R, Skhissi M, Maaqili R, Bellakhdar F. Multiple infected cerebral hydatid cysts. *J Clin Neurosci* 2008;15:591-3.
- Martín Oterino JA, Chimpén Ruiz VA, Reviriego Jaén G, Sánchez Rodríguez A. Repeated strokes as a sign of multiple cerebral hydatid cysts. *Neurologia* 1996;11:307-9.
- Pasaoglu A, Orhon C, Akdemir H. Multiple primary hydatid cysts of the brain. *Turk J Pediatr* 1989;31:57-61.
- Sen N, Laha D, Gangopadhyay PK, Mohanty BC. Young girl with multiple intracranial hydatid cyst. *Ann Neurosci* 2012;19:96-8.
- Todorov T, Vutova K, Petkov D, Balkanski G. Albendazole treatment of multiple cerebral hydatid cysts: Case report. *Trans R Soc Trop Med Hyg* 1988;82:150-2.
- Tüzün M, Hekimoglu B. Hydatid disease of the CNS: Imaging features. *AJR Am J Roentgenol* 1998;171:1497-500.
- Vaquero J, Jiménez C, Martínez R. Growth of hydatid cysts evaluated by CT scanning after presumed cerebral hydatid embolism. Case report. *J Neurosurg* 1982;57:837-8.
- Yüceer N, Güven MB, Yılmaz H. Multiple hydatid cysts of the brain: A case report and review of the literature. *Neurosurg Rev* 1998;21:181-4.
- Yurt A, Avci M, Selçuki M, Ozer F, Camlar M, Uçar K, et al. Multiple cerebral hydatid cysts. Report of a case with 24 pieces. *Clin Neurol Neurosurg* 2007;109:821-6.