

Case Report

Surgical decompression coupled with diagnostic dynamic intraoperative angiography for bow hunter's syndrome

Ha Son Nguyen, Ninh Doan, Gerald Eckardt, Glen Pollock

Department of Neurosurgery, Medical College of Wisconsin, Milwaukee, Wisconsin, USA

E-mail: *Ha Son Nguyen - hsnguyen@mcw.edu; Ninh Doan - ndoan@mcw.edu; Gerald Eckardt - geckardt@mcw.edu; Glen Pollock - gpollock@mcw.edu

*Corresponding author

Received: 05 June 15 Accepted: 29 July 15 Published: 14 September 15


Abstract

Background: Bow hunter's syndrome, also known as rotational vertebrobasilar insufficiency, arises from mechanical compression of the vertebral artery during the neck rotation. Surgical options have been the mainstay treatment of choice. Postoperative imaging is typically used to assess adequate decompression. On the other hand, intraoperative assessment of decompression has been rarely reported.

Case Description: A 52-year-old male began to see "black spots," and experienced presyncope whenever he rotated his head toward the right. The patient ultimately underwent a dynamic diagnostic cerebral angiogram, which revealed a dominant right vertebral artery and complete proximal occlusion of the right vertebral artery with the head rotated toward the right. Subsequently, the patient underwent an anterior transcervical approach to the right C6/C7 transverse process. The bone removal occurred along with the anterior wall of the C6 foramen transversarium, followed by the upper portion of the anterior C6 body medially, and the transverse process of C6 laterally. An oblique osseofibrous band was noted to extend across the vertebral artery; it was dissected and severed. An intraoperative cerebral angiogram confirmed no existing compression of the vertebral artery with the head rotated toward the right. The patient recovered from surgery without issues; he denied recurrence of preoperative symptoms at follow-up.

Conclusions: The authors report the third instance where intraoperative dynamic angiography was employed with good outcomes. Although intraoperative cerebral angiography is an invasive procedure, which prompts additional risks, the authors believe the modality affords better, real-time visualization of the vertebral artery, allowing for assessment of the adequacy of the decompression. This advantage may reduce the probability for a second procedure, which has its own set of risks, and may counteract the risks involved with intraoperative dynamic angiography.

Key Words: Bow hunter's syndrome, intraoperative angiography, surgical decompression

Access this article online
Website: www.surgicalneurologyint.com
DOI: 10.4103/2152-7806.165173
Quick Response Code:


INTRODUCTION

Bow hunter's syndrome, also known as rotational vertebrobasilar insufficiency, arises from mechanical compression of the vertebral artery during neck rotation.^[4] Diagnosis is typically made based on dynamic digital subtraction cerebral angiography (DSA). Symptoms typically occur due to occlusion of the dominant vertebral

This is an open access article distributed under the terms of the Creative Commons Attribution-NonCommercial-ShareAlike 3.0 License, which allows others to remix, tweak, and build upon the work non-commercially, as long as the author is credited and the new creations are licensed under the identical terms.

For reprints contact: reprints@medknow.com

How to cite this article: Nguyen HS, Doan N, Eckardt G, Pollock G. Surgical decompression coupled with diagnostic dynamic intraoperative angiography for bow hunter's syndrome. *Surg Neurol Int* 2015;6:147.

<http://surgicalneurologyint.com/Surgical-decompression-coupled-with-diagnostic-dynamic-intraoperative-angiography-for-bow-hunter's-syndrome/>

artery, but may also result from the nondominant vertebral artery.^[1] Etiologies of the occlusion include osteophytes, ligamentous bands, cervical instability, or atypical vessel anatomy.^[1] The level of occlusion predominantly involves the V2 segment, followed by the V3 segment.^[4] Treatment options include conservative management, traction, surgical decompression, spinal fusion, endovascular stent placement, and vessel bypass.^[4] For surgical approaches, intraoperative assessment of sufficient decompression has been rarely reported. The authors report the third instance where intraoperative dynamic angiography was employed and review the literature regarding intraoperative assessment for the treatment of bow hunter's syndrome.

CASE PRESENTATION

A 52-year-old male, with a history of multiple right shoulder surgeries, began to see "black spots" and experienced presyncope whenever he rotated his head toward the right. Moreover, he noted decreased sensation in the median nerve distribution on his right hand. He denied any vertigo, diplopia, or syncope. Given concerns for transient cerebral ischemia either as a consequence of a vertebral artery stenosis or a steal syndrome, a computed tomography angiography (CTA) head and neck was obtained, which revealed no significant stenosis of the right subclavian artery or vertebral artery. Magnetic resonance imaging (MRI) brain was unremarkable; MRI cervical spine exhibited multilevel degenerative disc disease without spinal canal narrowing. Subsequently, the patient underwent a dynamic cerebral angiogram, which revealed complete proximal occlusion of the right vertebral artery with the head turned toward the right [Figures 1a and b and 2a and b].

Decompression of the vertebral artery was recommended. An incision was made along the anterior border of the sternocleidomastoid muscle down to the suprasternal notch. The avascular plane medial to the border of the sternocleidomastoid muscle exposed. Dissection was carried down to the C6 transverse process after the

division of the omohyoid muscle and the sternal head of the sternocleidomastoid muscle. The disk space at C6–C7 was confirmed with C-arm fluoroscopy. The longus colli muscle was detached from the vertebral body anteriorly, and the fascia overlying the longus colli was incised and reflected laterally in an attempt to protect the sympathetic chain, which was not visualized. The longus colli muscle was then incised over the C6 transverse process and reflected laterally, allowing for identification of the transverse foramen and the vertebral artery, which was confirmed by palpation and a micro-Doppler assessment.

The bone removal occurred along with the anterior wall of the C6 foramen transversarium, followed by the upper portion of the anterior C6 body medially, and the transverse process of C6 laterally. This completed a 270° decompression of the foramen transversarium of C6. An oblique fibrous band was noted to extend across the vertebral artery in its anterior aspect superomedially to anterolaterally, starting at the level of the foramen transversarium of C6 and extending inferolaterally. The fibrous band was carefully dissected off the vertebral artery, and then severed using a 15 blade. An intraoperative cerebral angiogram initially imaged the right vertebral artery in neutral position [Figure 3]. When the head was turned toward the right, the artery maintained normal flow [Figure 4]. Subsequently, the wound was closed along anatomical layers. The patient recovered from surgery without issues; he denied recurrence of preoperative symptoms at follow-up.

DISCUSSION

More than half of the patients with bow hunter's syndrome present with syncope, while at least a third also exhibit vertigo, dizziness, and/or impaired vision.^[4] Less common symptoms include hypoacusis, dysphagia, and arm pain.^[4] Several modalities have been utilized for diagnosis, including transcranial Doppler,^[8] cerebral blood flow scintigraphy,^[5] and dynamic vascular studies (i.e., CTA, magnetic resonance angiography,^[1]

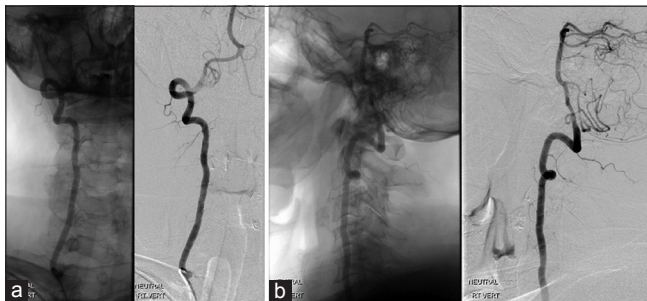


Figure 1: (a) Preoperative angiogram, right vertebral artery injection, with head in a neutral position anterior-posterior (AP). (b) Preoperative angiogram, right vertebral artery injection, with head in neutral position (lateral)

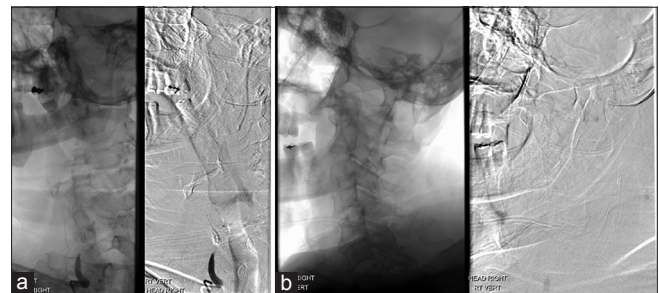


Figure 2: (a) Preoperative angiogram, right vertebral artery injection, with head turn rotated right (AP). (b) Preoperative angiogram, right vertebral artery injection, with head turn rotated right (lateral)

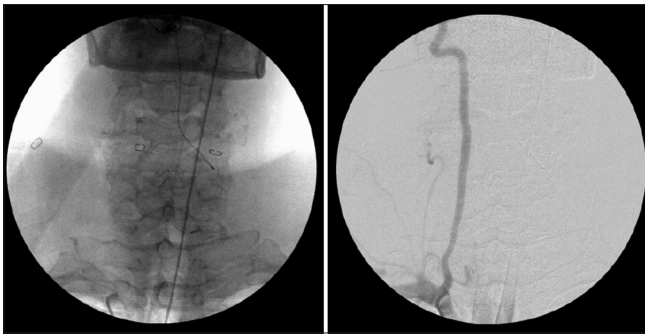

Figure 3: Intraoperative angiogram, right vertebral artery injection, with patient's head in neutral position (AP)

or DSA). From the recent extensive review by Jost and Dailey,^[4] surgical decompression without fusion has been the predominant treatment option, and have helped resolved symptoms in 87% of prior patients. Decompression and fusion, or fusion alone, have also had success. Other options include conservative management, use of a collar, traction, surgical decompression, spinal fusion, endovascular stent placement, and vessel bypass.^[2,4,6]

Intraoperative assessment of decompression has rarely been reported. In 2005, Vilela *et al.*^[8] emphasized the usefulness of transcranial Doppler to evaluate decompression based on posterior cerebral artery velocities. In that study, dependable signals were only achieved in 3 of 5 patients. In 2007, Whitmore *et al.*^[9] reported the first case that portrayed the use of intraoperative Doppler ultrasonography directly on the vertebral artery in the surgical decompression of bow hunter's syndrome. This modality is noninvasive and has been applied effectively for evaluation of the carotid artery after carotid endarterectomy. In 2014, Anaizi *et al.*^[1] discussed the benefits of intraoperative fluorescent angiography to evaluate patency of the vertebral artery.

Ding *et al.*^[3] and Velat *et al.*^[7] described two prior instances where intraoperative dynamic angiography had been performed after surgical decompression. The modality offers the ability to image the affected arterial segment, as well as unexposed parts of the vessel; adequate decompression can be assessed, which optimizes the extent of the operation and reduces manipulation of the vertebral artery. However, the modality prompts risks associated with diagnostic cerebral angiography such as groin hematoma, thromboembolism formation, vessel dissection, and ischemic stroke. These risks are magnified for patients with known peripheral vascular disease.^[7] Further studies may be beneficial to evaluate whether intraoperative assessment, particularly with intraoperative angiography, may also reduce the rate associated with the persistence or recurrence of symptoms. According to the recent

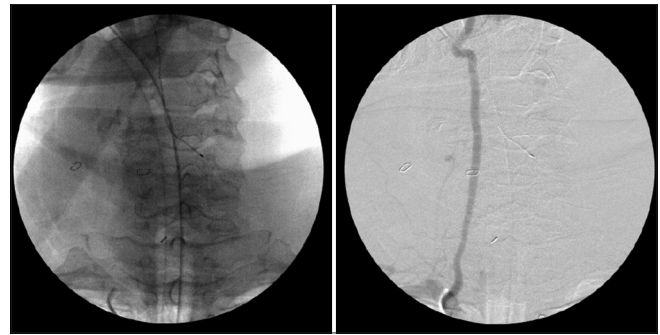


Figure 4: Intraoperative angiogram, right vertebral artery injection, with patient's head fully turned toward the right

review by Jost and Dailey,^[4] 13% of patients had either persistence or recurrence of symptoms after surgery. All patients underwent surgical decompression only; no patients with surgical fusion exhibited persistence or recurrence of symptoms. With a high rate of no improvement with decompression alone, it would be prudent to assess for whether the decompression has led to adequate improvement in flow when the neck is turned to the symptomatic side. Further decompression or even fusion might be warranted if there is still a lack of flow improvement demonstrated by intraoperative angiography. This ability to modify surgical managements based on intraoperative angiography findings should, in theory, avoid a second procedure had the angiography is not being done in the same setting. Minimizing the probability for a second procedure, which has its own set of risks, might counteract the risks involved with intraoperative dynamic angiography. A further large study comparing surgeries performed with and without intraoperative angiography is merited to elucidate the overall risks and benefits of utilizing intraoperative angiography for the treatment of bow hunter's syndrome.

CONCLUSION

The authors report the third instance where intraoperative dynamic angiography was employed with good outcomes. Noninvasive intraoperative modalities, including transcranial Doppler, Doppler ultrasonography directly on the vertebral artery, and fluorescent angiography have been discussed in the past. Although intraoperative cerebral angiography is an invasive procedure, which prompts additional risks, the authors believe the modality affords better, real-time visualization of the vertebral artery, allowing for assessment of the adequacy of the decompression. This advantage would guide further intraoperative surgical management of bow hunter's syndrome in one setting if needed, avoiding a second trip to operating room had the decompression found to be inadequate. Minimizing the probability for a second procedure, which has its own set of risks, might

counteract the risks involved with intraoperative dynamic angiography.

Financial support and sponsorship

Nil.

Conflicts of interest

There are no conflicts of interest.

REFERENCES

1. Anaizi AN, Sayah A, Berkowitz F, McGrail K. Bow hunter's syndrome: The use of dynamic magnetic resonance angiography and intraoperative fluorescent angiography. *J Neurosurg Spine* 2014;20:71-4.
2. Darkhabani MZ, Thompson MC, Lazzaro MA, Taqi MA, Zaidat OO. Vertebral artery stenting for the treatment of bow hunter's syndrome: Report of 4 cases. *J Stroke Cerebrovasc Dis* 2012;21:908.e1-5.
3. Ding D, Mehta GU, Medel R, Liu KC. Utility of intraoperative angiography during subaxial foramen transversarium decompression for bow hunter's syndrome. *Interv Neuroradiol* 2013;19:240-4.
4. Jost GF, Dailey AT. Bow hunter's syndrome revisited: 2 new cases and literature review of 124 cases. *Neurosurg Focus* 2015;38:E7.
5. Matsuyama T, Morimoto T, Sakaki T. Bow hunter's stroke caused by a nondominant vertebral artery occlusion: Case report. *Neurosurgery* 1997;41:1393-5.
6. Sugiu K, Agari T, Tokunaga K, Nishida A, Date I. Endovascular treatment for bow hunter's syndrome: Case report. *Minim Invasive Neurosurg* 2009;52:193-5.
7. Velat GJ, Reavey-Cantwell JF, Ulm AJ, Lewis SB. Intraoperative dynamic angiography to detect resolution of bow hunter's syndrome: Technical case report. *Surg Neurol* 2006;66:420-3.
8. Vilela MD, Goodkin R, Lundin DA, Newell DW. Rotational vertebrobasilar ischemia: Hemodynamic assessment and surgical treatment. *Neurosurgery* 2005;56:36-43.
9. Whitmore RG, Simon SL, Hurst RW, Nisenbaum HL, Kasner SE, Zager EL. Bow hunter's syndrome caused by accessory cervical ossification: Posterolateral decompression and the use of intraoperative Doppler ultrasonography. *Surg Neurol* 2007;67:169-71.