Surgical Neurology International

SNI: Cerebrovascular, a supplement to *Surgical Neurology International*

OPEN ACCESS

For entire Editorial Board visit : http://www.surgicalneurologyint.com

Editor: **James I. Ausman**, MD, PhD University of California, Los Angeles, CA, USA

Primary central nervous system vasculitis preceded by granulomatous hypophysitis: Case report with a review of the literature

Meng Huang, William J. Steele, David S. Baskin

Department of Neurosurgery, Kenneth R. Peak Brain and Pituitary Center, Houston Methodist Neurological Institute, Houston, TX, USA

E-mail: Meng Huang - Mhuang2@houstonmethodist.org; William J. Steele - wjsteele@houstonmethodist.org; *David S. Baskin - DBaskin@HoustonMethodist.org
*Corresponding author

Received: 09 January 15 Accepted: 29 June 15 Published: 28 September 15

Abstract

Background: Primary central nervous system (CNS) vasculitis is an idiopathic inflammatory process that selectively affects CNS vasculature without a systemic inflammatory response, and causes luminal obstruction with resultant ischemia of recipient tissue. Its varying clinical symptoms and signs depend on the caliber of vessels involved and distribution and location of the affected structures. Granulomatous hypophysitis (GH) is an autoimmune inflammatory process typically affecting women, and usually presents with hypopituitarism, and at times, diabetes insipidus, and/or visual loss. Both entities are rare CNS diseases, which, to our knowledge, have never been previously reported in the same patient.

Case Description: We present a unique case of chronic progressive primary CNS vasculitis causing limbic encephalopathy in a 30-year-old male with only a history of medication-controlled hypertension. He initially presented 4 months prior with nonspecific neurological complaints and was found to have a homogenously enhancing and enlarged pituitary, which was biopsy proven to be GH.

Conclusion: This rather unique presentation highlights the need to maintain a high index of suspicion for underlying PCNS vasculitis in a patient who does not fit the typical demographic for isolated GH.

Key Words: Central nervous system, hypophysitis, vasculitis, primary

Access this article online
Website: www.surgicalneurologyint.com
DOI: 10.4103/2152-7806.166176
Quick Response Code:

INTRODUCTION

Vasculitis is characterized by blood vessel inflammation that precipitates luminal occlusion and subsequent infarction. Clinical manifestations of vasculitis, which are often variable and nonspecific, depend on the caliber of affected vessel (s), the extent of local involvement, and the type of target organ (s). Vasculitis of the central nervous system (CNS) is most commonly secondary to a systemic process with collateral CNS involvement. Primary CNS vasculitis (PCNSV) is a poorly understood, rare, and complex disease with protean clinical manifestations that occurs in the absence of a systemic inflammatory process.[6,7,11,15,30,40,45]

Granulomatous hypophysitis (GH) is a rare autoimmune inflammatory disorder of the pituitary gland typically affecting middle-aged women, and may be a later manifestation of lymphocytic hypophysitis (LYH), which

This is an open access article distributed under the terms of the Creative Commons Attribution-NonCommercial-ShareAlike 3.0 License, which allows others to remix, tweak, and build upon the work non-commercially, as long as the author is credited and the new creations are licensed under the identical terms.

For reprints contact: reprints@medknow.com

How to cite this article: Huang M, Steele WJ, Baskin DS. Primary central nervous system vasculitis preceded by granulomatous hypophysitis: Case report with a review of the literature. Surg Neurol Int 2015;6:S407-13.
http://surgicalneurologyint.com/Primary-central-nervous-system-vasculitis-preceded-by-granulomatous-hypophysitis:-Case-report-with-a-review-of-the-literature/

usually affects younger peripartum females. The cases of GH and LYH involving nonpregnant women and men have been reported. Clinically, both conditions can involve the anterior and posterior pituitary, which can clinically manifest with their respective endocrine dysfunction syndromes.[1,4,5,20,23,28,32,34,35,37,48]

We present a unique case of progressive PCNSV causing limbic encephalopathy in a 29-year-old male who initially presented with isolated GH. The case is also of interest because it mimicked herpes encephalitis both clinically and radiologically.

CASE REPORT

A 29-year-old male initially presented to an otolaryngologist's office for evaluation of the acute onset of left-sided hearing loss. His past medical history was significant only for obesity with a body mass index 34, hypertension, and presumptive shingles on his left flank treated with valacyclovir, although no exanthema had ever appeared. He endorsed occasional alcohol but no smoking or illicit drug usage. The patient reported a 2 weeks history of headache, nausea, and vomiting was accompanied by photophobia. He had been to an emergency room, and anti-nausea and pain medications had been prescribed. While at the office, he received a local steroid injection, which provided no resolution of his symptoms. A subsequent magnetic resonance imaging (MRI) obtained at that time showed a diffusely enhancing and enlarged pituitary gland [Figure 1].

The patient was seen in the clinic by senior author and was subsequently admitted for transsphenoidal exploration and biopsy of the pituitary mass. Hormonal testing at that time was significant for thyroid-stimulating hormone level of 0.01 uIU/ml, luteinizing hormone of 0.8 mIU/ml, testosterone < 3, insulin-like growth factor-1 of 319, dehydroepiandrosterone at 13.2 ug/dl. The patient tolerated the procedure well, and intraoperative frozen pathology showed rubbery anterior pituitary gland with diffuse lymphocytic infiltration consistent with lymphocytic adenophypophysitis.

The final pathology, however, was interpreted to represent GH. Special stains for microorganisms were negative. Microscopically, cytologic preparations adenosine triphosphate showed predominantly blood with scattered lymphocytes and macrophages. Frozen (AFS) and permanent sections showed a pituitary gland with marked noncaseating granulomatous inflammation and diffused lymphocytic infiltrate. Immunostains such as CD68 confirmed the presence of histiocytes and CD3 and CD20 immunostains showed the lymphocytes to be a reactive population. Cytokeratin immunostains highlighted the pituitary gland and the intact acinar architecture in the background of inflammation. Special stains for fungal Gomori methenamine silver (GMS), bacterial (gram), and mycobacterial (Fite) organisms were negative. Cerebrospinal fluid (CSF) analysis was negative for malignancy, and immunohistochemical staining for herpes simplex virus (HSV1–2) was negative. The patient was discharged on postoperative day 1 neurologically intact and prescribed thyroid, testosterone, and pulsed high-dose oral steroid regimen. The patient's condition improved, and a subsequent MRI scan showed a decrease in size of pituitary back to a more normal configuration [Figure 2].

Approximately, 3 months after discharge, the patient developed fatigue, malaise, and progressive short-term memory deficits that progressed rapidly over a course of 2 weeks. He retained his remote memory and was able to recall name, birthday, and president without difficulty.

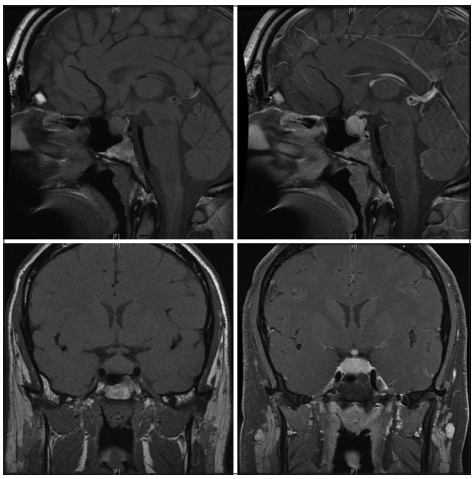

Figure 1: Pre- and post-contrast magnetic resonance images show the pituitary to be diffusely enlarged with homogenous enhancement, measuring 1.3 cm × 2.0 cm × 1.1 cm in cranial-caudal, transverse, and anterior-posterior dimensions, respectively. The pituitary stalk is markedly thickened and intensely enhancing

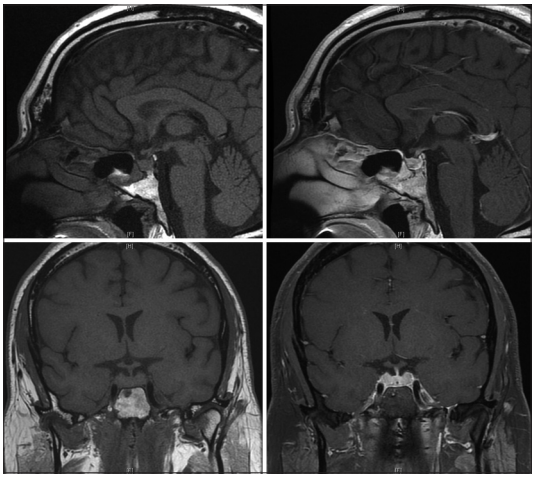

Figure 2: Magnetic resonance images obtained 1-month after surgery made with and without contrast show a decrease in size of the pituitary gland with no suprasellar extension or abnormal enhancement pattern

There was no fever, weight loss, chills, vision changes, slurred speech, facial droop, weakness, numbness, issues with gait, or other focal deficits except for his prior hearing loss in his left ear. He was tapering his steroid medications. The patient was readmitted to the hospital for concern of HSV encephalitis. MRI showed T2 signal changes, as well as bilateral contrast enhancement, in the medial temporal lobes [Figure 3].

A lumbar puncture was performed, which was negative for an infectious etiology including routine, acid-fast bacilli (AFB), and fungal cultures, cryptococcus antigen, HSV 1,2, HIV 1,2, Epstein–Barr virus (EBV), *West Nile*, venereal disease research laboratory, varizella zoster, and *Borrelia burgdorferi*. Flow cytometry showed no clonal B cells [Table 1].

Fifty percent of the cell populations were T cells by CD5 immunotyping, 8% mature B cells, with no light chain restriction or significant co-expression of CD5 or CD10, and <1% plasma cells. CSF analysis is described in Table 1 and suggested a mild disruption of the blood brain barrier.

Additional labs performed at that time included B2 microglobulin 1.0, angiotensin converting enzyme <5. The patient was placed on intravenous (IV) acyclovir, broad-spectrum antibiotics, and steroids. Clinically, the patient improved dramatically over the next several days with a resolution of his malaise and headaches, as well as his encephalopathy. On examination, he was oriented × 3 and able to follow complex commands. The laboratory tests for signs of autoimmune disease were all negative, as indicated in Table 2.

A repeat lumbar puncture performed 5 days later revealed slight improvement in CNS inflammation. Repeat testing through PCR, ELISA, and culture for HSV 1 and 2 remained negative. Repeat imaging showed unchanged T2 hyperintensities in bilateral temporal lobes with improvement in the enhancement pattern of the left temporal lobe [Figure 4]. The patient was discharged on IV acyclovir and a steroid taper.

The patient's clinical improvement did not last and approximately 1-week after discharge his short-term

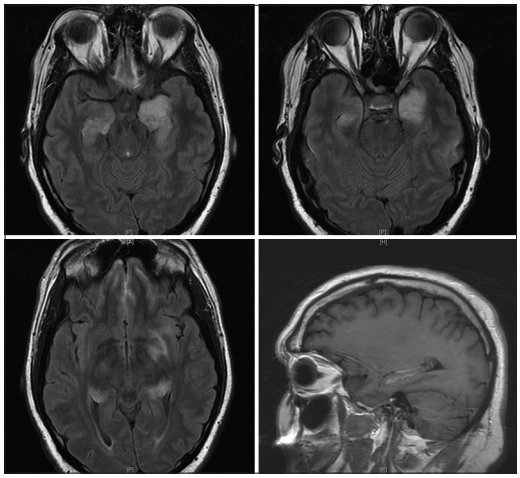

Figure 3: Axial T2 flair magnetic resonance images demonstrating hyperintensity in the bilateral mesial temporal lobes left greater than right, as well as contrast enhancement, in right mesial temporal lobe on sagittal section

Table 1: CSF analysis on admission 2 weeks after the onset of anterograde amnesia. The only findings were consistent with a slight disruption of the blood brain barrier

WBC	21 (94% lymphocytes)
RBC	378
Glucose	56
Protein	88
Prealbumin	2.3
Alpha 1	2.1
Alpha 2	8.6
Beta	12.0
Gamma	9.5
G/A ratio	0.16
IgG index	0.84
IgG synthesis rate	21.20
Q/albumin ratio, CSF	12.74
IgG, CSF	8.90
Albumin, CSF	57.2
IgG, serum	831
Albumin, electrophoresis	4490

CSF: Cerebrospinal fluid, WBC: White blood cell, RBC: Red blood cell

Table 2: Laboratory tests for signs of autoimmune disease, systemic inflammation were negative

ANA	Not detected
p-ANCA	<20
c-ANCA	<20
CRP	0.51
ESR	9
N-methyl-D-aspartate receptor antibody	<1.10
SSA antibody enzyme	1.39, negative
SSB antibody enzyme	0.55, negative
Scleroderma (Scl-70)	0
Anti-neuronal nuclear antibody type 1-3	Not detected
Anti-glial nuclear antibody type 1	Not detected
Purkinje cell cytoplasmic antibody 1, 2	Not detected
Amphiphysin	Not detected
CRMPs-IgG	Not detected
Striatal muscle antibody	Not detected
P/Q type calcium channel antibody	Not detected
N-type calcium channel antibody	Not detected
Ach receptor muscle binding antibody	Not detected
Ach receptor ganglionic neuronal antibody	Not detected
Neuronal K channel antibody	Not detected

CRP: C-reactive protein, ANA: Antinuclear antibody, p-ANCA: Perinuclear anti-neutrophil cytoplasmic antibodies, c-ANCA: Cytoplasmic anti-neutrophil cytoplasmic antibodies, ESR: Erythrocyte sedimentation rate, CRMPs: Collapsin response mediator proteins

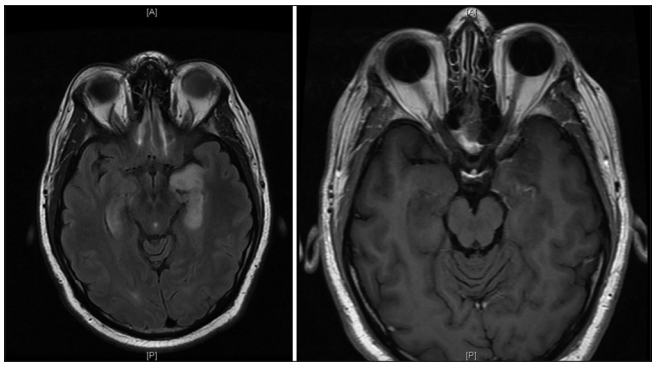

Figure 4: Axial magnetic resonance T2 flair image on the left and postcontrast T1 image on the right showing interval improvement in enhancement pattern with stable hyperintensity of bilateral mesial temporal lobes

memory loss returned and he remained unable to store new memories. He completed his antibiotic course and outpatient follow-up visits over the next 2 months revealed no improvement in his symptomatology. Given the patient's poor quality of life and the absence of diagnosis despite exhaustive testing, the patient was readmitted for right temporal craniotomy and biopsy to establish a tissue diagnosis. Examination at that time was significant for inability to recall items moments after they were told to him. He was awake, alert and oriented to person, place, and time. No focal deficits were noted. A new preoperative MRI showed interval progression of T2 signal abnormality and enhancement of the bilateral temporal lobes with increased mass effect [Figure 5]. The pituitary gland remained stable.

The patient tolerated the procedure well. The neurology and rheumatology services saw the patient. He was placed on steroids. Flow cytometry of the biopsy revealed 73% T-cells, 3% mature B-cells with no light chain restriction or significant co-expression of CD5, CD10. Repeat CSF analysis revealed worsening of the inflammatory response and breakdown of the blood-brain barrier [Table 3].

The final histology revealed transmural and perivascular noncaseating granulomatous vasculitis. Focal vessels showed thickening and hyalinization but were negative for amyloid. No vascular fibrinoid necrosis was seen as would be typical for polyarteritis nodosa, or rheumatoid or lupus vasculitis. Special stains for AFB (Fite), bacteria (gram), and fungus (GMS) were negative.

Immunohistochemical stains for the varicella-zoster virus, Herpes 1 and 2, cytomegalovirus, adenovirus, human herpesvirus 8, EBV, toxoplasma, amyloid were all negative. Repeat testing of autoimmune and infectious etiologies remained negative. Additional studies of paraneoplastic markers were negative including carbohydrate antigen 19–9, CEA, and alpha-FP. Heavy metal screen for lead, arsenic, and mercury all came back below detectable limits. A positron emission tomography scan of the brain showed hypermetabolism of temporal lobes and hippocampal gyri consistent with limbic encephalitis. The patient was discharged with steroids and cyclophosphamide, with persistent anterograde amnesia and a diagnosis of limbic encephalitis secondary to primary CNS vasculitis.

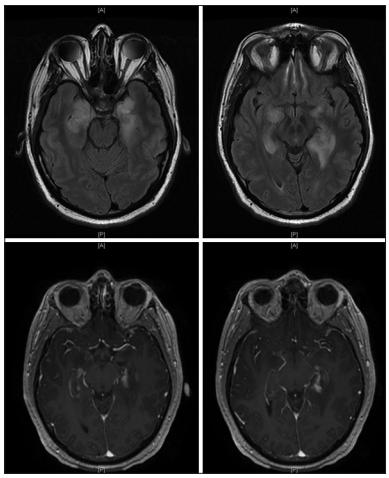

Figure 5: Preoperative magnetic resonance images 2 months after discharge. T2 signal changes and contrast enhancement pattern has increased, since the last magnetic resonance imaging scan

Table 3: CSF analysis on admission 2 months after anterograde amnesia onset, which indicates worsening of inflammation and disruption of the blood-brain barrier

WBC	98 (90% lymphocytes)
RBC	90
Glucose	68
Protein	108
G/A ratio	0.26
IgG index	1.61
IgG synthesis rate	50.86
Q/albumin ratio, CSF	13.94
IgG, CSF	14.00
Albumin, CSF	54.80
IgG, serum	625
Albumin, electrophoresis	3930

CSF: Cerebrospinal fluid, WBC: White blood cell, RBC: Red blood cell

He was treated as an outpatient with IV cyclophosphamide and high dose steroids. Follow-up imaging has shown improvement in both the T2 signal abnormality and contrast enhancement pattern [Figure 6]. There has been no improvement clinically.

DISCUSSION

Primary CNS vasculitis has an estimated incidence rate of 1–2.4 cases per 1 million.[6,10,15,40] The age of onset is between 40 and 60 years old in 50% of cases. Women are affected slightly more frequently than men.[15,30,44] Unfortunately, the pathogenesis of PCNSV is poorly understood, and no strong support exists for any potential etiological associations.[15]

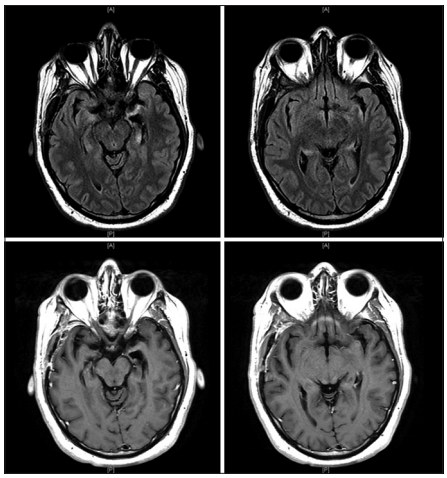

Figure 6: Axial magnetic resonance T2 (top) and T1 postcontrast (bottom) images taken 3 months after discharge after treatment with cyclophosphamide and prednisone showing improvement in both signal abnormality and contrast enhancement

The clinical manifestations of PCNSV are diverse and nonspecific, and onset can be abrupt, but the course is generally gradual and progressive though in rare cases it can be fulminant.[6,8,15,19,22,40,41,45,46] Neurologic symptoms in a 131 patients series include in order of decreasing frequency, headache, cognitive deficits, visual deficits (field cut, diplopia, blurred or decreased acuity, papilledema), hemiparesis, transient ischemic attack or cerebrovascular accident, ataxia, seizure, intracerebral hemorrhage, and amnestic syndrome.[15,40] The spinal cord can be involved as well and in approximately 5% of reported cases and results in a typical progressive myelopathy.[39]

Diagnostic laboratory analysis for nonspecific elevated acute phase reactants, ANA, and complement abnormalities, as well as specific markers, such as cytoplasmic anti-neutrophil cytoplasmic antibodies (c-ANCA), perinuclear ANCA (ANCA), and cryoglobulin immune complexes are negative.[5,6,8,11,40,45] CSF examination shows elevated white blood cell and protein in the majority of patients and occasionally oligoclonal banding.[6,15] Other secondary causes of vasculitis such as systemic lupus erythematosus, Sjogren's disease, infections, neoplasm, and drugs are not present.[7,11,15,40,45]

Radiographic analysis with MRI shows abnormalities in the majority of patients. Ischemic changes with diffusion restriction are seen in 50–75% of cases.[6,8,15,27,40,43,49] Contrast enhancing lesions resembling tumor are seen in 33% of cases.[6,15,22,27,40,46] Conventional digital subtraction angiography is the gold standard imaging modality due to the low sensitivity of magnetic resonance angiography for medium to small vessel disease.[3,11,16,45] Angiographic findings that support PCNSV include alternating segments of stenosis and normal or dilated segments (often referred to as "beading") and intracranial arterial occlusions, especially if the changes are bilateral and in multiple arteries. Nonetheless, studies have shown an angiographic false negative rate of 30–40% in histology proven cases.[11,16,45]

A brain biopsy is required for tissue histopathologic confirmation of PCNSV although the yield is reported at only 50–70% due to the focal segmental nature of the disease.[2,6,15,22,33,40]

Hypophysitis is a rare pituitary inflammatory disorder with an incidence of 1 in 9 million.[9,20] Young females are more often affected, and clinical manifestation is a result of local inflammation and mass effect, as well as endocrine dysfunction. With mass effect and dural irritation, headache, and visual impairment have been reported in up to 50–70% of cases. Bitemporal hemianopsia accounts for the majority of visual symptoms, with impaired acuity and diplopia being relatively uncommon. Endocrine dysfunction has been reported in up to 80% of cases. Endocrinologic dysfunction is referable to the lobe (s) of the pituitary that is, affected.[4,5,12,13,17,18,21,26,29,35,36,48]

MRI can reveal marked homogeneous enhancement, symmetric enlargement, and dural enhancement.[29,38] Diffuse thickening of the infundibulum with or without contrast enhancement is seen with posterior involvement.[24,36]

Hypophyseal biopsy, in the absence of features of fungus, tuberculosis, and sarcoidosis, is histologically subdivided into three pathologic subtypes: Lymphocytic, granulomatous, and xanthomatous with lymphocytic being the most common.[12,14,20,42,47] The primary GH is characterized by lymphocyte, macrophage, and plasma cell infiltration along with the defining presence of multinucleated giant cells. The primary LYH is characterized by diffuse polyclonal lymphocytic infiltration with CD4 predominant T cells in the absence of systemic inflammatory disease.[1,21,28,31,36]

Despite the distinction between the two conditions, controversy exists over whether they are truly disparate. The early observation suggested the possibility of a spectrum of progression starting with LYH and progressing to GH.[25] In contrast, other authors cited key epidemiological factors of LYH that were not found in GH including female bias, association with pregnancy, occasional spontaneous resolution, and association with established autoimmune disease.[12] Based on a more recent review of all published case series of GH, however, the majority of cases of GH do indeed have a predilection for females. Furthermore, the average age at presentation is approximately 8 years older than the average age of presentation for LYH. This supports the theory of GH as a progressive form of LYH.[20]

Our case was unusual and challenging diagnostically because the initial manifestation of PCNSV was the

isolated finding of GH, initially thought to be LYH on frozen section. This uncharacteristically presented in an otherwise previously healthy young male. The clinical course and radiographic appearance of what is now known as the progression of disease initially mimicked herpes encephalitis. A lesson learned is always to consider CNS vasculitis in the differential diagnosis of enhancing CNS lesions in the temporal lobe, particularly when CSF Herpes polymerase chain reaction studies are negative.

The occurrence of GH preceding the onset of primary CNS vasculitis in a previously healthy male is highly unusual and has never before been reported in the literature. Perhaps this suggests an underlying and unifying autoimmune etiology for both GH and PCNSV with a common target found in both hypophyseal and vascular tissue.

Acknowledgement

This work was supported in part by the Donna and Kenneth R. Peak Foundation, The Kenneth R. Peak Brain and Pituitary Center at Houston Methodist Hospital, The Taub Foundation, The Blanche Green Estate Fund of the Pauline Sterne Wolff Memorial Foundation, The Veralan Foundation, The Methodist Hospital Foundation, The American Brain Tumor Association, and by many patients and families who have been impacted by the devastating effects of brain tumors and other diseases of the central nervous system.

Financial support and sponsorship

This work was supported in part by the Donna and Kenneth R. Peak Foundation, The Kenneth R. Peak Brain and Pituitary Center at Houston Methodist Hospital, The Taub Foundation, The Blanche Green Estate Fund of the Pauline Sterne Wolff Memorial Foundation, The Veralan Foundation, The Methodist Hospital Foundation, The American Brain Tumor Association.

Conflicts of interest

There are no conflicts of interest.

REFERENCES

1. Abe T, Matsumoto K, Sanno N, Osamura Y. Lymphocytic hypophysitis: Case report. Neurosurgery 1995;36:1016-9.
2. Alrawi A, Trobe JD, Blaivas M, Musch DC. Brain biopsy in primary angiitis of the central nervous system. Neurology 1999;53:858-60.
3. Atalay MK, Bluemke DA. Magnetic resonance imaging of large vessel vasculitis. Curr Opin Rheumatol 2001;13:41-7.
4. Bellastella A, Bizzarro A, Coronella C, Bellastella G, Sinisi AA, De Bellis A. Lymphocytic hypophysitis: A rare or underestimated disease? Eur J Endocrinol 2003;149:363-76.
5. Beressi N, Beressi JP, Cohen R, Modigliani E. Lymphocytic hypophysitis. A review of 145 cases. Ann Med Interne (Paris) 1999;150:327-41.
6. Berlit P, Kraemer M. Cerebral vasculitis in adults: What are the steps in order to establish the diagnosis? Red flags and pitfalls. Clin Exp Immunol 2014;175:419-24.
7. Berlit P. Diagnosis and treatment of cerebral vasculitis. Ther Adv Neurol Disord 2010;3:29-42.
8. Birnbaum J, Hellmann DB. Primary angiitis of the central nervous system. Arch Neurol 2009;66:704-9.
9. Buxton N, Robertson I. Lymphocytic and granulocytic hypophysitis: A single centre experience. Br J Neurosurg 2001;15:242-5.
10. Calabrese LH, Dodick DW, Schwedt TJ, Singhal AB. Narrative review: Reversible cerebral vasoconstriction syndromes. Ann Intern Med 2007;146:34-44.
11. Calabrese LH, Mallek JA. Primary angiitis of the central nervous system. Report of 8 new cases, review of the literature, and proposal for diagnostic criteria. Medicine (Baltimore) 1988;67:20-39.
12. Caturegli P, Newschaffer C, Olivi A, Pomper MG, Burger PC, Rose NR. Autoimmune hypophysitis. Endocr Rev 2005;26:599-614.
13. Cebelin MS, Velasco ME, de las Mulas JM, Druet RL. Galactorrhea associated with lymphocytic adenohypophysitis. Case report. Br J Obstet Gynaecol 1981;88:675-80.
14. Folkerth RD, Price DL Jr, Schwartz M, Black PM, De Girolami U. Xanthomatous hypophysitis. Am J Surg Pathol 1998;22:736-41.
15. Giannini C, Salvarani C, Hunder G, Brown RD. Primary central nervous system vasculitis: Pathology and mechanisms. Acta Neuropathol 2012;123:759-72.
16. Hankey G. Isolated angiitis/angiopathy of the CNS. Prospective diagnostic and therapeutic experience. Cerebrovasc Dis 1991;1:2-15.
17. Hashimoto K, Takao T, Makino S. Lymphocytic adenohypophysitis and lymphocytic infundibuloneurohypophysitis. Endocr J 1997;44:1-10.
18. Heinze HJ, Bercu BB. Acquired hypophysitis in adolescence. J Pediatr Endocrinol Metab 1997;10:315-21.
19. Hunder GG, Salvarani C, Brown RD Jr. Primary central nervous system vasculitis: Is it a single disease? Ann Neurol 2010;68:573-4.
20. Hunn BH, Martin WG, Simpson S Jr, Mclean CA. Idiopathic granulomatous hypophysitis: A systematic review of 82 cases in the literature. Pituitary 2014;17:357-65.
21. Imura H, Nakao K, Shimatsu A, Ogawa Y, Sando T, Fujisawa I, *et al.* Lymphocytic infundibuloneurohypophysitis as a cause of central diabetes insipidus. N Engl J Med 1993;329:683-9.
22. Kraemer M, Berlit P. Primary central nervous system vasculitis: Clinical experiences with 21 new European cases. Rheumatol Int 2011;31:463-72.
23. Lee JH, Laws ER Jr, Guthrie BL, Dina TS, Nochomovitz LE. Lymphocytic hypophysitis: Occurrence in two men. Neurosurgery 1994;34:159-62.
24. Leggett DA, Hill PT, Anderson RJ. 'Stalkitis' in a pregnant 32-year-old woman: A rare cause of diabetes insipidus. Australas Radiol 1999;43:104-7.
25. Ludmerer K, Kissane J. Primary hypothyroidism and hypopituitarism in a young woman. Am J Med 1984;77:319.
26. Lury KM. Inflammatory and infectious processes involving the pituitary gland. Top Magn Reson Imaging 2005;16:301-6.
27. Mandell DM, Matouk CC, Farb RI, Krings T, Agid R, terBrugge K, *et al.* Vessel wall MRI to differentiate between reversible cerebral vasoconstriction syndrome and central nervous system vasculitis: Preliminary results. Stroke 2012;43:860-2.
28. McCutcheon IE, Oldfield EH. Lymphocytic adenohypophysitis presenting as infertility. Case report. J Neurosurg 1991;74:821-6.
29. Molitch ME, Gillam MP. Lymphocytic hypophysitis. Horm Res 2007;68 Suppl 5:145-50.
30. Moore PM. Vasculitis of the central nervous system. Curr Rheumatol Rep 2000;2:376-82.
31. Nishioka H, Ito H, Sano T, Ito Y. Two cases of lymphocytic hypophysitis presenting with diabetes insipidus: A variant of lymphocytic infundibulo-neurohypophysitis. Surg Neurol 1996;46:285-90.
32. Paja M, Estrada J, Ojeda A, Ramón y Cajal S, García-Uría J, Lucas T. Lymphocytic hypophysitis causing hypopituitarism and diabetes insipidus, and associated with autoimmune thyroiditis, in a non-pregnant woman. Postgrad Med J 1994;70:220-4.
33. Parisi JE, Moore PM. The role of biopsy in vasculitis of the central nervous system. Semin Neurol 1994;14:341-8.
34. Pestell RG, Best JD, Alford FP. Lymphocytic hypophysitis. The clinical spectrum of the disorder and evidence for an autoimmune pathogenesis. Clin Endocrinol (Oxf) 1990;33:457-66.
35. Portocarrero CJ, Robinson AG, Taylor AL, Klein I. Lymphoid hypophysitis. An unusual cause of hyperprolactinemia and enlarged sella turcica. JAMA 1981;246:1811-2.
36. Rivera JA. Lymphocytic hypophysitis: Disease spectrum and approach to diagnosis and therapy. Pituitary 2006;9:35-45.
37. Rumana M, Kirmani A, Khursheed N, Besina S, Khalil M. Lymphocytic

hypophysitis with normal pituitary function mimicking a pituitary adenoma: A case report and review of literature. Clin Neuropathol 2010;29:26-31.
38. Saiwai S, Inoue Y, Ishihara T, Matsumoto S, Nemoto Y, Tashiro T, *et al.* Lymphocytic adenohypophysitis: Skull radiographs and MRI. Neuroradiology 1998;40:114-20.
39. Salvarani C, Brown RD Jr, Calamia KT, Christianson TJ, Huston J 3rd, Meschia JF, *et al.* Primary CNS vasculitis with spinal cord involvement. Neurology 2008;70 (24 Pt 2):2394-400.
40. Salvarani C, Brown RD Jr, Calamia KT, Christianson TJ, Weigand SD, Miller DV, *et al.* Primary central nervous system vasculitis: Analysis of 101 patients. Ann Neurol 2007;62:442-51.
41. Salvarani C, Brown RD Jr, Morris JM, Huston J 3rd, Hunder GG. Catastrophic primary central nervous system vasculitis. Clin Exp Rheumatol 2014;32:S3-4.
42. Sautner D, Saeger W, Lüdecke DK, Jansen V, Puchner MJ. Hypophysitis in surgical and autoptical specimens. Acta Neuropathol 1995;90:637-44.
43. Scolding N. Can diffusion-weighted imaging improve the diagnosis of CNS vasculitis? Nat Clin Pract Neurol 2007;3:608-9.
44. Scolding NJ, Jayne DR, Zajicek JP, Meyer PA, Wraight EP, Lockwood CM. Cerebral vasculitis – Recognition, diagnosis and management. QJM 1997;90:61-73.
45. Scolding NJ. Central nervous system vasculitis. Semin Immunopathol 2009;31:527-36.
46. Tanei T, Nakahara N, Takebayashi S, Ito M, Hashizume Y, Wakabayashi T. Primary angiitis of the central nervous system mimicking tumor-like lesion – case report. Neurol Med Chir (Tokyo) 2011;51:56-9.
47. Tashiro T, Sano T, Xu B, Wakatsuki S, Kagawa N, Nishioka H, *et al.* Spectrum of different types of hypophysitis: A clinicopathologic study of hypophysitis in 31 cases. Endocr Pathol 2002;13:183-95.
48. Thodou E, Asa SL, Kontogeorgos G, Kovacs K, Horvath E, Ezzat S. Clinical case seminar: Lymphocytic hypophysitis: Clinicopathological findings. J Clin Endocrinol Metab 1995;80:2302-11.
49. Zuccoli G, Pipitone N, Haldipur A, Brown RD Jr, Hunder G, Salvarani C. Imaging findings in primary central nervous system vasculitis. Clin Exp Rheumatol 2011;29 1 Suppl 64:S104-9.