

Treatment of low back pain in patients with vertebral compression fractures and superior cluneal nerve entrapment neuropathies

Kyongsong Kim, Toyohiko Isu¹, Yasuhiro Chiba¹, Naotaka Iwamoto¹, Kazuyoshi Yamazaki¹, Daijiro Morimoto², Masanori Isobe¹, Kiyoharu Inoue³

Department of Neurosurgery, Chiba Hokuso Hospital, Nippon Medical School, Inzai, Chiba, ¹Department of Neurosurgery, Kushiro Rosai Hospital, Kushiro, Hokkaido, ²Department of Neurosurgery, Nippon Medical School, Tokyo, ³Department of Neurology, Sapporo Yamanoue Hospital, Spporo, Hokkaido, Japan

E-mail: *Kyongsong Kim - kyongson@nms.ac.jp; Toyohiko Isu - tqa00131@nifty.com; Yasuhiro Chiba - chibay511@hotmail.com; Naotaka Iwamoto - 4649nao-iwamoto@nms.ac.jp; Kazuyoshi Yamazaki - mt.kazu71@gmail.com; Daijiro Morimoto - daijiro@nms.ac.jp; Masanori Isobe - m-isobe@rio.odn.ne.jp; Kiyoharu Inoue - inovyeq@ric.hi-ho.ne.jp

*Corresponding author

Received: 14 August 15 Accepted: 24 September 15 Published: 25 November 15

Abstract

Background: Superior cluneal nerve entrapment neuropathy (SCN-EN) may contribute to low back pain (LBP). However, it is often misdiagnosed as lumbar spine disorder and poorly understood.

Methods: Between April 2012 and September 2013, we treated 27 patients (3 men, 24 women; mean age 75.0 years) with LBP due to SCN-EN elicited by vertebral compression fractures. Symptoms were unilateral in 4 patients and bilateral in 23 patients. The interval between symptom onset and treatment averaged 10.8 months; the mean postoperative follow-up period was 19.0 months. The clinical outcomes were assessed utilizing the numeric rating scale (NRS) for LBP, the Japanese Orthopedic Association (JOA) score, and the Roland–Morris Disability Questionnaire (RDQ) before and after treatment (e.g., until the latest follow-up).

Results: LBP in 17 patients was immediately improved by SCN block only. The remaining 10 patients required surgery (involving 18 sites) as SCN blocks were only transiently effective. Operative intervention resulted in the immediate and continued improvement of their LBP. Notably, their NRS decreased from 7.4 to 1.5, their RDQ scores from 19.6 to 7.0, and their JOA scores increased from 10.7 to 20.3.

Conclusions: In this series, 27 patients with LBP due to SCN-EN responded either to SCN blocks (17 patients) or surgical release of SCN entrapment (10 patients at 18 sites).

Key Words: Entrapment neuropathy, less invasive, low back pain, neurolysis, superior cluneal nerve, vertebral compression fracture

Access this article online

Website:

www.surgicalneurologyint.com

DOI:

10.4103/2152-7806.170455

Quick Response Code:



INTRODUCTION

Superior cluneal nerve entrapment neuropathy (SCN-EN) may contribute to low back pain (LBP) involving the iliac crest and buttocks.^[1,2,4,5] LBP due to SCN-EN is exacerbated by lumbar movement and can be easily misdiagnosed as a lumbar spine disorder. Here, we report our nerve block or surgical treatment results of SCN-EN contributing to LBP in 27 patients.

This is an open access article distributed under the terms of the Creative Commons Attribution-NonCommercial-ShareAlike 3.0 License, which allows others to remix, tweak, and build upon the work non-commercially, as long as the author is credited and the new creations are licensed under the identical terms.

For reprints contact: reprints@medknow.com

How to cite this article: Kim K, Isu T, Chiba Y, Iwamoto N, Yamazaki K, Morimoto D, et al. Treatment of low back pain in patients with vertebral compression fractures and superior cluneal nerve entrapment neuropathies. *Surg Neurol Int* 2015;6:S619-21. <http://surgicalneurologyint.com/Treatment-of-low-back-pain-in-patients-with-vertebral-compression-fractures-and-superior-cluneal-nerve-entrapment-neuropathies/>

MATERIALS AND METHODS

Between April 2012 and September 2013, we treated 27 LBP patients with SCN-EN and vertebral compression fractures (VCFs), it was induced by the movement such as rolling, standing, or walking [Table 1]. Acute-onset LBP due to VCF was reported by 23 patients (85.2%), in 6 VCF was due to trauma. The other four reported neither acute-onset pain nor trauma, their LBP increased gradually. On admission, radiological findings showed fresh VCF in 22 patients. During follow-up, all VCFs were cured under observation therapy, and there was no instability of the vertebra; 5 patients suffered new VCF.

Surgical procedure for superior cluneal nerve entrapment neuropathy

We performed microsurgical release for SCN-EN entrapment in the prone position in 10 patients (at 18 sites). First, a 5-cm-long skin incision was made across the trigger point on the iliac crest; this allowed for identification of the SCN nerve (e.g., located on the fat overlying the subcutaneous compartment) [Figure 1a]. The thoracolumbar fascia was incised to free the SCN of kinks; this maneuver decompressed the SCN both rostrally and distally [Figure 1b-d]. Where manual direct compression of the SCN failed to elicit radiating pain (e.g., involving the local trigger point on the iliac crest), it suggested entrapment of other SCNs that were also decompressed (e.g., the 11–18th sites). Treatment was considered complete when the radiating pain

disappeared upon manual direct compression on the iliac crest. Postoperatively, the patients' movements were not restricted.

RESULTS

We first performed repetitive SCN block; in 17 patients this produced pain reduction. The senior author (T.I.) operated 18 sites in 10 patients because pain alleviation was transient. One operated patient suffered LBP recurrence and underwent re-operation to address other SCNs. There were no surgical complications. SCN-EN treatment led to significant LBP improvement [Table 1].

DISCUSSION

In some patients with VCF, LBP is not adequately controlled by conservative measures and pain control medications may be poorly tolerated. Our experience suggests that in some patients SCN-EN contributes to LBP after VCF. Entrapment and irritation of the SCN at the orifice where it penetrates the thoracolumbar fascia produces LBP, and 1.6–12.0% of LBP has been reported to be due to SCN-EN.^[1-5] This type of LBP is exacerbated by lumbar movement and tends to be wrongly attributed to lumbar spine disorder. Of our 27 patients, 11 responded to SCN-EN treatment in the chronic phase of VCF; in 17 SCN block only was effective. When nerve block is only transiently effective, SCN-EN should be considered and neurolysis of the SCN under local anesthesia may be curative. A diagnosis of SCN-EN cannot be obtained based on radiological findings alone and occult SCN-EN must be ruled out in patients with VCF suffering treatment-resistant LBP.

Table 1: Summary of the 27 patients

Observation	Results
Gender	3 males/24 females
Age	Mean 75.0 years (57-89 years)
Affected side	Unilateral in 4/bilateral in 23 (50 sites)
Number of VCF	11 patients with 1-, 3 with 3-, 13 with more than 3 fractures
Location of pain	Unilateral LBP involving the iliac crest and buttocks
Trigger point	
Location	Over the posterior iliac crest located 7 cm from the midline
Symptoms	Numbness and radiating pain in the SCN area
Block at this point (SCN block)	Symptom relief in more than 75% by local anesthesia
Interval between symptom onset and treatment	Average 10.8 months (1 day-48 months)
Follow-up period	Mean 19.3 months (9-30 months)
Results of SCN-EN treatment (pretreatment to last follow-up)	NRS of LBP: 7.4 ± 2.1 to 1.5 ± 1.6 RDQ score: 19.6 ± 3.9 to 7.0 ± 5.4

SCN: Superior cluneal nerve, SCN-EN: SCN entrapment neuropathy, VCF: Vertebral compression fracture, NRS: Numeric rating scale, LBP: Low back pain, JOA: Japanese Orthopedic Association, RDQ: Roland-Morris Disability Questionnaire

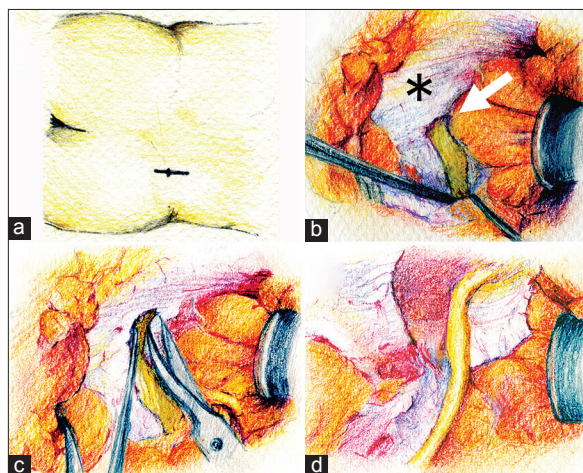


Figure 1: (a) A 5-cm-long skin incision is made across the trigger point on the iliac crest. (b) The superior cluneal nerve penetrates the thoracolumbar fascia (*) through the orifice (arrow) just before crossing over the iliac crest. (c) The orifice of the thoracolumbar fascia is opened and released by sharp dissection with microscissors along the superior cluneal nerve. (d) The superior cluneal nerve is decompressed and mobilized

CONCLUSIONS

We report 27 patients with VCF and LBP attributable to SCN-EN. They experienced pain abatement by SCN block or surgical release of the SCN entrapment. We suggest that SCN-EN should be considered and addressed in patients with VCF resulting in LBP.

Financial support and sponsorship

Nil.

Conflicts of interest

There are no conflicts of interest.

REFERENCES

1. Chiba Y, Isu T, Kim K, Iwamoto N, Morimoto D, Yamazaki K, *et al*. Intermittent low back pain attributable to superior cluneal nerve entrapment neuropathy. *J Neurosurg Spine*. [In Press].
2. Kim K, Isu T, Chiba Y, Morimoto D, Ohtsubo S, Kusano M, *et al*. The usefulness of ICG video angiography in the surgical treatment of superior cluneal nerve entrapment neuropathy: Technical note. *J Neurosurg Spine* 2013;19:624-8.
3. Kuniya H, Aota Y, Saito T, Kamiya Y, Funakoshi K, Terayama H, *et al*. Anatomical study of superior cluneal nerve entrapment. *J Neurosurg Spine* 2013;19:76-80.
4. Maigne JY, Doursounian L. Entrapment neuropathy of the medial superior cluneal nerve. Nineteen cases surgically treated, with a minimum of 2 years' follow-up. *Spine (Phila Pa 1976)* 1997;22:1156-9.
5. Morimoto D, Isu T, Kim K, Imai T, Yamazaki K, Matsumoto R, *et al*. Surgical treatment of superior cluneal nerve entrapment neuropathy. *J Neurosurg Spine* 2013;19:71-5.