

## Unusual brachial plexus lesion: Hematoma masquerading as a peripheral nerve sheath tumor

Khaled M. Krisht, Michael Karsy, Lubdha M. Shah<sup>1</sup>, Meic H. Schmidt, Andrew T. Dailey

Department of Neurosurgery, Clinical Neurosciences Center, University of Utah, <sup>1</sup>Department of Radiology, University of Utah, Salt Lake City, Utah 84132, USA

E-mail: Khaled M. Krisht - [khaled.krisht@hsc.utah.edu](mailto:khaled.krisht@hsc.utah.edu); Michael Karsy - [michael.karsy@hsc.utah.edu](mailto:michael.karsy@hsc.utah.edu); Lubdha M. Shah - [lubdha.shah@hsc.utah.edu](mailto:lubdha.shah@hsc.utah.edu); Meic H. Schmidt - [meic.schmidt@hsc.utah.edu](mailto:meic.schmidt@hsc.utah.edu); \*Andrew T. Dailey - [andrew.dailey@hsc.utah.edu](mailto:andrew.dailey@hsc.utah.edu)

\*Corresponding author

Received: 27 February 15    Accepted: 01 September 15    Published: 25 January 16

### Abstract

**Background:** Malignant peripheral nerve sheath tumors (MPNSTs) of the brachial plexus have unique radiographic and clinical findings. Patients often present with progressive upper extremity paresthesias, weakness, and pain. On magnetic resonance (MR) imaging, lesions are isointense on T1-weighted and hyperintense on T2-weighted sequences, while also demonstrating marked enhancement on MR studies with gadolinium diethylenetriamine pentaacetic acid. On the basis of their characteristic MR imaging features and rapid clinical progression, two brachial plexus lesions proved to be organizing hematomas rather than MPNST.

**Methods:** A 51-year-old male and a 31-year-old female were both assessed for persistent and worsened left-sided upper extremity pain, paresthesias, and weakness. In both cases, the MR imaging of the brachial plexus demonstrated an extraspinal enhancing lesion located within the left C7–T1 neuroforamina.

**Results:** Although the clinical and radiographic MR features for these 2 patients were consistent with MPNSTs, both lesions proved to be benign organizing hematomas.

**Conclusions:** These two case studies emphasize that brachial plexus hematomas may mimic MPNSTs on MR studies. Accurate diagnosis of these lesions is critical for determining the appropriate management options and treatment plans. Delaying the treatment of a highly aggressive nerve sheath tumor can have devastating consequences, whereas many hematomas resolve without surgery. Therefore, if the patient has stable findings on neurological examination and a history of trauma, surgical intervention may be delayed in favor of repeat MR imaging in 2–3 months to re-evaluate the size of the mass.

**Key Words:** Brachial plexus, hematoma, malignant peripheral nerve sheath tumor, nerve sheath tumor, schwannoma

#### Access this article online

**Website:**

[www.surgicalneurologyint.com](http://www.surgicalneurologyint.com)

**DOI:**

10.4103/2152-7806.174889

**Quick Response Code:**



### INTRODUCTION

Malignant peripheral nerve sheath tumors (MPNSTs) carry a poor prognosis; the 5-year survival rates of 16–50% (e.g., depending on neurofibromin 1 [NF1] status) necessitate rapid diagnosis and treatment.<sup>[1]</sup> Here, two patients presented with lesions originally diagnosed as MPNSTs based on their clinical presentation, and radiographic and magnetic resonance (MR) appearances;

This is an open access article distributed under the terms of the Creative Commons Attribution-NonCommercial-ShareAlike 3.0 License, which allows others to remix, tweak, and build upon the work non-commercially, as long as the author is credited and the new creations are licensed under the identical terms.

**For reprints contact:** [reprints@medknow.com](mailto:reprints@medknow.com)

**How to cite this article:** Krisht KM, Karsy M, Shah LM, Schmidt MH, Dailey AT. Unusual brachial plexus lesion: Hematoma masquerading as a peripheral nerve sheath tumor. *Surg Neurol Int* 2016;7:S64-6.

<http://surgicalneurologyint.com/Unusual-brachial-plexus-lesion:-Hematoma-masquerading-as-a-peripheral-nerve-sheath-tumor/>

however, both proved to be benign, organized hematomas.

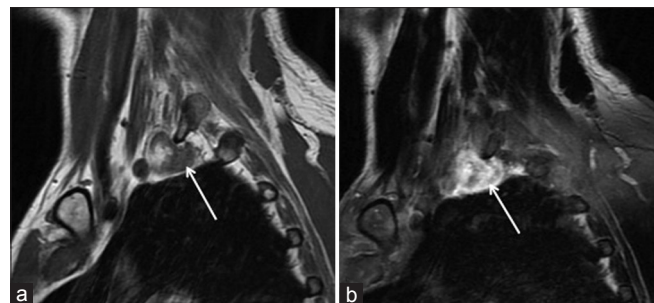## CLINICAL PRESENTATION

### Case 1

A 51-year-old male presented with several months of progressively worsening left arm and clavicle pain, accompanied by hyperesthesias (e.g., from the third digit laterally to the axilla), and diffuse 3–4/5 weakness. Four months prior to his presentation, he had fallen off a ladder and had hung suspended from his left arm. At that time, he had received a selective left C8 nerve root and interlaminar steroid injection for pain relief. MR imaging of his left posterior brachial plexus demonstrated a T1-weighted, heterogeneously enhancing, well-circumscribed lesion suggestive of a MPNST [Figure 1]. Two biopsies were nondiagnostic. An anterior, supraclavicular approach to the brachial plexus was undertaken. Healthy-appearing nerve fibers with good electromyographic response were seen along the superior capsule; however, a mass with a purple capsule was found after the inferior trunk of the brachial plexus was dissected. No electromyographic response was seen along the anteroinferior aspect of the mass where we longitudinally incised the epineurium, revealing a dark maroon-appearing hematoma from within the destroyed nerve fascicles. Specimens were sent for frozen and permanent sections; they were diagnostic of a hemorrhagic cyst. On follow-up 20 weeks postoperatively, the patient showed good pain resolution with some persistent left ulnar-derived weakness.

### Case 2

A 31-year-old female presented with a 3-month history, following a motor vehicle accident, of persistent pain along the left medial elbow, accompanied by tingling and numbness in her left fourth and fifth digits and left hand abduction weakness. The neurological findings were suggestive of a C8/T1 radiculopathy or a brachial plexopathy. The brachial plexus MR imaging demonstrated a T1 hypointense, T2 hyperintense,



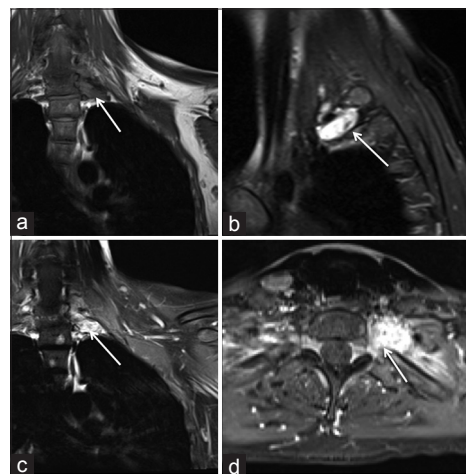
**Figure 1:** Magnetic resonance imaging of the left brachial plexus demonstrating a heterogeneous T1-hyperintense (a), homogeneously enhancing (b) well-circumscribed lesion located in the posterior brachial plexus (white arrows)

and markedly enhancing soft tissue mass on the T1/gadolinium diethylenetriamine pentaacetic acid study within and beyond the left C7/T1 and T1/T2 neuroforamina. The immediate concern was for a MPNST [Figure 2]. The patient underwent a computed tomography-guided fine-needle aspiration/biopsy of the mass; it demonstrated acute inflammation without tumor cells. Surgical treatment involved subperiosteal muscle dissection, exposure of the costotransverse joint of T1, and removal of the transverse processes of T1 and cranial portion of T2. The underlying mass consisted of a well-vascularized, nonencapsulated membrane with organized inflammatory tissue of a brownish color. The mass showed no electromyographic responses and was resected. The frozen and permanent specimens documented the soft connective tissue, degenerated peripheral nerve fascicles, and microscopic foci of hemosiderin consistent with an organizing hematoma rather than a neoplasm. Six months postoperatively, the patient reported complete resolution of her arm pain, but only mild improvement in her hand weakness.

## DISCUSSION

### Differential diagnosis of benign brachial plexus schwannoma or neurofibroma

Brachial plexus lesions are most commonly benign schwannomas or neurofibromas and only more rarely MPNSTs. Benign schwannomas and neurofibromas commonly show T2 hyperintensity and T1 isointensity; schwannomas grow at the periphery of nerves, while neurofibromas grow within the neural tissue and entrap nerve fibers. In addition, schwannomas are frequently encapsulated, showing a rim of low intensity along the tumor margin, while neurofibromas are not.<sup>[2]</sup> Although these MR imaging features are helpful, it often is difficult



**Figure 2:** Magnetic resonance imaging of the brachial plexus demonstrating a T1-isointense (a), T2-hyperintense (b), avidly enhancing (c and d) soft tissue mass along the left C7/T1 and T1/T2 neuroforamina (white arrows)

to determine the exact relationship of the nerve with the lesion when the lesion is large.

### Concern for malignant peripheral nerve sheath tumors

In a large series by Wasa *et al.*<sup>[5]</sup> comparing MR imaging characteristics of neurofibroma with those of MPNST, the most significant differentiating factors were size, peritumoral edema on T2-weighted imaging, and peripheral enhancement. Their appearance on T1- and T2-weighted imaging was equally iso- to hetero-intense and hyper- to hetero-intense, respectively. The margins of MPNSTs tend to be more infiltrative, with obscuration of the adjacent musculofascial planes and the invasion of adjacent structures. The sudden onset and rapidity of neurological decline in our cases was also more suggestive of MPNSTs. Our patients, however, did not have any of the neurocutaneous stigmata of NF-1, and their lesions were smaller than one would expect for MPNST and did not infiltrate soft tissue. Case 1 showed a T1 heterogeneously enhancing hyperintense mass consistent with a hemorrhage but also seen with tumor cysts or intratumoral hemorrhage, while case 2 showed a T2 hyperintense mass and atypical location that also raised the concern for a MPNST.

### Large brachial plexus tumor series

In the largest brachial plexus tumor series published to date, involving 111 tumors in 107 patients, the most common presenting symptoms were numbness/paresthesias, pain, weakness, and a palpable mass.<sup>[3]</sup> A mean age of 25 years was reported for the patients with neurofibromas associated with NF and 42 years for those with either non-NF neurofibromas and schwannomas. The duration of symptoms ranged from 2 months to 10 years prior to treatment. Eighty-two percent of the tumors were schwannomas, neurofibromas, or MPNSTs; none of the nonneural brachial plexus lesions were hematomas. Thus, the identification of an organizing hematoma in these two cases was unexpected in the setting of clinical and radiographic features more suggestive of a MPNST.

### Evolving T1 and T2 magnetic resonance images of brachial plexus hematoma

The T2- and T1-weighted MR imaging characteristics typical of nerve sheath tumors may also be characteristic of evolving hematomas. During the acute stage, a hematoma is isointense relative to the spinal cord on T1-weighted images and hyperintense relative to the spinal cord on T2-weighted images. In the subacute stage, approximately

30 h after the initial hemorrhage, the hematoma usually has a heterogenous hyperintensity on both T1- and T2-weighted images attributed to the degradation products of hemoglobin. In addition, neovascularization of the granulation tissue within the organized chronic hematoma accounts for the uptake of gadolinium; however, this tends to occur peripherally unlike the homogenous enhancement seen in our cases. This latter feature, along with the clinical scenario, makes the diagnosis of hematoma less likely versus a MPNST. Conversely, two cases of soft tissue sarcomas initially mimicked large hematomas.<sup>[4]</sup> Neither patient had a coagulopathy or history of prior/recent trauma, while both demonstrated pain and neurological deterioration. After initial resection revealed hematomas, the patients' persistent symptoms and re-expanding masses prompted secondary biopsies that yielded the diagnosis of soft tissue sarcomas.

### CONCLUSION

Brachial plexus hematomas are rare and can mimic MPNSTs both radiographically and clinically. Careful probing into the patient's history, including recent traumatic events, history of NF, and intake of antithrombotic medications, may help shed light on whether these lesions are benign hematomas or MPNSTs.

### Acknowledgments

We thank Gregory Jost, MD, for assistance with this case and Kristin Kraus, MSc, for editorial help.

### Financial support and sponsorship

Nil.

### Conflicts of interest

There are no conflicts of interest.

### REFERENCES

1. Ducatman BS, Scheithauer BW, Piepgras DG, Reiman HM, Ilstrup DM. Malignant peripheral nerve sheath tumors. A clinicopathologic study of 120 cases. *Cancer* 1986;57:2006-21.
2. Enzinger F, Weiss S. *Soft Tissue Tumors*. St. Louis, MO: CV Mosby; 1983.
3. Ganju A, Roosen N, Kline DG, Tiel RL. Outcomes in a consecutive series of 111 surgically treated plexal tumors: A review of the experience at the Louisiana State University Health Sciences Center. *J Neurosurg* 2001;95:51-60.
4. Niimi R, Matsumine A, Kusuzaki K, Okamura A, Matsubara T, Uchida A, *et al.* Soft-tissue sarcoma mimicking large haematoma: A report of two cases and review of the literature. *J Orthop Surg (Hong Kong)* 2006;14:90-5.
5. Wasa J, Nishida Y, Tsukushi S, Shido Y, Sugiura H, Nakashima H, *et al.* MRI features in the differentiation of malignant peripheral nerve sheath tumors and neurofibromas. *AJR Am J Roentgenol* 2010;194:1568-74.