

Intracranial dural arteriovenous fistula as a cause for symptomatic superficial siderosis: A report of two cases and review of the literature

Griffin R. Baum, Nefize Turan, Ferdinando S. Buonanno¹, Gustavo Pradilla, Raul G. Nogueira²

Departments of Neurosurgery and ²Neurology, Emory University School of Medicine, Atlanta, Georgia, ¹Department of Neurology, Massachusetts General Hospital, Boston, MA, USA

E-mail: Griffin R. Baum - gbaum@emory.edu; Nefize Turan - nefize.turan@emory.edu; Ferdinando S. Buonanno - buonanno.ferdinando@mgh.harvard.edu; Gustavo Pradilla - gpradil@emory.edu; *Raul G. Nogueira - raul.g.nogueira@emory.edu

*Corresponding author

Received: 17 September 15 Accepted: 07 January 16 Published: 01 April 16

Abstract

Background: Superficial siderosis (SS) is the occult deposition of hemosiderin within the cerebral cortex due to repeat microhemorrhages within the central nervous system. The collection of hemosiderin within the pia and superficial cortical surface can lead to injury to the nervous tissue. The most common presentation is occult sensorineural hearing loss although many patients have been misdiagnosed with diseases such as multiple sclerosis and amyotrophic lateral sclerosis before being diagnosed with SS. Only one case report exists in the literature describing an intracranial dural arteriovenous fistula (dAVF) as the putative cause for SS.

Case Description: We describe two cases of SS caused by a dAVF. Both patients had a supratentorial, cortical lesion supplied by the middle meningeal artery with venous drainage into the superior sagittal sinus. In both patients, symptoms improved after endovascular embolization. The similar anatomic relationship of both dAVFs reported presents an interesting question about the pathogenesis of SS. Similar to the pathologic changes seen in the formation of intracranial arterial aneurysms; it would be possible that changes in the blood vessel lining and wall might predispose a patient to chronic, microhemorrhage resulting in SS.

Conclusions: We describe the second and third cases of a dAVF as the cause of SS, and the first cases of successful treatment of SS-associated dAVF with endovascular embolization. As noninvasive imaging techniques become more sensitive and easily obtained, one must consider their limitations in detecting occult intracranial vascular malformations such as dAVF as a possible etiology for SS.

Key Words: Dural arteriovenous fistula, embolization, superficial siderosis

Access this article online

Website:

www.surgicalneurologyint.com

DOI:

10.4103/2152-7806.179577

Quick Response Code:



INTRODUCTION

Superficial siderosis (SS) occurs as a result of hemosiderin deposition along leptomeninges, pial, subpial, and subependymal tissues due to recurrent microhemorrhages within the central nervous system (CNS).^[32] Intracellular uptake of iron and possibly neuroinflammation causes neuronal injury leading to various symptoms of SS such as sensorineural hearing loss, ataxia, transient focal

This is an open access article distributed under the terms of the Creative Commons Attribution-NonCommercial-ShareAlike 3.0 License, which allows others to remix, tweak, and build upon the work non-commercially, as long as the author is credited and the new creations are licensed under the identical terms.

For reprints contact: reprints@medknow.com

How to cite this article: Baum GR, Turan N, Buonanno FS, Pradilla G, Nogueira RG. Intracranial dural arteriovenous fistula as a cause for symptomatic superficial siderosis: A report of two cases and review of the literature. *Surg Neurol Int* 2016;7:S223-7.

<http://surgicalneurologyint.com/Intracranial-dural-arteriovenous-fistula-as-a-cause-for-symptomatic-superficial-siderosis-A-report-of-two-cases-and-review-of-the-literature/>

neurological episodes similar to transient ischemic attack, and cognitive impairment.^[2,4,19,24,36,40,42-44]

SS is seen in nearly half of the patients after single episode of high grade aneurysmal subarachnoid hemorrhage.^[23] In the setting of nontraumatic and nonaneurysmal cortical SS, cerebral amyloid angiopathy has been described as the most common etiology of SS in large population studies.^[24,26] Vascular lesions such as cavernous malformations and neoplastic lesions such as ependymoma, hemorrhagic giant prolactinoma, meningeal melanocytoma, and childhood cerebellar tumors, have also been reported to induce SS.^[1,9,21,33,34,39]

Before the advent of magnetic resonance imaging (MRI), SS was diagnosed in postmortem studies. However, with the wide availability of MRI in current practice, the SS is more frequently being diagnosed. Pathognomic finding of hemosiderin deposition can be characterized as hypointensity on T2-weighted imaging (T2WI) MRI and gradient recalled echo T2-WI (GRE T2*WI) MRI.^[11,13,18,20] There is accumulating evidence that three-dimensional T2 star-weighted angiography^[12] may be superior to GRE T2*WI for the diagnosis of SS.^[8,46]

Previously, a case of intracranial dural arteriovenous fistula (dAVF) treated with open surgery and a spinal dAVF as a cause of symptomatic SS have been reported as the putative cause for SS of CNS.^[6,38] We will describe the second and third cases of intracranial dAVF as the cause of symptomatic intracranial SS and successful treatment of SS-associated dAVF with endovascular embolization.

CASE DESCRIPTIONS

Case 1

An 88-year-old male referred from outside center with the suspicion of subarachnoid hemorrhage, presented with bilateral upper extremity paresthesias and concern for stroke-like symptoms. The physical examination was unremarkable. His past medical history was significant for the previous stroke with residual right upper extremity paresthesias. A 1.5-tesla MRI revealed susceptibility artifact without associated fluid-attenuated inversion recovery nonsuppression along sulci predominately at the vertex [Figure 1a]. MR-angiography did not reveal any possible source for the findings. The diagnostic cerebral angiogram revealed a left parasagittal Borden Grade I dAVF supplied by arterial feeders from the frontoparietal trunk of the left middle meningeal artery with early venous drainage into the superior sagittal sinus (SSS) [Figure 1b]. The left parasagittal dAVF lesion was treated successfully using transarterial Onyx × 34 and Onyx × 18 embolization with no residual filling and no off-target embolization [Figure 1c-d]. After the procedure, the left sided paresthesias had completely resolved, and the right-sided paresthesias were decreased in frequency.

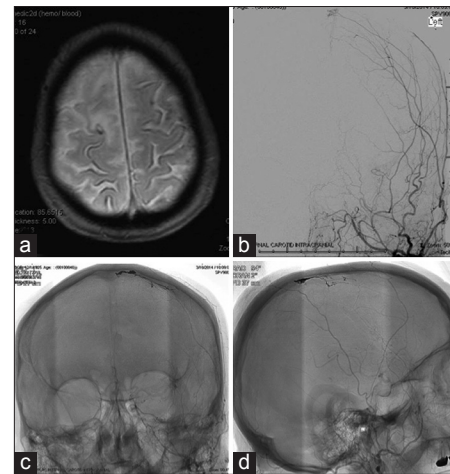


Figure 1: Case 1 - (a) Axial T2-weighted GRE magnetic resonance sequence demonstrating superficial siderosis of the cerebral cortex near the vertex. (b) Cerebral angiography – anteroposterior projection cerebral digital subtraction angiography of the left internal carotid artery injection demonstrating Borden I methyl methacrylate to superior sagittal sinus dural arteriovenous fistula. (c and d) Postembolization anteroposterior and lateral nonsubtracted cerebral angiography films showing embolization cast of dural arteriovenous fistula

The patient was discharged without complication on postprocedure day 1.

Case 2

A 73-year-old male presented with a history of progressive cognitive impairment, gait ataxia, and sensorineural hearing loss. MRI of the brain showed classic findings of SS. Conventional angiography showed a Borden III splenic AVE, which was supplied by the right middle meningeal artery and drained into the SSS with cortical venous reflux into the vein of Trolard [Figure 2a-c]. Embolization was carried out from the proximal portion of the pedicle with optimal penetration into the fistula resulting in angiographic cure and return of antegrade flow in the vein of Trolard [Figure 2d]. A follow-up angiogram was performed at 12 months which demonstrated stable cure of the dAVF.

DISCUSSION

Iron and ferritin are found in many types of cells in the brain including neurons, microglia, and oligodendroglia in a normal state.^[45] In pathological states where blood extravasates into the brain, brain converts the iron in heme to hemosiderin, which appears 6 days after extravasation of blood into the brain parenchyma.^[16] Moreover, SS of the CNS is thought to be a result of hemosiderin deposition within the external surface of the brain due to repeat microhemorrhages. Macroscopically, SS leads to dark brown discoloration of the leptomeninges and superficial CNS parenchyma.^[10] Microscopically, SS is characterized by hemosiderin deposition in the

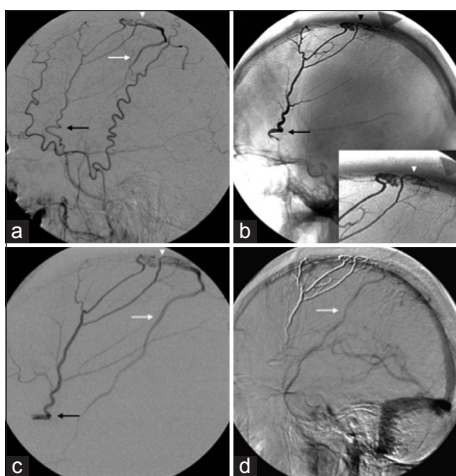


Figure 2: Case 2 - Lateral projections of cerebral digital subtraction angiography showing methyl methacrylate to superior sagittal sinus dural arteriovenous fistula (a-c) with successful endovascular embolization (d)

leptomeninges, subpial, and subependymal regions with the adjacent neuronal loss, reactive gliosis, and demyelination.^[14,15]

SS remains a rare disease with <300 total reported cases since its initial description by Hamill in 1908.^[7] The diagnosis was largely postmortem in the earlier years; however, the premortem detection has dramatically increased with the advent of MRI technology. SS affects a wide range of ages with men being approximately 3 times more frequently afflicted than women.^[5] SS has been reported in the literature as the result of many vascular and nonvascular intracranial pathologies, including tumors of the brain and spinal cord (e.g., myxopapillary ependymoma), ventricular shunts, chronic subdural hematomas, previous CNS surgery, cavernous, and arteriovenous malformations (AVMs).^[1,9,17,22,25,27,35,37,39,41,42]

The most common presentation of SS of CNS is reported to be occult sensorineural hearing loss followed by ataxia/gait imbalance. Corticospinal, cognitive, and olfactory dysfunctions are also frequent, and many patients have been misdiagnosed with diseases such as multiple sclerosis and amyotrophic lateral sclerosis before being diagnosed with SS.^[2,4,19,36,40,42-44] Cortical SS, on the other, is associated with permanent focal neurological deficits such as hemiparesis or hemianopia of abrupt onset transient focal neurological deficits mimicking transient ischemic attacks such as spreading paresthesia or transient aphasia, and less commonly cognitive impairment, seizures, and headache.^[24] Cerebrospinal fluid analysis may reveal xanthochromia and elevated iron, ferritin, and red blood cell count.^[5]

Dural arteriovenous fistulas (dAVF) represents 10–15% of cerebral vascular malformations and are not commonly associated with SS. There has only been one other

case of SS due to an intracranial dAVF described in the literature.^[38] This patient required open surgical obliteration of the fistula, which resulted in resolution of the patient's symptoms. We reported two additional cases of SS due to an intracranial dAVF which were treated using intra-arterial Onyx embolization. Rapid resolution of symptoms after embolization in the first case suggests that hemodynamic effects of the dAVF may partly responsible for the symptoms besides SS.

With the increased availability of MRI and concomitant reductions in cost to obtain these studies, it is presumed that prevalence of SS will increase. The majority of these cases would presumably be asymptomatic and incidental findings, but given the early identification of this potentially debilitating neurologic disease. The combined use of sensitive MR-angiographic techniques such as (four-dimensional time of flight) combined with diagnostic cerebral angiography in a select group of patients will conceivably increase the numbers of patients with SS due to occult intracranial vascular malformations such as dAVF.

While SS due to dAVF should be included in the differential diagnosis of an atypical presentation of neurologic disease, the likelihood of this being the etiology of the patient's disease process is low. An increasing number of reports associate atraumatic cortical SS with cerebral amyloid angiopathy and less commonly with reversible cerebral vasoconstriction syndrome, primary angiitis of the CNS, and reperfusion injury.^[24,26,28-30] With increasing numbers of vascular lesion induced SS cases reported in the literature, however, and potentially minimally invasive and highly effective treatment modalities such as endovascular embolization as treatment options, the well-informed clinician may be rewarded by considering a vascular lesions such as dAVFs as a possible etiology for SS.^[3,31] Since small AVMs and dAVFs may be missed even with the best noninvasive imaging techniques, when considering the potentially devastating consequences of SS, conventional angiographic evaluation can be considered for patients with symptomatic SS. Symptomatic SS with recurrent episodic encephalopathy due to a spinal dAVF has also previously been reported as a cause of symptomatic SS.^[6] The two additional cases reported in the present case as well as the previous case reports highlight the need for a thorough cerebrovascular workup in symptomatic SS patients and consideration of intracranial and spinal dAVFs in the differential diagnosis of SS.

The similar anatomic relationship of both dAVFs reported in the present report as well as the previous case report presents an interesting question about the likely pathogenesis of dAVF-induced SS. The middle meningeal artery supplied the arterial feeders in both lesions as well

as in the previous case report, and the drainage pattern was directly into the SSS with cortical venous reflux, whereas it was into transverse sinus in the previous case report. It is plausible that the cortical venous reflux supplied by a high flow venous structure such as the SSS could create sufficient turbulent vascular flow patterns to cause pathologic changes in the walls of the delicate and fragile blood vessels of dAVFs. In addition, similar to the pathologic changes seen in the formation of intracranial arterial aneurysms, it would be possible that changes in the blood vessels themselves might predispose a patient to chronic microhemorrhages resulting in SS.

CONCLUSION

We report the second and third cases of SS due to intracranial dAVF, which were treated with intra-arterial Onyx embolization. As noninvasive imaging techniques become more sensitive and easily obtained, it is crucial to keep in mind occult intracranial vascular malformations such as dAVF as a possible etiology for incidental SS in the appropriate patient population.

Financial support and sponsorship

Nil.

Conflicts of interest

There are no conflicts of interest.

REFERENCES

- Anderson NE, Sheffield S, Hope JK. Superficial siderosis of the central nervous system: A late complication of cerebellar tumors. *Neurology* 1999;52:163-9.
- Cerqueira AC, Nardi AE, Bezerra JM. Superficial siderosis of the central nervous system: An unusual cause of sensorineural hearing loss. *Arq Neuropsiquiatr* 2010;68:469-71.
- Chandra RV, Leslie-Mazwi TM, Mehta BP, Yoo AJ, Rabinov JD, Pryor JC, et al. Transarterial onyx embolization of cranial dural arteriovenous fistulas: Long-term follow-up. *AJNR Am J Neuroradiol* 2014;35:1793-7.
- Driver-Dunckley ED, Hoxworth JM, Patel NP, Bosch EP, Goodman BP. Superficial siderosis mimicking amyotrophic lateral sclerosis. *J Clin Neuromuscul Dis* 2010;11:137-44.
- Fearnley JM, Stevens JM, Rudge P. Superficial siderosis of the central nervous system. *Brain* 1995;118(Pt 4):1051-66.
- Gonella MC, Fischbein NJ, Lane B, Shuer LM, Greicius MD. Episodic encephalopathy due to an occult spinal vascular malformation complicated by superficial siderosis. *Clin Neurol Neurosurg* 2010;112:82-4.
- Hamill RC. Report of a case of melanosis of the brain, cord, and meninges. *J Nerv Ment Dis* 1908;35:594.
- Hayashida Y, Kakeda S, Hiai Y, Ide S, Ogasawara A, Ooki H, et al. Diagnosis of intracranial hemorrhagic lesions: Comparison between 3D-SWAN (3D T2*-weighted imaging with multi-echo acquisition) and 2D-T2*-weighted imaging. *Acta Radiol* 2014;55:201-7.
- Hsu WC, Loevner LA, Forman MS, Thaler ER. Superficial siderosis of the CNS associated with multiple cavernous malformations. *AJNR Am J Neuroradiol* 1999;20:1245-8.
- Hughes JT, Oppenheimer DR. Superficial siderosis of the central nervous system. A report on nine cases with autopsy. *Acta Neuropathol* 1969;13:56-74.
- Imazumi T, Chiba M, Honma T, Niwa J. Detection of hemosiderin deposition by T2*-weighted MRI after subarachnoid hemorrhage. *Stroke* 2003;34:1693-8.
- Jabbarli R, Reinhard M, Niesen WD, Roelz R, Shah M, Kaier K, et al. Predictors and impact of early cerebral infarction after aneurysmal subarachnoid hemorrhage. *Eur J Neurol* 2015;22:941-7.
- Janss AJ, Galetta SL, Freese A, Raps EC, Curtis MT, Grossman RI, et al. Superficial siderosis of the central nervous system: Magnetic resonance imaging and pathological correlation. Case report. *J Neurosurg* 1993;79:756-60.
- Koeppen AH, Dentinger MP. Brain hemosiderin and superficial siderosis of the central nervous system. *J Neuropathol Exp Neurol* 1988;47:249-70.
- Koeppen AH, Dickson AC, Chu RC, Thach RE. The pathogenesis of superficial siderosis of the central nervous system. *Ann Neurol* 1993;34:646-53.
- Koeppen AH. The history of iron in the brain. *J Neurol Sci* 1995;134 Suppl:S1-9.
- Kole MK, Steven D, Kirk A, Lowrie SP. Superficial siderosis of the central nervous system from a bleeding pseudomeningocele. Case illustration. *J Neurosurg* 2004;100:718.
- Kumar N, Cohen-Gadol AA, Wright RA, Miller GM, Piepgras DG, Ahlskog JE. Superficial siderosis. *Neurology* 2006;66:1144-52.
- Kumar N, Fogelson JL, Morris JM, Pichelmann MA. Superficial siderosis should be included in the differential diagnosis of motor neuron disease. *Neurologist* 2012;18:139-45.
- Kumar N. Neuroimaging in superficial siderosis: An in-depth look. *AJNR Am J Neuroradiol* 2010;31:5-14.
- Leussink VI, Flachenecker P, Brechtelsbauer D, Bendszus M, Sliwka U, Gold R, et al. Superficial siderosis of the central nervous system: Pathogenetic heterogeneity and therapeutic approaches. *Acta Neurol Scand* 2003;107:54-61.
- Li KW, Haroun RI, Clatterbuck RE, Murphy K, Rigamonti D. Superficial siderosis associated with multiple cavernous malformations: Report of three cases. *Neurosurgery* 2001;48:1147-50.
- Lummel N, Bernau C, Thon N, Bochmann K, Linn J. Prevalence of superficial siderosis following singular, acute aneurysmal subarachnoid hemorrhage. *Neuroradiology* 2015;57:349-56.
- Lummel N, Wollenweber FA, Demaerel P, Bochmann K, Malik R, Opherk C, et al. Clinical spectrum, underlying etiologies and radiological characteristics of cortical superficial siderosis. *J Neurol* 2015;262:1455-62.
- Manfredi M, Magni E, Gandolfini M, Beltramello A, Orlandini A, Donati E. Superficial siderosis of the central nervous system and anticoagulant therapy: A case report. *Ital J Neurol Sci* 1999;20:247-9.
- Martínez-Lizana E, Carmona-Iragui M, Alcolea D, Gómez-Choco M, Vilaplana E, Sánchez-Saudinós MB, et al. Cerebral amyloid angiopathy-related atraumatic convexal subarachnoid hemorrhage: An ARIA before the tsunami. *J Cereb Blood Flow Metab* 2015;35:710-7.
- McCarron MO, Flynn PA, Owens C, Wallace I, Mirakhor M, Gibson JM, et al. Superficial siderosis of the central nervous system many years after neurosurgical procedures. *J Neurol Neurosurg Psychiatry* 2003;74:1326-8.
- Mehndiratta P, Mendel TA. Cortical superficial siderosis, APOE genotype, and hemorrhage risk in cerebral amyloid angiopathy. *Neurology* 2015;84:1190-1.
- Na HK, Park JH, Kim JH, Kim HJ, Kim ST, Werring DJ, et al. Cortical superficial siderosis: A marker of vascular amyloid in patients with cognitive impairment. *Neurology* 2015;84:849-55.
- Ni J, Auriel E, Jindal J, Ayres A, Schwab KM, Martinez-Ramirez S, et al. The characteristics of superficial siderosis and convexity subarachnoid hemorrhage and clinical relevance in suspected cerebral amyloid angiopathy. *Cerebrovasc Dis* 2015;39:278-86.
- Nogueira RG, Dabus G, Rabinov JD, Eskey CJ, Ogilvy CS, Hirsch JA, et al. Preliminary experience with onyx embolization for the treatment of intracranial dural arteriovenous fistulas. *AJNR Am J Neuroradiol* 2008;29:91-7.
- Offenbacher H, Fazekas F, Schmidt R, Kapeller P, Fazekas G. Superficial siderosis of the central nervous system: MRI findings and clinical significance. *Neuroradiology* 1996;38 Suppl 1:S51-6.
- Sabat SB. Intraventricular cavernous malformation with superficial siderosis. *Arch Neurol* 2010;67:638-9.
- Salem A, Krainik A, Helias A, Bouccara D, Gaillard S, Feydy A, et al. MRI findings in a case of a superficial siderosis associated with an ependymoma. *J Neuroradiol* 2002;29:136-8.
- Satow T, Yamada S, Yagi M, Saiki M. Superficial siderosis of the central nervous system after ventriculoperitoneal shunt. *J Neurosurg* 2010;113:93-6.

36. Savoiardo M, Grisoli M, Pareyson D. Polyradiculopathy in the course of superficial siderosis of the CNS. *J Neurol* 2001;248:1099-100.
37. Shinmei Y, Harada T, Ohashi T, Yoshida K, Moriwaka F, Matsuda H. Trochlear nerve palsy associated with superficial siderosis of the central nervous system. *Jpn J Ophthalmol* 1997;41:19-22.
38. Signorelli F, McLaughlin N, Bojanowski MW. Superficial siderosis as a manifestation of a dural arteriovenous fistula. *Can J Neurol Sci* 2011;38:367-9.
39. Steinberg J, Cohen JE, Gomori JM, Fraifeld S, Moscovici S, Rosenthal G, et al. Superficial siderosis of the central nervous system due to chronic hemorrhage from a giant invasive prolactinoma. *J Clin Neurosci* 2013;20:1032-4.
40. Sydlowski SA, Cevette MJ, Shallop J. Superficial siderosis of the central nervous system: Phenotype and implications for audiology and otology. *Otol Neurotol* 2011;32:900-8.
41. Tacconi L, Marinella T. Superficial siderosis of the central nervous system secondary to a thalamic hamartoma. *J Clin Neurosci* 1999;6:532-5.
42. Tiryaki E, Azzarelli B, Biller J. Superficial siderosis of the central nervous system in a patient with chronic subarachnoid hemorrhage misdiagnosed as multiple sclerosis. *J Stroke Cerebrovasc Dis* 2002;11:288-9.
43. Turner B, Wills AJ. Superficial siderosis associated with anterior horn cell dysfunction. *J Neurol Neurosurg Psychiatry* 2002;72:274-5.
44. Wang K, Xu Z, Xiong G, Benyan L. Superficial siderosis of the central nervous system manifested with seizures. *J Clin Neurosci* 2010;17:277-8.
45. Zecca L, Youdim MB, Riederer P, Connor JR, Crichton RR. Iron, brain ageing and neurodegenerative disorders. *Nat Rev Neurosci* 2004;5:863-73.
46. Zhao H, Wang J, Lu Z, Wu Q, Lv H, Liu H, et al. Superficial siderosis of the central nervous system induced by a single-episode of traumatic subarachnoid hemorrhage: A study using MRI-enhanced gradient echo T2 star-weighted angiography. *PLoS One* 2015;10:e0116632.