

Diabetes may affect intracranial aneurysm stabilization in older patients: Analysis based on intraoperative findings

Jihye Song, Yong Sam Shin¹

Department of Neurosurgery, Konyang University Hospital, Konyang University College of Medicine, Daejeon, ¹Department of Neurosurgery, College of Medicine, Seoul St. Mary's Hospital, The Catholic University of Korea, Seoul, Republic of Korea

E-mail: Jihye Song - songjihye81@gmail.com; *Yong Sam Shin - nsshin@gmail.com

*Corresponding author

Received: 20 October 15 Accepted: 22 February 16 Published: 03 June 16

Abstract

Background: Only a small proportion of aneurysms progress to rupture. Previous studies have focused on predicting the rupture risk of intracranial aneurysms. Atherosclerotic aneurysm wall appears resistant to rupture. The purpose of this study was to evaluate clinical and morphological factors affecting atherosclerosis of an aneurysm and identify the parameters that predict aneurysm stabilization.

Methods: We conducted a retrospective analysis of 253 consecutive patients with 291 unruptured aneurysms who underwent clipping surgery in a single institution between January 2012 and October 2013. Aneurysms were categorized based on intraoperative video findings and assessed morphologic and demographic data. Aneurysms which had the atherosclerotic wall without any super thin and transparent portion were defined as stabilized group and the others as a not-stabilized group.

Results: Of the 207 aneurysms, 176 (85.0%) were assigned to the not-stabilized group and 31 (15.0%) to the stabilized group. The relative proportion of stabilized aneurysms increased significantly as the age increased ($P < 0.001$). Univariate logistic analysis showed that age ≥ 65 years ($P < 0.001$), hypertension ($P = 0.012$), diabetes ($P = 0.007$), and height ≥ 3 mm ($P = 0.007$) were correlated with stabilized aneurysms. Multivariate logistic analysis showed that age ≥ 65 years ($P = 0.009$) and hypertension ($P = 0.041$) were strongly correlated with stable aneurysms. In older patients (≥ 65 years of age), multivariate logistic regression revealed that only diabetes was associated with stabilized aneurysms ($P = 0.027$).

Conclusions: In patients ≥ 65 years of age, diabetes mellitus may highly predict the stabilized aneurysms. These results provide useful information in determining treatment and follow-up strategies, especially in older patients.

Key Words: Atherosclerosis, intracranial aneurysm, rupture risk, stabilization

Access this article online

Website:

www.surgicalneurologyint.com

DOI:

10.4103/2152-7806.183497

Quick Response Code:

This is an open access article distributed under the terms of the Creative Commons Attribution-NonCommercial-ShareAlike 3.0 License, which allows others to remix, tweak, and build upon the work non-commercially, as long as the author is credited and the new creations are licensed under the identical terms.

For reprints contact: reprints@medknow.com

How to cite this article: Song J, Shin YS. Diabetes may affect intracranial aneurysm stabilization in older patients: Analysis based on intraoperative findings. Surg Neurol Int 2016;7:S391-7.

<http://surgicalneurologyint.com/Diabetes-may-affect-intracranial-aneurysm-stabilization-in-older-patients:-Analysis-based-on-intraoperative-findings/>

INTRODUCTION

Intracranial aneurysms (IAs) occur in approximately 3% of the population,^[42] and the mean 1-year risk of aneurysm rupture is approximately 1%.^[41] Rupture of an IA occurs in relatively young people and has a high fatality and morbidity rate, but the majority of patients with incidentally detected IA have a benign course.^[32] In recent years, increasingly more unruptured aneurysms have been diagnosed due primarily to the widespread use of noninvasive brain imaging techniques.^[6,14,28,39] In patients with unruptured IA, physicians decide whether to treat preventively by balancing the risk of treatment against the risk of rupture. The decision is often not straightforward because the morbidity and mortality associated with clipping and coiling of unruptured aneurysms are up to 5%^[4] and knowledge regarding the natural history of IAs is limited.

The presence of atherosclerotic plaque in some IAs and similar histological and biochemical features of aneurysms and atherosclerotic lesions suggest that atherosclerosis may be a mechanism in the pathogenesis of IAs. Furthermore, atherosclerosis and IA share risk factors, such as hypertension and smoking. Aneurysms may rupture when the thinned wall can no longer withstand the tension.^[8] Previous studies which evaluated the aneurysm domes histologically showed that most ruptured aneurysms had thin and hypocellular walls and most unruptured aneurysm had organized and thick walls.^[24] The atherosclerotic aneurysm wall, due to its hypertrophied and stiff characteristics, appears more resistant to hydrostatic pressure than super thin-walled aneurysms.

The natural history of IA consists of three phases: Initiation, growth, and either stabilization or rupture with only a small

minority of aneurysms progressing to rupture.^[35] Previous studies on aneurysms mainly focused on identifying the parameters predicting aneurysm rupture^[2,3,5,7,11,16,20,23,45] but not on the factors affecting aneurysm stabilization which represent the majority of IAs. In this study, we defined the aneurysms with the atherosclerotic wall as stabilized and evaluated the morphological and demographic parameters that affect aneurysm stabilization.

MATERIALS AND METHODS

Patients

This study was conducted in accordance and with the approval of the Ethics Review Board of our hospital. All patients who underwent microsurgical clipping for ruptured or unruptured IAs between January 2012 and October 2013 in our department were identified using a prospectively collected database. Two hundred and fifty-three consecutive patients with 291 IAs were identified (204 patients with 242 unruptured IAs and 49 patients with 49 ruptured IAs) [Figure 1]. Only patients who had available intraoperative video files and distal subtraction angiography (DSA) data were included in the present study. Aneurysms which were partially dissected and exposed <50% of their entire dome were excluded. Fusiform aneurysms or clipped aneurysms after coil embolization were excluded. Ruptured or intraoperative premature ruptured aneurysms were excluded because blood obscured the aneurysm dome visualization. A total of 207 aneurysms in 182 patients were selected, and the patients' medical records and three-dimensional (3D) angiographic data were retrospectively reviewed. There were 68 males and 114 females, and the mean age was 55.8 ± 8.2 years (range: 30–76 years).

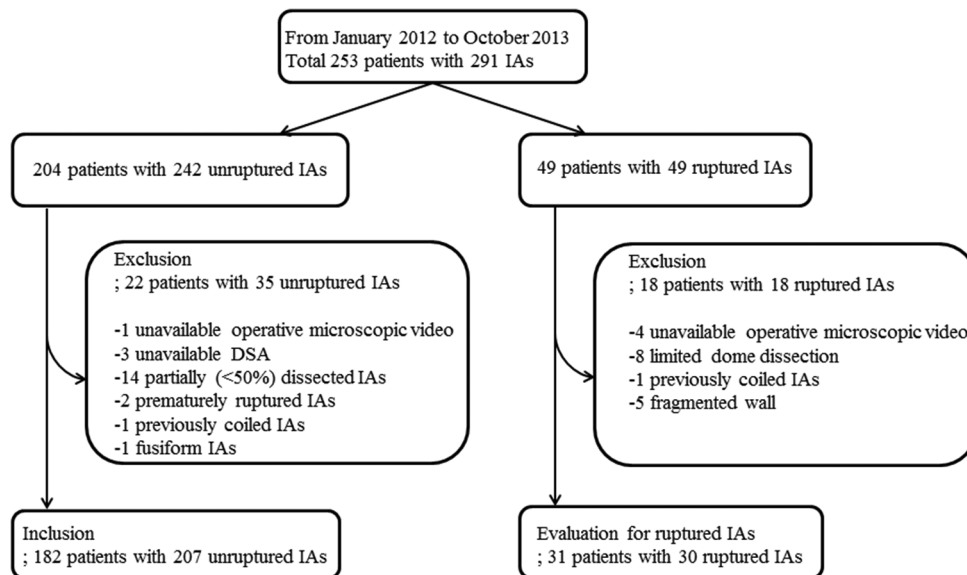


Figure 1: Flow diagram of patients inclusion and exclusion

Intraoperative video data

All intraoperative images were captured through a Pentero 900 or Pentero surgical microscope video (Carl Zeiss, Oberkochen, Germany) at 1920×1080 or 720×480 pixels during aneurysm clipping procedures. Aneurysms were assessed for their wall thickness based on color translucence and the presence of atherosclerosis and divided into two groups. Aneurysms with atherosclerotic wall without any transparent and super thin portion were defined as stabilized aneurysm range and the others as not-stabilized range [Figure 2]. Super thin regions were defined based on color intensity with respect to the parent vessel wall. Randomly selected thirty microscopic videos were reviewed together by two neurosurgeons (Jihye Song and Yong Sam Shin) to minimize the inter-observer bias of the aneurysm grouping. Then, they reviewed the rests of 152 microscopic videos independently. There was no discrepancy between the two surgeon's groupings of the aneurysms. Patient characteristics including medical histories were blinded to the video reviewers.

We reviewed microscopic videos of 49 consecutive ruptured aneurysm patients (41 females and eight males, mean age 57.6 years, range: 35–83 years) who underwent clipping surgery in our institution for the same period to evaluate whether aneurysms with atherosclerotic walls were stabilized. Because blood obscured the aneurysm dome, identification of the wall appearance was difficult. Of the 49 aneurysms, 18 aneurysms could not be evaluated because of limited dome dissection, absence of microscopic video, coiled aneurysm, or completely fragmented wall.

Demographic, angiographic, and intraoperative video data

Demographic data were reviewed from medical records. In this study, we used the following factors such as patient age, gender, current smoking habit, family history of stroke (both ischemic and hemorrhagic), hypertension (systolic blood pressure >140 mmHg or diastolic blood pressure >90 mmHg) or current treatment status,

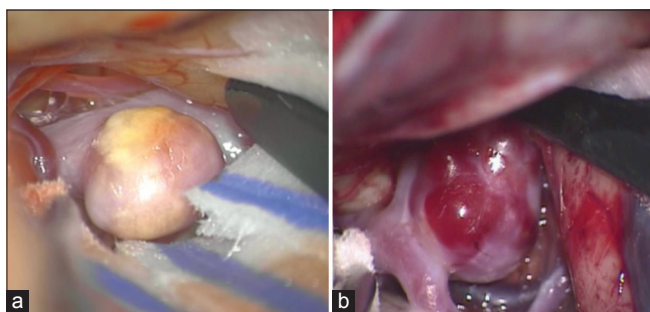


Figure 2: Intraoperative microscopic image of stabilized and not-stabilized aneurysm. (a) Stabilized aneurysm that was with thick atherosclerotic wall without any transparent and super thin portion. (b) Not-stabilized aneurysm that was with transparent and super thin portion and without atherosclerotic wall

and diabetes mellitus (DM, hemoglobin A1c ≥ 6.5) or current treatment status. Aneurysm size was defined as previously described.^[33] Angiographic data collected from 3D DSA images included maximal diameter (D_{max} ; defined as the largest of all cross-sections along the height of the aneurysm), neck diameter (D_{neck} ; defined as the average neck diameter), height (H; defined as the maximum perpendicular distance of the dome from the neck plane), aspect ratio (H/D_{neck} ; defined as the ratio of the maximum perpendicular height to the average neck diameter), bottleneck factor (W_{max}/D_{neck}), and height-width ratio (H/W_{max}).

Statistics

The continuous data were expressed as a mean \pm standard deviation. Chi-square test or Fishers exact test was used to compare medical comorbidities and dichotomized morphological parameters between stabilized and not-stabilized groups. An unpaired *t*-test was used for continuous variable statistical analysis. To identify the independent parameters that correlated significantly with the stabilization, univariate and multivariate logistic regression analyses were separately performed for all aneurysms. The odds ratio (OR) and 95% confidence interval (CI) were calculated. A $P < 0.05$ was considered significant. Statistical analysis was performed using SPSS (SPSS Inc., Chicago, IL, USA).

RESULTS

Intraoperative findings of ruptured aneurysm

Thirty-one ruptured aneurysms (five males and 26 females; mean age 57.35 years, range: 35–79 years) were evaluated for their wall morphology. Of the 31 evaluated aneurysms, only one patient, a 75-year-old female, was suspected of a stabilized aneurysm.

Demographics and morphologies of all aneurysms

Of the 207 aneurysms, 176 (85.0%) were assigned to the not-stabilized group and 31 (15.0%) to the stabilized group. Table 1 summarizes the demographic and morphological characteristics. Hypertension ($P = 0.008$) and DM ($P = 0.010$) were significantly higher in the stabilized group (χ^2 -test). There was no significant trend in morphological parameters. Figure 3 shows the relative proportion of stabilized aneurysms in each age group increased significantly as the age increased ($P < 0.001$). There were no stabilized aneurysms in the 30 s group, and all aneurysms were stabilized in the 70 s group. A positive trend was observed between stabilized aneurysm and age ($P = 0.002$; OR, 1.105; 95% CI, 1.037–1.178) based on multivariate analysis with morphologic factors.

To evaluate the predictive factors of stabilized aneurysms, statistical analyses were performed with dichotomized values [Table 2]. Univariate logistic regression analysis

revealed that age ≥ 65 years ($P < 0.001$), hypertension ($P = 0.008$), DM ($P = 0.010$), and height ≥ 3 ($P = 0.007$) were significantly related to stabilized aneurysms. Of the variables that influenced stabilized aneurysms, age ≥ 65 years ($P = 0.009$), hypertension ($P = 0.041$), and

height ≥ 3 mm ($P = 0.018$) remained significant in the multivariate regression analysis.

Older patients (≥ 65 years of age)

There were 26 patients (eight males and 18 females) older than 65 years of age and 11 (42.3%) were in the stabilized group. Medical comorbidities and aneurysm size were analyzed. There were no smokers in this group; thus, we could not obtain a value for smoking with multivariate analysis. Univariate logistic regression analysis showed that DM was the only significant predictor of stabilized aneurysms ($P = 0.019$), and it remained after multivariate logistic regression analysis ($P = 0.027$; OR, 29.435; 95% CI, 1.471–588.999).

Table 1: Patient characteristics of not-stabilized and stabilized aneurysms

Patient characteristics	Aneurysm group (n=207)		P value
	Not-stabilized (n=176)	Stabilized (n=31)	
Age (years)	54.9 \pm 7.8	61.2 \pm 8.1	<0.001
30-39	7 (100%)	0 (0%)	
40-49	33 (94.3%)	2 (5.7%)	
50-59	80 (87.9%)	11 (12.1%)	
60-69	56 (82.4%)	12 (17.6%)	
70-79	0 (0%)	6 (100%)	
Gender			0.573
Male	63 (35.8%)	11 (35.5%)	
Female	113 (64.2%)	20 (64.5%)	
Hypertension	75 (42.6%)	21 (67.7%)	0.008
Diabetes	15 (8.5%)	8 (25.8%)	0.010
Smoking	18 (10.2%)	1 (3.2%)	0.186
Family history	34 (19.3%)	7 (22.6%)	0.417
Multiplicity	65 (36.9%)	13 (41.9%)	0.367
Aneurysm location			0.444
ACA, Acom	42 (23.9%)	8 (25.8%)	
MCA, MCAB	98 (55.7%)	18 (58.1%)	
ICA	35 (19.9%)	4 (12.9%)	
Others	1 (0.6%)	1 (3.2%)	
Morphologic parameters (mean (SD))			
D _{max} (mm)	4.7 (2.1)	5.5 (2.2)	0.584
D _{neck} (mm)	3.5 (1.3)	3.7 (1.3)	0.779
Height (mm)	3.4 (1.5)	4.4 (1.7)	0.373
Aspect ratio	1.0 (0.4)	1.2 (0.4)	0.148
Bottle neck factor	1.3 (0.4)	1.5 (0.4)	0.263
Height waist ratio	0.8 (0.3)	0.9 (0.2)	0.411

ACA: Anterior cerebral artery, ACoA: Anterior communicating artery, MCA: Middle cerebral artery, MCAB: Middle cerebral artery bifurcation, ICA: Internal carotid artery, SD: Standard deviation, D_{max}: Maximum diameter, D_{neck}: Neck diameter

DISCUSSION

When IAs detected incidentally, physicians decide whether to treat or not by weighing up the risk of treatment against the rupture risk. The decision is often not straightforward because the complication associated with the treatment of unruptured aneurysms are up to 5%, and knowledge regarding the natural history of IAs is limited. To identify the factors which affect aneurysm rupture or stabilization if possible can help deciding treatment and follow-up strategy. With the hypothesis that aneurysms with atherosclerotic wall are stabilized, we

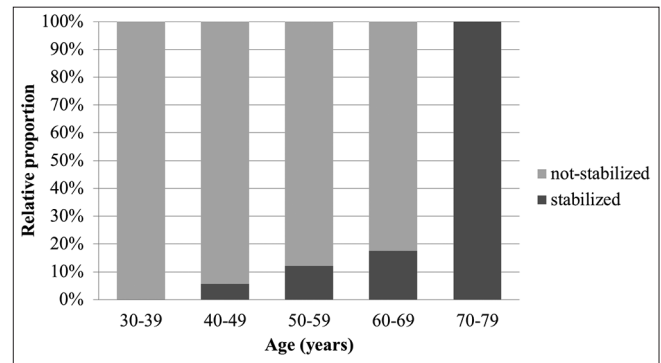


Figure 3: Graph showing the relative proportion of stabilized aneurysm in each age group increased significantly as the age increased ($P < 0.001$)

Table 2: Logistic regression analysis for stabilized intracranial aneurysms according to demographic and aneurysmal characteristics

	Univariate analysis (P)	OR (95% CI)	Multivariate analysis (P)	OR (95% CI)
Age ≥ 65 years	<0.001	5.903 (2.385-14.611)	0.009	3.821 (1.389-10.514)
Male	0.973	1.014 (0.457-2.251)	0.760	1.158 (0.451-2.972)
Hypertension	0.012	2.828 (1.258-6.358)	0.041	2.480 (1.038-5.927)
Diabetes	0.007	3.733 (1.425-9.779)	0.087	2.642 (0.869-8.304)
Smoking	0.240	3.418 (0.439-26.579)	0.474	2.234 (0.248-20.141)
D _{max} ≥ 5 mm	0.165	1.724 (0.799-3.720)	0.887	1.069 (0.426-2.685)
Height ≥ 3 mm	0.007	3.635 (1.421-9.295)	0.018	3.594 (1.245-10.373)

D_{max}: Maximum diameter

found that the relative proportion of stabilized aneurysms significantly increased as age increased and age showed a positive relationship with stabilized aneurysms. In older patients (≥ 65 years of age), diabetes remained the only independent factor predicting stabilized aneurysms.

Aneurysm wall thickness and rupture risk

Several studies reported that thin portion of aneurysm dome correlated with the point of rupture and clearly defined foci of translucency suggest focal weakness by influencing local stiffness and predisposes these regions to rupture.^[37] Aneurysms with hypertrophied and stiff atherosclerotic walls^[29] appear more resistant to hemodynamic pressure than aneurysms with super thin foci. An aneurysm ruptures when the balance between local high hemodynamic stresses and vascular wall strength is disrupted. Intense physical activities and accompanying high blood pressure have been associated with an increased risk of aneurysm rupture.^[34] Elevation in mean arterial blood pressure during such activities can increase aneurysm wall tension and if the aneurysm wall cannot withstand it, aneurysm ruptures. Aneurysms with hypertrophied and stiff atherosclerotic walls^[29,38] appear more resistant to hemodynamic pressure than aneurysms with very thin walls. In histologic assessments, Kataoka *et al.*^[24] found that thick intima-like walls were mostly unruptured and very thin and degenerated walls with hyaline deposits mostly ruptured. Frösen *et al.*^[13] identified histologically four aneurysm wall types. Aneurysms with thin, hyalinized, and hypocellular walls showed a 100% rupture rate and aneurysms with organized smooth muscle cells showed a 42% rupture rate. Our evaluation of 26 ruptured aneurysms, although limited due to obscuration by blood, showed that only one patient had an aneurysm with atherosclerotic wall.

Patient age and aneurysm size

Despite intensive research, the pathogenesis of IA remains unclear but can be related to the mechanisms of atherosclerosis.^[26] Killer-Oberpfalzer *et al.*^[25] and Kosierkiewicz *et al.*^[26] found that atherosclerotic lesions were present in all saccular IAs. In small aneurysms, atherosclerotic lesions were characterized by diffuse intimal thickening with minimal inflammatory cell infiltration and large aneurysms had advanced atherosclerotic lesions with more extensive macrophage, lymphocyte, and natural killer cell infiltration. There were no data to prove the time-dependent changes of atherosclerotic aneurysm walls. This study lacked sequential observation with time but showed that age was correlated positively with atherosclerotic aneurysm walls and the relative proportion of aneurysms increased with age. Age remained a risk factor in multivariate analysis with morphological and other risk factors. In dichotomized analysis, age ≥ 65 years was an independent risk factor for stabilized aneurysms. For the morphological

parameters, height was correlated positively with atherosclerotic aneurysmal walls. These results suggest that progression of atherosclerosis within the aneurysmal sac correlated positively with aneurysmal growth over time.

Diabetes mellitus and hypertension as risk factors

Atherosclerosis and aneurysm formation share similar risk factors including smoking and hypertension.^[29] DM is a well-known risk factor of atherosclerosis. Our data showed that hypertension ($P = 0.041$; OR, 2.480) was an independent risk factor of atherosclerotic aneurysm walls in multivariate analysis for all age groups and DM ($P = 0.027$; OR, 29.435) was the only remaining risk factor after stratification by age.

DM plays an important role in the pathogenesis of atherosclerosis but has not been sufficiently investigated to suggest its role in aneurysm formation or rupture. DM induces vascular endothelial damage and dysfunction, decreases cerebral tight junction protein expression, and^[47] promotes artery intima-media thickness and atherosclerotic vascular disease. Endothelial damage^[40] and reduction of tight junction protein expression are also related with cerebral aneurysm formation.^[36] Yan *et al.*^[46] showed in an *in vitro* study that Type I DM promotes the formation of IAs and atherosclerosis-like changes induced by increasing levels of inflammatory mediators including receptor of advanced glycation end-product, matrix metalloproteinase 9, degrades Type IV collagen, the main constituent of the basement membrane, contributes to the development of vascular lesions and toll-like receptor 4, and proinflammatory factors. However, in clinical studies, DM does not predispose the development or rupture of saccular aneurysms^[9,12,15,27] and patients with aneurysmal subarachnoid hemorrhage have a lower or equivalent prevalence of DM than the general population.^[1,12,15] Inagawa^[21] reported that DM is related to a decreased risk of aneurysm rupture in patients 60 years of age or older. The mechanisms responsible for this negative association remain unknown. Our data showed that DM was highly correlated with atherosclerotic, stabilized aneurysms ($P = 0.010$) and was the only independent factor in older patients (≥ 65 years of age). Based on the hypothesis that aneurysms with atherosclerotic walls are stabilized aneurysms, the negative relationships between aneurysm rupture and DM can be explained.

Hypertension is a well-known risk factor for atherosclerosis and is considered a risk factor for aneurysm formation and rupture.^[39] Hypertension may weaken the aneurysm wall directly by increasing mechanical stresses and indirectly by causing vascular inflammation and remodeling^[31] through activation of the local renin-angiotensin system. Previous studies showed a link between the

formation of IA and systemic hypertension^[17-19,30] but the relationship between IA rupture and hypertension has not been fully established in either experimental or clinical studies. Tada *et al.*^[39] showed that normalization of blood pressure with antihypertensive medication did not prevent aneurysm formation but prevented rupture after aneurysm formation in mice. In several clinical studies, hypertension was not associated with aneurysm rupture.^[22,43,44] The conflicting findings may be due to the majority of patients with hypertension are treated with antihypertensive agents and as a result, these patients tend to have normal blood pressure at the time of aneurysm diagnosis. Our results showed that hypertension was related to stabilized, atherosclerotic aneurysm walls but the association did not remain after stratification by age. Hypertension may play a role in the pathogenesis of atherosclerosis and aneurysm stabilization.

Advance in knowledge and clinical implications

To the best of our knowledge, this is the first report investigating clinical and morphological characteristics of atherosclerotic lesions in IAs and the first attempt to identify factors associated with aneurysm stabilization. Age ($P = 0.002$; OR, 1.105) showed a positive trend with atherosclerotic aneurysm walls and DM ($P = 0.027$; OR, 29.435) was the only factor predicting stabilized aneurysms in older patients.

The positive association of age and atherosclerotic aneurysm walls suggest the aneurysm may progress with atherosclerotic changes over time and may help to predict the natural history of the aneurysm. The suggested parameters for predicting aneurysm stabilization can help in determining treatment strategy when an unruptured aneurysm is found incidentally. First, the parameters can help in deciding whether to treat or not, especially in elderly patients who have a short life expectancy and usually a higher morbidity rate under general anesthesia. Second, the parameters can help estimate the potential risk of treatment because atherosclerotic aneurysms usually have a higher risk of intraoperative ischemia^[10] during clipping surgery or may have a higher risk of perioperative embolic complications with endovascular treatment.

Limitations

The first limitation of this study is the uncertainty whether aneurysms with atherosclerotic walls are stabilized in terms of rupture because the natural history or the rupture mechanism of the aneurysm is unknown. Moreover, there are no large and prospective data showing aneurysm wall morphology and rupture risk. Instead, there are studies that thin portion of aneurysm dome correlated with the point of rupture.^[37] An aneurysm ruptures when the local hemodynamic stresses exceed vascular wall strength and aneurysms with hypertrophied atherosclerotic walls^[29] appear more resistant to hemodynamic pressure than aneurysms with

a thin wall. To support our hypothesis, we evaluated the intraoperative videos of 31 ruptured aneurysms and only one patient was suspected to have an atherosclerotic wall and did not have a transparent wall. The second limitation is that this analysis was based on intraoperative findings and included only surgical cases. Unclippable, very small-sized aneurysms were excluded and the study mainly included aneurysms involving anterior circulation, particularly the middle cerebral artery. Third, intraoperative microscopy did not allow circumferential visualization of the entire aneurysm dome in some cases. Translucent portions on the opposite side may be neglected. To minimize this possibility, we excluded the aneurysm which did not exposed <50%. However, this exclusion may produce a biased sample. Fourth, the number of patients in not-stabilized aneurysm was much more than the number in stabilized aneurysm (176 vs. 31), and it might impact comparability.

CONCLUSIONS

Based on the hypothesis that aneurysms with atherosclerotic walls are stabilized aneurysms, we revealed the relative proportion of stabilized aneurysms increased significantly as age increased. In addition, in older patients, DM was the only factor predicting aneurysm stabilization. These results provide useful information for determining treatment and follow-up strategies, especially in elderly patients.

Financial support and sponsorship

Nil.

Conflicts of interest

There are no conflicts of interest.

REFERENCES

1. Adams HP Jr., Putman SF, Kassell NF, Torner JC. Prevalence of diabetes mellitus among patients with subarachnoid hemorrhage. *Arch Neurol* 1984;41:1033-5.
2. Bacigaluppi S, Piccinelli M, Antiga L, Veneziani A, Passerini T, Rampini P, *et al.* Factors affecting formation and rupture of intracranial saccular aneurysms. *Neurosurg Rev* 2014;37:1-14.
3. Baharoglu MI, Lauric A, Gao BL, Malek AM. Identification of a dichotomy in morphological predictors of rupture status between sidewall- and bifurcation-type intracranial aneurysms. *J Neurosurg* 2012;116:871-81.
4. Bekelis K, Missios S, MacKenzie TA, Desai A, Fischer A, Labropoulos N, *et al.* Predicting inpatient complications from cerebral aneurysm clipping: The Nationwide Inpatient Sample 2005-2009. *J Neurosurg* 2014;120:591-8.
5. Bijlenga P, Ebeling C, Jaegersberg M, Summers P, Rogers A, Waterworth A, *et al.* Risk of rupture of small anterior communicating artery aneurysms is similar to posterior circulation aneurysms. *Stroke* 2013;44:3018-26.
6. Brisman JL, Song JK, Newell DW. Cerebral aneurysms. *N Engl J Med* 2006;355:928-39.
7. Cebra JR, Mut F, Weir J, Putman CM. Association of hemodynamic characteristics and cerebral aneurysm rupture. *AJNR Am J Neuroradiol* 2011;32:264-70.
8. Crompton MR. Mechanism of growth and rupture in cerebral berry aneurysms. *Br Med J* 1966;1:1138-42.
9. Damsgaard EM, Frøland A, Green A, Hauge M. An alternative sampling

- approach to the study of diabetes prevalence. *Scand J Soc Med* 1984;12:115-20.
10. D'Andrea V, Cantisani V, Catania A, Todini A, Stio F, Di Matteo FM, et al. Angiomegaly and arterial aneurysms. *G Chir* 2010;31:429-32.
 11. Dhar S, Tremmel M, Mocco J, Kim M, Yamamoto J, Siddiqui AH, et al. Morphology parameters for intracranial aneurysm rupture risk assessment. *Neurosurgery* 2008;63:185-96.
 12. Feigin VL, Rinkel GJ, Lawes CM, Algra A, Bennett DA, van Gijn J, et al. Risk factors for subarachnoid hemorrhage: An updated systematic review of epidemiological studies. *Stroke* 2005;36:2773-80.
 13. Frösen J, Piippo A, Paetau A, Kangasniemi M, Niemelä M, Hernesniemi J, et al. Remodeling of saccular cerebral artery aneurysm wall is associated with rupture: Histological analysis of 24 unruptured and 42 ruptured cases. *Stroke* 2004;35:2287-93.
 14. Gabriel RA, Kim H, Sidney S, McCulloch CE, Singh V, Johnston SC, et al. Ten-year detection rate of brain arteriovenous malformations in a large, multiethnic, defined population. *Stroke* 2010;41:21-6.
 15. Greenhalgh RM, Laing S, Taylor GW. Risk factors in carotid artery stenosis and intracranial aneurysms. *J Cardiovasc Surg (Torino)* 1980;21:559-67.
 16. Greving JP, Wermer MJ, Brown RD Jr., Morita A, Juvela S, Yonekura M, et al. Development of the PHASES score for prediction of risk of rupture of intracranial aneurysms: A pooled analysis of six prospective cohort studies. *Lancet Neurol* 2014;13:59-66.
 17. Hashimoto N, Handa H, Hazama F. Experimentally induced cerebral aneurysms in rats. *Surg Neurol* 1978;10:3-8.
 18. Hashimoto N, Handa H, Hazama F. Experimentally induced cerebral aneurysms in rats: Part II. *Surg Neurol* 1979;11:243-6.
 19. Hashimoto T, Meng H, Young WL. Intracranial aneurysms: Links among inflammation, hemodynamics and vascular remodeling. *Neurol Res* 2006;28:372-80.
 20. Hoh BL, Siström CL, Firment CS, Fautheree GL, Velat GJ, Whiting JH, et al. Bottleneck factor and height-width ratio: Association with ruptured aneurysms in patients with multiple cerebral aneurysms. *Neurosurgery* 2007;61:716-22.
 21. Inagawa T. Risk factors for the formation and rupture of intracranial saccular aneurysms in Shimane, Japan. *World Neurosurg* 2010;73:155-64.
 22. Juvela S, Porras M, Heiskanen O. Natural history of unruptured intracranial aneurysms: A long-term follow-up study. *J Neurosurg* 1993;79:174-82.
 23. Kashiwazaki D, Kuroda S; Sapporo SAH Study Group. Size ratio can highly predict rupture risk in intracranial small (<5 mm) aneurysms. *Stroke* 2013;44:2169-73.
 24. Kataoka K, Taneda M, Asai T, Kinoshita A, Ito M, Kuroda R. Structural fragility and inflammatory response of ruptured cerebral aneurysms. A comparative study between ruptured and unruptured cerebral aneurysms. *Stroke* 1999;30:1396-401.
 25. Killer-Oberpfalzer M, Aichholzer M, Weis S, Richling B, Jones R, Virmani R, et al. Histological analysis of clipped human intracranial aneurysms and parent arteries with short-term follow-up. *Cardiovasc Pathol* 2012;21:299-306.
 26. Kosierkiewicz TA, Factor SM, Dickson DW. Immunocytochemical studies of atherosclerotic lesions of cerebral berry aneurysms. *J Neuropathol Exp Neurol* 1994;53:399-406.
 27. Lindgren AE, Kurki MI, Riihinen A, Koivisto T, Ronkainen A, Rinne J, et al. Type 2 diabetes and risk of rupture of saccular intracranial aneurysm in eastern Finland. *Diabetes Care* 2013;36:2020-6.
 28. Loumriotis I, Wagenbach A, Brown RD Jr, Lanzino G. Small (< 10-mm) incidentally found intracranial aneurysms, Part I: Reasons for detection, demographics, location, and risk factors in 212 consecutive patients. *Neurosurg Focus* 2011;31:E3.
 29. Maltete D, Bellien J, Cabrejo L, Iacob M, Proust F, Mihout B, et al. Hypertrophic remodeling and increased arterial stiffness in patients with intracranial aneurysms. *Atherosclerosis* 2010;211:486-91.
 30. Morimoto M, Miyamoto S, Mizoguchi A, Kume N, Kita T, Hashimoto N. Mouse model of cerebral aneurysm: Experimental induction by renal hypertension and local hemodynamic changes. *Stroke* 2002;33:1911-5.
 31. Muller M, van den Beld AW, Bots ML, Grobbee DE, Lamberts SW, van der Schouw YT. Endogenous sex hormones and progression of carotid atherosclerosis in elderly men. *Circulation* 2004;109:2074-9.
 32. Nagamine Y. Natural history and management of asymptomatic unruptured cerebral aneurysms. *Rinsho Shinkeigaku* 2004;44:763-6.
 33. Raghavan ML, Ma B, Harbaugh RE. Quantified aneurysm shape and rupture risk. *J Neurosurg* 2005;102:355-62.
 34. Reynolds MR, Willie JT, Zipfel GJ, Dacey RG. Sexual intercourse and cerebral aneurysm rupture: Potential mechanisms and precipitants. *J Neurosurg* 2011;114:969-77.
 35. Rinkel GJ, Djibuti M, Algra A, van Gijn J. Prevalence and risk of rupture of intracranial aneurysms: A systematic review. *Stroke* 1998;29:251-6.
 36. Sato A, Watanabe S, Okubo S, Toi T, Doi T, Nakano H, et al. The therapeutic importance of home blood pressure assessment and combination antihypertensive therapy for achieving target blood pressure control: Ibaraki hypertension assessment trial. *Hypertens Res* 2010;33:1264-71.
 37. Song J, Park JE, Kim HR, Shin YS. Observation of cerebral aneurysm wall thickness using intraoperative microscopy: Clinical and morphological analysis of translucent aneurysm. *Neurol Sci* 2015;36:907-12.
 38. Starke RM, Chalouhi N, Ding D, Raper DM, Mckisic MS, Owens GK, et al. Vascular smooth muscle cells in cerebral aneurysm pathogenesis. *Transl Stroke Res* 2014;5:338-46.
 39. Tada Y, Wada K, Shimada K, Makino H, Liang EI, Murakami S, et al. Roles of hypertension in the rupture of intracranial aneurysms. *Stroke* 2014;45:579-86.
 40. Tamura T, Jamous MA, Kitazato KT, Yagi K, Tada Y, Uno M, et al. Endothelial damage due to impaired nitric oxide bioavailability triggers cerebral aneurysm formation in female rats. *J Hypertens* 2009;27:1284-92.
 41. UCAS Japan Investigators, Morita A, Kirino T, Hashi K, Aoki N, Fukuhara S, et al. The natural course of unruptured cerebral aneurysms in a Japanese cohort. *N Engl J Med* 2012;366:2474-82.
 42. Vlak MH, Algra A, Brandenburg R, Rinkel GJ. Prevalence of unruptured intracranial aneurysms, with emphasis on sex, age, comorbidity, country, and time period: A systematic review and meta-analysis. *Lancet Neurol* 2011;10:626-36.
 43. Wiebers DO, Whisnant JP, O'Fallon WM. The natural history of unruptured intracranial aneurysms. *N Engl J Med* 1981;304:696-8.
 44. Wiebers DO, Whisnant JP, Sundt TM Jr., O'Fallon WM. The significance of unruptured intracranial saccular aneurysms. *J Neurosurg* 1987;66:23-9.
 45. Wiebers DO, Whisnant JP. Rupture of an intracranial aneurysm. *Surg Neurol* 1990;33:157-8.
 46. Yan T, Chopp M, Ning R, Zacharek A, Roberts C, Chen J. Intracranial aneurysm formation in type-one diabetes rats. *PLoS One* 2013;8:e67949.
 47. Ye X, Chopp M, Cui X, Zacharek A, Cui Y, Yan T, et al. Niaspan enhances vascular remodeling after stroke in type I diabetic rats. *Exp Neurol* 2011;232:299-308.