

## Original Article

# Management strategies for neoplastic and vascular brain lesions presenting during pregnancy: A series of 29 patients

Celestino Esteves Pereira, Jose Carlos Lynch

Neurosurgical and Obstetrics Departments of Servidores do Estado Hospital, RJ, Brazil

E-mail: Celestino Pereira - [celestino.pereira@br.inter.net](mailto:celestino.pereira@br.inter.net); \*Jose Carlos Lynch - [Jclynch@globo.com](mailto:Jclynch@globo.com)

\*Corresponding author

Received: 27 May 16 Accepted: 12 December 16 Published: 20 February 17

## Abstract

**Background:** The occurrence of a brain tumor or intracranial vascular lesion during pregnancy is a rare event, but when it happens, it jeopardizes the lives of both the mother and infant. It also creates challenges of a neurosurgical, obstetric, and ethical nature. A multidisciplinary approach should be used for their care.

**Methods:** Between 1986 and 2015, 12 pregnant women diagnosed with brain tumors and 17 women with intracranial vascular lesion underwent treatment at the Neurosurgery Department of the Servidores do Estado Hospital and Rede D'Or/São Luis. The Neurosurgery Department teamed up with Obstetrics Anesthesiology Departments in establishing the procedures. The patients' records, surgical descriptions, imaging studies, and histopathological material were reviewed.

**Results:** Among 12 patients presenting with brain tumors, there were neither operative mortality nor fetal deaths. Among the vascular lesions, aneurysm rupture was responsible for bleeding in 6 instances. Arteriovenous malformation was diagnosed in 7 patients. In this subgroup, the maternal and fetal mortality rates were 11.7% and 23.7%, respectively.

**Conclusions:** We can assert that the association between a brain tumor and vascular lesions with pregnancy is a very unusual event, which jeopardizes both the lives of the mother and infant. It remains incompletely characterized due to the rare nature of these potentially devastating events. Knowing the exact mechanism responsible for the interaction of pregnancy and with these lesions will improve the treatment of these patients.

**Key Words:** Arteriovenous malformation, brain tumor, cerebral aneurysm, pregnancy

### Access this article online

**Website:**[www.surgicalneurologyint.com](http://www.surgicalneurologyint.com)**DOI:**

10.4103/2152-7806.200575

**Quick Response Code:**

## INTRODUCTION

The occurrence of a brain tumor or intracerebral hemorrhage during pregnancy poses risks to both the mother and infant, and presents unique challenges to the neurosurgeon. There are few data on the risks of pregnancy in women with these diseases and no clear guidelines regarding its management during pregnancy, delivery, and puerperium.<sup>[6,12,13,20,32,38,39,40]</sup> This study aims

This is an open access article distributed under the terms of the Creative Commons Attribution-NonCommercial-ShareAlike 3.0 License, which allows others to remix, tweak, and build upon the work non-commercially, as long as the author is credited and the new creations are licensed under the identical terms.

**For reprints contact:** [reprints@medknow.com](mailto:reprints@medknow.com)

**How to cite this article:** Pereira CE, Lynch JC. Management strategies for neoplastic and vascular brain lesions presenting during pregnancy: A series of 29 patients. *Surg Neurol Int* 2017;8:27.

<http://surgicalneurologyint.com/Management-strategies-for-neoplastic-and-vascular-brain-lesions-presenting-during-pregnancy--A-series-of-29-patients/>

at identifying the best medical and surgical procedures to be followed for a pregnant patient harboring a brain tumor or an intracranial vascular lesion.

## MATERIALS AND METHODS

### Data collection

A retrospective study was performed to evaluate 29 pregnant patients with concomitant intracranial lesions treated between January 1986 and January 2015. We will analyze the two groups of patient's separately; 12 consecutive pregnant women diagnosed with brain tumors and 17 patients with vascular lesion underwent treatment in the Neurosurgery Department at the authors' institutions. The Obstetrics Department of Hospital Federal dos Servidores do Estado (HFSE) is a reference center for high-risk pregnant patients in the city of Rio de Janeiro. All the postoperative care was carried out at the intensive care unit (ICU), a unit with a long history of high-risk pregnancy management. Medical records, surgical descriptions, imaging studies, and the histopathological material were reviewed, thereby creating a database from which information pertinent to the present study was collected. The intraoperative videos and/or photos of 15 patients were analyzed for nuances of the microsurgical technique. The Neurosurgery Department teamed up with Obstetrics, Psychology, and Anesthesiology Departments, as well as with families and patients themselves, for establishing the procedures. The need for informed consent was waived due to the retrospective nature of the study. The first visit in the pediatric, obstetric, and neurosurgery clinics was approximately 15 days after hospital discharge and then after 2 and 6 months, and thereafter, patients were reexamined at 1-year intervals until the fifth postoperative year. The Glasgow Outcome Scale (GOS) defined the neurological outcome. The meningiomas and astrocytomas tumors grading are consistent with the World Health Organization (WHO) classification.

In this series, we performed 9 craniotomies during pregnancy (5 for tumors and 4 for vascular lesions). In all cases, a meticulous neurosurgical dissection with microsurgical removal of the tumor or aneurysms occlusion was successfully carried out without any deleterious effect on the mother or baby. However, a number of special cautionary steps were taken:

- *Operative Positioning* – The pregnant uterus should not compress the inferior vena cava because this leads to a decrease in the venous return, causing arterial hypotension and shock. The dorsal decubitus position, with a trunk rotation to the left, leaned on a roll, prevents aortocaval compression. When the lesion is located on the posterior fossa, the ventral decubitus position is disallowed
- *Anesthesia* – Anesthetic consideration involves safety of the mother and fetus. Nitrous oxide is teratogenic

in humans and should be avoided. Hyperventilation was used to diminish cerebral blood volume and to facilitate surgical exposure. A PaCO<sub>2</sub> between 28 and 30 mmHg is sufficient to maintain adequate surgical conditions, without interfering in fetal oxygenation. Induced arterial hypotension aiming at reducing bleeding must be cautiously used. When the intraoperative fetal monitoring reveals fetal suffering caused by arterial hypotension or hypoxia, it is the precise moment for the systemic arterial pressure to be adjusted. The use of Mannitol between 0.5 and 1 g/kg does not usually cause adverse effects to the hydric balance of the fetus

- *Medications* – Corticosteroids were cautiously prescribed during pregnancy to control cerebral edema and intracranial hypertension, as well as to accelerate pulmonary fetal maturity. Their prolonged use during pregnancy may result in neonatal hypoadrenalism. Convulsion causes hypoxia and fetal acidosis, and therefore, anticonvulsants' benefits are probably greater than the possible teratogenic effects and they were used either for treatment or prophylaxis in patients at risk of developing a convulsive crisis. The anticonvulsants should be closely monitored during pregnancy and puerperium.

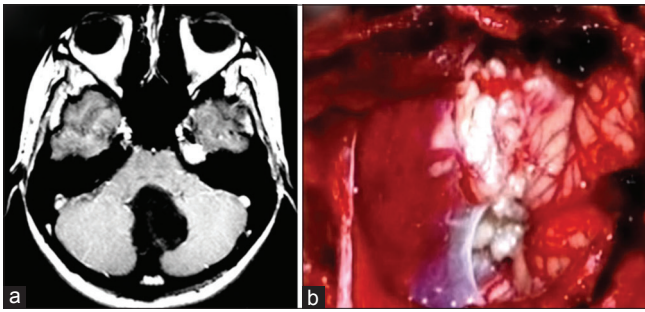
## RESULTS

### Neoplastic lesions

There were 12 patients with ages varying from 25 to 37 years (average, 31 years). The gestational age varied from 16 to 40 weeks (average, 29.7 weeks). The symptoms, location of the tumors, surgical resection extension, and other pertinent information are presented in Table 1. The 12 pregnant patients underwent a neurosurgical intervention, and no surgical maternal death occurred in this series. One patient diagnosed with metastatic melanoma died due to melanoma dissemination, 8 months following craniotomy. No fetal deaths were observed. Eight patients had cesarean section (CS) deliveries prior to craniotomy, 3 others had vaginal deliveries (VD) during the postoperative period, and in one woman, a spontaneous abortion occurred. In this sample, histological diagnosis revealed 4 grade 2 astrocytomas, all of which had a gross total removal (GTR). Three patients (75%) developed dedifferentiation varying from 12 to 46 months; and 2 of them died during the follow-up period. We also detected 1 grade 2 oligodendroglioma, 3 grade 1 meningiomas, 1 melanoma metastasis, 1 epidermoid tumor [Figure 1a and b]; 1 case of chemodectoma and 1 patient with a pituitary apoplexy in a non-function adenoma.

### Vascular lesions

The patients' ages varied from 17 to 39 years (average, 28 years). Six patients harbored intracranial aneurysms,



**Figure 1: (a) Axial T1-weighted MRI image revealing hypointense lesion located in the cerebellar vermis with invasion of the four ventricule. (b) Operative view showing epidermoid tumor in the magnum cistern. The patient was operated on after CS during the 38<sup>th</sup> gestational week in a semi-sitting position**

6 harbored AVMs, and 1 patient presented cerebral cavernous malformation (CCM) [Figures 2-4]. We diagnosed 4 patients with eclampsia. In 8 women, the hemorrhage occurred in the second trimester, in 7 in the third trimester of pregnancy, and in 2 individuals during the puerperal period. We did not detect a single case of intracranial hemorrhage in the first trimester of the pregnancy. In our series, 5 patients underwent microsurgical repair of their aneurysms during pregnancy. In this series, 3 patients with grade-3 AVMs were allowed to carry the pregnancy to term, followed by elective operations of the AVMs. They had complete obliteration of the AVMs confirmed by postoperative angiography. No adverse outcomes were observed in this group. One patient with intraventricular hematoma and with Spetzler–Martin grade 1 AVM was operated on during pregnancy and showed an excellent result [Figure 3a-d]. We recommended conservative management for 2 grade 5 AVMs patients. Another patient with an occipital grade 3 AVM received radiosurgery, following a term delivery with excellent result. No maternal deaths were observed in this group. CS was ordered in 47% of the cases and VD in 17,6%.

Two patients, although undergoing prompt surgical removal of massive intracerebral hematomas, had an unfavorable evolution. Among the 4 patients with eclampsia, two died due to aspiration complication and sepsis. We documented 6 fetal deaths. The presenting symptoms and other clinical features are summarized in Table 2.

## DISCUSSION

Neoplastic and vascular lesions in pregnant patients have some features in common along with some differences; understanding these differences and nuances is essential to choose the most appropriate medical treatment for these patients.

### Neoplastic lesions

The occurrence of a brain tumor during pregnancy is a rare event.<sup>[12,13,29,27,16,31,32,39,40]</sup> Isla *et al.*<sup>[19]</sup> observed

**Table 1: Demographic features, histopathological types and results of 12 pregnant patients with brain tumors**

Age at treatment: 17 - 35 years (mean, 24.5 years)

Symptoms:

Headache: 7 (58.3%)

Hemiparesis: 5 (41.6%)

Blindness: 2 (16.6%)

Seizure: 2 (16.6%)

Delivery:

CS: 8 patients (66.6%)

VD: 4 patients (33.3%)

Delivery in relation to surgery

Before: 7 patients (58.3%)

After: 5 patients (41.6%)

Histological variants:

Astrocytomas: 4

Meningiomas: 3

Melanoma metastasis: 1

Pituitary adenoma: 1

Epidermoid: 1

Chemodectoma: 1

Oligodendroglioma: 1

GOS 4 and 5: 9 (76.4%)

**Table 2: Demographic features, etiology, and results of 17 pregnant patients with vascular brain lesions**

Age at treatment: 17 - 39 years (mean, 24.5 years)

Etiology:

MAV: 7 (41.1%)

Aneurysm: 6 (35.2%)

Eclampsia: 4 (23.5%)

Mortality:

Maternal: 2 (11.7%)

Fetal: 6 (23.5%)

Type of delivery:

CS: 8 (47.0%)

VD: 3 (17.6%)

Abortion: 6 (35.2%)

Delivery in relation to surgery:

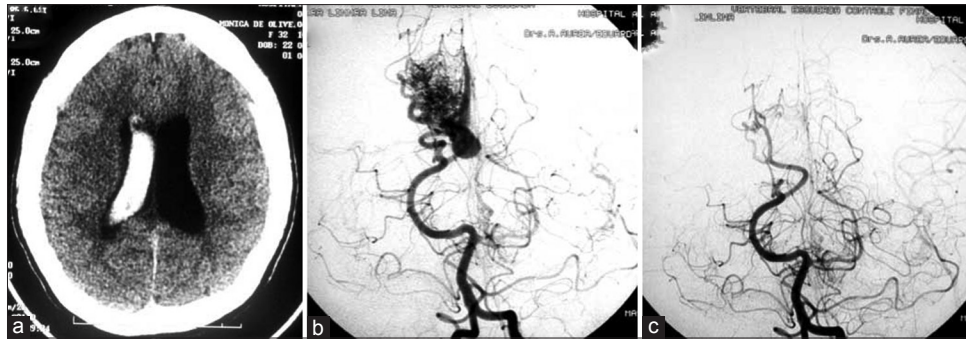
Before: 9 (52.9%)

After: 4 (23.5%)

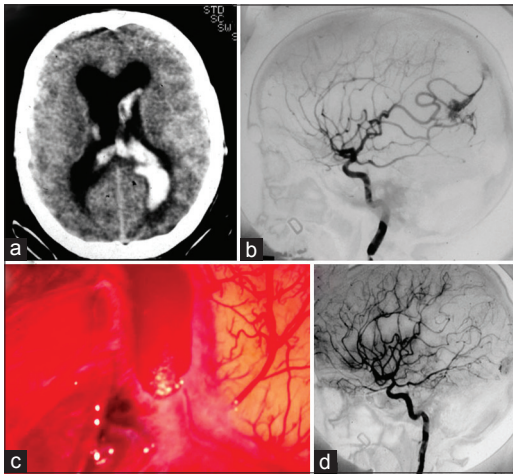
Clinical treatment: 4 (23.5%)

GOS: 4 and 5: (88.2%)

only 7 women with brain tumor in a series of 126,413 pregnancies. In addition to putting at risk the lives of both the mother and infant, this association represents a real therapeutic challenge.<sup>[6,12,13,20,32,38,39,40]</sup> It is, therefore, fundamental that a multidisciplinary care team approach be established.<sup>[7,6,32,39,40]</sup> Different histological types of brain tumors associated with pregnancy were described.<sup>[6,12,13,20,26,29,30,36,37,39,40]</sup> In this series as well as in others,<sup>[6,12,20,32,37,39]</sup> the gliomas were the most prevalent



**Figure 2: (a) Axial CT scans showing a left intraventricular hemorrhage in a third trimester pregnancy patient. (b) Cerebral angiography detected a large AVM fed by the posterior cerebral artery. (c) Angiography post-radiosurgery done after delivery showing complete AVM occlusion**



**Figure 3: (a) Axial CT scans detecting a right intraventricular hematoma in a second trimester pregnant patient. (b) Cerebral angiography revealed a small AVM fed by the angular artery. (c) Operative image displaying a large draining vein. (d) Postoperative angiography showing the complete exclusion of the lesion. The surgery was performed during pregnancy**

histological type; the meningiomas were the second more frequent. In our material, four cases of astrocytomas were detected. Three of them (75%) developed dedifferentiation in the mean period of 27 months. This suggests that sex hormones occurring during gestation may have an effect on tumor growth, recurrence, and dedifferentiation.<sup>[24,28]</sup> Blaauw *et al.*<sup>[4]</sup> studied 67 meningiomas and they found progesterone receptor (PR) in more than 80% of the specimens. Hsu *et al.*<sup>[18]</sup> and Lesch and Fahlbusch<sup>[25]</sup> reported nuclear staining for PR of the material examined in 83% and 76%, respectively. These studies suggest that meningiomas may be targets of the progesterone action, which would explain the development, and even the appearance, of meningiomas during gestation.<sup>[15,27]</sup> Otherwise, Erik *et al.*<sup>[14]</sup> believe that the rapid tumor growth that occurs in some meningiomas is more often due to water retention and engorgement of the intracranial vessels rather than hormone-induced cellular proliferation.

Treatment should always preserve the mother's life and, secondarily, the life of the embryo. Analyzing the

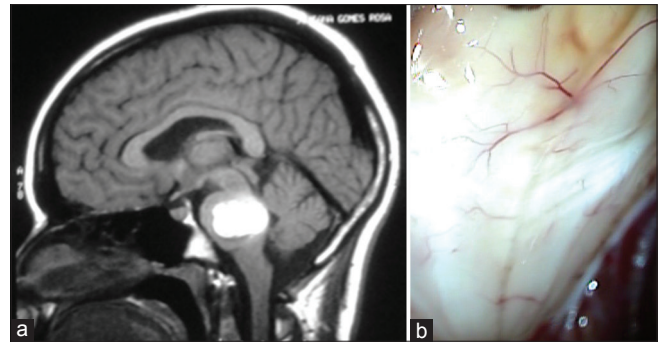
mentioned factors, we could establish five different clinical scenarios:

- If the patient presents stable neurological conditions, the neurosurgery may be deferred until gestational period reaches the 30<sup>th</sup> week. After that, the delivery can be either a VD or a CS, depending exclusively on the obstetric criteria. The craniotomy in this situation is an elective procedure to be performed after the delivery. This was the case of 3 patients
- If the patient presents with brain edema, but is neurologically stable, cortisone is prescribed to control the cerebral edema as well as to accelerate fetal lung maturity. When the fetus lungs are mature, delivery is performed, followed by an elective craniotomy for tumor removal. This was the procedure for 2 patients
- If aggravation of neurological symptoms occurs during the fetal maturation period, craniotomy is performed immediately. CS is done just before or after craniotomy. This was an alternative for 1 patient
- When the patient presents with sudden or severe neurological conditions or has intracranial hypertension, surgery is immediately performed to save the life of the mother. Both gestation and delivery will have routine postoperative follow-up. This was the case of 3 patients
- If a malignant glioma is suspected, a microsurgical tumor removal should be performed as soon as possible, regardless of gestational age, and not delayed until the postpartum period with risk of disease progression in the meantime.<sup>[12,20]</sup> If adjuvant chemotherapy is to be ordered and gestation is in the first trimester, therapeutic abortion can be considered because chemotherapy may cause severe damage to the formation of the fetus. Brain radiotherapy can be cautiously utilized in cases of high-grade gliomas. The use of additional shielding is valuable.<sup>[12,13,20]</sup> We strongly advocate multidisciplinary counsel to individualize and optimize the decision-making process. We believe that pregnant women with brain tumors can be treated just as effectively as non-pregnant women.

## Vascular lesions

SAH is rare among pregnant women and the occurrence rate varies from 0.002 to 0.05% of all pregnancies.<sup>[2,5,7,8,10,11,31,32,34]</sup> Intracranial hemorrhage is responsible for 4–12% of all maternal deaths during pregnancy.<sup>[1,3,8,35]</sup> Maternal mortality may be as high as 35% to 80% for aneurysmal and 28% for AVM-related hemorrhages.<sup>[5,7,11,34,35]</sup> There is an increased propensity for aneurysms bleeding with advancing gestational age. The association between hemodynamic changes during pregnancy and intracranial hemorrhage probably occurs because of maternal blood volume, arterial blood pressure, and venous pressure progressively increasing during pregnancy, reaching the maximum at the end of the third trimester.<sup>[5,11,34,35]</sup> In our material, in all 6 patients, subarachnoid hemorrhage secondary to rupture cerebral aneurysm occurred in the second trimester of gestation. Only 10% of our aneurysms bled in the first trimester, however, none in this series. Surprisingly, it is very unusual to observe aneurysm rupture during labor.<sup>[3]</sup> Dias and Sekhar<sup>[10]</sup> reviewed treatment of 106 pregnant patients with aneurysms brain hemorrhage. In their surgical group, the maternal mortality rate was 11%, while in the conservative treatment group, it was 63%. They concluded that surgical treatment is superior to the clinical treatment and recommended surgery, regardless of the pregnancy stage. Pool<sup>[33]</sup> and Robison *et al.* among others follow the same principles.<sup>[1,5]</sup> In our series, 6 patients underwent microsurgical repair of their aneurysms during pregnancy. No maternal deaths were observed in this group. In our sample, CS occurred in 47% of the cases and VD in 17.6%. Kim *et al.*<sup>[23]</sup> observed that CS in pregnant patients with aneurysms is significantly higher than in the general population. The usual microsurgical techniques should be employed, however, inducing hypotension during dissection or clipping of the aneurysm should be avoided. One should preferably utilize the temporary arterial clipping for dissection and final aneurysm occlusion. Endovascular occlusion of the aneurysm is an attractive alternative for aneurysm treatment, however, this was not used in this series.

The appropriate treatment in pregnant patients with MAV is conflicting.<sup>[10,16,17,22,23,33]</sup> Horton *et al.*<sup>[17]</sup> studied 343 MAVs patients and concluded that pregnancy does not increase the risk of bleeding. Others surgeons claim an opposite view.<sup>[33]</sup> Dias and Sekhar<sup>[10]</sup> reviewed 35 cases in the literature of intracranial hemorrhage from AVMs, and observed that maternal mortality rate was the same after surgical or clinical treatment, concluding that the treatment should be elected on a case-by-case basis. The appropriate delivery for gravid patients with untreated AVMs remains undefined, given the small sample size in published series. Robinson *et al.*<sup>[33]</sup> advocate CS at the 38<sup>th</sup> week of pregnancy. Sawin *et al.*<sup>[34]</sup> and others,<sup>[23]</sup> state



**Figure 4: (a) Sagittal T1-weighted MRI showing a hematoma located in the Pons that occurs in the second trimester of pregnancy. (b) Operative photographs revealing stain on the floor of the 4th ventricle and a venous angioma. The cavernous angioma was not removed**

that either VD or CS can be chosen based on obstetrical reasons only. Three of our MAVs patients were operated on after the CS delivery.

Kalani and Zabramski<sup>[21]</sup> studied the risk for symptomatic hemorrhage from a CCM during pregnancy. They claimed that the risk of symptomatic hemorrhage from a CCM during pregnancy is not increased and a history of CCM is not a contraindication to pregnancy or vaginal delivery. The single patient with a 4<sup>th</sup> ventricle CCM had it explored but not removed due to its critical location [Figure 4a and b]. Four patients with intracranial bleeding due to eclampsia were treated nonoperatively.

In the future, better-powered studies will hopefully enable more high-level recommendations for managing patients with neoplastic or vascular brain lesions presenting during pregnancy.

## CONCLUSIONS

We can assert that the association between a brain tumor and vascular lesions during pregnancy is an unusual event, which jeopardizes both the life of the mother and infant and creates challenges of a neurosurgical, obstetric, and ethical nature. Therefore, a multidisciplinary approach should be used for their care. When aneurysm SAH occurs, microsurgery clipping or endovascular occlusion of the aneurysm is prescribed at any age of the pregnancy. If the bleeding is due to an AVM rupture, the best procedures are yet to be defined, and the therapeutic choice should be made on a case-by-case basis. In a patient with a brain tumor, surgery may be deferred until gestational period reaches at least its 30<sup>th</sup> week. If the patient presents with neurological deterioration, surgery is immediately performed to save the mothers' life.

## Financial support and sponsorship

Nil.

## Conflicts of interest

There are no conflicts of interest.

## REFERENCES

- Albert RJ, Morrison CJ. Neurologic diseases in pregnancy. *Obstet Gynecol Clin N Am* 1992;19:765-81.
- Amias GA. Cerebral Vascular Disease in pregnancy: I. Hemorrhage. *J Obstet Gynaecol Br Comn* 1970;77:100-20.
- Barno A, Freeman DW. Maternal deaths due to spontaneous subarachnoid hemorrhage. *Am J Obstet Gynecol* 1976;125:384-92.
- Blaauw G, Blankenstein MA, Lamberts SW. Sex steroid receptors in human meningiomas. *Acta Neurochir* 1986;79:42-7.
- Cannell ED, Botterel HE. Subarachnoid hemorrhage and pregnancy. *Am J Obstet Gynecol* 1956;72:844-55.
- Cohen-Gadol AA, Jonathan A, Friedman JA, Friedman JD, Tubbs RS, Munis JR, et al. Neurosurgical management of intracranial lesions in the pregnant patient: A 36-year institutional experience and review of the literature. *Clinical article. Neurosurgery* 2009;111:1150-7.
- Copelan EI, Mabon RF. Spontaneous intracranial bleeding in pregnancy. *Obstet Gynaecol* 1967;20:373-8.
- Daane TA, Tanty RW. Rupture of congenital intracranial aneurysms in pregnancy. *Obstet Gynecol* 1960;15:305-14.
- Day J, Batjer HH. Operative positioning and fetal monitoring consideration. In: Loftus M, editor. *Neurosurgical aspect of pregnancy*. Illinois: The American Association Neurological Surgeons; 1996. pp. 177-8.
- Dias MS, Sekhar LN. Intracranial Hemorrhage from Aneurysms and Arteriovenous Malformation During Pregnancy and the Puerperium. *Neurosurgery* 1990;27:855-66.
- Donaldson JO. Neurologic emergencies in pregnancy. *Obstet Gynaecol Clin N Am* 1991;18:199-212.
- Ducray F, Colin P, Cartalat-Carel S. Management of malignant gliomas diagnosed during pregnancy. *Rev Neurol* 2006;162:322-92.
- Erickson ML, Johnson R, Bannykh SI, Lotbiniere A, Kim JH. Malignant rhabdoid tumor in a pregnant adult female: Literature review of central nervous system rhabdoid tumors. *J Neuro-Oncol* 2005;74:311-9.
- Eriks AL, Scheithauer BW, Yachnis AT, Fischer BR, Chicoine MR, Werner P, et al. Meningiomas in Pregnancy: A Clinicopathologic Study of 17 Cases. *Neurosurgery* 2012;71:951-96.
- Grunberg SM, Daniels AM, Muensch H, Daniels JR, Bernstein L, Korte V, et al. Correlation of meningioma hormone receptor status with hormone sensitivity in a tumor stem-cell assay. *J Neurosurg* 1987;66:405-8.
- Haba Y, Twyman N, Thomas SJ, Overton C, Dendy P, Burnet NG. Radiotherapy for glioma during pregnancy: Fetal dose estimates, risk assessment and clinical management. *Clin Oncol* 2004;16:210-4.
- Horton JC, Chambers WA, Lyons SL, Adams RD, Kjellberg RN. Pregnancy and the Risk of hemorrhage from cerebral Arteriovenous malformations. *Neurosurgery* 1990;27:867-72.
- Hsu DW, Efrid JT, Hedley-Whyte ET. Progesterone and estrogen receptors in meningiomas: Prognostic considerations. *Neurosurgery* 1997;86:113-20.
- Isla A, Alvarez F, Gonzalez A, Garcia-Grande A, Perez-Alvarez M, Garcia-Blazquel M. Brain Tumor and Pregnancy. *Obstet Gynecol* 1997;89:19-22.
- Jayasekera BAP, Bacon AD, Peter C, Whitfield PC. Management of glioblastoma multiforme in pregnancy. A review. *J Neurosurg* 2012;116:1187-94.
- Kalani MYS, Zabramski JM. Risk for symptomatic hemorrhage of cerebral cavernous malformations during pregnancy. *Clinical article. J Neurosurg* 2013;118:50-5.
- Kasper EM, Hess PE, Silasi M, Lim K, Gray J, Reddy H, Gilmore L, et al. A pregnant female with a large intracranial mass: Reviewing the evidence to obtain management guidelines for intracranial meningiomas during pregnancy. *Surg Neurol Int* 2010;1:95.
- Kim YW, Neal D, Hoh BL. Cerebral Aneurysms in Pregnancy and Delivery: Pregnancy and Delivery Do Not Increase the Risk of Aneurysm Rupture. *Neurosurgery* 2013;72:143-50.
- Laws ER, Taylor WF, Clifton MB, Okazaki H. Neurosurgical management of low-grade astrocytoma of the cerebral hemispheres. *J Neurosurg* 1984;61:665-73.
- Lesch KP, Fahlbusch R. Simultaneous estradiol and progesterone receptor analysis in meningiomas. *Surg Neurol* 1986;26:257-63.
- Mamelak AN, Withers GJ, Wang X. Choriocarcinoma brain metastasis in a patient with viable intrauterine pregnancy. *J Neurosurg* 2002;97:477-81.
- Markwalder TM, Zava DT, Goldhirsch A, Markwalder RV. Estrogen and progesterone receptors in meningiomas in relation to clinical and pathologic features. *Surg Neurol* 1983;20:42-7.
- McCormack BM, Miller DC, Budzilovich GN, Voorhees GJ, Ransohoff J. Treatment and survival of low-grade astrocytoma in adults – 1977–1988. *Neurosurgery* 1992;31:636-42.
- Michelsen JJ, New PFJ. Brain tumor and pregnancy. *J Neurol Neurosurg Psychiatr* 1969;32:305-7.
- Molitch ME. Pituitary tumors and pregnancy. *Growth Horm IGF Res* 2003;(Suppl A):38-44.
- Nossek E, Ekstein M, Rimon E, Kupferminc MJ, Ram Z. Neurosurgery and pregnancy. *Acta Neurochir* 2011;153:1727-35.
- Ravindra VM, Braca JA, Jensen RL, Duckworth EA. Management of intracranial pathology during pregnancy: Case example and review of management strategies. *Surg Neurol Int* 2015;6:43.
- Robinson JL, Hall CS, Sedzimir CB. Arteriovenous Malformations, Aneurysms and Pregnancy. *J Neurosurg* 1974;41:63-70.
- Sawin PD. Spontaneous subarachnoid hemorrhage in pregnancy and the puerperium. In: Loftus CM, editor. *Neurosurgical Aspects of Pregnancy*. Illinois: American Association of Neurological Surgeons; 1966. pp. 85-99.
- Shorshar T, Lamy C, Mas JL. Incidence and causes of strokes with pregnancy and puerperium. Study in public hospitals of the Isle de France. *Stroke* 1995;26:930-9.
- Simon SL, Moonis G, Judkins AR, Scobie J, Burnett MG, Rhiina HA, et al. Intracranial capillary hemangioma: Case report and review of the literature. *Surg Neurol* 2005;64:154-9.
- Tewari KS, Cappuccini F, Asrat T, Flamm BL, Carpenter SE, Disaia PL, et al. Obstetric emergencies precipitated by malignant brain tumors. *Am J Obstet Gynecol* 2000;182:1215-21.
- Tuncali B, Aksun M, Katircioglu K, Akkol I, Savaci S. Intraoperative fetal heart rate monitoring during emergency neurosurgery in a parturient. *J Anesth* 2006;20:40-3.
- Verheecke M, Halaska MJ, Lok CA, Ottvanger PB, Petronella B, Fruscio R, et al. Primary brain tumours, meningiomas and brain metastases in pregnancy: Report on 27 cases and review of literature. *EJC* 2014;50:1462-71.
- Vougioukas V, Kyroussis G, Gläsker S, Tatagiba M, Scheufler KM. Neurosurgical interventions during pregnancy and the puerperium: Clinical considerations and management. *Acta Neurochir* 2004;146:1287-92.