

## Case Report

**Aneurysm of azygos anterior cerebral artery associated with falcine meningioma: Case Report and review of the literature**

Lucas C. Meguins, Raquel C. T. Hidalgo, Antônio R. Spotti, Dionei F. de Moraes

Department of Neurological Sciences, Division of Neurosurgery, Hospital de Base, Faculdade de Medicina de São José do Rio Preto (FAMERP/SP), São Paulo, Brazil

E-mail: \*Lucas C. Meguins - [lucascrociati@hotmail.com](mailto:lucascrociati@hotmail.com); Raquel C. T. Hidalgo - [raquelhidalgo@terra.com.br](mailto:raquelhidalgo@terra.com.br);Antônio R. Spotti - [arspotti@cerebrocoluna.com.br](mailto:arspotti@cerebrocoluna.com.br); Dionei F. de Moraes - [dionei.fm@terra.com.br](mailto:dionei.fm@terra.com.br)

\*Corresponding author

Received: 29 July 16 Accepted: 21 November 16 Published: 20 February 17

**Abstract**

**Background:** The azygos anterior cerebral artery (ACA) is an uncommon intracranial vascular anomaly of the circle of Willis. Identification of aneurysm from azygos ACA with anterior falcine meningioma is an extremely rare association. The aim of the present study is to report the case of an adult female with a ruptured aneurysm from azygos ACA in association with an anterior falcine meningioma.

**Case Description:** A 65-year-old female was admitted in the Emergency Department reporting sudden onset of severe headache. Computed tomography (CT) revealed an intracerebral hematoma and an expansive calcified lesion. AngioCT showed the presence of a large aneurysm in the distal portion of the azygos ACA. During the surgical procedure, it was possible to visualize the aneurysm in contact with an expansive lesion arising from the anterior third of the falx. Microsurgical clipping of the aneurysm was performed uneventfully and partial resection of the tumor was done. Histopathological analysis showed a fibrous meningioma. The patient was discharged home on the seventh postoperative day in good clinical conditions.

**Conclusion:** The association of aneurysm from azygos ACA and falcine meningioma is an extremely rare event and must be remembered when expansive masses are present in the vicinity of vascular lesions.

**Key Words:** Aneurysm, azygos anterior cerebral artery, falcine meningioma

**Access this article online****Website:**[www.surgicalneurologyint.com](http://www.surgicalneurologyint.com)**DOI:**

10.4103/2152-7806.200577

**Quick Response Code:****INTRODUCTION**

The azygos anterior cerebral artery (ACA) is a very uncommon anomaly of the circle of Willis with an incidence of 1–4%.<sup>[1,3,7,8,18]</sup> In this variant of normal embryogenesis, the confluence of both A1 segments results in the formation of a single distal ACA in the interhemispheric fissure.<sup>[1,3,8]</sup> This unique vascular configuration is frequently associated with saccular aneurysms and has significant impact on the arterial hemodynamics of the frontal lobe.<sup>[7]</sup> The increased blood flow in the azygos pericallosal, which has twice the hemodynamic pressure of a normally paired A2 region,

results in significant stress at the bifurcation of distal ACA and predispose to aneurysm formation.<sup>[3,7]</sup> Moreover, azygos ACA usually accompany other malformations,

This is an open access article distributed under the terms of the Creative Commons Attribution-NonCommercial-ShareAlike 3.0 License, which allows others to remix, tweak, and build upon the work non-commercially, as long as the author is credited and the new creations are licensed under the identical terms.

**For reprints contact:** [reprints@medknow.com](mailto:reprints@medknow.com)

**How to cite this article:** Meguins LC, Hidalgo RC, Spotti AR, de Moraes DF. Aneurysm of azygos anterior cerebral artery associated with falcine meningioma: Case Report and review of the literature. *Surg Neurol Int* 2017;8:25.

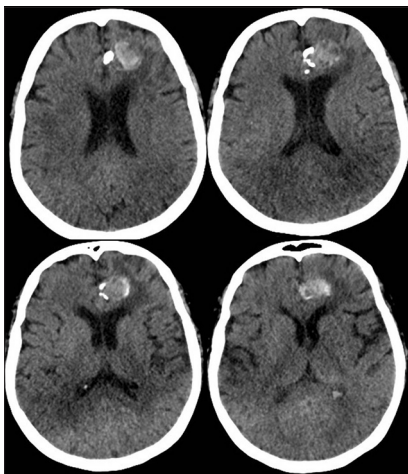
<http://surgicalneurologyint.com/Aneurysm-of-azygos-anterior-cerebral-artery-associated-with-falcine-meningioma--Case-Report-and-review-of-the-literature/>

such as agenesis of corpus callosum, hydranencephaly and arteriovenous malformations (AVMs).<sup>[6]</sup> However, the association of falcine meningiomas and large aneurysm of azygos ACA is an extremely rare association.

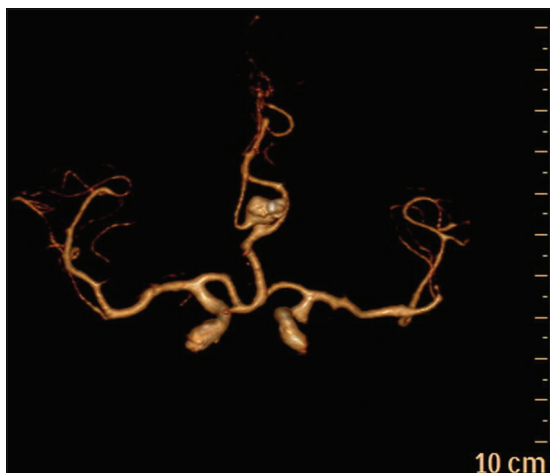
The aim of the present study is to report the case of an adult patient presenting with a large aneurysm of azygos ACA in association with a falcine meningioma.

## CASE REPORT

A 65-year-old female was admitted in the Emergency Department reporting sudden onset of severe headache. Her past medical history was remarkable for arterial hypertension and diabetes mellitus type 2 on use of two antihypertensive drugs and subcutaneous insulin three times daily. On clinical assessment, she was hemodynamically stable, with a blood pressure of 130 × 90 mmHg, pulse 80, and temperature of 37.3°C. Neurological examination was essentially normal. Computed tomography (CT) [Figure 1] revealed an intracerebral hematoma and an expansive



**Figure 1:** Head CT showing intracerebral hemorrhage and a calcified lesion



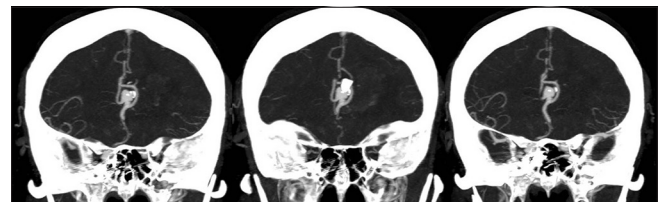**Figure 3:** 3D angioTC showing the aneurysm

calcified lesion. AngioCT [Figures 2 and 3] showed the presence of a large aneurysm in the distal portion of the azygos ACA. During the surgical procedure through interhemispheric approach it was possible to visualize the aneurysm in contact with an expansive lesion arising from the anterior third of the falx [Figure 4]. Microsurgical clipping of the aneurysm was performed uneventfully and partial resection of the tumor was done. Histopathological analysis showed a fibrous meningioma. The patient had an uneventful recovery without neurologic deficits and was discharged home in good clinical conditions on the seventh postoperative day. After six months of follow-up, she presented no recurrence of her clinical symptoms.

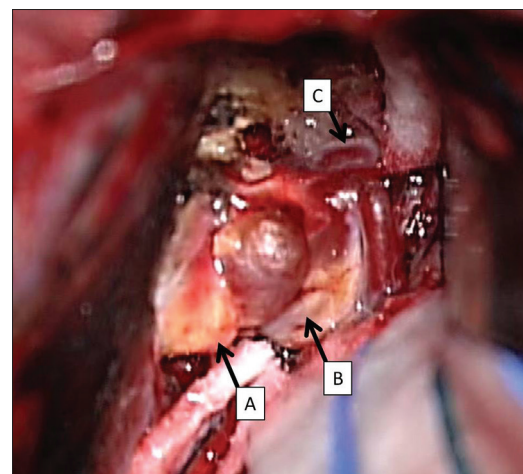
## DISCUSSION

According to Yasargil, Wilder was the first to describe the fusion of both A2 segments of ACA to a single artery and to introduce the term “arteria termatica” in 1885.<sup>[14]</sup> The presence of a single, distal A2 segment of the ACA is named azygos ACA. This is also known as unpaired pericallosal artery or azygos pericallosal artery.<sup>[5,11,12]</sup> Although the presence of unpaired ACA is common in lower mammals, it is uncommon in humans, with an incidence varying from 1% to 4%.<sup>[1,3,7,8,18]</sup> Others important anomalies of ACA are the bihemispheric ACA, triplications ACA, and crossover branches of ACA.<sup>[11,12]</sup>

Baptista reviewed the literature and found that, of the 2153 brains studied, 23 had azygos ACAs (1.06%).<sup>[4]</sup>



**Figure 2:** Coronal MIP angioTC showing the aneurysm



**Figure 4:** Intraoperative aspect of the aneurysm and tumor. (A: Falcine meningioma; B: Aneurysm; C: Azygos ACA)

In contrast, Le May and Gooding reported four cases of azygos ACA (3.73%) in 107 consecutive carotid angiograms.<sup>[13]</sup> Huh *et al.* found a total of three cases of azygos ACA aneurysm in a series of 781 consecutive patients with subarachnoid hemorrhage (0.38%).<sup>[7]</sup> Ghanta *et al.* reported two cases of ruptured azygos ACA aneurysm among 105 (1.9%).<sup>[5]</sup>

In 1963, Baptista presented a scale of three groups for the anatomical variations of azygos ACA.<sup>[4]</sup> In type I anomaly (true azygos ACA), there is only one azygos ACA from which all major branches spread to both the hemispheres. Type II anomaly is bihemispheric ACA, where both right and left ACA are present, however, most of the major branches to the bilateral hemispheres arise from one ACA and the other is rudimentary. In type III anomaly, a third artery (accessory ACA) arises from anterior communicating artery. In the present report, our patient showed a type I variation from this scale.<sup>[4]</sup>

Azygos ACA is also known to be associated with other midline malformations including genesis of the corpus callosum, porencephalic cysts, holoprosencephaly arteriovenous malformations, and saccular aneurysms.<sup>[6]</sup> In addition, the presence of intracranial aneurysm and brain tumor is not a new phenomenon<sup>[15]</sup> and meningiomas seem to be the most likely tumors to facilitate the formation of intracranial aneurysm.<sup>[15]</sup> Kim *et al.* identified a significant association between intracranial aneurysms and meningiomas.<sup>[10]</sup> Twenty three patients (7.7%) diagnosed with meningiomas were also identified to harbor intracranial aneurysm.<sup>[10]</sup> However, the association of primary intracranial tumors and aneurysm of azygos pericallosal artery is an extremely rare association. In the present report, we describe the coexistence of a falicine meningioma and a large aneurysm of azygos ACA.

We believe that many factors have contributed to the appearance of this unique case. First, the presence of long-term arterial hypertension associated with irregular use of antihypertensive drugs was a remarkable report by the patient. Arterial hypertension is a well-known risk factor for both intracranial aneurysms<sup>[2,9,16]</sup> and meningiomas, especially in females in the age group of 60–69 years.<sup>[5,17]</sup> Second, the presence of a vascular anomaly such as azygos ACA that adds hemodynamic pressure on the anterior circulation twice of that observed in normal patients may contribute to aneurysm formation and growth. Finally, the presence of a neoplasm as a meningioma in close proximity to the bifurcation of the pericallosal artery may have also contributed to aneurysm growth, once inflammatory factors present and released by the tumor may affect the vascular wall in touching the tumor borders. Furthermore, the pulsatile effect of the aneurysm over the tumor may also have produced a traumatic effect on the tumor, increasing the inflammatory process.

## CONCLUSION

In conclusion, the association of large aneurysm from azygos ACA and falicine meningioma is an extremely rare event and must be remembered when expansive masses are present in the vicinity of vascular lesions.

## Financial support and sponsorship

Nil.

## Conflicts of interest

There are no conflicts of interest.

## REFERENCES

1. Auguste KI, Ware ML, Lawton MT. Nonsaccular aneurysms of the azygos anterior cerebral artery. *Neurosurg Focus* 2004;17:E12.
2. Backes D, Rinkel GJ, Laban KG, Algra A, Vergouwen MD. Patient- and Aneurysm-Specific Risk Factors for Intracranial Aneurysm Growth: A Systematic Review and Meta-Analysis. *Stroke* 2016;47:951-7.
3. Baldawa S, Katikar D, Marda S. Giant saccular distal azygos artery aneurysm: Report of a case and review of literature. *Asian J Neurosurg* 2016;11:175.
4. Baptista AG. Studies on the arteries of the brain. II. The anterior cerebral artery: Some anatomic features and their clinical implications. *Neurology* 1963;13:825-35.
5. Ghanta RK, Kesnakurthy MV, Vemuri VN. Aneurysm of azygos anterior cerebral artery: A report of two cases. *Asian J Neurosurg* 2016;11:312.
6. Hayashi M, Kobayashi H, Kawano H, Handa Y, Kabuto M. Giant aneurysm of an azygos anterior cerebral artery: Report of two cases and review of the literature. *Neurosurgery* 1985;17:341-4.
7. Huh JS, Park SK, Shin JJ, Kim TH. Saccular aneurysm of the azygos anterior cerebral artery: Three case reports. *J Korean Neurosurg Soc* 2007;42:342-5.
8. Jagetia A, Kumar PN, Sinha S, Sharma A. Saccular bilobed aneurysm of an azygos anterior cerebral artery. *J Clin Neurosci* 2007;14:777-9.
9. Kim T, Lee H, Ahn S, Kwon OK, Bang JS, Hwang G, *et al.* Incidence and risk factors of intracranial aneurysms: A national cohort study in Korea. *Int J Stroke* 2016 [Epub ahead of print].
10. Kim YH, Lee YJ, Han JH, Ahn S, Lee J, Kim JH, *et al.* Association of intracranial aneurysms and meningiomas: A case-control study. *J Neurosurg* 2015;123:357-61.
11. Lehecka M, Dashti R, Hernesniemi J, Niemelä M, Koivisto T, Ronkainen A, *et al.* Microneurosurgical management of aneurysms at A3 segment of anterior cerebral artery. *Surg Neurol* 2008;70:135-51.
12. Lehecka M, Dashti R, Hernesniemi J, Niemelä M, Koivisto T, Ronkainen A, *et al.* Microneurosurgical management of aneurysms at A4 and A5 segments and distal cortical branches of anterior cerebral artery. *Surg Neurol* 2008;70:352-67.
13. LeMay M, Gooding CA. The clinical significance of the azygos anterior cerebral artery (A.C.A.). *Am J Roentgenol Radium Ther Nucl Med* 1966;98:602-10.
14. Ozkal E, Erongun U, Acar O, Kalkan E. Ruptured aneurysm of an azygos anterior cerebral artery. *Turk Neurosurg* 1990;1:140-2.
15. Pia HW, Obrador S, Martin JG. Association of brain tumours and arterial intracranial aneurysms. *Acta Neurochir* 1972;27:189-204.
16. Qian Z, Kang H, Tang K, Jiang C, Wu Z, Li Y, *et al.* Assessment of Risk of Aneurysmal Rupture in Patients with Normotensives, Controlled Hypertension, and Uncontrolled Hypertension. *J Stroke Cerebrovasc Dis* 2016;25:1746-52.
17. Schneider B, Pülhorn H, Röhrig B, Rainov NG. Predisposing conditions and risk factors for development of symptomatic meningioma in adults. *Cancer Detect Prev* 2005;29:440-7.
18. Topsakal C, Ozveren MF, Erol FS, Cihangiroglu M, Cetin H. Giant aneurysm of the azygos pericallosal artery: Case report and review of the literature. *Surg Neurol* 2003;60:524-33.