

Technical Note

Modified extradural temporopolar approach with suction decompression for clipping of large paraclinoid aneurysm: Technical note

Naoki Otani, Terushige Toyooka, Kojiro Wada, Kentaro Mori

Department of Neurosurgery, National Defense Medical College, Tokorozawa, Saitama, Japan

E-mail: *Naoki Otani - naotani@ndmc.ac.jp; Terushige Toyooka - teru_toy1809@friend.ocn.ne.jp; Kojiro Wada - stingray@ndmc.ac.jp; Kentaro Mori - kmori@ndmc.ac.jp

*Corresponding author

Received: 21 September 16 Accepted: 26 March 17 Published: 18 July 17

Abstract

Background: Surgical clipping of complicated large paraclinoid aneurysms are still challenging because strong adhesion of aneurysm itself may hinder the dissection of the perforators and the surrounding anatomical structures from the aneurysm dome.

Methods: We describe 13 consecutive patients and the clipping of complicated, large-sized paraclinoid aneurysms using a modified extradural temporopolar approach combined with retrograde suction decompression and discuss its advantages and pitfalls.

Results: Modified extradural temporopolar approach with suction decompression (SD) assistance was performed in all patients. There was no complication related to the surgical procedure. Postoperative outcome was good recovery in 7 patients, moderate disability in 4, and severe disability in 2 caused by severe subarachnoid hemorrhage. Favorable outcomes were achieved in 10 patients (84.6%).

Conclusion: We recommend its less invasive, safe, and useful combined technique in the treatment of symptomatic paraclinoid aneurysms, which carry the risk of neurovascular injury caused by dissection from the aneurysm dome.

Key Words: Extradural anterior clinoidectomy, extradural temporopolar approach, paraclinoid aneurysm, suction decompression

Access this article online

Website:www.surgicalneurologyint.com**DOI:**

10.4103/sni.sni_377_16

Quick Response Code:

BACKGROUND

There are considerable difficulties in the complete clipping of large paraclinoid aneurysms for achieving proximal control of the parent artery and obtaining adequate visualization of the aneurysm neck due to their large sizes and broad necks and because of the complicated anatomical location close to the optic and surrounding bony structures.^[4,8,9,10]

Microsurgical treatment of these aneurysms may often require the use of the retrograde suction decompression (RSD) technique to facilitate safe and

complete clipping.^[7,8] The extradural temporopolar approach (ETA) gives us enough surgical working space

This is an open access article distributed under the terms of the Creative Commons Attribution-NonCommercial-ShareAlike 3.0 License, which allows others to remix, tweak, and build upon the work non-commercially, as long as the author is credited and the new creations are licensed under the identical terms.

For reprints contact: reprints@medknow.com

How to cite this article: Otani N, Toyooka T, Wada K, Mori K. Modified extradural temporopolar approach with suction decompression for clipping of large paraclinoid aneurysm: Technical note. *Surg Neurol Int* 2017;8:148.

<http://surgicalneurologyint.com/Modified-extradural-temporopolar-approach-with-suction-decompression-for-clipping-of-large-paraclinoid-aneurysm:-Technical-note/>

with securing the clinoid segment of the internal carotid artery (ICA).^[5,6] We have recently modified this approach to a less invasive technique for reducing the risk of intraoperative neurovascular injury.^[15] In this article, we present the surgical advantages and pitfalls in direct clipping of these complicated paraclinoid aneurysms using the modified ETA with RSD through direct puncture of the common carotid artery (CCA).

PATIENTS AND METHODS

This retrospective study included 13 consecutive patients with complicated large-sized paraclinoid aneurysms treated by direct clipping via a modified ETA with RSD assistance between March 2004 and March 2016.

Surgical procedures

Just before positioning in the surgical posture, lumbar spinal drainage was instituted to ensure adequate brain relaxation, to obtain full exposure of the epidural space in the extradural surgical procedure, and to avoid postoperative cerebrospinal fluid leakage. Intraoperative monitoring of the motor evoked potential was routinely monitored for a safe neck clipping. Indocyanine green videoangiography and/or microvascular Doppler ultrasonography were regularly used to assess blood flow of the parent and branch vessels.

The surgical procedure is shown in Figure 1. After induction of general anesthesia, the patient is placed in the supine position, and the head is rotated 30 degrees away from the operative side. The neck is slightly extended to facilitate exposure of the cervical carotid artery. A semicoronal skin incision is performed followed by interfascial dissection. The temporal muscle is reflected inferiorly and posteriorly. A standard frontotemporal craniotomy is performed up to the supraorbital notch, and the temporal squama is rongeuired out until the floor of the middle cranial fossa is exposed. If the orbitozygomatic approach is needed, the orbitozygomatic bar is removed in a two-piece manner. The frontal dura and the temporal dura are subperiosteally dissected. The lesser wing of the sphenoid is flattened until the meningo-orbital band is exposed and incised to a length of approximately 4 mm. The superior orbital fissure is skeletonized to expose the junction between the dura propria and the periosteal dura.^[15] Peeling of the dura propria from the lateral wall of the cavernous sinus continues until the ACP is epidurally exposed. Drilling of the ACP with a high-speed drill using cold saline irrigation starts from the lateral part of the ACP, and the optic canal is then opened partially in the medial part of the ACP. The optic canal is then widely opened using a micropunch to avoid heat injury. After removal of the ACP, the clinoid segment (C3) of the ICA can be seen. The remainder of the optic strut can be removed with either a small diamond drill or micropunch to provide space for the clip blade in cases of paraclinoid aneurysm. The dura mater is opened

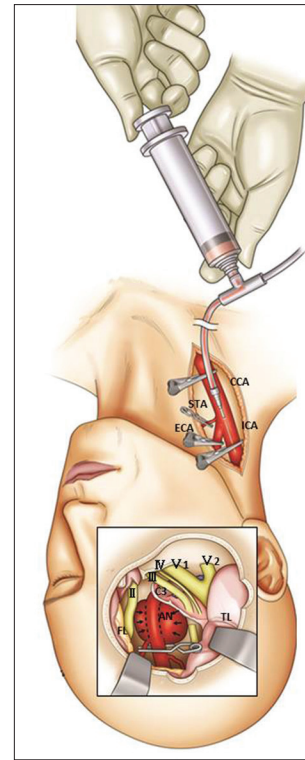


Figure 1: Surgical procedure for the suction decompression with modified extradural temporopolar approach. Just before dissection of the aneurysm, the CCA was punctured with a 20 gauge plastic needle and connected with the pressurized bag filled with heparinized saline (heparin 5000 U/500 ml saline). The aneurysm was trapped by clamping of the CCA and ECA followed by temporary clipping of the intracranial ICA distal to the aneurysm neck. Blood was then aspirated through a catheter, resulting in shrinkage of the aneurysm dome and allowing complete dissection and clipping of the aneurysm

along the sylvian fissure, and continued inferomedially to the level of the optic nerve. Additional wide opening of the sylvian fissure is helpful for minimal retraction of the frontal lobe to expose the ICA and the optic nerve. The posterior communicating artery (PcomA), anterior choroidal artery (AchoA), and their branches are identified. An incision from the falciform ligament to the optic sheath helps to mobilize the optic nerve. The tentorial edge is incised from the anterior petroclinoid ligament and the temporal lobe can be retracted posteriorly over the dura mater. An additional incision is made across the distal dural ring to expose and identify the origin of the ophthalmic artery and to mobilize the ICA. Such incisions of the falciform ligament and distal dural ring will facilitate movement of the optic nerve and ICA. Cerebrospinal fluid leakage is a potential risk if the ethmoid air cells are opened during drilling of the ACP. Therefore, the opened ethmoid air cells should be carefully packed with autologous muscle with fibrin glue sealant.

Simultaneously, the cervical CCA, ICA, and external carotid artery (ECA) are routinely exposed for proximal control, suction decompression, intraoperative angiography,

and high-flow bypass, if necessary. The CCA is punctured using a 20-gauge plastic needle just before suction decompression. After 3000 ~ 5000 U heparinization, the CCA and ECA are clamped. Subsequently, the aneurysm is temporarily trapped by putting a temporal clip on the intracranial ICA distal to the aneurysm neck with special attention to spare the AChA. Blood is aspirated through the catheter introduced into the cervical ICA, resulting in collapse of the aneurysm, and therefore, enabling the surgeon to complete dissection and neck clipping. The occlusion time can be limited to within 5 min even if there are no obvious changes occur in electrophysiological monitoring. The RSD were repeated after declamping the arteries for duration longer than each occlusion time. These procedures can be repeated until confirming the complete clipping. Intraoperative DSA through the catheter placed in the cervical ICA confirmed the complete clipping without stenosis of the parent artery. Complete hemostasis at the puncture site is achieved by suturing.

RESULTS

All patient characteristics are summarized in Table 1. The presenting symptoms were SAH in 3 patients, symptomatic in 5, and asymptomatic visual disturbance in 5. Extradural anterior clinoidectomy via modified ETA was performed in all patients. There was no complication related to the direct puncture of the CCA for suction decompression. Postoperative outcome was good recovery in 7 patients, moderate disability in 4, and severe disability in 2 caused by severe SAH. Favorable outcomes were achieved in 10 patients (84.6%). Postoperative outcome in the 5 symptomatic patients was good

recovery in 1 patient, moderate disability in 4. However, muscle strength was restored, and the patients became independent in activities of daily living by the 3-month follow-up examination. All aneurysms were successfully clipped, and postoperative 3DCTA revealed no major branch occlusion or residual aneurysm.

DISCUSSION

Removal of the ACP is one of the essential skull base techniques to treat large paraclinoid lesions,^[4,14] which has evolved from two main techniques as intradural and/or extradural approach. It seems that the intradural approach can expose only the distal dural ring; on the other hand, extradural approach can expose until the proximal dural ring with complete exposure of the carotid cave, which will be necessary to dissect in clipping for large paraclinoid aneurysms. Tripathi *et al.*^[18] provided details of exposure with both techniques with quantitative comparative evaluation, and suggested that extradural clinoidectomy is the preferred technique because of better anatomic orientation. Extradural anterior clinoidectomy requires peeling of the lateral wall of the cavernous sinus to entirely expose the ACP for drilling.^[5,6] This extradural procedure has been refined by minimizing the area of peeling in the lateral wall of the superior orbital fissure (SOF) including the anterior part of the CS.^[2,12,13] We have recently modified the ETA to a less invasive technique to provide an extensive exposure of the ACP with simple and safe handling,^[15] which requires skeletonization of the SOF to expose interleticular layer and needs only minimal dural incision between the SOF and foramen rotundum (FR) where no cranial nerves are present.

Table 1: Clinical characteristics of 13 patients who underwent modified extradural temporopolar approach with suction decompression in large sized paraclinoid aneurysm between March 2004 and August 2015

Case No	Age	Sex	Side	Symptom	Size (mm)	Complications	Surgical outcome		
							ADL	KPS	GOS
1	76	F	R	Asymptomatic	20	VD	2	90	GR
2	66	F	R	Asymptomatic	13	ONP	1	90	GR
3	53	F	L	Asymptomatic	25	—	1	100	GR
4	42	F	L	Asymptomatic	15	—	1	100	GR
5	73	F	L	Asymptomatic	13	—	1	100	GR
6	68	F	L	SAH (grade II)	20	—	1	100	GR
7	56	F	R	Symptomatic	13	—	1	100	GR
8	72	F	L	Symptomatic	16	—	2	80	MD
9	59	F	L	Symptomatic	25	—	2	80	MD
10	73	F	R	Symptomatic	12	—	3	40	MD
11	65	F	L	Symptomatic	13	—	2	80	MD
12	73	F	R	SAH (grade III)	18	—	4	20	SD
13	69	F	L	SAH (grade IV)	12	—	4	40	SD

M: Male, F: Female, R: Right side, L: Left side, ICA: Internal carotid artery, PC: Posterior communicating artery, SAH: subarachnoid hemorrhage, ETA: extradural temporopolar approach, VD: Visual disturbance, ONP: Oculomotor nerve palsy, ACA: Anterior cerebral artery, AN: Aneurysm, SV: Symptomatic vasospasm, CI: Cerebral infarction, AChA: Anterior choroidal artery, ADL: Activity of daily living, KPS: Karnofsky performance status, GOS: Glasgow Outcome Scale, GR: Good recovery, MD: Moderate disability, SD: Severe disability

The RSD through an angiocatheter inserted into the cervical ICA was reported in 1990 and 1991.^[1,17] This technique provides adequate relaxation of the aneurysm dome enabling the surgeon to fully dissect between the ICA, its branches and the aneurysm dome to obtain adequate visualization of the aneurysm neck for reconstruction of the parent artery.^[7,8] In addition, the CCA can be used for proximal control of the ICA and intraoperative angiography, as well as preparation for high-flow bypass, because of severe calcification and sclerotic change of the aneurysmal neck. Therefore, the direct puncture route is helpful for intra-arterial injection of the contrast medium.

On the other hand, endovascular techniques have gained widespread application in the treatment for paraclinoid aneurysms. However, high aneurysmal recurrent risk has been the main limitation of endovascular treatment of intracranial aneurysms.^[3] Recently, flow diversion has been proposed as a new strategy with a higher rate of complete obliteration in the treatment of complex intracranial aneurysms.^[11] However, approximately one-third of the ophthalmic artery will undergo proximal thrombosis when covered with flow diversion devices for the treatment of proximal ICA aneurysms.^[16] Therefore, flow diverters have not, to date, been tested in direct comparison with other available treatments. Further long-term follow-up will be necessary to clarify the definitive validation of the flow diversion as a superior treatment strategy for large paraclinoid aneurysms.

CONCLUSION

Our experience of direct clipping of complicated paraclinoid aneurysms using RSD through direct puncture of the CCA combined with modified ETA is a less invasive technique. The RSD technique, which can be easily and rapidly prepared, provides several benefits such as proximal flow control of the ICA, opportunity to safely repeat deflation of the aneurysm, and unlimited possibilities to perform intraoperative DSA and/or extracranial-intracranial bypass without limitations of the operative field. We recommend this less invasive, safe, and useful combined technique in the treatment of symptomatic paraclinoid aneurysms which carry the risk of neurovascular injury caused by dissection from the aneurysm dome.

Financial support and sponsorship

Nil.

Conflicts of interest

There are no conflicts of interest.

REFERENCES

- Batjer HH, Samson DS. Retrograde suction decompression of giant paraclinoid aneurysms. Technical note. *J Neurosurg* 1990;73:305-6.
- Coscarella E, Bakaya MK, Morcos JJ. An alternative extradural exposure to the anterior clinoid process: The superior orbital fissure as a surgical corridor. *Neurosurgery* 2003;53:162-6.
- Crobeddu E, Lanzino G, Kallmes DF, Cloft HJ. Review of 2 decades of aneurysm recurrence literature, Part I: Reducing recurrence after endovascular coiling. *AJNR Am J Neuroradiol* 2013;34:266-70.
- Day AL. Aneurysms of the ophthalmic segment. A clinical and anatomical analysis. *J Neurosurg* 1990;72:677-91.
- Day JD, Giannotta SL, Fukushima T. Extradural temporopolar approach to lesions of the upper basilar artery and infrachiasmatic region. *J Neurosurg* 1994;81:230-5.
- Day JD, Fukushima T, Giannotta SL. Cranial base approaches to posterior circulation aneurysms. *J Neurosurg* 1997;87:544-54.
- Fan YW, Chan KH, Lui WM, Hung KN. Retrograde suction decompression of paraclinoid aneurysm--a revised technique. *Surg Neurol* 1999;51:129-31.
- Fulkerson DH, Horner TG, Payner TD, Leipzig TJ, Scott JA, DeNardo AJ, et al. Results, outcomes, and follow-up of remnants in the treatment of ophthalmic aneurysms: A 16-year experience of a combined neurosurgical and endovascular team. *Neurosurgery* 2009;64:218-29.
- Giannotta SL. Ophthalmic segment aneurysm surgery. *Neurosurgery* 2002;50:558-62.
- Hauck EF, Wohlfeld B, Welch BG, White JA, Samson D. Clipping of very large or giant unruptured intracranial aneurysms in the anterior circulation: An outcome study. *J Neurosurg* 2008;109:1012-8.
- Lanzino G, Crobeddu E, Cloft HJ, Hanel R, Kallmes DF. Efficacy and safety of flow diversion for paraclinoid aneurysms: A matched-pair analysis compared with standard endovascular approaches. *AJNR Am J Neuroradiol* 2012;33:2158-61.
- Mori K, Yamamoto T, Nakao Y, Esaki T. Surgical Simulation of Extradural Anterior Clinoidectomy through the Trans-superior Orbital Fissure Approach Using a Dissectable Three-dimensional Skull Base Model with Artificial Cavernous Sinus. *Skull Base* 2010;20:229-35.
- Noguchi A, Balasingam V, Shiokawa Y, McMenomey SO, Delashaw JB Jr. Extradural anterior clinoidectomy. Technical note. *J Neurosurg* 2005;102:945-50.
- Nutik SL. Removal of the anterior clinoid process for exposure of the proximal intracranial carotid artery. *J Neurosurg* 1988;69:529-34.
- Otani N, Wada K, Toyooka T, Fujii K, Kobayashi Y, Mori K. Operative surgical nuances of modified extradural temporopolar approach with mini-peeling of dura propria based on cadaveric anatomical study of lateral cavernous structures. *Surgical neurology Int* 2016;7(Suppl 16):S454-8.
- Puffer RC, Kallmes DF, Cloft HJ, Lanzino G. Patency of the ophthalmic artery after flow diversion treatment of paraclinoid aneurysms. *J Neurosurg* 2012;116:892-6.
- Tamaki N, Kim S, Ehara K, Asada M, Fujita K, Taomoto K, et al. Giant carotid-ophthalmic artery aneurysms: Direct clipping utilizing the "trapping-evacuation" technique. *J Neurosurg* 1991;74:567-72.
- Tripathi M, Deo RC, Damodaran N, Suri A, Srivastav V, Baby B, et al. Quantitative analysis of variable extent of anterior clinoidectomy with intradural and extradural approaches: 3-dimensional analysis and cadaver dissection. *Neurosurgery* 2015;11(Suppl 2):147-60.