

## Case Report

## Fatal cerebral swelling immediately after cranioplasty: A case report

Yuta Kaneshiro, Keiji Murata, Shigeru Yamauchi, Yumiko Urano

Department of Neurosurgery, Shimada Municipal Hospital, Shimada City, Shizuoka, Japan

E-mail: \*Yuta Kaneshiro - [yuta.kaneshiro@gmail.com](mailto:yuta.kaneshiro@gmail.com); Keiji Murata - [kmurata@municipal-hospital.shimada.shizuoka.jp](mailto:kmurata@municipal-hospital.shimada.shizuoka.jp);  
Shigeru Yamauchi - [y-mailadd@silver.ocn.ne.jp](mailto:y-mailadd@silver.ocn.ne.jp); Yumiko Urano - [yumi@fk9.so-net.ne.jp](mailto:yumi@fk9.so-net.ne.jp)

\*Corresponding author

Received: 10 April 17 Accepted: 05 May 17 Published: 25 July 17

**Abstract****Background:** Cranioplasty is a standard neurosurgical procedure which is performed after decompressive craniotomy. Fatal complications associated with this procedure are not well documented. Here, we report a case of fatal cerebral swelling after cranioplasty and discuss the possible mechanism of this complication.**Case Description:** A 64-year-old man was admitted with the diagnosis of cerebral hemorrhage, and emergency surgery for hemorrhage removal and decompressive craniotomy were performed. One month after surgery, cranioplasty was performed using a titanium mesh plate. Sixteen hours after the surgery, the patient became comatose with bilateral dilated pupils followed by blood pressure lowering. Computed tomography of the brain showed bilateral massive cerebral edema. The titanium mesh plate was immediately removed, however, the patient's neurological condition did not recover and he died 7 days after the surgery. We speculated that the negative pressure difference and increase in cerebral blood flow after cranioplasty may have attributed to the fatal cerebral swelling.**Conclusion:** Fatal cerebral swelling after cranioplasty is a rare but devastating complication. Although it is rare, neurosurgeons should keep in mind that this fatal complication can follow cranioplasty.**Key Words:** Cerebral edema, cerebral swelling, cranioplasty, decompressive craniotomy, fatal complication**Access this article online****Website:**[www.surgicalneurologyint.com](http://www.surgicalneurologyint.com)**DOI:**

10.4103/sni.sni\_137\_17

**Quick Response Code:****INTRODUCTION**

Cranioplasty is usually performed after decompressive craniotomy for several neurological conditions, including traumatic injury, brain infarction, cerebral hemorrhage, and subarachnoid hemorrhage. Although cranioplasty is a standard neurosurgical procedure, it is associated with a high complication rate owing to concerns such as wound infection, bone resorption, and epidural or subdural hematoma.<sup>[1,8]</sup> However, fatal complications associated with this basic surgical procedure are not adequately reported. Here, we report a case of fatal cerebral swelling that occurred immediately after cranioplasty and discuss the possible mechanism underlying this rare complication.

**CASE DESCRIPTION**

A 64-year-old man was admitted to the Department of Neurosurgery after sudden onset of consciousness disturbance. On admission, the patient was comatose with

This is an open access article distributed under the terms of the Creative Commons Attribution-NonCommercial-ShareAlike 3.0 License, which allows others to remix, tweak, and build upon the work non-commercially, as long as the author is credited and the new creations are licensed under the identical terms.

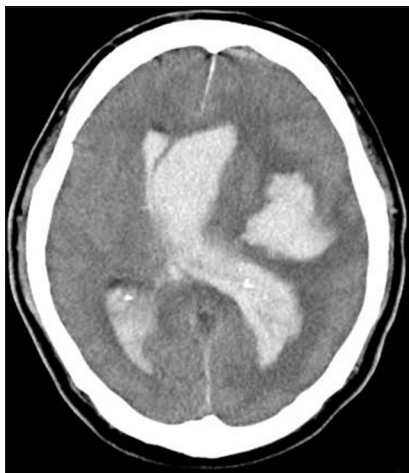**For reprints contact:** [reprints@medknow.com](mailto:reprints@medknow.com)**How to cite this article:** Kaneshiro Y, Murata K, Yamauchi S, Urano Y. Fatal cerebral swelling immediately after cranioplasty: A case report. *Surg Neurol Int* 2017;8:156. <http://surgicalneurologyint.com/Fatal-cerebral-swelling-immediately-after-cranioplasty--A-case-report/>

decerebrate postures. Computed tomography (CT) of the brain showed a massive left intracerebral hemorrhage accompanying intraventricular hemorrhage [Figure 1]. Emergency surgery for hemorrhage removal was performed. After removal of hemorrhage, brain tension was high, for which decompressive craniotomy was additionally performed. Further exploration of hemorrhagic causes did not detect sources such as cerebral aneurysm, arteriovenous malformation, or moyamoya disease.

One month after the surgery, consciousness and neurological status of the patient gradually improved and CT showed remarkable brain sinking [Figure 2a]. Therefore, cranioplasty was performed under general anesthesia. Intraoperative dural tension was unremarkable; therefore, a titanium mesh plate was used and a closed drainage system was placed under the scalp in the usual manner. The drainage system was not connected to the suction system during the surgery. The surgery was uneventful. The patient was extubated, and consciousness and neurological status of the patient promptly recovered to the preoperative status. The closed drainage system was placed on the bedside and suctioned without continuous negative pressure. Sixteen hours after the surgery, the patient became comatose with bilateral dilated pupils followed by blood pressure lowering. Brain CT showed bilateral massive cerebral edema [Figure 2b]. Further exploration was impossible because of rapid exacerbation. The titanium mesh plate was immediately removed, however, the patient's neurological condition did not recover and he died 7 days after the surgery.

## DISCUSSION

Cranioplasty is performed not only to address the cosmetic problem but also to improve the neurological

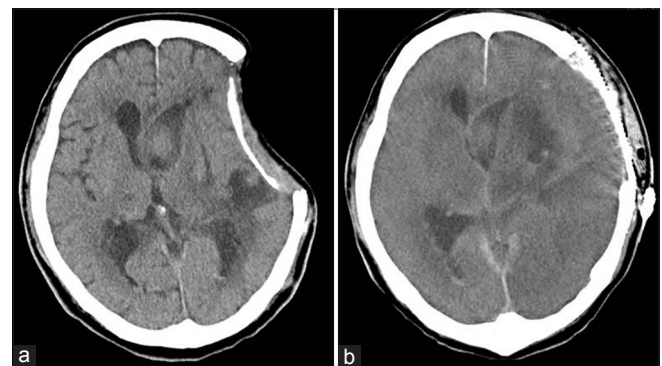


**Figure 1:** A computed tomography image on admission showing massive left intracerebral hemorrhage

status of patients who have undergone decompressive craniotomy.<sup>[4,7]</sup> The surgical procedure of cranioplasty is generally considered safe, and the reported mortality rate is low. Accordingly, fatal massive cerebral swelling as a complication of cranioplasty presented here is rare and has been infrequently reported.<sup>[2,3,5,6,9-11]</sup>

The exact mechanism underlying massive cerebral swelling after cranioplasty has not yet been fully understood. Lee *et al.*<sup>[6]</sup> reported a case of unexpected and severe postoperative cerebral edema following autologous cranioplasty. The authors in this previous report speculated that placing an epidural drainage system with active suction may have caused an acute decrease in intracranial pressure and the subsequent rapid expansion of the brain, leading to the impairment of autoregulation and reperfusion injury. Similarly, Hasaneen *et al.*<sup>[2]</sup> reported a patient who died after cranioplasty because of rapidly progressing cerebral edema. They mentioned the possibility of impaired cerebral autoregulation following cranioplasty within living neural tissue led to the development of malignant cerebral edema. Svirid *et al.*<sup>[10]</sup> also reported 4 patients who died because of massive cerebral swelling immediately after cranioplasty. The authors reviewed the literature on similar cases and proposed a mechanism underlying this rare complication. They suggested that a negative pressure difference owing to the elimination of atmospheric pressure that had been chronically applied to the injured shrinking brain combined with the negative pressure applied by the closed subgaleal suction drain may have led to a massive brain shift toward the cranioplasty site and initiated a fatal vasomotor reaction.

In the present case, we speculated two mechanisms that may have attributed to fatal cerebral swelling. First, the shrinking brain before cranioplasty may have changed the brain compliance because of long-term compression under the atmospheric pressure. Therefore, negative pressure difference owing to the



**Figure 2:** (a) A computed tomography image before cranioplasty showing shrinking of the brain. (b) A computed tomography image after cranioplasty showing bilateral massive cerebral edema

elimination of atmospheric pressure in combination with the negative pressure applied by the closed subgaleal suction drain may have easily induced the brain shift, as previously reported.<sup>[10]</sup> Second, the shrinking brain before surgery may have impaired autoregulation because of long-term compression under the atmospheric pressure and damage owing to cerebral hemorrhage. According to a previous report, cranioplasty can remarkably increase cerebral blood flow of the ipsilateral and contralateral hemispheres at the cranioplasty site.<sup>[7]</sup> This increase in cerebral blood flow toward the autoregulatory impaired brain may have caused the massive cerebral edema.

## CONCLUSION

Fatal cerebral swelling after cranioplasty is a rare but devastating complication. Although it is rare, neurosurgeons should keep in mind that this fatal complication can follow cranioplasty.

## Financial support and sponsorship

Nil.

## Conflicts of interest

There are no conflicts of interest.

## REFERENCES

1. Gooch MR, Gin GE, Kenning TJ, German JW. Complications of cranioplasty following decompressive craniectomy: Analysis of 62 cases. *Neurosurg Focus* 2009;26:E9.
2. Hassaneen W, Germanwala A, Tsimpas A. Malignant cerebral edema following cranioplasty. *J Clin Neurosci* 2016;25:130-2.
3. Honeybul S. Sudden Death Following Cranioplasty. *J Korean Neurosurg Soc* 2016;59:182-4.
4. Isago T, Nozaki M, Kikuchi Y, Honda T, Nakazawa H. Sinking skin flap syndrome: A case of improved cerebral blood flow after cranioplasty. *Ann Plast Surg* 2004;53:288-92.
5. Kwon SM, Cheong JH, Kim JM, Kim CH. Reperfusion injury after autologous cranioplasty in a patient with sinking skin flap syndrome. *J Korean Neurosurg Soc* 2012;51:117-9.
6. Lee GS, Park SQ, Kim R, Cho SJ. Unexpected Severe Cerebral Edema after Cranioplasty: Case Report and Literature Review. *J Korean Neurosurg Soc* 2015;58:76-8.
7. Mah JK, Kass RA. The impact of cranioplasty on cerebral blood flow and its correlation with clinical outcome in patients underwent decompressive craniectomy. *Asian J Neurosurg* 2016;11:15-21.
8. Mukherjee S, Thakur B, Haq I, Hettige S, Martin AJ. Complications of titanium cranioplasty - a retrospective analysis of 174 patients. *Acta Neurochir (Wien)* 2014;156:989-98; discussion 998.
9. Santana-Cabrera L, Perez-Ortiz C, Rodriguez-Escot C, Sanchez-Palacios M. Massive postoperative cerebral swelling following cranioplasty. *Int J Crit Illn Inj Sci* 2012;2:107-8.
10. Sviri GE. Massive cerebral swelling immediately after cranioplasty, a fatal and unpredictable complication: Report of 4 cases. *J Neurosurg* 2015;123:1188-93.
11. Zebian B, Critchley G. Sudden death following cranioplasty: A complication of decompressive craniectomy for head injury. *Br J Neurosurg* 2011;25:785-6.