

## Case Report

# Atypical imaging features of posterior fossa's dermoid cyst: Case report and review of literature

Mohamed Badri, Ghassen Gader, Kamel Bahri, Ihsen Zammel

Department of Neurosurgery, Trauma and Burns Center, Ben Arous, Faculty of Medicine of Tunis, El Manar-Tunis University, Tunisia

E-mail: Mohamed Badri - [badri.med@gmail.com](mailto:badri.med@gmail.com); \*Ghassen Gader - [gastghagad@yahoo.fr](mailto:gastghagad@yahoo.fr); Kamel Bahri - [kamelbahri@yahoo.com](mailto:kamelbahri@yahoo.com); Ihsen Zammel - [ihsenzammel@gmail.com](mailto:ihsenzammel@gmail.com)

\*Corresponding author

Received: 07 November 17 Accepted: 29 March 18 Published: 07 May 18

## Abstract

**Background:** Intracranial dermoid cysts are uncommon lesions with characteristic imaging appearances. Symptomatic clinical presentation usually occurs in one of two ways: mass effect or rupture. Radiologically, dermoid cysts typically present as low density masses on computed tomography (CT) scan and are generally hyperintense on T1-weighted magnetic resonance imaging (MRI) sequences with variable signal on T2-weighted sequences.

**Case Description:** We present the case of a 35-year-old female presented with symptoms of increased intracranial pressure. Radiological investigations showed a cystic posterior fossa tumor that was not only hyperdense on CT scans but also hypointense on MRI T1-weighted images. The patient underwent a total-gross resection of an extra-parenchymal posterior fossa tumor. Pathologic examination of the specimen concluded to dermoid cyst.

**Conclusion:** Dermoid cyst of the posterior fossa is a benign lesion surgically treatable. Only an appropriate radiological diagnosis of this lesion would permit a well-targeted therapeutic approach.

**Key Words:** Computed tomography, dermoid cyst, magnetic resonance imaging, posterior fossa

### Access this article online

**Website:**[www.surgicalneurologyint.com](http://www.surgicalneurologyint.com)**DOI:**

10.4103/sni.sni\_411\_17

**Quick Response Code:**

## INTRODUCTION

Dermoid cysts are rare congenital lesions as a result of developmental malformation, with the defect in gastrulation affecting the surface ectoderm and causing a secondary disruption of neural tube closure.<sup>[10]</sup> Computed tomography (CT) and magnetic resonance imaging (MRI) delineate many characteristic features of dermoid cysts. Their most common site is the posterior cranial fossa nearby the midline, when extradural, may arise at the anterior fontanelle.<sup>[3,6]</sup> However, some unusual radiological features may elude radiologists and surgeons to other differential diagnosis.

In this paper, we report a patient having fourth ventricle dermoid cyst with atypical radiological features.

## CASE REPORT

We report the case of a 35-year-old female presented with headaches, vomiting, and gradually worsening blurred

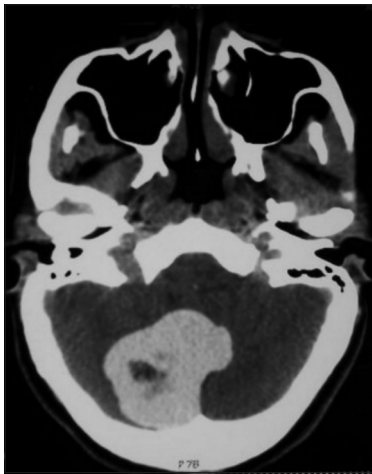
This is an open access journal, and articles are distributed under the terms of the Creative Commons Attribution-NonCommercial-ShareAlike 4.0 License, which allows others to remix, tweak, and build upon the work non-commercially, as long as appropriate credit is given and the new creations are licensed under the identical terms.

**For reprints contact:** [reprints@medknow.com](mailto:reprints@medknow.com)

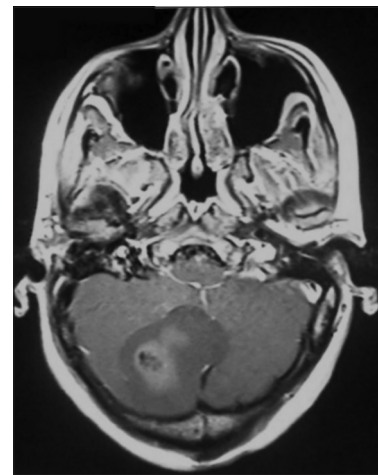
**How to cite this article:** Badri M, Gader G, Bahri K, Zammel I. Atypical imaging features of posterior fossa's dermoid cyst: Case report and review of literature. *Surg Neurol Int* 2018;9:97.

<http://surgicalneurologyint.com/Atypical-imaging-features-of-posterior-fossa's-dermoid-cyst-Case-report-and-review-of-literature/>

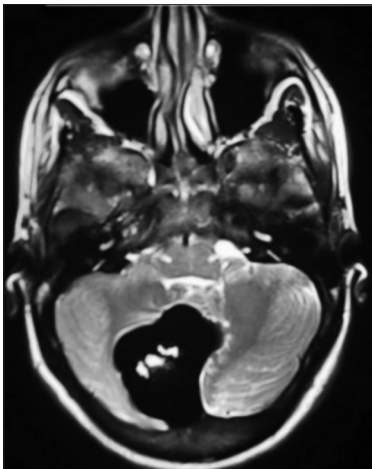
vision. Physical examination was unremarkable except for a grade 2 papillary edema on the fundi. Brain CT scan showed imaging a large median and paramedian spontaneous homogenous hyperdense lesion in the posterior fossa. Mild surrounding edema and mass effect on the fourth ventricle was associated provoking a triventricular hydrocephalus [Figure 1]. On MRI, the lesion appeared hypointense on T1-weighted images and extremely hypointense on T2-weighted images with a hyperintense central area on T1 and T2 without enhancement after injection of gadolinium [Figures 2-4]. A total resection of an extra-parenchymal tumor was performed through a midline suboccipital craniotomy. The lesion was cystic and nonhemorrhagic. After opening the thin cyst wall, a viscid and light brown substance containing few short dark hairs was removed. The patient had a good postoperative recovery and was discharged on the 5<sup>th</sup>-postoperative day. Histopathologic examination [Figure 5] revealed a stratified squamous epithelium with fatty cellular debris, few hair follicles, and scattered sebaceous glands. The diagnosis of dermoid cyst was retained.



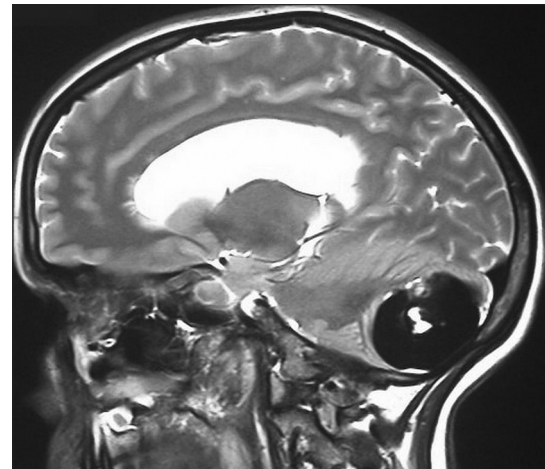
**Figure 1:** Axial CT scan showing a hyper-attenuating lesion centered by an hypodensity of the posterior fossa



**Figure 2:** MRI on axial T1 weighted image revealing an hypointense and heterogeneous contrast enhancement of the solid component of the dermoid cyst



**Figure 3:** MRI on axial T2 weighted images showing a hypointense signal of the dermoid cyst



**Figure 4:** MRI on Sagittal T2 weighted images showing a hypointense signal of the lesion

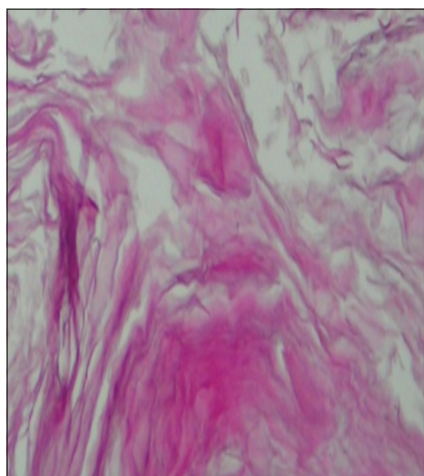
## DISCUSSION

The intracranial dermoid cyst is a rare entity, accounting for 0.1–0.7% of all intracranial tumors.<sup>[14]</sup> Dermoid cysts are derived from the ectopic inclusion of epithelial cells during neural tube closure between the 3<sup>rd</sup> and 5<sup>th</sup> week of fetal development, so that the preferential location in the medial line of the posterior fossa and the spinal cord.<sup>[11,13]</sup> They are slow growing lesions and may become quite large before becoming symptomatic. Rarely, they may rupture and present with meningitis.<sup>[3,13]</sup> Dermoid cysts are well-circumscribed lesions lined by stratified squamous epithelium. They contain thick, foul-smelling, yellowish material from the secretion of sebaceous glands, lipid metabolites, whorls of hair, calcifications, and desquamated epithelium.<sup>[5]</sup>

To our knowledge, nine cases have been reported about posterior fossa's dermoid cyst so far. All those cases are resumed in Table 1.

**Table 1: Cases of posterior fossa's dermoid cyst reported in the literature**

Authors	Age	Sex	Location	CT	T1	T2	Mural nodule	Follow up after surgery
Bizzozero <i>et al.</i> <sup>[1]</sup>	20 years	Female	Posterior fossa	Hyperdense	-	-	No	18 months
Goh <i>et al.</i> <sup>[4]</sup>	19 years	Female	Posterior fossa	Hyperdense	Low signal	Low signal	No	-
Brown <i>et al.</i> <sup>[2]</sup>	18 years	Female	Posterior fossa	Hyperdense	Hyperintense	Hypointense	Yes	8 months
Neugroschl <i>et al.</i> <sup>[8]</sup>	73 years	Male	Posterior fossa	Hyperdense	Hyper signal	Low signal	No	-
Sanchez-Mejia <sup>[9]</sup>	16 years	Male	Posterior fossa	-	Mild hyperintensity	Hypointensity	No	-
Wallace <i>et al.</i> <sup>[12]</sup>	74 years	Female	Posterior fossa	Hypodense	Hypointense	Hyperintense	No	-
Morina <i>et al.</i> <sup>[7]</sup>	49 years	Male	Posterior fossa	-	Hyperintense	-	Yes	6 months



**Figure 5: Histopathological examination of the surgical specimen revealing a stratified squamous epithelium with fatty cellular debris, few hair follicles and scattered sebaceous glands consistent with the diagnosis of dermoid cyst**

The appearance of the dermoid cyst in typical cases is easily recognizable in imaging. They are usually extremely hypodense on CT scan with a Hounsfield unit (HU) of  $-20$  to  $-140$ , explained by their lipid content.<sup>[4,5]</sup> On MRI, dermoid cysts typically appear hyperintense on both T1-weighted and FLAIR sequences, with variable signal on T2-weighted sequences that ranges from hypointense to inhomogeneously hyperintense. There is usually associated neither vasogenic edema nor contrast enhancement. The presence of spontaneous hemorrhage is extremely rare.<sup>[3]</sup> On both CT and MRI images, fat density droplets may be seen throughout the subarachnoid space and inside the ventricular system if rupture of the cyst has occurred.

The unusual radiological finding in our patient was the hyperdensity on CT scan and the hyposignal on MRI T1-weighted images. The hyperdensity could be explained by the high protein content of the necrotic tissue within the lesion.<sup>[4]</sup> The hyposignal on T1-weighted images could be explained by the saponification of lipid or keratinized debris with secondary microcalcification in suspension.<sup>[12]</sup>

## CONCLUSION

The dermoid cyst of the posterior fossa is a benign lesion surgically treatable. The appropriate radiological diagnosis of this lesion permits a well-targeted therapeutic approach. The radiological study is often unequivocal during this lesion. Nevertheless, the hyperdense aspect of the lesion on CT associated with hyposignal on T1-weighted images on MRI may make the diagnosis of a dermoid cyst more difficult.

## Financial support and sponsorship

Nil.

## Conflicts of interest

There are no conflicts of interest.

## REFERENCES

- Bizzozero L, Talamonti G, D'Angelo V, Casadei G, Arrigoni G, Collice M. Dermoid cyst mimicking hematoma in the posterior fossa. *Clin Neurol Neurosurg* 1992;94:61-3.
- Brown J, Morokoff A, Mitchell P. Unusual imaging appearance of an intracranial dermoid cyst. *Am J Neuroradiol* 2001;22:1970-2.
- Douvoyannis M, Goldman D, Abbott I, Litman N. Posterior fossa dermoid cyst with sinus tract and meningitis in a toddler. *Pediatr Neurol* 2008;39:63-6.
- Goh G, Page R, Nixon T. An unusual CT and MR appearance of a posterior fossa dermoid cyst. *Eur J Radiol* 1995;20:46-7.
- Lunardi P, Missori P, Gagliardi F, Fortuna A. Dermoid cysts of the posterior cranial fossa in children. Report of nine cases and review of the literature. *Surg Neurol* 1990;34:39-42.
- Matthys M, Long S, Huisman T, Pindrik J, Tekes A. Posterior fossa dermoid cyst with a sinus tract and restricted diffusion on MR imaging: Value of structural imaging findings and signal characteristics. *J Neuroradiol* 2012;39:134-5.
- Morina A, Kelmendil F, Morina Q, Morina D. Cerebellar dermoid cyst with contrast enhancement mural nodule. *Acta Clin Croat* 2014;53:479-82.
- Neugroschl P, David N, Sadeghi A, Soebert B, Pirotte S, Rorive D. Unusual CT features of dermoid cyst in the posterior fossa. *Eur Radiol* 2002;12:2726-9.
- Sanchez-Mejia R, Limbo M, Tihan T, Galvez M, Woodward M, Gupta N. Intracranial dermoid cyst mimicking hemorrhage. Case report and review of the literature. *J Neurosurg* 2006;105:311-4.
- Sharma M, Sharma B, Yadav A, Khosla V. Posterior fossa dermoid in association with Klippel-Feil syndrome: A short report. *Neurol India* 2001;49:210-2.
- Tan L, Kasliwal M, Harbhajanka A, Kellogg R, Arvanitis L, Munoz L. Hyperdense suprasellar mass: An unusual radiological presentation of intracranial dermoid cyst. *J Clin Neurosci* 2015;22:1208-10.
- Wallace D, Tress B, Kwan P. Radiologically atypical congenital posterior fossa dermoid cyst presenting late in life. *J Clin Neurosci* 2008;15:835-8.
- Wang Y, Chang T, Lo C, Tu M. Spontaneous rupture of intracranial dermoid cyst with chemical meningitis. *J Emerg Med* 2013;44:275-6.
- Yasargil M, Abernathy C, Sarioglu A. Microsurgical treatment of intracranial dermoid and epidermoid cyst. *Neurosurgery* 1989;24:561-7.