

Image Report

Intraventricular metastasis mimicking meningioma

Saraj K. Singh, Himanshu Agarwal¹, Prakash Singh, Khushbu Goel²

Departments of Neurosurgery, ¹Neurointervention, ²Neurology, Max Super Speciality Hospital, Saket, New Delhi, India

E-mail: *Saraj K. Singh - dr.sarajkumarsingh@gmail.com; Himanshu Agarwal - himanshu.20rd@gmail.com;

Prakash Singh - prakash.singha@maxhealthcare.com; Khushbu Goel - Khushbugoel@yahoo.com

*Corresponding author

Received: 02 March 18 Accepted: 12 June 18 Published: 26 July 18

A 69-year-old male patient presented with multiple episodes of fall for 6 months. Magnetic resonance imaging of the brain showed T1 isointensity, T2 hyperintensity, and homogenous enhancement on contrast [Figure 1a-f]. Intraoperatively, the tumor was completely intraventricular without any attachment to the surrounding thalamus or tela choroidea. This unique case was managed as (according to history and imaging) meningioma, but biopsy came out as metastatic deposit of squamous cell carcinoma from the lung [Figure 2a-d].

Intraventricular metastasis presents with various aspects of enhancement (uniform, punctate, ring) which can often lead to misdiagnosis of meningioma.^[1,2] This case is educational for both neurosurgeons and radiologist as

missing proper diagnosis can affect both the management and outcome of patients.

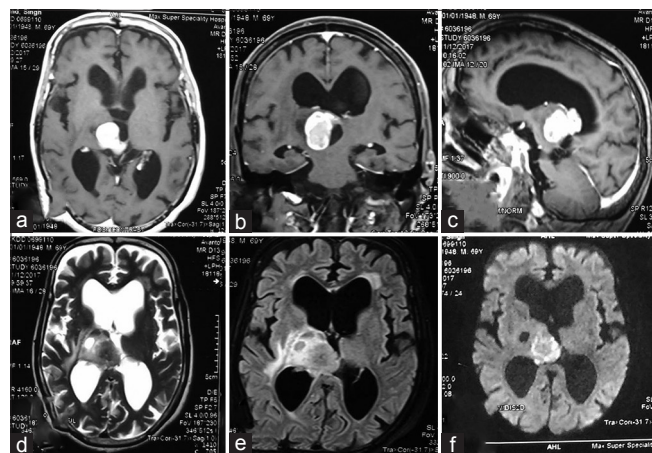


Figure 1: (a-c) Contrast-enhanced brain MRI (axial, coronal and sagittal sequences, respectively) showing homogeneously enhancing lesion at the posterior third ventricular region. (d) Axial T2 brain MRI sequence showing hyperintense mass attached to tela choroidea. (e) FLAIR sequence of brain MRI showing hyperintense lesion. (f) DWI sequence of brain MRI showing diffusion restriction in the lesion

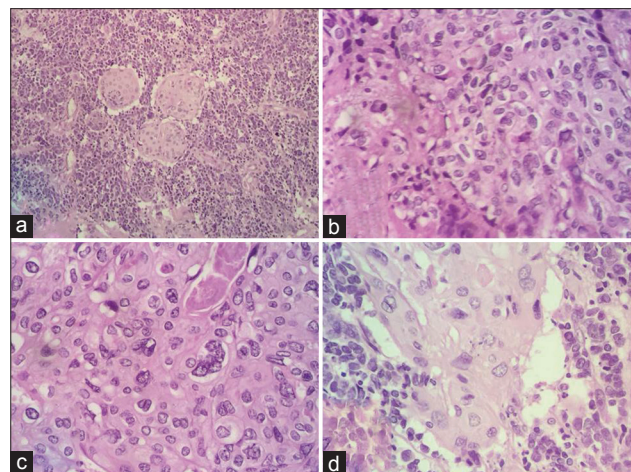


Figure 2: (a) Microphotograph showing tumor cell population (H and E, x100). (b-d) High-power view (H and E, x400) of the carcinoma cells with focal keratinization

This is an open access journal, and articles are distributed under the terms of the Creative Commons Attribution-NonCommercial-ShareAlike 4.0 License, which allows others to remix, tweak, and build upon the work non-commercially, as long as appropriate credit is given and the new creations are licensed under the identical terms.

Access this article online	
Quick Response Code:	Website: www.surgicalneurologyint.com
	DOI: 10.4103/sni.sni_68_18

How to cite this article: Singh SK, Agarwal H, Singh P, Goel K. Intraventricular metastasis mimicking meningioma. *Surg Neurol Int* 2018;9:149.
<http://surgicalneurologyint.com/Intraventricular-metastasis-mimicking-meningioma/>

Financial support and sponsorship

Nil.

Conflicts of interest

There are no conflicts of interest.

REFERENCES

1. Tagle P, Villanueva P, Torrealba G, Huete I. Intracranial metastasis or meningioma? An uncommon clinical diagnostic dilemma. *Surg Neurol* 2002;58:241-5.
2. Brant WE, Helms CA. *Fundamentals of diagnostic radiology*, 3rd ed. Philadelphia: Lippincott Williams & Wilkins; 2007. p. 143.