



Case Report

Coxiella burnetii infection of the spine requiring neurosurgical intervention

Paige Lundy¹, Paul Arnold², Kirk Hance³

Department of ¹Neurosurgery and ³Division of Vascular Surgery, The University of Kansas Health System, Kansas City, Kansas, ²Department of Neurosurgery, Carle Illinois College of Medicine, Carle Foundation Hospital, Urbana, Illinois, USA.

E-mail: *Paige Lundy - plundy@kumc.edu; Paul Arnold - paul.arnold@carle.com; Kirk Hance - khance2@kumc.edu



***Corresponding author:**

Paige Lundy,
The University of Kansas Health
System, 3901 Rainbow Blvd,
Kansas City, Kansas 66160,
USA.

plundy@kumc.edu

Received : 11 July 19
Accepted : 30 August 19
Published : 20 September 19

DOI
10.25259/SNI_205_2019

Quick Response Code:



ABSTRACT

Background: Infections from *Coxiella burnetii*, resulting in what is known as Q fever, are relatively rare and difficult to diagnose. Very few reports of spinal infection from *C. burnetii* have been reported rarely have these cases required surgical intervention.

Case Description: We report a patient with the previous vascular surgery and Q fever spinal osteomyelitis. Previously reported cases with spinal involvement have described initial infection of vascular grafts in proximity to the spine. Literature on spinal infection from *C. burnetii* reports only one case that required surgical intervention of the spine. We report a patient with L5-S1 diskitis who required surgical intervention and subsequent percutaneous drainage.

Conclusion: Spinal infections from *C. burnetii* are rare; however, in the setting of a patient with osteodiscitis with negative cultures as well as a history of significant vascular disease with stents, the diagnosis of Q fever should be entertained. Operative and interventional procedures should also be considered in these patients to help alleviate pain and maintain neurologic function.

Keywords: *Coxiella burnetii*, Osteodiscitis, Q fever

INTRODUCTION

Infections from *Coxiella burnetii*, resulting in what is known as Q fever, are relatively rare and difficult to diagnose. A wide array of clinical presentations with a typical indolent course makes them a diagnostic challenge.^[2] A known risk factors for infection are vascular prostheses and aneurysms.^[2] These sites have also been shown rarely to spread either by direct contact or through hematogenous routes to the spine.^[2] We report a patient with the previous vascular surgery and Q fever spinal osteomyelitis.

CASE REPORT

A 74-year-old man with a medical history of coronary artery disease, abdominal aortic aneurysm, and lumbar stenosis presented to the ER in January 2018 reporting severe sharp low back pain with radiation down his right lower extremity. He had recently undergone multiple vascular surgeries including repair of the right internal iliac aneurysm, which required a vascular

graft, in April 2017, and L1-4 laminectomy in July 2017. His preoperative symptoms had initially resolved; however, in December 2017, he began to have a gradual return of low back pain and radiculopathy. His neurologic examination was normal. Imaging revealed concerns for L5-S1 osteodiscitis [Figure 1]. The patient underwent IR aspiration of the L5-S1 disc space from which cultures failed to reveal a pathogen. He was started empirically on vancomycin and piperacillin/tazobactam with plans to continue this regimen for 6 weeks. A more extensive workup was also sent at that time including serology for Q fever. When titers returned with 32,000 Phase 1 immunoglobulin G, the patient was started on doxycycline and hydroxychloroquine therapy, and vancomycin was also continued. As vascular grafts are a known risk factor for Q fever infections, and the previous reports have shown an association between vascular graft and vertebral osteomyelitis, the suspicion was that our patient's infection was related to his history of vascular disease and intervention.^[4,5]

Unfortunately, despite antibiotic treatment, the patient pain progressed to the point, he was no longer able to ambulate independently. A positron emission tomography scan was performed in March 2018 that showed progression of the L5-S1 spondylodiscitis with hypermetabolic activity in the paraspinous region as well as around the right iliac artery aneurysm that directly abutted the paraspinous phlegmon. Magnetic resonance imaging (MRI) showed progression of the spondylodiscitis as well with now mild height loss at L5-S1 [Figure 2]. He was readmitted to the hospital at

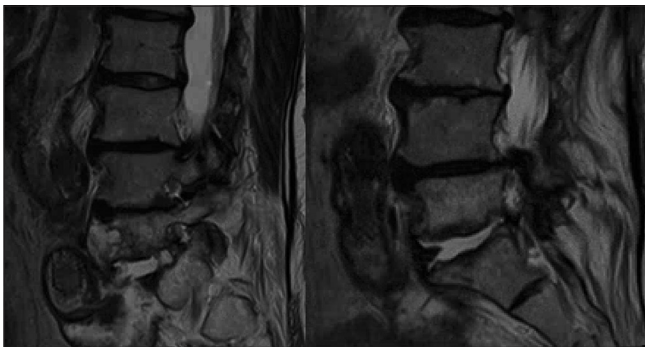


Figure 1: Initial MRI in January 2018 showing L5/S1 osteodiscitis.

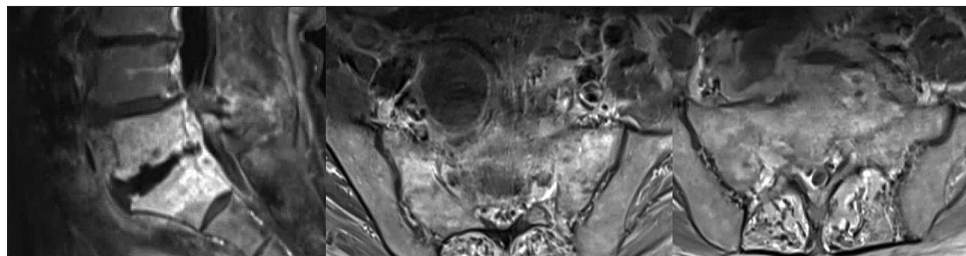


Figure 2: MRI at return in March 2018 – Increased height loss of L5 vertebral body with epidural phlegmon resulting in severe L5-S1 foraminal stenosis. An extensive prevertebral phlegmon is abutting the large right common iliac artery and graft.

that time and underwent anterior exposure to the L5-S1 disc space with discectomy and retroperitoneal washout in a combined vascular surgery and neurosurgery procedure. Under the advice of the CDC closed filtration, respirators devices were worn by all operating room staff and surgeons. The room was sealed during the operation with needed materials delivered through a one-way entrance. Cultures from the operative site again were negative for bacteria, acid-fast bacilli, and fungal organisms. Polymerase chain reaction of the pelvic tissue was positive for *C. burnetii*.

In May, the patient was reporting continue back discomfort with new severe radicular right leg pain. MRI and computed tomography angiography were obtained to reveal a recurrent fluid collection in the prevertebral space. The patient underwent IR drainage/drain placement for this and experienced resolution of his symptoms, and follow-up studies showed resolution of the fluid.

As of the last follow-up, the patient is again ambulating without assistance and has made a marked improvement with plans to continue antibiotic therapy for 12–18 months.

DISCUSSION

Q fever is a zoonosis caused by *C. burnetii*. Goats, sheep, and cattle are known reservoirs for this Gram-negative bacteria and serve as the source for human infection.^[5] Roughly 1–5% of patients progress to have chronic Q fever, which can result in years of subclinical infection.^[5] As this organism is an obligate intracellular pathogen, cultures do not yield a diagnosis. Serologic testing is the standard for diagnosing Q fever, and long-term antibiotic treatment with hydroxychloroquine and doxycycline is the current recommendations.^[5]

Pre-existing cardiovascular disease, aortic aneurysms, and vascular grafts are reported risk factor for chronic Q fever infections.^[5]

Reports of spinal involvement are limited, but this diagnosis may serve as an important differential in patients with concomitant vascular grafts and suspected osteodiscitis, especially in the case when initial spinal cultures remain

negative and traditional antibiotics fail to adequately treat infection.

O'Donnell *et al.* presented a series of six patients, all of whom suffered from *C. burnetii* infections involving vascular prosthetics.^[4] They reported a patient with vascular graft infection as well as lumbar vertebral body osteomyelitis. The patient underwent vascular graft excision with subsequent bypass and repair of a pseudoaneurysm. The vertebrae were examined and determined to be without evidence of acute inflammation or abscess formation, and thus, further spinal debridement was not reported.^[4]

Landais *et al.* performed literature review spanning 1966–2006 that identified three previous cases of pseudoaneurysm of prosthetic aortic bypass grafts and contiguous vertebral osteomyelitis.^[1] No surgical intervention was reported for the patients found in this literature review. Four patients were reviewed in detail, two of which had spinal involvement. A patient initially with L2-3 spondylodiscitis returned after 2 weeks of doxycycline and rifampin treatment with worsening back pain and was found to have extension of their infection to L4-L5 vertebrae with new epidural involvement. Hydroxychloroquine was added and the patients subsequent MRI showed reduced infiltration but persistent L2-3 and L4-5 discitis. The patient continued to have back pain at 2-month follow-up. A second patient with spinal involvement at L5-S1 including epidural abscess was initially treated for tuberculosis. The patient went onto develop a fistula from a biopsy scar. Serology of fluid from this fistula tested positive for chronic Q fever markers. After starting on doxycycline, hydroxychloroquine, and rifampicin, the patient recovered reporting no further back pain at 1 month. MRI at 1-year follow-up showed remaining inflammatory signs at L5-S1 as well as three levels above.^[4]

A recent case report from France presents a patient with destruction of the L2-3 disc space associated with an aortic stent graft that had eroded into the body of L3.^[3] This patient subsequently underwent exploration of the stent with aortobiiliac bypass and osteosynthesis of the lumbar spine. This was the only previous neurosurgical intervention found regarding treatment of *C. burnetii* in the spine.^[3] Our patient required surgical debridement due to worsening symptoms despite appropriate antibiotic management.

CONCLUSION

Spinal infections from *C. burnetii* are rare; however, in the setting of a patient with osteodiscitis with negative

cultures as well as a history of significant vascular disease with stents, the diagnosis of Q fever should be entertained. Then with proper diagnosis by serology treatment can be appropriately changed. Although rarely reported, operative and interventional procedures should also be considered in these patients to help alleviate pain and maintain neurologic function.

Declaration of patient consent

The authors certify that they have obtained all appropriate patient consent forms. In the form, the patient(s) has/have given his/her/their consent for his/her/their images and other clinical information to be reported in the journal. The patients understand that their names and initials will not be published and due efforts will be made to conceal their identity, but anonymity cannot be guaranteed.

Financial support and sponsorship

Nil.

Conflicts of interest

There are no conflicts of interest.

REFERENCES

1. Landais C, Fenollar F, Constantin A, Cazorla C, Guilyardi C, Lepidi H, *et al.* Q fever osteoarticular infection: Four new cases and a review of the literature. *Eur J Clin Microbiol Infect Dis* 2007;26:341-7.
2. Michel M, Cesini J, Michon J, Dargere S, Vergnaud M, Marcelli C, *et al.* Vertebral fractures and abdominal aortic aneurysm revealing Q fever. *Joint Bone Spine* 2016;83:241-2.
3. Mongardon N, Dubory A, Dorget A, De Wailly G, Lepeule R, Cochennec F, *et al.* Vascular infection and vertebral destruction in a patient with Q fever. *Lancet Infect Dis* 2018;18:226.
4. O'Donnell ME, Manshani N, McCaughey C, Soong C, Lee B. *Coxiella burnetii* infection of an aortic graft with multiple vertebral body erosion. *J Vasc Surg* 2007;45:399-403.
5. Wegdam-Blans MC, Kampschreur LM, Delsing CE, Bleeker-Rovers CP, Sprong T, van Kasteren ME, *et al.* Chronic Q fever: Review of the literature and a proposal of new diagnostic criteria. *J Infect* 2012;64:247-59.

How to cite this article: Lundy P, Arnold P, Hance K. *Coxiella burnetii* infection of the spine requiring neurosurgical intervention. *Surg Neurol Int* 2019;10:182.