

KUOPION YLIOPISTON JULKAISUJA D. LÄÄKETIEDE 284
KUOPIO UNIVERSITY PUBLICATIONS D. MEDICAL SCIENCES 284

TIMO KOIVISTO

**Prospective Outcome Study of
Aneurysmal Subarachnoid Hemorrhage:
Endovascular Versus Surgical Therapy**

Doctoral dissertation

To be presented by permission of the Faculty of Medicine of the University
of Kuopio for public examination in Kuopio University Hospital Auditorium,
on Saturday 7th September 2002, at 12 noon

Departments of Neurosurgery, Clinical Radiology,
Anesthesiology and Intensive Care,
Clinical Physiology and Nuclear Medicine
Faculty of Medicine
University of Kuopio



- Distributor:** Kuopio University Library
P.O.Box 1627
FIN-70211 KUOPIO
FINLAND
Tel. +358 17 163 430
Fax +358 17 163 410
- Series editors:** Professor Esko Alhava, M.D., Ph.D.
Department of Surgery
University of Kuopio
- Professor Martti Hakumäki, M.D., Ph.D.
Department of Physiology
University of Kuopio
- Professor Raimo Sulkava, M.D., Ph.D.
Department of Public Health and General Practice
University of Kuopio
- Author's address:** Department of Neurosurgery
Kuopio University Hospital
P.O.Box 1777
FIN-70211 KUOPIO
FINLAND
Tel. +358 17 172 297
Fax +358 17 173 916
- Supervisors:** Professor Matti Vapalahti, M.D., Ph.D.
Department of Neurosurgery
University of Kuopio
- Professor Juha Hernesniemi, M.D., Ph.D.,
Department of Neurosurgery
University of Helsinki
- Reviewers:** Docent Esa Heikkinen, M.D., Ph.D.
Department of Neurosurgery
University of Oulu
- Docent Simo Valtonen, M.D., Ph.D.
Department of Neurosurgery
University of Turku
- Opponent:** Professor Bryce Weir, M.D., Ph.D.
Section of Neurosurgery
University of Chicago
USA

ISBN 951-781-884-X
ISSN 1235-0303

Kuopio University Printing Office
Kuopio 2002
Finland

ABSTRACT

Background: The recent development of detachable platinum coils means that they now represent an alternative method to surgery in the treatment of intracranial aneurysms which avoids surgical trauma to the brain. Currently no prospective randomized studies have compared these two modalities of treatment.

Patients and methods: 109 consecutive patients with acute (<72h) aneurysmal subarachnoid hemorrhage (SAH) were randomly assigned to either endovascular (n = 52) or surgical (n = 57) treatment. Follow-up angiography was scheduled after clipping and 3 and 12 months after endovascular treatment. Clinical and neuropsychological outcomes were assessed 3 and 12 months after treatment; magnetic resonance imaging (MRI) of the brain was performed at 12 months. Hemodynamics and gastric intramucosal pCO₂ were measured during the first 4 hours and between 6 and 12 hours after aneurysm treatment in a sample of 26 patients. Cerebral perfusion was measured both before and one week after treatment by using ^{99m}Tc-ECD and single photon emission computed tomography (SPECT).

Results: Significantly better primary angiographic results were achieved after surgery in patients with ACA aneurysm (n = 55, *P* = 0.005) and after endovascular treatment in those with posterior circulation aneurysm (n = 11, *P* = 0.045). The technique-related mortality rate was 2% in the endovascular group and 4% in the surgical group. The overall gastric intramucosal-arterial pCO₂ difference (pCO₂ gap) and gastric intramucosal pH (pHi) remained stable. Furthermore, there were no differences in pCO₂ gap or pHi between treatment groups or Hunt&Hess grade groups during the study period. In the visual comparison between the first and second SPECT the number of new or enlarged deficits (*P* = 0.006), and deficits which expanded from being unilateral to bilateral (*P* = 0.020) significantly increased in the surgical group, but not in the endovascular group. In the semiquantitative evaluation of the second SPECT, surgical patients had regional abnormalities in the right frontobasal cortex when compared to the endovascular patients and in the ipsilateral frontobasal cortex and ipsilateral temporal apex when compared to contralateral side of the ruptured aneurysm.

In the intention to treat analysis at the one year outcome, 41 endovascular / 43 surgical patients had good or moderate recovery, 4/5 had severe disability or were in a vegetative state and 7/9 were dead. Those patients with good clinical recovery did not differ in their neuropsychological test scores. Symptomatic vasospasm, poorer Hunt&Hess grade, need for permanent and larger size of the aneurysm independently predicted worse clinical outcome regardless of the treatment modality. In MRI, superficial brain retraction deficits and ischemic lesions in the territory of the ruptured intracranial aneurysm were more frequent in the surgical group. Kaplan-Meier analysis (mean follow-up 39±18 months) revealed equal survival in both treatment groups. There were no occurrences of late rebleedings.

Conclusion: In selected patients with acutely ruptured intracranial aneurysms, endovascular treatment provides a feasible method of treatment. Surgery achieves better primary angiographic occlusion rates in most anterior circulation aneurysms while aneurysms in the posterior circulation are better treated with coils. Splanchnic tissue perfusion may be insufficient after SAH though this is independent on the modality of treatment or pre-treatment Hunt&Hess grade. Progression of perfusion deficits is more common in the surgical group than in the endovascular group. One-year clinical and neuropsychological outcomes seem to be similar after either modality of treatment, even though endovascular treatment is significantly less often associated with MRI-detectable brain injury. Repeated angiographic controls are needed to ensure the stability of the endovascular occlusion. The long-term efficacy of endovascular treatment in the prevention of rebleeding remains open.

National Library of Medicine Classification: WL 200, WL 355, WL 368

Medical Subject Headings: subarachnoid hemorrhage/therapy; aneurysm, rupture; intracranial aneurysm/surgery; embolization, therapeutic; human; comparative study; treatment outcome; randomized clinical trials; follow-up studies; perfusion, regional; splanchnic circulation; tomography, emission-computed, single-photon; magnetic resonance imaging; neuropsychological tests

To Konsta and Anne

ACKNOWLEDGEMENTS

This work was carried out in the Department of Neurosurgery, Kuopio University Hospital, in collaboration with the Departments of Clinical Radiology, Anesthesiology and Intensive Care and Clinical Physiology and Nuclear Medicine during the years 1995-2001.

My deepest feelings of gratitude are directed to Professor Matti Vapalahti, M.D., Head of the Department of Neurosurgery, my main supervisor of this work. It has been a privilege to work in his excellent department and under his personal surveillance. He has given his essential support and guidance during all phases of this study.

I owe my deepest gratitude to Professor Juha Hernesniemi, M.D., my other supervisor. I admire his dedication to neurosurgery and his extensive expertise in it. He has taught me a great deal about microneurosurgery, but also the steps of scientific research. I agree that it is easy to think up plenty of good ideas for research but the real challenge is to finish off even one of them.

I am greatly indebted to Docent Ritva Vanninen, M.D., my co-worker. Her collaboration has been essential from the very beginning of this study. In addition to being another member of our extremely skillful neurointerventional team, she has given her enthusiastic guidance and practical help whenever needed. Her clear and analytical thinking, her organizational abilities and her effective way to use time in research have always impressed me.

I gratefully acknowledge Docent Esko Vanninen, M.D., who has held an essential role during the whole study period. His extensive experience and knowledge in Nuclear Medicine made it possible to design and carry out the part of this study dealing with the disturbances in cerebral perfusion. However, his contribution was not limited to this alone. Throughout the study period he has guided me in scientific thinking, encouraged and supported me and given a lot of good advice.

I wish to express my warmest gratitude to Tapani Saari, M.D., who has been an essential member in the neurointerventional team. Without his extensive expertise in interventional neuroradiology and his willingness to be always available, this study would never have been completed.

I want to express my gratitude to Professor Jukka Takala, M.D., for originally introducing the idea of performing gastric tonometry in these critically ill patients with subarachnoid hemorrhage and creating the possibilities to carry out this part of the study in the Intensive Care Unit of Kuopio University Hospital.

I am deeply grateful to Ilkka Parviainen, M.D., for his huge contribution in analyzing the gastric tonometry data and in preparing and writing the manuscript. With his always-positive attitude, he has increased my knowledge about the mysteries of the splanchnic circulation.

I wish to express my sincere gratitude to Neuropsychologist Heleena Hurskainen, M.Sc., who diligently performed a wide pattern of special neuropsychological tests on most of our patients even though many of them were too confused to co-operate.

I thank the official referees of this study, Docent Esa Heikkinen, M.D., and Docent Simo Valtonen, M.D., for their thorough review and constructive criticism.

I wish warmly thank Mrs. Pirjo Halonen, M.Sc., from Computing Centre, University of Kuopio, for patiently advising me in the statistical analyses throughout this study.

I am grateful to Dr. Ewen MacDonald, D. Pharm., Mrs. Leslie Suhonen, M.D., and David Laaksonen, M.D., who revised the English language of the manuscripts.

I am grateful to Minna Husso-Saastamoinen, M.Sc, for her contributions to the analysis of the SPECT data and to Professor Jyrki Kuikka, M.D. for visually evaluating the SPECT data and reviewing the manuscript.

I owe my sincere thanks to Physicist Pauli Vainio, Ph.L., for his patient help in several technical problems and the genius of his advice in many other troublesome situations.

I want to thank Neuropsychologist Tuomo Hänninen, M.Sc., for his valuable comments.

I am most grateful to all my colleagues in the Department of Neurosurgery, especially Docent Jaakko Rinne, M.D., and Antti Ronkainen, M.D., for encouraging me during this study and for their collaboration in the aneurysm research in general, Matti Luukkonen, M.D., and Markku Vihavainen, M.D., they all have patiently guided me in neurosurgery. Arto Immonen, M.D., has not only shared my room but also many moments of joy and despair. It was friendly and helpful of Sakari Savolainen, M.D., to share his experiences in preparing his recent thesis with me. I am also grateful for the colleagues Sirpa Leivo, M.D., and Anu-Maaria Sandmair, M.D., for their friendship and support.

I thank all the seriously ill patients who participated in this study.

I also want to direct my gratitude to the skilful and helpful personnel in the Units of Neurosurgery, Clinical Radiology, Anesthesiology and Intensive care and Clinical Physiology and Nuclear Medicine.

I owe my sincere thanks to Tuula Bruun for secretarial assistance. I wish also to thank Information Scientist Liisa Salmi and the personnel at the Kuopio University Library, for their professional help.

There is also life beyond work and research. I want to thank all my long time friends for patiently being around despite of the lack of time to share very many activities with you, Aatu, Eske, Hiska, Jontte, Jore, Jouni, Lipponen, Mitsa, Pekka, Santtu, Urmas, Ykä and all the others. I owe my special thanks to Eero, Hedu, Ile, Jari, Jarmo, Jukka, Jymy, Masa and Tapsa for helping me to keep in fit by forcing me occasionally to leave the world of science during these years. The essential annual "Jyväskylä in my mind" meetings with Outi, Jaakko, Riitta, Petri, Mervi, Teppo, Satu and Juha have reinforced the unique friendship, which began over ten years ago while we all worked in the Jyväskylä Central Hospital. Väly, I have not forgot our old deal and Petri, you owe me a dinner!

I dedicate my dearest thanks to my parents Leena and Sakari Koivisto for their love and never ending encouragement in all efforts of mine.

Finally I wish to express my love and thanks to my dear wife Anne and our charming little son Konsta. It has not always (or never) been easy to combine research, hard work and family life. However, you have been the most important persons, making sure that I actually finished this thesis. You have made life and this process meaningful.

This research has been supported by grants from the Kuopio University Hospital, Finnish Neurosurgical Association, The Finnish Cultural Foundation of Northern Savo, Maire Taponen Foundation and Research Foundation of Orion Corporation.

ABBREVIATIONS

3D-TOF	three-dimensional time-of-flight
^{99m} Tc-ECD	^{99m} Tc-ethyl-cysteine-dimer
ACA	anterior cerebral artery
ACoA	anterior communicating artery
AVM	arteriovenous malformation
CCR	cortico-cerebellar perfusion ratio
CT	computed tomography
CTA	computed tomography angiography
DID	delayed ischemic deficit
DSA	digital subtraction angiography
EC-IC	extracranial-intracranial
GCS	Glasgow coma scale
GDC	Guglielmi detachable platinum coils
GOS	Glasgow outcome scale
H&H	Hunt & Hess scale
ICA	internal carotid artery
ICU	intensive care unit
MCA	middle cerebral artery
MIP	maximum intensity projection
MRA	magnetic resonance angiography
MRI	magnetic resonance imaging
NPV	negative predictive value
OSF	organ system failure
pCO ₂ gap	gastric intramucosal-arterial pCO ₂ difference
PCoA	posterior communicating artery
PET	positron emission tomography
Pg-etCO ₂	gut-to-end-tidal PCO ₂ difference
pHi	gastric intramucosal pH
PPV	positive predictive value
rCBF	regional cerebral blood flow
rCMRO ₂	regional cerebral oxygen utilization
rCVB	regional cerebral blood volume
rOEF	regional oxygen extraction fraction
ROI	region of interest
SAH	subarachnoid hemorrhage
SIADH	inappropriate antidiuretic hormone secretion syndrome
SIRS	systemic inflammatory response syndrome
SPECT	single photon emission computed tomography
SvO ₂	saturated venous oxygen
TCD	transcranial doppler ultrasound
THRT	transient hyperemic response test
VBA	vertebrobasilar artery
VSP	vasospasm
WFNS	World Federation of Neurological Surgeons
XeCT	xenon-computed tomography

LIST OF ORIGINAL PUBLICATIONS

The thesis is based on the following articles, which are referred to in the text by their Roman numerals:

1. Vanninen R, Koivisto T, Saari T, Hernesniemi J, Vapalahti M. Ruptured intracranial aneurysms: acute endovascular treatment with electrolytically detachable coils--a prospective randomized study. *Radiology* 1999;211:325-336.
2. Koivisto T, Vanninen R, Hurskainen H, Saari T, Hernesniemi J, Vapalahti M. Outcomes of Early Endovascular Versus Surgical Treatment of Ruptured Cerebral Aneurysms: A Prospective Randomized Study. *Stroke* 2000;31:2369-2377.
3. Koivisto T, Parviainen I, Vapalahti M, Takala J. Gastric tonometry after subarachnoid hemorrhage. *Intensive Care Med* 2001;27:1614-1621.
4. Koivisto T, Vanninen E, Vanninen R, Kuikka J, Halonen P, Hernesniemi J, Vapalahti M. Cerebral Perfusion Before and After Endovascular or Surgical Treatment of Acutely Ruptured Cerebral Aneurysms. A One-Year Prospective Follow-up Study. *Neurosurgery* 2002;51:312-326.

CONTENTS

INTRODUCTION	17
REVIEW OF THE LITERATURE	20
1. Subarachnoid hemorrhage	20
1.1. Incidence of primary subarachnoid hemorrhage	20
1.2. Etiology of subarachnoid hemorrhage	20
1.3. Intracranial aneurysms	21
1.4. Risk factors for aneurysmal subarachnoid hemorrhage	22
2. Natural history of ruptured intracranial aneurysms	22
2.1. Factors that influence prognosis	22
2.2. Rebleeding	23
2.3. Grading methods for predicting outcome	23
3. Methods for outcome assessment	24
4. Imaging studies	26
4.1. Computed tomography	26
4.2. Digital subtraction angiography	27
4.3. Magnetic resonance imaging	27
5. Management of ruptured intracranial aneurysms	28
5.1. Surgical repair of ruptured aneurysms	28
5.1.1. Technical aspects of surgical repair of ruptured aneurysms	29
5.1.2. Timing of surgical treatment of ruptured aneurysms	30
5.1.3. Outcomes in clinical trials on surgical treatment of ruptured aneurysms	31
5.1.4. Special features and limitations of surgical treatment	35
5.1.5. Improvement of surgical treatment	37
5.2. Endovascular treatment of ruptured intracranial aneurysms	37
5.2.1. The Guglielmi Detachable Coil system	38
5.2.2. Clinical trials on endovascular treatment of ruptured aneurysms	38
5.2.3. Special features and limitations of Guglielmi Detachable Coil treatment	42
5.2.4. Improvement of endovascular techniques	45

5.3. Combined endovascular and surgical treatment of ruptured aneurysms	46
5.4. Clinical trials comparing endovascular and surgical treatment of ruptured aneurysms	46
6. Splanchnic tissue perfusion in critically ill patients	47
6.1. Assessment of splanchnic perfusion	48
6.1.1. Gastric tonometry	48
6.1.2. Gastric tonometry, clinical experiences	49
7. Cerebral vasospasm	50
7.1. Etiology and pathophysiology of delayed ischemic deficit	50
7.2. Diagnostic methods of investigating vasospasm	51
7.2.1. Assessment of regional cerebral blood flow	51
7.2.2. Positron emission tomography	52
7.2.3. Radioactive and stable xenon methods	52
7.2.4. Single photon emission tomography	53
7.2.7. Diffusion and perfusion weighted magnetic resonance imaging	53
7.2.8. Transcranial doppler ultrasound	54
7.3. Treatment of cerebral vasospasm	54
7.3.1. Preventing or reversing arterial narrowing	55
7.3.2 Preventing or reversing delayed ischemic deficits and protection from infarction	56
8. Other complications of subarachnoid hemorrhage	56
8.1. Hydrocephalus	56
8.2. Seizures	57
AIMS OF THE STUDY	58
PATIENTS AND METHODS	59
1. Study design and patient selection	59
2. Diagnostic angiography and embolization procedure	60
3. Surgery	61
4. Patient care	61
5. Treatment of the non-ruptured aneurysms	62
6. Intensive care unit monitoring and gastric tonometry	62

7. Single photon emission tomography	63
8. Follow-up	64
9. Patients	66
9.1. The whole study population (Studies I-II)	66
9.2. Study III population	66
9.3. Study IV population	66
10. Statistics	69
RESULTS	71
1. Comparability of the study groups	71
2. Technical complications of endovascular treatment	71
3. Technical complications of surgical treatment	75
4. Primary angiographic results of the treatment	76
5. Cross-over between treatment groups during the primary hospitalization	76
6. Gastric tonometry	78
6.1. Hemodynamic and oxygen transport data	82
6.2. Clinical problems associated with subarachnoid hemorrhage	82
7. Single photon emission tomography	83
7.1. Visual analysis of single photon emission tomography	83
7.2. Semiquantitative regional analysis of single photon emission tomography	83
7.3. Laterality of the ruptured aneurysm and regional cerebral perfusion	84
7.4. Association between single photon emission tomography and vasospasm	84
8. Angiographic follow-up	87
8.1. Endovascular treatment group	87
8.2. Surgical treatment group	87
9. Delayed crossover treatment	88
10. Final morphological results according to intended modality of treatment	89
11. Twelve-month clinical outcomes	90
12. Neuropsychological outcomes	92
13. Twelve-month magnetic resonance imaging of the brain	93

14. Survival analysis	94
DISCUSSION	96
1. Safety of the treatment	96
2. Feasibility of the treatment in acute stage of subarachnoid hemorrhage	97
3. Efficacy of the treatment	99
3.1. Morphological results	99
3.2. Risk of rebleeding	100
3.3. Refilling of the aneurysms and angiographic follow-up	101
4. Aneurysm retreatment after embolization or surgical ligation	103
5. Clinical outcomes	104
5.1. Hydrocephalus	104
6. Twelve-month magnetic resonance imaging of the brain	105
7. Neuropsychological outcomes	106
8. Future prospects in aneurysm treatment	107
9. Medical complications and splanchnic tissue perfusion after subarachnoid hemorrhage	108
9.1. Splanchnic tissue perfusion, assessed by gastric tonometry	110
10. Vasospasm and cerebral perfusion	111
10.1. Cerebral perfusion before and after treatment, assessed by single photon emission tomography	112
10.2. Vasospasm and single photon emission tomography	114
CONCLUSIONS	116
REFERENCES	117
ORIGINAL PUBLICATIONS I-IV	

INTRODUCTION

Aneurysmal subarachnoid hemorrhage (SAH) is sudden and often catastrophic event with a 50% mortality (71, 235). Recent improvements in the management of patients with aneurysmal SAH, may have slightly decreased the case fatality rates during the last decades (106). However, it is known that only 60% of patients with aneurysmal SAH reaching neurosurgical care actually recover to lead a normal life (236), and more than 20% of patients still die (135, 236, 238). In USA it is estimated that SAH accounts over 25% of all stroke-related years of potential life lost before age 65 (124). In Finland, the incidence of primary SAH (19.5-23.4/100.000/year) is almost three times higher than in most parts of the world as reviewed by Linn et al. (161), and thus it is of our special interest to find a way to improve the outcome of these patients.

A ruptured intracranial aneurysm carries a high risk of rebleeding with a case-fatality rate of approximately 70% (199, 284). The risk of rebleeding with conservative therapy has found to be highest (4%) on the first day after SAH. It then remains constant at a rate of 1% to 2% per day during the subsequent two weeks (134). Thus, the primary aim of treating intracranial aneurysms is to prevent rebleeding by eliminating the intracranial aneurysm from the circulation while preserving blood flow through parent and branch vessels. Delayed cerebral deficit (DID) due to cerebral vasospasm (VSP) following aneurysmal SAH is the second major determinant of poor clinical outcome. It is the cause of death or disability in 14 % of the patients who reach neurosurgical care within three days after hemorrhage (135). The most common time for the appearance of DID is between day 4 and day 14 after SAH (276, 277). Thus, the secondary aim of securing a ruptured intracranial aneurysm is to permit aggressive medical or interventional treatment of arterial VSP to prevent or reverse this delayed ischemia (10, 59).

Traditionally the application of a spring clip across the neck of an aneurysm has been considered as the best way to eliminate an aneurysm from the circulation (38, 50, 52, 289, 290). Open surgery is often demanding because of the fragile and swollen brain, which is covered by a thick layer of blood in the acute stage of SAH. Manipulation of the brain and cerebral arteries during surgery may cause structural damage to the brain tissue, induce VSP and increase the frequency of delayed

cerebral ischemia (94, 101, 224, 282). To avoid these problems, several endovascular methods of treating ruptured intracranial aneurysms have been developed since 1970's (43, 51, 78, 104, 227, 239). In 1991, Guglielmi et al. (88, 90) introduced an electrically detachable platinum coil system (Guglielmi detachable platinum coil (GDC)) that permitted endovascular occlusion of the aneurysm and readjustment of the coil position before final detachment.

Clinical trials have shown GDC treatment to be efficient in preventing rebleeding, and improving the clinical outcome in comparison to simple conservative treatment of ruptured intracranial aneurysms (24, 27, 145, 216, 285). However, comparisons at recent surgical series (96, 101, 135, 136, 198, 236, 238, 291) with most endovascular series (24, 27, 145, 216, 285) have encountered a considerable bias concerning the nature of the population characteristics and the timing of the treatment after SAH. However, some data do suggest that endovascularly treated patients with ruptured intracranial aneurysms have a tendency towards suffering less neuropsychological impairment and less structural brain damage in comparison to the surgically treated patients (94).

One of the major concerns about endovascular therapy is the long-term efficacy of the treatment. In a recent systematic review of endovascular series, complete occlusion was achieved in only half of the ruptured intracranial aneurysms (20). Furthermore, occlusion of the coiled aneurysms is frequently unstable with a reported recanalization rate of 28% to 46% (98, 257). A recent series by Byrne et al. (24) reported a rebleeding rate of 7.9% in the aneurysms with an unstable occlusion during a median of 22.3 months follow-up indicating the need for long-term angiographic follow-up of the coiled aneurysms.

The severity of the initial bleeding and the clinical condition of the patient after bleeding are the most important factors predicting clinical outcome (101, 135, 189). However, medical complications after aneurysmal SAH may have a significant effect on the overall mortality rate (101, 135, 136, 149, 244, 293). Insufficient splanchnic tissue perfusion has been regarded as one of the possible mechanisms being responsible for the development of systemic medical complications (7, 155). Increased levels of catecholamines or cytokines may cause vasoconstriction in the splanchnic area and lead to deterioration of splanchnic tissue perfusion (241, 279). High levels of catecholamines in plasma have been found in patients with SAH (47). There is evidence that splanchnic ischemia occurs commonly in isolated

neurotrauma, with a trend toward development of mucosal ischemia accompanied by decreased cerebral perfusion (279). However, there are no studies about this issue concerning the patients with SAH. In theory, open surgery of the ruptured aneurysm is more traumatic to the brain than endovascular therapy, and would be predicted to be more likely to induce splanchnic hypoperfusion.

Although VSP is one of the major determinants of a poor outcome, the appropriate diagnosis before the irreversible delayed ischemic changes have developed remains problematic, especially in patients with impaired consciousness (48, 144). Clinical suspicion of VSP may be confirmed by directly addressing the effects of VSP on the regional cerebral blood flow (rCBF). In recent studies, semiquantitative single photon emission computed tomography (SPECT) has provided important data for detecting VSP (40, 207, 245).

The high incidence of SAH in Finland, the defined catchment area (900,000 people) with no referral bias, and the experience with early surgery (100, 101, 189) allowed us to design and conduct this prospective randomized study of the treatment of recently ruptured (<72 hours) intracranial aneurysms either by GDC occlusion or by conventional surgical clipping. The main objectives of the study were to compare early safety, efficacy and outcome of endovascular and surgical therapy, and to determine the differences between these treatment modalities in long-term clinical, neuropsychological and radiological (angiographic occlusion rate; magnetic resonance imaging (MRI) of the brain) outcomes. Furthermore, the prospective setting of the study meant that it was feasible to evaluate with SPECT the differences in the cerebral perfusion before and after surgical or endovascular treatment as well as determining differences in splanchnic tissue perfusion, which was assessed by gastric tonometry immediately after endovascular or surgical treatment.

REVIEW OF THE LITERATURE

1. Subarachnoid hemorrhage

SAH is a medical emergency. The typical clinical presentation of SAH is a sudden and severe headache. The onset of headache may be associated with a brief loss of consciousness, nausea and/or vomiting, focal neurological deficits or stiff neck (172). Despite the typical clinical features of SAH the differential diagnosis especially with other acute diseases presenting with headache can be difficult (269). A minor leak with a sudden transient headache can precede the major bleeding in 20-37% of cases, and recognition of this “warning sign” may increase the chances of the patient to enjoy a favorable outcome (121, 125).

1.1. Incidence of primary subarachnoid hemorrhage

Primary SAH is defined as a bleeding, which takes place primarily in the intracranial subarachnoid space, and is not a secondary manifestation of some other disease (199). In a recent systematic review of the literature, the worldwide overall incidence of SAH was 10.5. per 100.000 person years (269). However, taking into account the fact that the incidence in Japan was 23.0 / 100 000 person years and in Finland 22.0 / 100 000 person years, the incidence in other parts of the world was only 7.8 / 100 000 person years. The overall incidence of aneurysmal SAH has remained constant during the last decades (161), but increases almost linearly with increasing age (71). However, the mean age of death in patients with SAH (59 years) is considerably lower than for ischemic stroke (81 years). In the United States, SAH accounts for only 4% of stroke mortality but over 25% of all stroke-related years of potential life lost before age 65 (124).

1.2. Etiology of subarachnoid hemorrhage

The cause for primary SAH is rupture of an intracranial aneurysm in more than 80% of cases (237, 269). SAH of unknown origin represents 9% to 15% of cases (135, 228). In these cases, the pattern of bleeding is different from the aneurysmal type of bleeding. Typically, the maximum amount of blood is found anterior to the pons with

possible extension to the ambient cisterns or to the basal parts of the Sylvian fissures (223). The source of the bleeding of unknown origin can be a rupture of small perforating artery or a micro- arteriovenous malformation (AVM), which is not identifiable in diagnostic imaging (228). Intracranial artery dissections, cerebral AVMs, dural AVMs, trauma, bleeding disorders, substance abuse, a spinal origin of the hemorrhage and other rare conditions account for primary SAH in less than 5% of cases (269).

1.3. Intracranial aneurysms

An aneurysm is a persistent localized dilatation of the vessel wall. Saccular aneurysms account for the vast majority (98%) of all intracranial aneurysms. Other types of aneurysms are arteriosclerotic ectatic aneurysms (fusiform in shape), dissecting aneurysms, infectious (mycotic) aneurysms and traumatic aneurysms (289).

Aneurysms seem to be acquired lesions. Hemodynamic stress upon the arterial bifurcations and pathological changes in vessel wall predispose to aneurysm formation. Factors that alter blood flow, such as vessel occlusions, arteriovenous malformations, hypertension and connective tissue diseases may accelerate the degenerative process (275, 278).

Intracranial aneurysms are reported to be present in 1% to 5% (range, 0.2% to 8.0%) of the general population (230). The prevalence figures are clearly related with the study method. The true prevalence of intracranial aneurysms remains unknown. In large forensic clinical and autopsy series, the locations of intracranial aneurysms are internal carotid artery (ICA) (24% - 41%), anterior cerebral artery (ACA) (30% - 39%), middle cerebral artery (MCA) (20% - 33%) and vertebrobasilar arteries (VBA) (4% - 12%) (278). In our consecutive series of 1314 patients before the era of 4-vessel studies, the corresponding figures were ICA (23%), ACA (30%), MCA (39%) and VBA (7%) (224). The predominance of MCA aneurysms is often reported in other Finnish series (71, 199). In Finnish series, up to one third of the intracranial aneurysms are multiple, which has become a common clinical therapeutic problem (224, 225).

1.4. Risk factors for aneurysmal subarachnoid hemorrhage

Cigarette smoking, large size of the unruptured intracranial aneurysm, advanced age, hypertension and alcohol abuse have been recognized as risk factors for SAH (126, 127, 254). Female gender has also been recognized to predispose towards SAH but only in the age group of over 40 years. This has been suggested to be related with hormonal factors (142). In the historical Finnish series of Pakarinen (199), females outnumbered males in all age groups, though only slightly in the age groups under 60 years. However, in recent Finnish series, males are more often affected (101, 224, 235).

There is evidence that genetic factors are associated with the predisposition for SAH. In east Finland, approximately 10% of aneurysmal SAH patients have a positive family history of aneurysmal SAH or incidental intracranial aneurysms, with at least 2 affected first-degree family members (229). Within familial SAH families, the risk for harboring intracranial aneurysms among asymptomatic family members is at least 4 times higher than in sporadic SAH families (230). Familial intracranial aneurysms seem to rupture at an earlier age than their sporadic counterparts and they may be smaller when they rupture. The occurrence of aneurysmal SAH is also associated with some rare heritable connective tissue disorders such as autosomal dominant polycystic disease, Ehlers-Danlos syndrome type IV, neurofibromatosis type I and Marfan's syndrome (237).

2. Natural history of ruptured intracranial aneurysms

With conservative treatment, the outcome of aneurysmal SAH is not very impressive. According to a historical unselected series of 363 patients with ruptured intracranial aneurysms reported by Pakarinen (199) there was a 15% mortality prior to hospital admission and a mortality of 32%, 46%, 56% and 60% at day 1, week 1, month 1 and month 6, respectively.

2.1 Factors that influence prognosis

The overall outcome of SAH patients is dependent on the severity of the hemorrhage, the initial posthemorrhage clinical condition of the patient and the

occurrence of subsequent events such as rebleeding, VSP, hydrocephalus, medical complications and complications of therapy (72, 135, 164, 189, 244). Prognostic factors for mortality are: decreased level of consciousness at admission, increased age, thick clot of blood on initial CT scanning, hypertensive disease, other pre-existing medical illnesses, large aneurysm and aneurysm located in the posterior circulation (101, 135, 150, 189).

2.2. Rebleeding

In the prospective Cooperative Aneurysm Study (134), the risk of rebleeding with conservative therapy was highest (4%) on the first day after SAH and then remained constant at the rate of 1% to 2% per day during the subsequent two weeks. In his earlier series, Pakarinen (199) reported a cumulative frequency of rebleeding of 7%, 16%, 23% and 33% at week 1, week 2, week 3 and week 4, respectively. The cumulative incidence of recurrences within the first 8 weeks was 40% and within the first six months 43%. This is in accordance with the series by Locksley (163) in which the risk of recurrent bleeding was 30% within the first month and 40% within 6 months after SAH. In the series of Pakarinen (199), the mortality at first recurrence was 63.6% and at second recurrence it had risen to 86%. According to Winn et al. (284) those who survive six months still have a risk of subsequent bleeding of 3% per year and the mortality from subsequent rebleeding is as high as 67% of cases.

2.3. Grading methods for predicting outcome

Fisher (70) grading method (Table 1) for estimating the amount of cisternal blood after SAH has been widely used (101, 135, 189, 236). The problem with the classification is that there are often interobserver disagreements (248).

The most common system for grading the clinical condition after SAH is the Hunt and Hess (H&H) (114) scale (Table 1). In the original classification according to Hunt&Hess, patient grade was increased by one level in the presence of serious underlying medical disorders. On this scale, a higher grade at presentation correlates with increasingly poor clinical outcome. In 1987, the World Federation of Neurological Surgeons (WFNS) (218) proposed a new grading system (Table 1), in which two factors have been assigned to differentiate grades: consciousness level, classified

with the Glasgow coma scale (GCS) (253), and focal neurological deficits. A recent survey of published articles on SAH reported that from 1985 to 1992, 71% of authors used the H&H scale, 19% used the WFNS scale, and 10% used another scale to report the clinical results (268). Timing of the grading is important because the patient's worst clinical grade is the best predictor of outcome, especially when the patient is assessed using the WFNS scale or the GCS (28).

3. Methods for outcome assessment

Many studies on outcome after aneurysmal SAH focus on the case-fatality rate (106, 117). A large variety of grading systems have been advocated, however, outcome is still often graded in a robust way as “poor”, “fair”, or “good” (107). The most frequently specified outcome measures are the Glasgow outcome scale (GOS) (122) and the Rankin scale (212) of neurological disability, with scores ranging from 1 (no disability) to 5 (severe disability) (Table 1). These scales rely on physician-orientated global assessments. The facility with which these scales are administered and recorded has made them popular instruments. However, there have been attempts towards more specific determination of functional outcome and quality of life (26, 107, 194).

It is not uncommon for patients classified as having good neurological outcome are found to experience with some deficits in higher mental function when this is tested by sensitive neuropsychological measures. Cognitive status may be determined with the Mini-Mental State Examination (73) only, but more accurate information of the mental sequel of SAH can be achieved by performing a pattern of special neuropsychological tests (17, 18, 94, 115, 116, 162, 174, 193, 194, 226, 283). Especially sequel after rupture of an ACA aneurysm has been suggested to result in a poorer neuropsychological outcome than in the aneurysms at other sites (18). However, even modern neuropsychological tests may fail to demonstrate the potential neuropsychological impairment (4, 283). In practice, telephone interviews for cognitive status (282) may often replace the more comprehensive neuropsychological assessments. Late imaging studies may provide additional information of the extent of persisting brain tissue damage (94, 140, 283). However, normal cognitive functioning does not exclude pathological CT or MRI findings, and vice versa (226).

Table 1. The most common clinical and radiological grading systems used after subarachnoid hemorrhage (SAH).

Fisher classification (70)		Blood on computed tomography	
Grade	1	No blood detected	
	2	Diffuse or vertical layers < 1mm thick	
	3	Localized clot and/or vertical layer ≥ 1mm thick	
	4	Intracerebral / intraventricular clot with Diffuse or no SAH	
Hunt & Hess Scale (114)		Clinical findings	
Grade	0	No SAH	
	I	Asymptomatic or mild headache, mild nuchal rigidity	
	II	Moderate to severe headache, nuchal rigidity, no neurologic deficit, except cranial nerve palsy	
	III	Drowsiness, confusion, or mild focal deficit	
	IV	Stupor or mild to moderate hemiparesis; possible early decerebrate rigidity	
	V	Deep coma, decerebral posturing, moribund	
World Federation of Neurosurgical Societies (WFNS) Scale (218)		GCS*	Motor deficit
Grade	0	15	Absent and no SAH
	1	15	Absent
	2	13-14	Absent
	3	13-14	Present
	4	7-12	Present
	5	3-6	Present or absent
Glasgow Outcome Scale (122)		Clinical findings	
Grade	5	Good recovery	
	4	Moderate disability (disabled but independent)	
	3	Severe disability (conscious but disabled)	
	2	Persistent vegetative state	
	1	Death	
Rankin Outcome Scale (212)		Clinical findings	
Grade	1	No significant disability: able to carry out all usual daily routines	
	2	Slight disability: unable to carry out some previous activities but able to look after affairs without assistance	
	3	Moderate disability: requiring some help but able to walk without assistance	
	4	Severe disability: bedridden, incontinent and requiring constant nursing care and attention	

Note: *Glasgow Coma Scale (253)

4. Imaging studies

4.1. Computed tomography

If SAH is suspected, computed tomography (CT) scanning is the first diagnostic procedure to be undertaken (66, 172, 237, 269). If CT is performed within 24 hours of the bleeding, a high-density layer of blood can be seen in over 90% of cases. The sensitivity of CT declines after the first day and 5 days after the hemorrhage blood can be detected in less than 60% of patients with SAH (135). A lumbar puncture for analysis of spinal fluid should be performed in those cases where there is a negative CT scan. The diagnostic spinal tap is considered to be reliable if performed between 12 hours and two weeks after the onset of headache (280). In addition to the diagnosis of SAH, the CT scan provides information of the severity and possible origin of the bleeding as well as the hydrocephalus, the mass effect caused by a hematoma and possible ischemic complications and other brain lesions. The localization of blood has been used with a variable success rate in order to identify the ruptured aneurysm in a case of multiple aneurysms (267).

CT angiography (CTA) is based on the technique of helical CT. It requires only intravenous injection of contrast medium, being thus quicker and less invasive than conventional angiography. The technique provides a multidimensional view of the aneurysm and the adjacent structures including the bony landmarks, which is useful in any subsequent surgical procedures (5, 295). In the studies where CTA and conventional angiography have been compared, the sensitivity of CTA has been good (96-97%) and its specificity even better (90-100%) (5, 295). However, in small aneurysms (<5 mm) CTA is considered to be less reliable than conventional angiography (109). Further, difficulties may be encountered with aneurysms in proximity to the skull base (5). Recent series have indicated that good-quality CTA studies could be used as the only preoperative neuroimaging technique in a large proportion of patients with ruptured intracranial aneurysms at least in emergency situations (295).

4.2. Digital subtraction angiography

Conventional cerebral angiography is the gold standard for aneurysm detection (269). However, it can be time consuming and it is invasive with a complication rate of 1.8-2.1% (31, 96). In addition it provides limited anatomical information of the actual geometry of the aneurysm or the adjacent vessels. Three dimensional rotational digital subtraction angiography (3-D DSA) allows a multidimensional visualization of the aneurysmal and a high resolution perspective of vascular anatomy (251). The intra-arterial injections have to be prolonged (>6 seconds) if one is to achieve arterial opacification during the entire C-arm movement. The relatively high volume of nonionic contrast material and the prolonged acquisition time has been found to be well tolerated (264). Recent advances in computing technology have shortened the time required for 3-D reconstruction and the images can be obtained within ten minutes after acquisition. Furthermore, a good correlation of 3-D DSA with surgical anatomy as well as usefulness of the novel technique in planning both endovascular and surgical procedures has been demonstrated (251).

4.3. Magnetic resonance imaging

The role of MRI in the early evaluation of SAH is limited (237). Technically it is possible to detect acute SAH with a special MRI technique (FLAIR, fluid attenuated inversion recovery) as reliably as with CT (190) but MRI tends to be impractical because it is time consuming and confused patients cannot be studied without sedation and assisted ventilation (269). However, in the subchronic stage of SAH, MRI is superior to CT in detecting subarachnoidal blood (192). In addition, diffusion-weighted sequences can be used to detect ischemic complications more accurately than can be achieved CT (79).

Noninvasive three-dimensional time-of-flight (3D-TOF) MRA has been found to be especially useful in the preprocedural evaluation of ruptured intracranial aneurysms with a complex anatomy. It is also useful in the assessment of thrombosed aneurysms. However, caution has to be advocated with respect to the small aneurysms and aneurysms located close to the skull base (3). The newly developed endovascular methods in treating intracranial aneurysms have stressed the need for a noninvasive method for long-term monitoring of the stability of

occluded aneurysms. 3D-TOF MRA with postprocessing using targeted maximum intensity projection (MIP) reconstructions seems to hold promise for this purpose. However, it is limited in its ability to detect the small aneurysm remnants (19, 129).

5. Management of ruptured intracranial aneurysms

The natural history of the ruptured intracranial aneurysms obligates an early treatment of these lesions. The goal of the treatment is to prevent rebleeding by occluding the ruptured aneurysm. In recent years the trend has been towards early treatment (within three days after SAH), although there is no conclusive evidence that this is truly beneficial (29, 66, 72, 135, 136, 195).

5.1. Surgical repair of ruptured aneurysms

The first surgeon to operate a ruptured intracranial aneurysm was Dott (50), in 1931, who packed the aneurysmal sac with muscle to reinforce the aneurysm wall. In 1938 Walter Dandy (38) was the first to occlude an intracranial aneurysm by clipping its neck. In the 1950's ruptured intracranial aneurysms were diagnosed with angiography and treated operatively in many centers. However, in 1959, based on a retrospective detailed analysis of 599 either conservatively or operatively treated patients with angiographically proven ruptured intracranial aneurysms, McKissock et al. (175) concluded that although surgical treatment appeared to benefit patients when only gross mortality figures were considered, this was simply because only the better patients were selected for surgery. The conclusion was that if the populations of conservatively and surgically treated patients were similar, the mortality figures would be identical. In 1971 Troupp and af Björkestein (261) published their prospective controlled trial of late surgical versus conservative treatment of intracranial aneurysms involving 178 SAH patients of good clinical grade. They concluded that good grade patients have such a good natural prognosis that the value of late surgery appeared limited.

The results of operative treatment were poor until the advances in neurosurgical techniques and neuroanesthesia in the late 1960's allowed neurosurgeons to treat successfully the majority of intracranial aneurysms (52). The goal for surgical treatment of intracranial aneurysms is to eliminate the aneurysm from the circulation

while preserving blood flow through parent artery and branch vessels. This treatment is best accomplished by direct clip placement across the aneurysm neck.

5.1.1. Technical aspects of surgical repair of ruptured aneurysms

Surgical aneurysm operations are mostly performed under general anesthesia and using the microsurgery techniques introduced by Yasargil (289-291). Microneurosurgical instrumentation includes a microscope, a head fixation device, a self-retaining brain retractor, arm rest, bipolar coagulation, scissors with a smooth closing action, small caliber suction tip, high-speed drill and a variety of different aneurysm clips with their applicators (289). The clips for temporary occlusion of the parent artery have a low closing force in order not to cause permanent damage to the vessel wall. To achieve permanent clipping, there are multiple choices of clips in different sizes, shapes and closing forces. The modern clips are MRI compatible (202).

An operative approach must take into account the location of the aneurysm and it should allow minimal brain retraction. According to Yasargil (289), the most useful approaches are: 1) pterional craniotomy for aneurysms of the anterior circulation and upper basilar artery, 2) paramedian frontal craniotomy for pericallosal artery aneurysms 3) lateral suboccipital craniotomy for the aneurysms of the vertebral circulation below the origin of the superior cerebellar arteries (289, 290). Drake (55), however, favored a subtemporal approach for most of his upper basilar artery aneurysms.

Using gentle brain retraction the arachnoid cisterns are entered with sharp dissection and finally the aneurysm and the adjacent vessels are exposed with a meticulous dissection. Prior to application of the clip, the aneurysm neck must be free of adhesions to surrounding arteries and neural structures. In narrow necked aneurysms, the clip can be placed across the aneurysm neck. However, in complex aneurysms several clips may be needed to appropriately occlude the aneurysm in a stepwise manner (101, 289, 290). Although most aneurysms are amenable to clipping, their size, location, morphology, or the technical difficulties encountered may sometimes prevent the procedure. Alternative techniques for treating these unclipable aneurysms include proximal vessel occlusion with or without extracranial-intracranial (EC-IC) bypass, trapping, wrapping or excision of the aneurysm (55, 233, 246, 289,

290). Proximal endovascular balloon occlusion for unclipable aneurysms may provide a convenient and effective option of producing arterial occlusion (54).

5.1.2. Timing of surgical treatment of ruptured aneurysms

The optimal timing for surgical treatment of the acutely ruptured aneurysms was under constant investigation and a subject of major controversy during the 1980s (29, 134-136, 195, 250). In the 1960s, operative treatment was still generally delayed 3 to 4 weeks following SAH so that the brain could recover from the acute effects of SAH. However, mortality and morbidity during the waiting period was high because of occurrence of VSP and rebleeding (136). An operation during an early phase (within 72 hours following SAH) or even during the acute phase (within 24 hours following SAH) was considered justifiable in order to prevent early rebleeding and allow aggressive treatment of VSP, and thus improve the outcome of the patients.

The nonrandomized International Cooperative Study on the Timing of Aneurysm Surgery (135, 136) carried out between December, 1980, and July, 1983 did not find any major differences between the outcomes of the patients treated either with early (≤ 3 days) or delayed surgery (> 10 days). In contrast to these results, the North American Participants of the Cooperative Study (96) found evidence for early surgery in evaluating the data of patients treated in North America. In accordance with these results were the results achieved by early surgery simultaneously in Lund, Sweden and in Kuopio, Finland during the calendar year 1982 (272). The results of the only randomized study on timing of surgery by Öhman et al. (195) favored early surgery compared with surgery on days 4 to 7, with respect to the achievement of independence at the 3-month follow-up. However, in the overall outcome at 3 months after the SAH there was only a trend toward better results in the acute surgery group. In the population-based study of Fogelholm et al. (72) patients having undergone early surgical treatment had better functional outcome than those with delayed surgery. However, early surgery only marginally improved survival.

Although the data available is not consistent, early surgery for patients in good preoperative clinical grade (Hunt&Hess Gr I-III) has gradually been accepted as treatment policy in many institutions (101, 195, 198, 236, 238). Delayed surgery for patients in poor preoperative clinical grade, however, may be advisable unless immediate surgical intervention is required because of large hematoma or severe

hydrocephalus (100, 101, 203). On the other hand, the results of recent systematic review of the literature published between 1974 and 1998 suggested that both early and intermediate surgical treatment can improve the outcome after SAH especially in good grade patients but to a lesser degree also in patients with poor preoperative grades (42).

5.1.3. Outcomes in clinical trials on surgical treatment of ruptured aneurysms

The results of management outcome in patients with aneurysmal SAH have not been reported in a standardized manner. The reports should include data on neurological condition at admission, other prognostic factors such as primary CT findings, and the overall management results (42). Another severe problem is the selection bias related in most of the surgical series, especially in those studies conducted in large referral centers (281). The following studies (101, 135, 136, 198, 236, 238) have been chosen to demonstrate the overall management results or surgical results in referral centers with an active admission policy allowing early treatment of ruptured aneurysms. The overall management outcomes (135, 136, 236, 238) and surgical outcomes (101, 135, 136, 198, 238) have been summarized in the Tables 2 and 3.

The prospective International Cooperative Study on the Timing of Aneurysm Surgery (135, 136) studied patients treated between 1980 and 1983 (Table 2 and 3). Both the surgical and management outcomes were reported for a total of 3521 patients. There was, however, a considerable selection bias since 5358 patients were excluded from the study, mainly because they were admitted more than 3 days post-SAH (46% of cases). Although more than 75% of the patients were admitted in good clinical condition, only 58% of the overall 3521 patients and 68% of the surgically treated 2922 patients were classified as being independent at the follow-up examination. Prognostic factors for poor clinical outcome were decreased level of consciousness due to the initial bleeding, thick layer of blood on admission CT, larger size of the aneurysm, advanced age (almost linearly), pre-existing medical conditions and higher blood pressure on admission. In terms of overall management results, patients with ACA and VBA aneurysms fared worse than patients with ICA or MCA aneurysms. However, this difference was not noted in the surgical results. Aside from the direct effects of the initial hemorrhage, VSP was the leading cause of unfavorable

Table 2. Management outcomes according to clinical grades, aneurysm sites and aneurysm sizes in the recent large series of surgical treatment of patients with acutely ruptured aneurysms including overall procedural morbidity / mortality rates.

Study	Number of patients with SAH	Average follow-up time	Site of the ruptured Aneurysm n (%)		Outcome GOS (%)			Hunt & Hess Grades (n / %)		Outcome GOS (n%)			Overall Morbidity / Mortality						
					GR/MD	SD/VS	Death			GR/MD	SD/VS	Death							
Kassell et al. -90 (137, 138)	3521	GOS at 6-months	ICA	1051 (30)	68	8	24	I-II	1722 (49)	82	5	13	16 % / 26 %						
			MCA	786 (22)				III	1136 (32)					64	8	28			
			ACA	1374 (39)				IV-V	663 (19)								31	12	57
			VBA	203 (6)															
Seiler et al. -88 (236)	153	GOS at 6-months	ICA	40 (26)	67	6	27	I-II	82 (53)	67	6	27	14 % / 27 %						
			MCA	23 (15)				III	24 (16)										
			ACA	76 (50)				IV-V	47 (31)										
			VBA	14 (9)															
Säveland et al. -92 (247)	325	GOS at 12 months	ICA	70 (21)	GR 60	MD-SD 29	Death 11	I-II	72 (50)	80	12	9	23 % / 21 % (Procedural morbidity / mortality 7 %; 276 had surgery)*						
			MCA	93 (29)				III	53 (16)					56	26	18			
			ACA	136 (42)				IV-V	110 (34)								20	37	43
			VBA	26 (8)															

Note: * Procedural morbidity and mortality figures are included because the surgical results could not be derived from this series for more detailed presentation as could be done from the series of Kassell et al. (137, 138) and Seiler et al. (236) (Table 3).

MCA = middle cerebral artery, ACA = anterior cerebral artery, anterior communicating artery, pericallosal artery

ICA = internal carotid artery, ophthalmic artery, posterior communicating artery, anterior choroidal artery, VBA = vertebrobasilar arteries

GOS = Glasgow Outcome Scale (124)

GR = good recovery, MD = moderate recovery, SD = severe disability, VS = vegetative state

Table 3. Surgical outcomes according to clinical grades, aneurysm sites and aneurysm sizes in the recent large series of patients with acutely ruptured aneurysms including overall and procedural morbidity / mortality rates.

Study	Number of SAH patients with early surgery	Average Follow-up Time	Site of the ruptured Aneurysm n (%)		Outcome GOS (%)			Hunt & Hess Grades (n / %)		Outcome GOS (n%)			Overall Morbidity / Mortality (%)	Procedure Related Morbidity / Mortality (%)			
					GR/MD	SD/VS	Death			GR/MD	SD/VS	Death					
Kassel et al. -90 (137, 138)	1478 / 2922 (51%)	GOS at 6-months	ICA	882 (30)	79	8	13	I-II	1882 (64)	87	5	8	18 / 14	3.5 – 10.0 (according to timing of surgery, not reported in detail)			
			MCA	707 (24)	80	7	13	III	727 (25)	72	9	19					
			ACA	1104 (38)	76	7	17	IV-V	313 (11)	39	22	39					
			VBA	190 (7)	78	10	12										
Seiler et al. -88 (236)	58 / 115 (50%)	GOS at 6-months	ICA	34 (30)	85	7	8	I-II	77 (66)	85	7	8	16 / 8	2.6 / 3.5			
			MCA	20 (17)				III	19 (17)								
			ACA	53 (46)				IV-V	19 (17)								
			VBA	8 (7)													
Hernesniemi et al. - 93 (101, 189) (1007 patients including 60 patients with UIA:s)	524 / 947 (55%)	GOS at 12-months	ICA	205 (22)	78	8	14	I-II	558 (59)	91	4	5	24 / 14 (at one year)	6.9 / 3.9 (In the whole series of 1007 patients with surgery)			
			MCA	335 (35)				III	290 (31)						68	13	19
			ACA	350 (37)				IV-V	99 (10)								
			VBA	58 (6)													
Osawa et al. -01 (198)	1685 / 2055 (82%)	GOS at discharge	ICA	555 (27)	68	19	13	I-II	1057 (51)	86	9	5	19 / 13	? / 2.6			
			MCA	598 (29)	68	18	14	III	567 (28)	65	22	13					
			ACA	777 (38)	69	19	12	IV-V	431 (21)	32	37	31					
			VBA	125 (6)	70	19	11										

*Note: MCA = middle cerebral artery, ACA = anterior cerebral artery, anterior communicating artery, pericallosal artery
ICA = internal carotid artery, ophthalmic artery, posterior communicating artery, anterior choroidal artery, VBA = vertebrobasilar arteries
GOS = Glasgow Outcome Scale (124), GR = good recovery, MD = moderate recovery, SD = severe disability, VS = vegetative state*

results and resulted in death or disability in 13.5% of the patients studied. Rebleeding was the second most prominent cause of mortality and mortality, producing unfavorable results in 7.5% of patients.

The defined hospital populations of patients and aneurysms as well as the overall management outcomes in the retrospective study of Seiler et al. (238) and the prospective study of Säveland et al. (236) were in accordance with the populations and results of the Cooperative Study (135). Accordingly the surgical outcomes were clearly better than the overall outcomes. The results are summarized in Tables 2 and 3. However, although the surgical results in the series of Säveland et al. (236) were in accordance with the other two studies, they could not be summarized in detail, thus those results have been omitted from Table 2. In this series the overall percentage of full recoveries was 56% versus 66% in surgically treated patients; with the corresponding mortality rates being 21% versus 11%.

Delayed ischemia accounted for 13% of unfavorable outcomes in both the studies of Seiler et al. (238) and Säveland et al. (236), while in the Cooperative Study (135) DID caused 32% of the unfavorable outcomes. The difference may be explained by the fact that in contrast to the Cooperative Study (135) most of the patients received nimodipine in both of the first mentioned studies (236, 238). Rebleeding caused unfavorable outcomes in 9.8% of the patients in the study of Seiler et al. (238), in 7.5% of the patients in the Cooperative Study (135) and in 4.3% of patients in the study of Säveland et al. (236). Approximately half of the surgically treated patients in the Cooperative study (135) and in the study of Seiler et al. (238) underwent surgery within 3 days after SAH, while in the study of Säveland et al. (236) the corresponding proportion of patients was 72%.

In the retrospective hospital based study of Hernesniemi et al. (101, 189), 55% of patients underwent early surgery. This series contains 1150 patients with intracranial aneurysms. Surgical cases, and patients with multiple bleedings and emergency surgery are included in the analysis. Morbidity (24%) and mortality (14%) rates are comparable with the rates in the Cooperative Study (135) (Table 3). Accordingly preoperative clinical grade (Hunt&Hess), age of the patient and size of the aneurysm were strongly related to outcome. The best results were obtained in the ACA aneurysms; the lowest rate of useful recoveries was achieved in the VBA aneurysms. The retrospective hospital based study of Osawa et al. (198) include surgical results of 2055 patients treated between 1988 and 1998, thus representing

modern standards of surgical and medical treatment of aneurysmal SAH. Eighty-two percent of patients were treated within 3 days of SAH. Mortality and morbidity rates are comparable with the aforementioned studies. The outcome of basilar artery aneurysms was significantly poorer compared to other sites including vertebral artery aneurysms. However, in this study the outcomes have been evaluated at discharge, which makes it difficult to compare these figures with the data from other series (Table 3). In the Hernesniemi study (101, 189), mortality increased by four percent between discharge from the hospital and the one-year follow-up.

5.1.4. Special features and limitations of surgical treatment

There are several instances where surgical treatment of acutely ruptured aneurysms is either challenging or even impossible. Recent prospective series reported a frequency of 30% of intraoperative complications resulting in poor outcome in 7.9% of the patients (74). Swelling of the brain accounted for 29% of all intraoperative problems, although a swollen and tight brain did not appear to be a serious practical problem in another series (136). However, patients with severe bleedings and poor clinical grades have not usually been considered as good candidates for early surgical treatment (101, 238). In particular, giant aneurysms and posterior circulation aneurysms that pose anatomic difficulties may be too hazardous to be surgically treated during the early phase after SAH (100, 152, 203). On the other hand, it may be possible to differentiate those poor grade patients and patients with posterior circulation aneurysms in whom the early surgical intervention is feasible (11, 105, 152, 203).

Perioperative rupture of the aneurysm has been reported to occur in 6% to 21% of cases (13, 55, 74, 101, 113). This event may occur during clipping, aneurysm dissection, brain retraction, hematoma evacuation or even more prematurely, immediately after the dural or arachnoid opening (13, 55, 101, 113). Very premature rupture tends to be a catastrophic event with a high mortality (113). Presumably the dissection technique and the surgeons experience are factors that influence the incidence of premature rupture and its outcome. A premature rupture may be handled by using suction, cottonoid tamponation and temporary ligation of the proximal parent artery (55, 289). In the posterior circulation aneurysms, a premature rupture may double the morbidity and mortality even in the most experienced hands

(55). In the series of Batjer et al. (13), 88% of the patients with uneventful operative procedures had favorable outcomes, whereas only 62% of the patients suffering intraoperative rupture recovered well. However, in anterior circulation aneurysms, perioperative rupture may not have any major influence on outcome, but temporary ligation or inadvertent ligation of a main vessel during the acute stage of SAH may often be catastrophic (101).

A special group of patients are those with multiple aneurysms. Many aneurysms may be approached at one session, but certain contralateral aneurysms and aneurysms in other unreachable locations may necessitate a second-stage operation. Ligating many aneurysms inevitably leads to increased manipulation of the brain and the adjacent arteries, thus potentially adversely affecting the outcome (224).

Incidence and natural history of surgical aneurysm remnants

It is generally considered that incomplete clipping of the aneurysms rarely occurs. Feuerberg (63) reported 3.8% of aneurysm remnants in a series of 715 patients with routine immediate follow-up angiography. Of the 147 clipped aneurysms, 8.2% displayed a residual neck on immediate postoperative angiography in the study of David et al. (39). Tsutsumi et al. (262) studied 454 clipped aneurysms postoperatively and reported aneurysm remnants in 7.3% of those cases. Sindou et al. (242) reported 5.9% of incompletely clipped aneurysms in a series of 305 operated patients. A recent systematic review of the literature summarized the overall incidence of 5.2% of incompletely clipped aneurysms (256).

There are few data on the long-term angiographic follow-up of surgically treated aneurysms. Even those aneurysms with perfect clip position on immediate control have been reported to regrow in 1.5% to 2.4% of cases (39, 262). The clip may slip from the aneurysm neck or growth may occur apparently from a tiny bit of the neck that has remained unobserved after clipping (160). Regrowth from an aneurysm remnant has been reported in 5% to 25% of cases (39, 63, 262), and in broad-based residual necks, the frequency may be significantly higher (75%) (39). On the other hand, spontaneous thrombosis or a decrease of the remnant may occur in up to 35% of the cases (63). The risk of hemorrhage of an aneurysm remnants may be 0.4% to 1.9% / year (39, 55, 63). Tsutsumi et al. (263) calculated a 9.0% cumulative recurrence rate at 20 years after SAH. In their series, 2 of 6 rebleedings were from

de novo aneurysms, which had not been visible in the original angiography. With respect to these data long-term angiographic follow-up is suggested for those patients with aneurysms with known residual necks, and for young patients even when there has been complete clipping of the aneurysm (39, 160, 262).

5.1.5. Improvement of surgical treatment

There are constant improvements in the performance of operating microscopes, more and more sophisticated clips and surgical micro instruments. Several diagnostic and therapeutic advances in the management of SAH have emerged during the last decades. There is no direct evidence that the improvement in surgical technique has actually improved the outcome of patients. However, there is no doubt that profound experience in microsurgery gives better results. Improvements in neuroanesthesia, critical-care techniques and the management of VSP in addition to a policy of earlier treatment may be associated with the improved outcome observed during the last decades (49, 72, 106, 149).

5.2. Endovascular treatment of ruptured intracranial aneurysms

Several endovascular treatment techniques for intracranial aneurysms have been developed over the past 20 years. These techniques were initially intended for use in those patients with aneurysms that were considered unclipable or in patients with a high risk for morbidity and/or mortality. In 1974 Serbinenko (239) published results of endovascular balloon occlusion of the carotid artery for treatment of unclipable aneurysms. Subsequently, silicon and detachable balloons were used to induce aneurysm thrombosis by occlusion of the parent vessel (43) and by trapping the aneurysm with two balloons (16). In 1982 Romodanov and Scheglov (227) reported a series of 93 patients who had their intracranial aneurysms completely occluded using a detachable balloon catheter without compromise of the parent vessel. In several subsequent reports, detachable balloons were advocated to pack the aneurysm sac allowing the preservation of the parent vessel (102-104). However, the rate of morbidity and mortality in these series was high.

In 1990 Graves et al. (78) reported the treatment with platinum coils of 21 experimental aneurysms of the lateral wall of the carotid artery. Thrombogenic coils

augmented with silk fibers resulted in total thrombosis of the aneurysm in only 40% of the treated aneurysms. Dowd et al. (51) were among the first to introduce platinum coils into intracranial aneurysms. These “free coils” were pushed through the microcatheter with a separate delivery wire. The problem with these coils was that they were impossible to control during deposition.

5.2.1. The Guglielmi Detachable Coil system

In 1991 Guglielmi et al. (88, 90) introduced an electrically detachable coil system (GDC) that permitted readjustment of the coil position before its final detachment. The GDC system consists of a platinum coil attached to a stainless steel delivery wire (pusher). The pusher has been coated for electrical isolation with the exception of the most distal part: the detachment zone. A guiding catheter is used in advancing to the ICA or vertebral artery. A microcatheter with 2-tip-markers and a guidewire are used for hyperselective catheterization of the aneurysmal sac. The distal end of the microcatheter is shaped with steam to tailor the vascular geometry before catheterization. Digital road mapping may be used in order not to touch the aneurysmal wall with the guidewire or catheter. A continuous pressurized flush of heparinized saline is maintained in both the guiding catheter and the microcatheter. The aneurysm sac is then filled with coils of selected shapes and sizes. The system allows the removal of the coil as well as repositioning of the mesh to an optimal position. When the coil is seen to be in a suitable position inside the aneurysm, positive direct electric current is applied to the proximal end of the stainless steel guidewire. The current provokes thrombus formation in the aneurysmal cavity and dissolves the uninsulated stainless steel coil closest to the platinum coil resulting in detachment of the coil (87, 90). Recently, several other detachable platinum coils have been developed.

5.2.2. Clinical trials on endovascular treatment of ruptured aneurysms

Most of the reports of patients treated by coil embolization for ruptured intracranial aneurysms have dealt with the short-term efficacy and procedural safety. In comparison with the recent large surgical series (96, 101, 135, 136, 198, 236, 238) most endovascular series (24, 27, 145, 216, 285) present with a considerable bias

concerning the nature of the population characteristics and the timing of the treatment after SAH. Due to the heterogeneity of the populations treated with coils comparison of the results is difficult. A summary of the results of the pivotal endovascular series is presented in Table 4.

The largest study to date for the GDC embolization of recently ruptured aneurysms is the United States Food and Drug Administration-approved study (285) consisting of 403 patients. Posterior circulation aneurysms as well as large and giant aneurysms were over-represented. All aneurysms were treated within 15 days of rupture and 37% of the aneurysms within 48 hours of rupture. Complete aneurysm occlusion was detected in 70.8% of small aneurysms with a small neck, 35% of large aneurysms, and 50% of giant aneurysms. Overall rates of 8.9% morbidity and 6.2% mortality were observed. The mortality related to the GDC technique was 1.7%. Most patients had at least a 6-month clinical follow-up though this report does not present any systemic follow-up data (Table 4). The study of Malish et al. (167) seems to contain partially overlapping data with the above study and examined the midterm (Range for period from 2 to 6 years) clinical follow-up results of 48 patients presenting with SAH (Hunt&Hess grade I-II, 67%; III, 15%; IV-V, 19%). With respect to those patients with H&H grade I-II, 91% experienced an excellent or good recovery and 9% had a fair or poor recovery. Of patients of H&H grade III, 86% had an excellent or good recovery and 14% had a fair recovery. However, for patients with grade IV-V only 22% had fair or poor recovery and 78% died. Sixty-six percent of the ruptured aneurysms were located in the posterior circulation and the vast majority of the patients were considered very poor candidates for surgery. Only 17% of the patients with SAH were treated within 3 days after the hemorrhage.

Raymond and Roy presented (216) a series of 75 patients with acutely ruptured aneurysms treated with GDCs. The 6-month angiographic follow-up data was available for 50 (67%) patients of whom 88% had complete or nearly complete occlusion of their aneurysms. Eighty-two percent of patients with Hunt&Hess grades I-III had good 6-month clinical outcomes with procedure related morbidity and mortality of 8% (Table 4).

The recent series of Cognard et al. (34) consisted of 150 patients with SAH (Hunt&Hess grade 0, 9%; I-II, 78%; III, 9%; IV-V, 21%). Altogether 132 of 150 ruptured aneurysms were successfully treated. Clinical follow-up data for at least a 3-month period was available for 120 patients. Excellent outcome and moderate

Table 4. Summarized results of the pivotal clinical series of endovascular treatment of patients with acutely ruptured intracranial aneurysms.

Study	Number of Patients with SAH / Average Follow-up Time		Site of the ruptured Aneurysm (%)		Hunt & Hess Grades (%)		Outcome (GOS / Other Outcome Data) (%)		Overall initial Complete Occlusion Grade or Occlusion Grade According to Aneurysm Size (%)		Overall Final Occlusion Grade / Stability Of The Aneurysm Follow-up (%)		Overall / Procedure Related	
													Morbidity (%)	Mortality (%)
Casasco et al. -93 (27)	67	GOS at 6-months Angiography at 13-months (65/71 pts)	ICA	25	I-II	69	Good / Moderate	89	< 10 mm (n=31)	94	Complete	83	4.2	11.3
			MCA	6	III	18	SD / Vegetative	0	11-25 mm (n=23)	82	Near complete	12		
			ACA	10	IV-V	13	Death	11	> 25 mm (n=6)	60	Incomplete	5	rebleeding rate: 2 / 67 = 2.8%	
			VBA	59										
Vinuela et al. -97 (285)	403	GOS at discharge Immediate angiographic results presented	ICA	27	I-II	46	"Unchanged"	85	< 10 mm (n=168) with neck ≤ 4 mm	71	Complete	NA	NA	6.2
			MCA	3	III	30	"Deterioration"	9	< 10 mm (n=77) with neck > 4 mm	31	Near complete	NA	8.9 rebleeding rate: 9 / 403 = 2.2% (≈ 6-36 mo f-up)	1.7
			ACA	13	IV-V	24	Death	6	11-25 mm (n=140)	35	Incomplete	NA		
			VBA	57									> 25 mm (n=18)	50
Raymond and Roy -97 (216)	75	GOS and *angiography at 6-months * 50/75 patients	ICA	26	I-II	41	Good / Moderate	72	Complete	40	Complete	46	10.6	23.0
			MCA	9	III	40	SD / Vegetative	5	Near complete	37	Near complete	42	4.0 rebleeding rate: 4/75 = 5.0%	4.0
			ACA	17	IV-V	19	Death	23	Incomplete	19	Incomplete	12		
			VBA	48										
Kuether et al. -98 (145)	31	GOS 2.2 years *Angiography 1.5 years, combined data (ruptured and unruptured)	ICA	36	I-II	52	Good / Moderate	74	Complete	41	Complete	41	NA	6.5 in SAH patients
			MCA	4	III	16	SD / Vegetative	19	Near complete	50	Near complete	46	9.1 rebleeding rate: 2.9% (whole series)	7.8 (whole series) 6.4 (2/31 of the pts with SAH)
			ACA	13	IV-V	32	Death	7	Incomplete	9	Incomplete	13		
			VBA	47										
Byrne et al. -99 (24)	317	6 Month GOS from 98.7% of patients	ICA	22	I-II	76	Good / Moderate	81	< 10 mm (n=176)	66	Stable	85.3	NA 5 / 259 pts had rebleeding (1.9%)	NA
			MCA	16	III	13	SD / Vegetative	14	11-25 mm (n=81)	58	Recurrence	14.7		
			ACA	26	IV-V	11	Death	5	> 25 mm (n=2)	50	Improved occlusion grade	8.5 (?)		
			VBA	35										
Brilstra et al. -99 (20) Meta-analysis of series reported before 1999	509	509 aneurysms in 509 patients Outcome data from min. 436 pts	ICA	22	I-III	80	Good / Moderate	89	Complete	52	Complete	NA	7.5	10.9
			MCA	2			SD / Vegetative	3	Near complete	32	Near complete	NA		
			ACA	18	IV-V	20	Death	8	Incomplete	6	Incomplete	NA	1.1 rebleeding rate: 16 / 509 (?) = 3.1% / years?	2.4
			VBA	58										

Note: NA = Not available

MCA = middle cerebral artery, ACA = anterior cerebral artery, anterior communicating artery, pericallosal artery

ICA = internal carotid artery, ophthalmic artery, posterior communicating artery, anterior choroidal artery, VBA = vertebrobasilar arteries

GOS = Glasgow Outcome Scale (122)

GR = good recovery, MD = moderate recovery, SD = severe disability, VS = vegetative state

disability of the patients was seen in 81% and 7% of patients respectively. Fifteen (11%) of the 132 patients died, technique-related mortality was 3%. Immediate total occlusion rate was 79% of all aneurysms.

Debrun et al. (44) presented their series of 144 patients of whom 55 patients with ruptured aneurysms and 89 patients with unruptured ones. For the patients with SAH (Hunt&Hess grade I, 24%; II, 29%; III, 25%; IV, 14% and V, 7%), an excellent outcome was seen in 74%, with procedure-related morbidity and mortality of 3.6% and 1.8% respectively. The data is presented differentiated into two groups representing the early and late experience in their series.

Kuether et al. (145) examined clinical and angiographic outcomes from 74 patients with aneurysms of whom 31 presented with SAH. At least a six-month clinical follow-up was available for all patients with SAH. Of the patients of H&H grade I-II, 81% were independent, 6% were moderately disabled and 13% died (2 procedure related deaths). All the patients of grade III showed a good clinical outcome. Half of the patients with Grade IV-V recovered to independent status, 30% were left severely disabled and 20% died. Taking into account the unruptured patients, they observed 9.1% morbidity and 7.8% mortality rates related to GDC embolization (Table 4).

Byrne et al. (24) reported their five-year experience of coil treatment for ruptured aneurysms in 317 patients. The median clinical follow-up time was 22.3 months, which was available for 98.7% of patients. Excellent or good outcomes measured at 6 months post treatment were achieved in 87.8% of patients with WFNS grades I and II, in 71.4% of patients with WFNS grade III and in 48.5% of patients with WFNS Grade IV and V. Angiographic assessment of the degree of occlusion was made in 259 aneurysms in 250 (84.2%) of the available 297 patients between 6 and 12 months after coil embolization. Following the treatment, 64% of the aneurysms were completely occluded, 34% had small remnants and 5% had more substantial residual filling. In all, 85.3% of the followed-up aneurysms remained stable or demonstrated an improved degree of occlusion, 14.7% of the aneurysms were enlarged to some degree (Table 4).

In 1999 a systematic review included an analysis of all available studies of aneurysms treated by embolization with coils (20). Five hundred and nine patients in 14 studies had ruptured intracranial aneurysms. The sites of the aneurysms were available from all patients, the clinical grades only from 488 patients and the time

interval between embolization and SAH from 436 patients. Aneurysm occlusion grades were available from all 509 patients but clinical follow-up data only from 93 patients (Table 4). The deviation from normal population characteristics of the ruptured aneurysms is clearly demonstrated by the inability of the study to find any relation between outcome measures and aneurysm size, the aneurysm being ruptured or unruptured or any baseline characteristics. Although the severity of the initial bleeding has been consistently shown to be the most important predictive factor for late complications and outcome (135, 189), in this review no such relation could be found (20).

5.2.3. Special features and limitations of Guglielmi Detachable Coil treatment

Size, location and morphology of the aneurysms

Factors that reportedly affect the success rate in endovascular coil occlusion include the luminal size, neck size, geometry and location of the aneurysm. Endovascular coil occlusion seems to be particularly feasible in small aneurysms. In two recent clinical series, more than 90% of small aneurysms and approximately 80% of large aneurysms could be sufficiently occluded (22, 285). However, the total occlusion rate achieved in giant aneurysms was only 50%. Zubillaga et al. (62) chose 4 mm as the discriminative value for wide versus narrow necks. They achieved a success rate of 85% for narrow-necked aneurysm versus 16% for wide-necked aneurysms. Others have also emphasized the importance of neck-size (108). Debrun et al. (44, 45) emphasized the importance of aneurysm geometry, including shape and dome-to-neck ratio, which should be at least 2 if one is to achieve a successful occlusion. They also suggest that the percentage of complete aneurysm occlusion is related to the density of coil packing.

Giant aneurysms with wide necks remain a major therapeutic challenge. With respect to the currently available data, GDC treatment should be reserved for those individuals who are considered poor candidates for open surgery (82).

The location of the aneurysm may not have any major effect on the achieved occlusion rate. However, vessel tortuosity and difficult anatomic positions may limit access to the aneurysm (23, 44). Configurations unfavorable to successful coiling include locations where multiple branches arise, such as the MCA trifurcation. A branch of a vessel may arise from the neck of the aneurysm, an anatomical

consideration often prevalent in posterior communicating artery (PCoA) aneurysms (44). The three-dimensional configuration of the aneurysm neck may be difficult to angiographically define especially in the anterior communicating artery (ACoA) aneurysms. However, some authors have reported that good and stable occlusion rates can be achieved by coil occlusion in this location as well (35, 181). Coiling more distal aneurysms requires meticulous coiling technique (176).

Posterior circulation aneurysms, especially distal basilar artery aneurysms are the easiest to reach from the endovascular route, thus a high success rate with a low morbidity and mortality in ruptured aneurysms has been reported (60, 89, 157, 217). The feasibility of coil treatment for the posterior circulation aneurysms has been well demonstrated in patients with poor clinical grades (144). The ICA aneurysms located in close proximity to the skull base are also considered to be good candidates for endovascular coil treatment (92, 234).

Thromboembolic complications

In a recent review of 23 studies using GDCs for treatment of intracranial aneurysms, an overall rate of 8.2% of thromboembolic complications was assessed being related to GDC treatment of aneurysms (208). The majority of events occurred intraoperatively. The complications were asymptomatic or transient ischemic attacks (TIAs) in 33% of patients; rest of the patients experienced strokes with a mortality rate of 14%. In the above large clinical series, the reported rate of thromboembolic complications varied between 6.0% and 14.7% (27, 34, 44, 145, 216, 285).

There are several different immediate versus delayed mechanisms that may predispose to thromboembolic events: 1) occlusion and manipulation of the parent vessel cause stasis of distal flow, which leads to intraluminal thrombosis; 2) during embolization of the aneurysmal sac with GDCs, emboli may be sheared off leading to parent artery occlusion; 3) the thrombogenic coil may slip or protrude into the vessel lumen and promote thrombus formation; 4) if the occlusion is incomplete, a new thrombus may form in an aneurysm remnant (208, 209).

For patients with SAH, perioperative heparin administration is recommended. A routine postprocedural use of heparin is not recommended because of the risk of rebleeding (271). However, there are exceptions e.g. the patients with a coil protruding in the parent vessel, with angiographically evident thrombus outside the aneurysm, or with procedure related ischemic symptoms. Those patients may benefit

from heparin administration to be continued for 24 hours postprocedurally. A combination of aspirin and ticlopidine may be used for 4 weeks, to ensure endothelialization of thrombogenic surfaces. The risk of thromboembolic events should be very low after the first 4 weeks (208, 209).

Rupture during treatment of acutely ruptured aneurysms

Aneurysm perforation may occur during catheterization or placement of coils into the aneurysm. Several recent reports highlight this complication (173, 221, 243, 265). Recently ruptured aneurysms carry a higher risk for rupture than unruptured aneurysms (187, 221, 265). Furthermore, a small aneurysm size has been proposed to predispose towards rupture (221, 243), but the likelihood of perforation may be more dependent on the coiling technique used than any factor related to the aneurysm itself (265). The rate of perforations reported in the literature varies between 0.8% and 8.0% (265). In the largest GDC series of 403 patients, the rate of perforations was 2.7%, this being fatal in 6 of the 11 patients who experienced perforation (285). According to a recent review (243) of 13 studies in which the results of 2030 aneurysm treatments were reported, procedure-related rupture of intracranial aneurysms during GDC treatment occurs in 2.5% of cases and is responsible for 1% of treatment-related deaths.

The suggested treatment in the case of aneurysm rupture during coiling is to reverse anticoagulation therapy and rapidly continue GDC coil delivery until complete occlusion is achieved (173, 221, 265, 285). However, the patient may rapidly deteriorate due to the elevation of intracranial pressure. Therefore, neurosurgical assistance should be available for all embolization procedures and emergency craniotomy or ventriculostomy may be indicated after an intraprocedural aneurysm rupture (221, 265).

Remnants of aneurysms after treatment with Guglielmi Detachable Coils

Long-term stability of GDCs is a potential concern. The orifice of the aneurysm may remain open since failure to achieve endothelial proliferation to cover the luminal surface of the thrombus has been found in animal studies (219) and in histological follow-up studies of previously coil treated aneurysms (14). The late occurrence of coil movement and compaction may predispose aneurysm revascularization or growth. Even those aneurysms with initial total occlusion after coil embolization have

shown a rate of 1.8% to 37% of refilling (24, 35, 44, 145, 187, 257). Furthermore, the long-term natural history of the neck remnants remain largely unknown. Completeness of obliteration may spontaneously improve in 8.5% to 46% of coiled aneurysms (24, 44, 98, 187, 257). In two recent follow-up series, however, recanalization of the incompletely occluded aneurysm occurred in 28% to 46% of cases (98, 257). Thus, occlusion of the coiled aneurysms may frequently be unstable.

In their 5-year follow-up study consisting 317 patients, Byrne et al. (24) calculated overall annual rebleeding rates of 0.8% in the first year, 0,6% in the second year, and 2,4% in the third year. No further rebleedings occurred in the 67 patients who were observed beyond 3 years. They did not detect any difference in the stability between the small or large aneurysms. Large and giant aneurysms have found to have a substantially higher risk of rebleeding (4 and 33%, respectively) (167). Raymond et al. (216) observed subsequent rebleeding in 4 of 75 patients after treatment of acutely ruptured aneurysms, 75% of rebleedings occurred in aneurysms that were initially incompletely occluded.

The efficacy of the GDC treatment is an essential issue. Postembolization angiography is usually recommended for all treated patients within a 6-month post treatment period (24, 35, 44, 98, 145, 216, 285). Recommendation for follow-up thereafter varies from a single 1-year angiography (285) to annual angiographies for all coiled aneurysm (216).

5.2.4. Improvement of endovascular techniques

The latest current technological solutions to treat those aneurysms with wide necks and to prevent recanalization include a new generation 3 D coils (32), neck-bridge devices (214), the remodeling technique of balloon assisted GDC placement (6, 156, 166, 180), and a new generation of flexible stents, which allow tight coil packing through the stent and may provide an endoluminal matrix for endothelial growth (148, 177). Embolization of wide-necked aneurysms with new liquid embolic agents combined with protective devices, such as flexible stents or microballoons have proved feasible in experimental settings (185), as well as in clinical studies (170). Endovascular treatment by intra-aneurysmal injection of glue may be preferable to GDC embolization in aneurysms in very distal locations (36).

The further development of GDC coils includes development of the biologically active covered coils (2). In experimental studies, ion implantation and protein coating have been used in order to alter the surface properties (thrombogenicity, endothelial cellular migration, and adhesion) of GDCs (183). Experimental coils coated with new bioabsorbable polymeric materials (184), as well as radioactive platinum coils (32P-coils) (215) may accelerate aneurysm fibrosis and intensify neck neointima formation.

5.3. Combined endovascular and surgical treatment of ruptured aneurysms

Previous incomplete endovascular treatment does not necessarily hinder subsequent successful surgery, provided the coils are compacted in the dome and do not protrude into the neck or into the parent vessel (30, 91, 258). Difficulties are encountered when the aneurysm is either small and incompletely occluded with coils or when the coils protrude into the lumen of the parent vessel (91, 258). Occasionally further treatment is considered necessary even though the coils remain in the basal portion of the aneurysm. In such cases, clip placement over the coil mesh or simple remodeling of the neck of the aneurysm with a clip allowing further treatment by coils may represent a good option for treatment (110).

Sometimes incomplete surgical clipping may be safely accomplished by endovascular treatment with coils (255). Excellent results may be achieved when these two treatment methods are used in a complementary fashion. The endovascular approach is less dependent than surgery on the location of the aneurysm, the clinical state of the patient, and the timing of the intervention (285).

5.4. Clinical trials comparing endovascular and surgical treatment of ruptured aneurysms

The current literature contains no prospective or randomized series comparing endovascular and surgical treatment of ruptured aneurysms. The retrospective outcome studies consisting of consecutive patients of defined time period share the findings that GDC embolization does not seem to be associated with a higher risk of morbidity and mortality than open surgery (128, 153). Richling et al. (220) detected a slight tendency toward better early clinical outcome in a small subgroup of patients with Hunt&Hess Grade III who were treated with GDCs (220). The clinical outcomes

seemed comparable in the studies of Kähärä et al. (128) and Leber et al. (153). However, in all of these studies, the patient populations were imbalanced and the outcome results have been reported in insufficient details.

Struraitis et al. (247) retrospectively investigated the impact of the introduction of the GDC therapeutic option on the overall management outcome of intracranial aneurysms. They could not find any significant impact of integration of the GDCs in the protocol of treatment on clinical outcome, mortality, morbidity, or effectiveness of treatment. Hadjivassiliou et al. (94) compared cognitive outcome as well as structural damage after aneurysmal SAH and treatment with either clips or coils. They suggested that endovascular treatment might cause less MRI detectable structural brain damage than surgery. Furthermore, endovascularly treated patients seemed to have a more favorable cognitive outcome based on comprehensive neuropsychological tests performed one year after treatment.

Several studies focus on specific aspects related to the treatment of patients with SAH. Groden et al. (80) found similar outcomes in 40 poor grade patients (Hunt&Hess IV-V) with anterior circulation aneurysms treated either endovascularly (n=20) or surgically (n=20). Gruber et al. (86) compared patients with acutely ruptured basilar artery apex aneurysms and comparable Hunt&Hess grades of I-III treated either with clipping (n=13) or GDCs (n=11). The patients who underwent GDC embolization had significantly better outcomes and a shorter hospital stay than the surgically treated patients. The two studies investigating the frequency of chronic shunt-dependent hydrocephalus (83) or the frequency of interventions needed for treatment of hydrocephalus (240) could not find any differences between the results of the groups treated either with GDCs or clipping. Similarly no clear association with the frequency of VSP and the modality of treatment chosen could be shown (85).

6. Splanchnic tissue perfusion in critically ill patients

Medical complications after aneurysmal SAH may significantly contribute to the overall mortality rate (101, 135, 136, 149, 244, 293). The most often encountered medical complications include hypertension, sepsis or pneumonia, meningitis, venous thrombosis, pulmonary embolism, anemia, cardiac arrhythmias, gastrointestinal bleeding, inappropriate ADH secretion (SIADH syndrome) and wound infection (101, 135, 244). Extracerebral organ system failures (OSFs) and increased

mortality have been found to be associated with the occurrence of systemic inflammatory response syndrome (SIRS) without infection, which is encountered also in other types of cerebral injury (84, 293). Insufficient splanchnic tissue perfusion has been regarded as one of the possible mechanisms responsible for the SIRS and OSFs (7, 155).

6.1. Assessment of splanchnic tissue perfusion

Many invasive methods have been available to monitor gut perfusion. These include direct doppler investigations, reflectance spectrophotometry, transcutaneous oxygen measurements and measurement of hepatic venous oxygen saturation, lactate concentration and blood flow (201). However, these invasive methods are not used in clinical practice.

Gastric tonometry is a noninvasive method which has been used to assess the adequacy of visceral tissue oxygenation (64). Measurement of intramucosal PCO_2 (PgCO_2) with CO_2gap (gastric-to-arterial CO_2 difference) has been preferred to pHi . PgCO_2 has been proposed to be a more specific index of gut mucosal perfusion than pHi (154).

6.1.1. Gastric tonometry

Gastric tonometry is a relatively noninvasive way to measure the mucosal pHi . The saline tonometric technique for assessing gut luminal PCO_2 was first introduced in 1982 (65). A gastric tonometer is a gas-impermeable sampling tube to which a gas-permeable silicone balloon has been attached distally. After being placed in position, the balloon is filled with saline. Following an equilibration time of at least 10 min, the PCO_2 of the saline becomes equilibrated with the PCO_2 of the gastrointestinal lumen. A sample of saline can then be aspirated and PCO_2 determined with a blood-gas analyzer. Assuming that the bicarbonate (HCO_3^-) concentration in the mucosa and in the arterial blood are equivalent, pHi can be calculated by applying a modified Henderson-Hasselbalch equation: $\text{pHi} = 6.1 + \log (\text{arterial } \text{HCO}_3^- / \alpha \cdot \text{tonometer}$

$PCO_2 \cdot k$), where α represents the solubility of CO_2 in plasma ($\alpha = 0.03$) and k is the time-dependent factor of equilibration (64).

There are several problems associated with pHi measurements. The measurements of PCO_2 from saline samples can introduce errors in pHi values because of the low stability of PCO_2 in saline and the large variations in the quality of the many gas analyzers (222, 249). Due to the equilibration period needed, the data obtained is not real time data and thus rapid changes cannot be promptly detected (155). Recently these methodological drawbacks have been largely eliminated with the development of automated gas tonometry. This technique allows semi-continuous monitoring of gut-to-end-tidal PCO_2 difference ($Pg-etCO_2$) where $PetCO_2$ is used as a non-invasive index of arterial PCO_2 ($PaCO_2$) (37).

6.1.2. Gastric tonometry, clinical experiences

Gastric tonometry has been investigated as a diagnostic tool, as a predictive tool and as a therapeutic index (154). Several studies have shown that low pHi after admission to or during intensive care predicts an increase in morbidity and mortality in critical care patients (93, 200). Therefore, the rationale to diagnose and correct splanchnic tissue hypoperfusion is logical. However, the results of studies using “splanchnic-directed therapy” are controversial. In their prospective randomized series of 260 patients, Gutierrez et al. (93) concluded that therapy guided by pHi measurements improved survival in patients whose pHi on admission to ICU was normal but not in those patients whose pHi on admission was already low. However, Gomersall et al. (76), in their prospective randomized study of 210 patients failed to improve the ICU outcome by treating patients with $pHi < 7.35$ with additional colloids and dobutamine. Equally, Pargger et al. (200) could not improve postoperative outcome in patients after elective repair of infrarenal abdominal aneurysms by treatment to elevate low pHi values. On the other hand, in the study of Barquist et al. (12), trauma patients having persistent low $pHi (< 7.25 \text{ mmHg})$ seemed to benefit from a “splanchnic-directed therapy”. Venkatesh et al. (279) investigated splanchnic ischemia in patients with brain injury, and found evidence that splanchnic ischemia occurs commonly in isolated neurotrauma, with a trend toward development of mucosal ischemia with decreased cerebral perfusion. There is a lack of clinical

studies using CO₂gap determined with saline tonometry or Pg-etCO₂ automated gas tonometry as the therapeutic tool (154).

7. Cerebral vasospasm

The most feared complication of SAH is a form of delayed-onset cerebral arterial narrowing known as VSP (66). Angiographic VSP is detected in 50% to 70% of patients in the first two weeks after SAH (276). In about one-half of cases, angiographic VSP manifests itself by the occurrence of a delayed ischemic neurological deficit, which may resolve or progress to permanent cerebral infarction (171). The development of delayed ischemic deficit (DID) is still considered to be the major cause of morbidity and mortality in the patients who survive long enough to reach the neurosurgical unit. In a recent large multicenter study, DID killed 7% of patients with aneurysmal SAH and left another 7% with severe permanent neurological deficits (135). Despite intensive research in the field of VSP and developments in the therapy, the figures at the present time have not changed to any significant extent (101, 171, 189, 274).

7.1. Etiology and pathophysiology of delayed ischemic deficit

The acute period of VSP is fully developed within 3-5 days after SAH and lasts for 2-3 weeks (277). It is best characterized as prolonged intense vasoconstriction, which leads secondarily to smooth cell damage (68). When the arteries are constricted, endothelial cells lose their flat shape and a major increase in wall thickness occurs in the media (67, 274, 277). The time course for the development of DIDs follows the time course of the development of VSP. According to Weir et al. (276, 277) the most common time for the appearance of delayed ischemic neurological deficits is after day 4 following SAH, and they rarely appear later than day 14 after SAH. There is evidence that parenchymal vessels distal to arteries undergoing angiographic spasm after SAH do not show normal autoregulatory vasodilatation (294).

Blood localized in the subarachnoid space has been considered to be the most important etiological factor in VSP (68, 70, 139). Probably compounds released from the clot interact in some way with the vessel wall. The time course of the spasm could be explained by some spasmogen released from erythrocytes during their

hemolysis in CSF (67). Although VSP probably has a complex and multifactorial pathogenesis, hemoglobin, particularly oxyhemoglobin, seems to be an important cause of VSP. Other substances, which have been considered as possible causes of VSP, include: methemoglobin, bilirubin, eicosanoids, serotonin, epinephrine and neuropeptides (67, 274).

Classically, the clinical symptoms of VSP consist of impairment of consciousness, confusion, disorientation, and worsening neurological deficits such as dysphasia and hemiplegia (277). The clinical diagnosis of VSP is traditionally based on the time of onset of the deficits, the rate of development of the deficits (hours), the nature of the deficits and the exclusion of other factors that may cause gradual deterioration of the patient or focal neurological signs (133). The diagnosis is therefore not always definitive. It is especially difficult to differentiate symptoms of VSP from other causes that worsen the clinical state in patients with impaired consciousness (48, 144).

7.2. Diagnostic methods of investigating vasospasm

Invasive digital subtraction angiography is still the standard method for assessing the degree of arterial narrowing caused by cerebral VSP (70). However, this technique is invasive and carries a risk for complications (31). That has encouraged the search for less invasive methods for evaluating the degree of arterial narrowing. CTA has been found to be highly accurate in detecting either no spasm or severe VSP in proximal arterial location, as compared with DSA (8). A study of 0.5 T MR angiography with 3D-TOF MRA in diagnosing VSP after SAH showed excellent sensitivity for detecting VSP for the ACA (100%), moderate for the MCA (56%) and poor for the ICA (25%) (77). Many studies have demonstrated that after SAH there is a fall in cerebral blood flow to a degree which depends on the severity of VSP (120, 288).

7.2.1. Assessment of regional cerebral blood flow

Regional CBF after SAH depends on dynamic pathophysiological processes and it would ideally be continuously monitored for several days. There is, however, lack of bedside methods allowing continuous monitoring of rCBF readily introducible for clinical use. Indirect bedside estimation of CBF is possible by investigating cerebral

blood flow velocities with transcranial doppler ultrasound (TCD) using simultaneous cerebral perfusion pressure data (1). However, there are no semiquantitative nor truly quantitative methods currently available for investigating rCBF which are suitable for bedside monitoring.

7.2.2. Positron emission tomography

Positron emission tomography (PET) is the gold standard for quantitative evaluation of rCBF. Additionally this method allows quantitative measurement of regional cerebral blood volume (rCVB), regional cerebral oxygen utilization (rCMRO₂) and regional oxygen extraction fraction (rOEF) (206, 294). The PET radiopharmaceuticals for brain imaging that are labeled with positron-emitters have to be first prepared in a cyclotron, which is the major limiting factor preventing their routine clinical use. However, there are several clinical PET-studies evaluating rCBF and brain metabolism in the acute stage of SAH (81, 99, 206, 294).

7.2.3. Radioactive and stable xenon methods

Both the ¹³³Xe injection method (118) and the ¹³³Xe inhalation method (178) have been used in quantitative evaluation of changes in rCBF after SAH as well as in evaluating the correlation of those changes with symptomatic VSP and patient outcomes. The main advantages of the more recently introduced Xenon-Computed Tomography (XeCT) is that it noninvasively provides rapid access to high-resolution, quantitative, local CBF information coupled to CT anatomy. The technology can be incorporated into all existing CT technology at relatively little expense. Since flow measurements based on Xe can be repeated within 20-minute intervals, flow measurements before and after the “therapeutic” manipulation of blood pressure have proven useful for guiding therapy after SAH. The disadvantages are the radiation dose from the CT scanner, the pharmacological effects of xenon gas, and the limitations of the survey (123, 292).

7.2.4. Single photon emission computed tomography

Nuclear imaging of the brain with the SPECT technique uses radionuclides emitting gamma radiation. Brain perfusion imaging requires radiotracers, which efficiently cross the blood-brain barrier so that uptake is proportional to cerebral blood flow (146). SPECT images are generated using gamma cameras that record photons emitted by tracers trapped in the brain. Data collection with a modern multihead gamma camera provides a good spatial resolution and image quality (46, 169). Of the many radiotracers available for imaging CBF with SPECT, *d,l*-hexamethylpropyleneamine oxime (^{99m}Tc -HMPAO) is the most widely used. The more recently introduced technetium-labeled tracer ethyl cysteinate dimer (^{99m}Tc -ECD) is considered to fit CBF more closely than ^{99m}Tc -HMPAO (9).

Brain perfusion SPECT does not routinely allow quantitation of rCBF. Absolute quantification of perfusion by means of single-photon emission tomography (SPET), most often requires arterial sampling, careful modeling and highly accurate instrumentation (169, 270). However, the spectral analysis technique may allow non-invasive absolute quantification of CBF by means of ^{99m}Tc -ECD, which has direct applicability in routine settings (270).

For a number of routine clinical studies, qualitative or semi-quantitative images of brain perfusion are sufficient. Initial visual analysis helps in selecting certain regions of interest (ROIs) for further evaluation of disturbances in rCBF (9, 40, 41, 159, 259). In semi-quantitative analysis of CBF, the counts of tracer uptake in some internal reference point has to be used for comparison to the regional counts of tracer uptake in the desired ROIs. Either cortico-cerebellar ratios or lesion-to-contralateral-normal ratios may be used (40, 41, 146, 159). Although, semiquantitative estimation of rCBF improves the accuracy of SPECT evaluation, the results are commonly reported on the basis of visual interpretation only (207, 211, 232). In clinical use, qualitative SPECT imaging with rCBF markers has provided useful data for detecting VSP (40, 207, 245).

7.2.7. Diffusion and perfusion weighted magnetic resonance imaging

The new MR imaging techniques of perfusion and diffusion imaging are exquisitely sensitive in revealing early infarction in cases of ischemic stroke (79).

Different patterns of flow alterations depending on the time of MR imaging after SAH has been detected using MRI perfusion and diffusion imaging techniques, findings consistent with the known pathophysiology of VSP (79, 231). MR imaging may be an ideal technique for the evaluation of VSP since it can address both the angiographic findings for direct identification of arterial VSP and the functional aspect by measuring the regional CBF and CBV (77).

7.2.8. Transcranial doppler ultrasound

The use of an ultrasonic TCD technique has been proposed for noninvasive evaluation of cerebral VSP (1). Although, TCD velocity changes have been found to be useful in diagnosing and managing elevated cerebral blood flow velocities (CBFV) and ischemic neurological deficit following SAH (273), in many studies the limitations of TCD evaluation alone have been highlighted. Even if the presence of proximal arterial narrowing is correctly identified, TCD does not directly address the more important question of the effects of this VSP on the rCBF in the associated vascular territories (33, 41, 69). Vora et al. (287) found out that for individual patients, only low or very high MCA flow velocities (i.e., <120 or $>$ or $=200$ cm/s) reliably predicted the absence or presence of clinically significant angiographic VSP. Comparison studies of TCD and CBF examination have shown that the most common pathological finding associated with elevated blood flow velocities is hyperemia instead of ischemia (33). By demonstrating a loss of autoregulation, a vascular territory that is acutely ischemic can be identified more reliably. Transient hyperemic response test (THRT) in conjunction with TCD evaluation for examining the autoregulatory reserve has been found to predict the development of DIDs after aneurysm treatment with a high degree of accuracy (147, 213).

7.3. Treatment of cerebral vasospasm

Treatment strategies can be divided into those directed at preventing or reversing arterial narrowing, those directed primarily at preventing or reversing the resulting cerebral ischemia and protecting from infarction (133).

7.3.1. Preventing or reversing arterial narrowing

Early surgery was introduced after it was considered that early clipping of the aneurysm not only prevented rebleeding but also allowed surgical removal of spasmogenic clot from the basal cisterns (250). The concept of intrathecal fibrinolytic treatment after SAH is to promote rapid dissolution of blood clot prior to hemolysis and the release of spasmogenic intermediates. A trend toward less severe VSP and improved outcome with fibrinolytic treatment was seen in two recent prospective, randomized studies (67, 196). A recent review of literature found similar tendency toward decreased occurrence of severe VSP with rt-PA (260).

Initially, the use of calcium channel blockers in the prevention or treatment of secondary ischemia was based on the assumption that these drugs reduce the frequency of VSP by blocking influx of the extracellular calcium needed for contraction of large cerebral arteries. However, subsequent studies have demonstrated that nimodipine does not significantly prevent or reverse large-vessel narrowing after SAH (67). A recent systematic review of all randomized controlled trials on calcium antagonists in patients with SAH showed a significant reduction of secondary ischemia and, thus in the frequency of poor outcome (61). Separate analysis showed that only nimodipine had a positive effect on outcome; nicardipine and AT877 significantly reduced the frequency of VSP. Thus calcium antagonists maybe should be classified as neuroprotective agents. In addition, their use may favor the development of collateral circulation (260).

Recent development in endovascular treatments have enabled the direct dilatation of constricted cerebral arteries by transluminal angioplasty (151, 296). Since angioplasty is not effective in dilating the distal arteries, superselective intra-arterial papaverine administration was proposed as an alternative or conjunctive method of treatment (131). Subsequently the use of intra-arterial papaverine has been discouraged (205), and the studies comparing the effects of transluminal angioplasty with intra-arterial papaverine have found angioplasty to be superior in reversing DID and in improving CBF (58, 69).

7.3.2 Preventing or reversing delayed ischemic deficits and protection from infarction

Induced hypertension combined with volume expansion was found to be effective in reversing ischemic symptoms caused by cerebral VSP already in the 70's (143). The hypertensive component of this therapy was based on the hypothesis that in the presence of impaired autoregulation cerebral blood flow is directly dependent on perfusion pressure (10, 118, 143). The rationale for hypervolemia is based on evidence that SAH results in contraction of the extracellular and vascular spaces (168). Increasing CO with intravascular volume expansion would augment CBF (67). Hemodilution affects blood viscosity and improves the microcirculation rheology (260). Combination therapy of hypervolemia, hemodilution and hypertension is called "triple-H therapy" (197).

Several observational studies have shown triple-H treatment to be effective in preventing or reversing DID (10, 132, 197). However, no conclusive randomized trials have been conducted to demonstrate the efficacy of triple-H treatment (57, 158). High costs and the potentially high rate of severe complications associated with triple-H therapy, including pulmonary edema, myocardial ischemia and cerebral swelling have been emphasized (57, 244). Avoidance of hypovolemia is recommended while triple-H therapy should be given only in case of symptomatic VSP (158).

A synthetic nonhormonal 21-aminosteroid acting against free radical generation and lipid peroxidation might be effective in improving overall outcome in patients following SAH (130). However, the positive effect was seen only in men and it could not be repeated in a parallel study (95).

8. Other complications of subarachnoid hemorrhage

8.1. Hydrocephalus

Acute hydrocephalus is frequently associated with SAH. In the International Cooperative Study on the Timing of Aneurysm Surgery (135), early hydrocephalus was initially noted in 15% of the overall population (3521 patients). During the course of treatment 18% of the patients received ventricular CSF drainage, 8% had lumbar CSF drainage and finally 8% received a permanent shunt device (135).

Correspondingly in the prospective aneurysm study of Säveland et al. (236), 27 of 325 (8%) patients with SAH required shunt placement. In the surgical series of 835 consecutive patients with aneurysmal SAH, Tapaninaho et al. (252) reported a frequency of 35% of early hydrocephalus. Ten percent of patients finally developed a shunt-dependent hydrocephalus. Severe bleeding, into the CSF cisterns or intraventricularly, was the basic prognostic factor in the development of chronic hydrocephalus. Shunt-dependent hydrocephalus had a clear adverse effect on outcome.

8.2. Seizures

There was frequency of 4.5% in the occurrence of seizures during the primary hospital course in the International Cooperative Study on the Timing of Aneurysm Surgery (135). In the series of Hernesniemi et al. (101, 189), epilepsy was seen in approximately 14% of patients with acute aneurysmal SAH treated surgically who were still alive two months following treatment (101). Keränen et al. (137) reported an overall frequency of 14% of late epilepsy in surgically treated patients with supratentorial aneurysms; 2.5% in patients with preoperative Hunt&Hess grade I and 33% in patients with Hunt&Hess grade III-V. Ukkola et al. (266) reported a lower frequency of 8% of secondary epilepsy in their series of 183 consecutive patients operated on for ruptured aneurysms. They noted that the development of secondary epilepsy was associated with MCA aneurysms, temporary clipping during surgery, the wrapping technique used to treat the aneurysm and postoperative angiographic VSP.

AIMS OF THE STUDY

The general aim of the study was to compare the safety, efficacy and outcome of endovascular and surgical therapy in the treatment of acutely ruptured intracranial aneurysms.

The more specific aims were:

1. To compare early safety and efficacy of endovascular and surgical treatment of acutely ruptured intracranial aneurysms. I
2. To determine the differences between endovascular and surgical treatment modalities in long-term clinical, neuropsychological and radiological outcome. II
3. To evaluate splanchnic tissue perfusion by gastric tonometry immediately after endovascular or surgical treatment in order to detect the disturbances and differences in splanchnic tissue perfusion that occur after either treatment. III
4. Single photon emission tomography (SPECT) evaluation of the differences in brain perfusion that occur before and after endovascular or surgical treatment of ruptured intracranial aneurysms. IV

PATIENTS AND METHODS

1. Study design and patient selection

The study design was approved by the Ethical Committee of the Kuopio University and Hospital. During the study period between February 1, 1995 and August 31, 1997, all patients who were admitted to our university hospital because of primary SAH were evaluated as potential candidates for the present prospective randomized study. Since the start of the study until February 1997, the study protocol included a repeated SPECT for the patients. During a period between May 1, 1995 and August 31, 1996 the study protocol also included splanchnic tissue perfusion evaluation by gastric tonometry.

After diagnosis of SAH by CT and obtaining informed consent from the patient or from the patient's closest relative, the first SPECT was scheduled before any treatment for ruptured intracranial aneurysm. The final enrollment into the study was made after the diagnostic angiography. All patients with ruptured intracranial aneurysms considered suitable for both endovascular treatment and surgical clipping were consecutively included provided that none of the following exclusion criteria was fulfilled: 1. Age >75 years; 2. Bleeding >3 days previously; 3. Large hematoma necessitating surgery; 4. Mass effect causing neurological deficit; 5. The ruptured aneurysm had been previously operated on. The aneurysm was not considered as suitable for endovascular treatment and randomization if the diagnostic angiography revealed (a) the neck of the aneurysm to be wider than the fundus, (b) the aneurysm to be fusiform, (c) the neck and its relationship to the parent vessel and adjacent branches to be not distinguishable, or (d) the size of the aneurysm to be < 2 mm (less than the smallest coil available). The patient's suitability for randomization and endovascular treatment was always considered according to the morphology of the aneurysm that had most probably ruptured (aneurysm irregularity, size and findings in computerized tomography (CT)).

Stratified randomization was used to avoid selection bias. Sealed envelopes were allocated for each group of patients according to their pre-treatment clinical grades (Hunt & Hess Grade I-II, Grade III, and Grade IV-V patients). After the procedure, both the endovascular and surgical patients were treated in the ICU and in the neurosurgical ward in a similar manner. Systemic hemodynamics, oxygen

transport and gastric mucosal perfusion, assessed by gastric tonometry, were measured during the first four hours and between 6 and 12 hours after endovascular or surgical treatment.

Symptoms of VSP were recorded on a daily basis. The second SPECT was scheduled 7 days after SAH. Follow-up angiography was scheduled after surgical clipping during the primary hospitalization, and in case of a minor neck-remnant, 12 months after clipping and 3, 12 and 36 months after endovascular treatment. Clinical outcome assessment according to GOS and comprehensive neuropsychological examination were scheduled 3 and 12 months after SAH. MRI of the brain was scheduled 12 months after treatment.

2. Diagnostic angiography and embolization procedure

Diagnostic angiography was performed via the femoral route through a 6 F introducer and using DSA equipment with a 1024 x 1024 matrix (Siemens Polytron, Siemens Medical Engineering Group, Erlangen, Germany). Angiography was usually immediately followed by randomization and, if indicated, endovascular treatment in the same session. In angiography, the site, orientation and morphology of the aneurysm were carefully evaluated and the size of the aneurysm and the width of the neck were measured with a digital caliper using two coins as the reference.

All the embolization procedures were performed under balanced anesthesia or sedative medication by one of two interventional neuroradiologists (TS or RV) or both. A 6 F guiding catheter was advanced to the ICA near the level of the skull base or to the upper cervical portion of the vertebral artery. A Tracker-10 or Tracker-18 microcatheter with 2-tip-markers and a Dasher-14, usually followed by a Dasher-10 guidewire (Target Therapeutics, Fremont, CA) were used for hyperselective catheterization of the aneurysmal sac. The distal end of the microcatheter was shaped with steam to tailor the vascular geometry before catheterization. Using digital road mapping control, care was taken not to touch the aneurysmal wall with the guidewire or catheter. Intra-aneurysmal angiograms were not performed. A continuous pressurized flush of heparinized saline was maintained in both the guiding catheter and the microcatheter.

The sac was then filled with GDC coils (GDC-10, GDC-10 soft or GDC-10 2-Diameter coils, Target Therapeutics, Fremont, CA) (Guglielmi). Complete occlusion

of the aneurysmal sac and neck was always attempted. The largest coil, selected according to the measured aneurysm diameters, was positioned first to form a basketlike frame in the aneurysm. The smaller coils were thereafter sequentially delivered inside the aneurysm, until the lumen was completely occluded and flow inside the aneurysm as well as in the secondary pouch was arrested. In aneurysms with an oblong or irregular shape, filling was started at the ruptured site when this was identifiable, usually in the dome of the aneurysm. If the size of the selected coil proved unsuitable, the GDC system allowed the removal of the coil as well as repositioning of the mesh to an optimal position.

3. Surgery

The surgical operations were performed under balanced anesthesia by a team of 7 neurosurgeons (JH 26 cases, JR 10, ML 9, SS 5, AR 3, MVA 2 and MVI 2 cases) with a collective operative experience of approximately 2000 aneurysm operations. The principal investigator (TK) was not involved in surgery. A pterional, subtemporal, frontal interhemispherical or lateral suboccipital approach was used depending on the location of the aneurysm. A standard microsurgical method was used for clipping the aneurysmal neck with a Sugita or Aesculap clip. If feasible, the aneurysm was opened and/or coagulated. Hyperventilation was used routinely. All patients received corticosteroids and mannitol.

4. Patient care

In all of the Grade IV-V patients and in a majority of the Hunt & Hess Grade III patients, embolization was performed under general anesthesia. In Grade I-II and some Grade III patients, no sedation was applied. During the procedure, systemic heparinization (5000 IU initial bolus for the first 5 patients and 2500 IU for the rest, followed by 1000 IU after an hour and according to the measured activated clotting time thereafter), nimodipine and steroid as well as aspirin (500 mg orally or via a nasogastric tube) were used.

Regardless of the method of securing the ruptured aneurysm, every patient was treated in a similar manner with hypervolemia, prolonged bed rest (10 days as a routine protocol in order to prevent orthostatic hypotension), glucocorticoids and

intravenous nimodipine. In the ICU, hypervolemia was ascertained by Swan Ganz catheter and measurement of the pulmonary artery wedge pressure. Ventricular drainage was performed immediately after embolization, when indicated. Heparinization was not routinely continued in the ICU. Oral aspirin (250 mg daily) was continued for three months after embolization.

5. Treatment of the non-ruptured aneurysms

Twenty-eight (26 %) patients had altogether 43 additional unruptured aneurysms. The additional aneurysms were treated in the same operation, when possible, in the surgical group, and by embolization after the acute phase of SAH in the endovascular treatment group if they were suitable for embolization. So far, 22 additional unruptured aneurysms in 15 patients have been operated on, 2 unruptured aneurysms in two patients have been embolized, 4 patients with 8 additional aneurysms are dead, 3 patients with 3 aneurysms are severely disabled and the remaining 8 aneurysms in 4 patients are under angiographic follow-up.

6. Intensive care unit monitoring and gastric tonometry

A pulmonary artery catheter and gastric tonometer were inserted before or immediately after treatment. Gastric intramucosal pCO₂ was measured by a saline tonometer after 30-90 minutes of equilibration (Tonometrics, Instrumentarium, Helsinki, Finland). The patients received an intravenous infusion of 5% glucose. None of the patients received enteral feeding. The correct position of the tonometer was confirmed by chest x-ray. The time corrected gastric mucosal pCO₂ was obtained by multiplying the measured saline pCO₂ by the correction factors determined by the manufacturer for equilibration times of 30-90 min. The pCO₂ gap was calculated as gastric intramucosal pCO₂ - arterial pCO₂. The pHi was calculated by a modification of the Henderson-Hasselbach equation. Blood gas analyses and pCO₂ values from tonometer were corrected for core temperature and measured by ABL 500 Blood Gas System (Radiometer A/S, Copenhagen, Denmark). Cardiac output was measured by thermodilution in triplicate using 10 ml saline at room

temperature. Plasma lactate concentrations were measured enzymatically (Stat Plus 2300, Yellow Springs Instrument Co., Ohio, USA).

7. Single photon emission tomography

Regional cerebral perfusion was measured both preoperatively and postoperatively with a Siemens MultiSPECT3 gamma camera equipped with fan beam collimators (Siemens Medical Systems Inc., Hoffman Estates, Ill., USA) and using ^{99m}Tc -ethylcysteine-dimer (^{99m}Tc -ECD; Neurolite[®], DuPont Pharma/Durham APS, Kastrup, Denmark) as the blood flow tracer. During the study period, SPECT was available during working days from 8 a.m. to 19 p.m. and on Saturdays from 8 a.m. to 14 p.m., but not on Sundays or national holidays. ^{99m}Tc -ECD was injected into the patient's antecubital vein 30-45 min before the SPECT acquisition was started. A full 360° rotation was obtained (40 views/head, each for 35 s, matrix size 128 x 128) resulting in 6-8 million counts. The imaging resolution was 7 - 8 mm. Transaxial slices (3 mm thick) oriented by the orbito-meatal line were reconstructed using a filtered back projection technique (Butterworth filter: order 6 and cut-off frequency of 0.55 cm^{-1}). Chang's correction method of the tissue attenuation was applied with a uniform attenuation coefficient of 0.12 cm^{-1} . Two consecutive slices were combined to obtain a slice thickness of 6 mm and then saved onto a hard disk for further analysis.

The saved slices were prepared for the analysis of the ROIs by using a semiautomatic brain quantification program from Siemens. First, the slices were rotated and realigned according to orbito-meatal line so that the transaxial (x-direction), sagittal (y-direction) and coronal (z-direction) slices were at 90° angles to each other. Secondly, the ROIs were drawn with a 45 % threshold on the aligned transaxial slices on the right and then mirrored to the left. For temporal ROIs, transaxial slices were reangulated (30°) according to the temporal lobe. To minimize the possible effect of crossed cerebellar diaschisis, all regional counts (per voxel) were normalized to average cerebellar tracer uptake, which was presumed to be least affected by the SAH (159). Normalization was achieved by dividing the average counts of each ROI by the mean cerebellar counts (cortico-cerebellar ratio, CCR).

The following ROIs were determined on each side: frontobasal cortex, frontal cortex, pericallosal area, temporal apex, temporal cortex, parietal cortex and occipital

cortex. The control group had identical ROIs defined, except for the pericallosal area (Figure 1, Study IV). The analyses of the SPECT images included also visual evaluation by two nuclear medicine specialists (EV, JK). The readers were blinded to the mode of treatment and to other imaging findings. The size (no defect / small / medium/ large), severity (no defect / mild to moderate / severe), location (anterior / middle / posterior cerebral artery territory on any combination) and side of possible perfusion defect were recorded. In discrepant cases, a consensus was reached between the readers.

8. Follow-up

Clinical outcome at 3 months after treatment was evaluated by the neurosurgeon primarily responsible for treatment or the principal investigator (TK) of the study who was not involved in the surgery. The twelve-month outcome was evaluated by a single neurosurgeon (TK). The last outcome data obtained by telephone interview was evaluated by a single neurosurgeon (TK) or by a single trained nurse.

Neuropsychological assessment was performed by the same neuropsychologist (Heleena Hurskainen) on three occasions. The short-term assessment 10 days after treatment was limited to a few tests. The comprehensive evaluation 3 and 12 months after treatment included tests of general intelligence, memory and selected language abilities and assessment of attention and flexibility of mental processing. In the tests of learning and memory, parallel sets of tests were used to minimize the retest learning effects, and the order of the sets was randomly alternated.

The follow-up angiography was performed after surgical clipping during the primary hospitalization, and in case of a minor neck-remnant, 12 months after clipping and 3, 12 and 36 months after endovascular treatment. The achieved angiographic occlusion rate of the aneurysms was evaluated by consensus by a neurosurgeon (TK) and an interventional neuroradiologist (RV).

In MRI, T2- and proton density-weighted transaxial slices of the brain were evaluated by a neuroradiologist (RV) and a neurosurgeon (TK) by consensus. The following factors were analyzed: 1.The presence, number and dimensions of ischemic lesions a) in the vascular territory of the parent artery of the ruptured aneurysm and b) in other vascular territories; 2.Traces indicative of mechanical

retraction injury; 3. Lesions caused by hematoma; 4. Lesions already present in the initial CT examination; and 5. Ventricular-to-intracranial width ratio.

9. Patients

9.1. The whole study population (Studies I-II)

During the study period, 321 patients were admitted to the hospital because of primary SAH. Twenty-four patients did not undergo angiography and were treated conservatively because they were in a moribund state. Of the remaining 297 patients, 47 had negative angiograms and 8 had arteriovenous malformations. Of the 242 consecutive patients with angiographically proven aneurysmal SAH, 131 were not randomized (Table 5).

Altogether 111 patients were randomized. Two patients were excluded from the analysis after randomization (one from both treatment groups). In both cases, the decision to randomize the patient had been mistakenly based on the characteristics of an unruptured aneurysm while the ruptured aneurysm, partially or totally thrombosed and misinterpreted in the initial diagnostic angiography, was not suitable for either treatment modalities. The basic characteristics of the 109 patients included in the analyses are shown in Table 6.

9.2. Study III population

During the substudy period between May 1, 1995 and August 31, 1996, 56 patients were randomized for treatment. Twenty-six patients (13 endovascular / 13 surgical) were included into the study (Table 6) and 30 patients (14 endovascular / 16 surgical) were excluded because they did not tolerate the stiff gastric tonometry tube.

9.3. Study IV population

Since February 1, 1995 until February 28 1997 the study protocol included a repeated SPECT for the patients. During the 2-year SPECT-study period, 81 patients were randomly assigned for either treatment. Of these consecutive patients, 35 (17 endovascular and 18 surgical patients) were excluded because the first SPECT study was not available (14 endovascular patients and 17 surgical), the patients died early (1 in both treatment groups), severe post-treatment bleeding (1 endovascular patient) or the patient refused (1 endovascular patient). Altogether 46 patients (22 in the

endovascular and 24 in the surgical treatment group) underwent the first SPECT before any treatment for the ruptured aneurysm as well as the postoperatively scheduled second SPECT approximately one week after treatment and were included in the present study. The basic characteristics of the patients are shown in Table 6. The control group for quantitative SPECT consisted of 10 healthy individuals (2 men and 8 women, mean age 40 years; range 27-55 years).

Table 5. Excluded patients from the consecutive 242 patients with proven aneurysmal SAH.

Reason for exclusion	Number of patients (%)
Large hematoma	35 (26.7)
Aneurysm morphology, not suitable for coiling	33 (25.2)
> 72 h from bleeding	26 (19.9)
Age > 75 years	11 (8.4)
Patient in moribund state	9 (6.9)
Coil therapy not available	6 (4.6)
Previous aneurysmal SAH	3 (2.3)
Aneurysm location, not suitable for ligation	2 (1.5)
Aneurysm causing mass effect	2 (1.5)
Patient refused	2 (1.5)
Patient from abroad	2 (1.5)
Total	131 (100.0)

Locations of the aneurysms in excluded patients	Number of patients (%)
ACA	34 (26.0)
MCA*	59 (45.0)
ICA	27 (20.6)
VBA	11 (8.4)
Total	131 (100.0)

*Note: *significantly more often associated with large hematoma ($p < 0.001$)*

MCA = middle cerebral artery

ACA = anterior cerebral artery, anterior communicating artery, pericallosal artery

*ICA = internal carotid artery, ophthalmic artery, posterior communicating artery,
anterior choroidal artery*

VBA = vertebrobasilar arteries

Table 6. Basic characteristics of the study subjects.

Characteristic	Studies I-II (n = 109)		Study III (n = 26)		Study IV (n = 46)				
	Endovascular group No. of Pts (Total 52)	<i>P</i>	Surgical group No. of Pts (Total 57)	Endovascular group No. of Pts (Total 13)	<i>P</i>	Surgical group No. of Pts (Total 13)	Endovascular group No. of Pts (Total 22)	<i>P</i>	Surgical group No. of Pts (Total 24)
Male / Female	28 / 24	0.758	23 / 34	7 / 6	0.695	6 / 7	12 / 10	0.758	12 / 12
Age (years (mean (range)))	49 (16-73)	0.553	50 (14-75)	52 (36-72)	0.868	53 (14-75)	49 (24-72)	0.553	52 (14-75)
Hunt & Hess grade		0.748			0.121			0.748	
I-II	31		36	3		7	13		16
III	12		14	5		4	7		5
IV-V	9		7	5		2	2		3
Fisher grade		0.191			0.803			0.191	
1-2	20		22	3		4	11		8
3-5	32		35	10		9	11		16
Pre-treatment hydrocephalus		0.142			0.166			0.142	
No	26		36	3		7	9		16
Moderate	23		17	9		5	12		6
Severe	3		4	1		1	1		2
Aneurysm site		0.437			0.138			0.437	
ICA	12		12	1		4	4		6
MCA	7		12	2		3	3		5
ACA	27		28	7		4	12		10
VBA	6		5	3		2	3		3
Aneurysm size		0.358			0.108			0.358	
Small (2-7 mm)	39		41	11		11	18		16
Medium (8-14 mm)	13		15	2		1	4		7
Large (15-24 mm)	0		1	0		1	0		1
Neck size		0.270			0.626			0.270	
Small (<4 mm)	38		46	11		10	16		15
Wide (≥4mm)	14		11	2		3	6		9

Note: *P* = Statistical difference between the treatment groups

MCA = middle cerebral artery, ACA = anterior cerebral artery, anterior communicating artery, pericallosal artery

ICA = internal carotid artery, ophthalmic artery, posterior communicating artery, anterior choroidal artery, VBA = vertebrobasilar arteries

10. Statistics

All analyses were performed with the statistical package SPSS for Win, Versions 6.01–9.01 (SPSS Inc., Chicago, Ill., USA) by the principal investigator of the study (TK) consulting the statistician (PH). The intention-to-treat analysis was used in all comparisons of endovascular and surgical patients. In addition to intention to treat analyses, the statistical analyses were performed leaving out the patients having undergone crossover treatment to verify the statistical significance of the results.

In general, all continuous variables were tested for normal distribution with the Kolmogorov-Smirnov 1-sample test (level of statistical difference at $P < 0.1$). The Mann-Whitney U test for continuous variables with non-normal distribution or ordinal scale variables was used for group comparisons in the case of two independent samples, and the Wilcoxon Signed Ranks Test in the case of two related samples. Chi-square test was used for dichotomized discrete variables and the Student's t-test for continuous variables with normal distribution for group comparisons in case of two independent samples. The paired samples t-test was applied for two related samples. Differences were considered to be statistically significant if the two-tailed p-value was below 0.05.

In Studies I-II and IV, potential predictors that showed statistically significant associations with the clinical outcome (GOS) of the patients in univariate analyses were further included in a stepwise multiple logistic regression analysis. A stepwise model-building procedure was performed for the parameters, using $p < 0.25$ achieved in univariate analysis. In the final multivariate analysis, the statistical level of significance was set at $p < 0.05$. Significance was calculated by the likelihood ratio test. The goodness of fit of the model was estimated with Nagelkerke- R^2 .

In Study II, the subgroups of patients were compared in terms of time to a primary endpoint event, using Kaplan-Meier survival analysis and the Log Rank test.

In Study III each measurement was used two times for two separate comparisons, i.e. endovascular vs. surgical and Hunt&Hess grade I-II vs. grade III-V. Significant effects of time-group interaction were identified by the Independent Samples T-test or the Mann-Whitney U-test after calculating new test-variables representing the differences between the first and second samples, each new test variable being used two times for two separate comparisons as well. In Study IV, each numerical SPECT parameter (cerebro-cerebellar ratios in different ROIs) was

used three times for separate comparisons, i.e. endovascular vs. surgical group and patients vs. controls in the second SPECT, and first SPECT vs. second SPECT within the treatment groups. Each recoded (ipsilateral or contralateral according to the side of the ruptured aneurysm) numerical SPECT parameter was used twice for two separate comparisons, i.e. ipsilateral vs. contralateral sides and the first SPECT vs. second SPECT within the treatment groups. The multiple comparisons were corrected with Bonferroni adjustment (191) and the significant *P* -value in the analyses using the same parameter twice was $0.05 / 2 = 0.025$ and in the analyses using the same parameter three times was $0.05 / 3 = 0.017$.

The sensitivity and the specificity of the visually analyzed second SPECT in corroboration of the clinical diagnosis of VSP or in predicting late ischemic deficits in the MRI were analyzed, as well as the positive (PPV) and the negative (NPV) predictive values, and the overall accuracy of the SPECT 2 (287). Ninety five percent confidence intervals (95% CI) for the accuracy percentages were computed.

RESULTS

1. Comparability of the study groups

The endovascular and surgical treatment groups in none of the Studies I-IV showed any statistically significant differences in their age or gender distribution, or in the Hunt & Hess grades, Fisher grades or frequency of hydrocephalus in pre-treatment CT. Furthermore, there was no significant difference between groups according to the site or size of the ruptured aneurysm (Table 6).

In Study III the patients in poor condition (pre-treatment Hunt&Hess grade III-V) were older than the patients in good condition (pre-treatment Hunt&Hess grade I-II) ($p=0.126$). The patients in poor condition were treated sooner after SAH (26 ± 12 vs. 42 ± 21 hours; $p=0.043$) (Table, Study III).

In Study IV, the time intervals from SAH to treatment and to the first and the second SPECT were comparable (Table 2, Study IV). Individuals in the control group were younger (mean age 40 years; range 27-55 years) than patients in the endovascular (mean age 49 years; range 24-72 years) ($P=0.022$) and surgical group (mean age 52 years; range 14-75 years) ($P=0.017$).

The numbers of patients completing all the neuropsychological tasks, their ages, gender and years of formal education were equal in both treatment groups (Table 7). The proportion of patients undergoing MRI did not significantly differ between the treatment groups in either Study II or Study IV populations (Table 8).

2. Technical complications of endovascular treatment

One incompletely occluded MCA aneurysm rebled on the first day following embolization. The large intracerebral hematoma was immediately evacuated. However, the patient died within two weeks after the hemorrhage (Table 9). Another patient had his MCA aneurysm totally occluded under general anesthesia. The aneurysm seemed to be totally occluded, however, a previously nondiagnosed intracerebral hematoma was detected immediately after the procedure (Table 9). The aneurysm had possibly ruptured before embolization in this already anesthetized patient. Despite immediate surgical evacuation of the hematoma and ligation of the aneurysm, the patient remained severely disabled. After these two cases early in the

study, the heparin bolus was reduced from 5000 IU to 2500 IU. In three cases, the aneurysmal wall was perforated during coil delivery (Table 9). In one patient with an MCA aneurysm, coil delivery was successfully continued, and he made a good recovery. In two unanesthetized patients, perforation was followed by severe

Table 7. Neuropsychological test scores (\pm SD) at 12 months after SAH in patients having good outcome according to the Glasgow Outcome Scale (GOS V).

Test	Embolization (N = 38)	Surgery (N = 37)	P
Verbal IQ§	99.0 \pm 16.5	97.0 \pm 16.7	0.198
Performance IQ§	106.3 \pm 16.6	106.4 \pm 20.2	0.998
Memory (MQ)	112.2 \pm 18.2	110.0 \pm 17.3	0.526
Story recall: immediate	9.3 \pm 3.3	8.6 \pm 3.9	0.429
Story recall: delayed	8.1 \pm 3.2	7.5 \pm 3.8	0.501
Visual reproduction: immediate	10.9 \pm 2.9	10.6 \pm 3.0	0.620
Visual reproduction: delayed	8.3 \pm 4.3	7.0 \pm 4.2	0.178
Rey, reproduction delayed	12.4 \pm 5.4	12.5 \pm 6.8	0.948
Digit Span	12.8 \pm 4.0	12.5 \pm 3.4	0.750
Word fluency	38.3 \pm 16.1	36.1 \pm 12.5	0.510
Boston naming	23.7 \pm 3.8	22.4 \pm 4.4	0.180
Stroop A (s)	31.1 \pm 26.5	27.8 \pm 6.8	0.462
Stroop B (s)	38.3 \pm 26.2	34.8 \pm 10.4	0.449
Stroop C (s)	69.1 \pm 37.0	67.3 \pm 23.4	0.802
Trail making A (s)	46.8 \pm 34.7	45.8 \pm 24.9	0.892
Trail making B (s)	132.6 \pm 83.8	128.5 \pm 73.6	0.824
Tapping dominant hand (/10s)	49.6 \pm 9.8	48.5 \pm 9.1	0.627
Age	46.8 \pm 14.3	49.2 \pm 13.2	0.455
Years of education	9.6 \pm 3.2	9.6 \pm 3.0	0.959
Gender (F / M)	16 / 22	23 / 14	0.107
Days from SAH	438 \pm 107	460 \pm 216	0.576

Note: P- value indicates statistical difference between patients in different treatment groups.

restlessness or convulsions and unconsciousness, prohibiting further delivery of coils. The latter patients were subsequently operated on and recovered uneventfully. Extrusion of coils from the aneurysm neck occurred in three patients (Table 9).

In one patient with an ACoA aneurysm, protruding coils caused a slight

Table 8. Occurrence of clinical symptoms of vasospasm (VSP) and radiological (MRI) outcome of the patients.

Follow-up	Endovascular group (n = 52)	P	Surgical group (n = 57)
Clinical symptoms of VSP (n (%))		0.556	
No symptoms	28 (54)		29 (51)
Gradual deterioration only (possible VSP)	10 (19)		8 (14)
Sudden deterioration and / or focal neurological symptoms (probable VSP)	14 (27)		20 (35)
12-month MRI findings (n (%))			
MRI-study performed (total)	40 (77)		47 (83)
Ventricular/intracranial width ratio	0.24 ± 0.07	0.936	0.24 ± 0.08
Ischemic deficits			
Parental artery territory	8 (20)	0.018	21 (45)
Mean diameter (mm)	43 ± 40	0.624	36 ± 31
Other vascular territory	9 (23)	0.521	8 (17)
Mean diameter (mm)	30 ± 29	0.152	52 ± 30
Mean diameter of all ischemic deficits (mm)	39 ± 36	0.382	41 ± 30
Superficial brain retraction deficits	4 (10)	< 0.001	21 (45)
Deficit caused by preoperative ICH	10 (25)	0.862	11 (23)
Previous lesions			
cortical infarctions	1 (3)	0.460	0 (0)
lacunar infarctions	1 (3)	0.621	3 (6)
atrophy	1 (3)	0.621	3 (6)
chronic white matter lesions	7 (18)	0.843	9 (19)

Note: P-value indicates the statistical difference in results between the treatment groups. Values are numbers of patients (%) unless otherwise indicated.

Table 9. Acute technical complications associated with either surgical or endovascular treatment.

Intended Modality of Treatment	Hunt&Hess Grade	Site	Aneurysm Size mm	Neck mm	Complication	Treatment	Outcome
Embolization	II	MCA	12	3	Coil migration 2cm	ICU	GR
Embolization	II	MCA	7	4	Hematoma (possible perforation)	Surgery	SD
Embolization	IV	MCA	6	3	Rebleeding after failed occlusion	Surgery	Death
Embolization	III	MCA	12	3	Perforation	Coil delivery	GR
Embolization	II	ACom	3	2	Perforation	Surgery	GR
Embolization	II	ACom	5	4	Parent vessel obstruction	Heparin, surgery	GR
Embolization	III	ACom	4	2	Coil protrusion	ICU	VS
Embolization	II	Peric	8	3	TIA	ICU	GR
Embolization	II	Peric	3	2	Perforation	Surgery	GR
Surgery	II	CoP	7	2	Clip kinking after ligation, transient hemiparesis	Re-surgery	MD
Surgery	II	MCA	5	3	Rupture during ligation preceding severe brain oedema	ICU	Death
Surgery	II	MCA	6	2	Rupture during dissection	ICU	GR
Surgery	II	Basil	12	4	Rupture during ligation, main vessel occlusion	ICU	Death

*Note: MCA = middle cerebral artery, ACom = anterior communicating artery, Peric = pericallosal artery
TIA = transient ischemic attack, ICU = observation and monitoring in the intensive care unit
GR = good recovery, MD = moderate recovery, SD = severe disability, VS = vegetative state*

angiographical flow obstruction. Continuing heparin infusion in the ICU, however, resulted in thrombolysis of the aneurysm. The patient made a good recovery after surgical removal of the protruding coils and aneurysm ligation. In another case, coil protrusion from an ACoA aneurysm did not seem to cause any flow obstruction and no treatment was considered necessary. Later on, however, the patient developed severe VSP with no response to aggressive treatment, including balloon angioplasty, and the patient remained in a vegetative state. In a third patient with a medium-sized MCA aneurysm, the proximal end of the first coil moved into an MCA branch, without clinical consequences, and the aneurysm was successfully occluded.

One patient with a left-sided pericallosal aneurysm had a transient paresthesia of the right leg during coil delivery without further clinical consequences (Table 9). No other obvious technique-related thromboembolic complications occurred in the patients.

Four technical complications had no clinical consequences and required no therapy. In five cases which had additional direct surgery, three patients had good recovery, one had a severe disability and one patient died because of early rebleeding from the incompletely occluded aneurysm. Thus, morbidity as well as mortality due to the technique were 1/52 (1.9%).

3. Technical complications of surgical treatment

In two patients, the MCA aneurysm ruptured during an otherwise successful ligation (Table 9). One of these patients, developed severe MCA territory edema and died two days later. The other patient had also ischemic changes in the MCA territory in the postoperative CT, but made a good recovery. One patient with a PCoA aneurysm underwent immediate resurgery because of transient hemiparesis caused by a kinking clip (Table 9). One basilar bifurcation aneurysm ruptured during unsuccessful ligation resulting in early death (Table 9).

One patient developed an abscess in the frontal lobe five months after ligation of an ACoA aneurysm, and surgical evacuation was required. This complication was not, however, directly related to the surgical ligation of the aneurysm since the abscess had developed on the site of external CSF drainage.

The four technical complications did not lead to permanent morbidity in two cases, but in two cases, the death of the patient was related to the technique. The mortality due to the technique was 2/57 (3.5 %).

4. Primary angiographic results of the treatment

The primary angiographic results achieved purely with the intended modality of treatment according to different aneurysm locations are shown in Table 10. The aneurysmal sac was completely obliterated with coils in the first session in 26 (50 %) of the endovascularly treated patients. Subtotal occlusion with a small neck remnant was achieved in an additional 18 cases (35 %) and some filling of the fundus of the aneurysm remained in 3 (6 %) cases. In five patients there was a failure to achieve endovascular treatment resulting in no occlusion of the aneurysm. Of the small aneurysms with a small neck, 61% were totally obliterated in the first session (Table 10).

The surgical results are not directly comparable with the endovascular results since early postoperative angiography was not performed in 7 patients. Fifty surgical patients underwent postoperative control angiography during the first hospitalization, and in 7 cases the occlusion rate was confirmed only on operation or at autopsy. The ruptured aneurysm was considered to be totally ligated in 42 (74%) cases. A small neck remnant was imminent in 9 (16%) aneurysms. In 5 (9%) cases, a significant residual part of the aneurysmal fundus remained open after surgery (Table 10).

In the aneurysms located in the posterior circulation (n=11), the primary angiographic results proved to be significantly better in the endovascular treatment group (p=0.045), whereas in the ACA aneurysms (n=55), the morphologic results were significantly better in the surgical group (p=0.005). In the MCA (n=19) or ICA (n=24) aneurysms, no significant differences in the morphological results were seen between the treatment groups (Table 10).

5. Cross-over between treatment groups during the primary hospitalization

Eight patients (15%) underwent a crossover from endovascular to surgical treatment and one patient underwent a crossover from surgical to endovascular treatment

Table 10. Primary and final angiographic results of early endovascular and surgical treatment of recently ruptured aneurysms according to the site of the aneurysm.

	Endovascular treatment				<i>p</i>	Surgical treatment			
	Total obliteration	Neck remnant	Significant filling of fundus	No occlusion		Total obliteration	Neck remnant	Significant filling of fundus	No occlusion
<i>Primary results†</i>									
All aneurysms	26 (50.0%)	18 (34.6%)	3 (5.8%)	5 (9.6%)	0.015	42 (73.7%)	9 (15.8%)	5 (8.8%)	1 (1.7%)
Anterior circulation									
MCA	4	1	1	1	0.186	10	2	0	0
ACA	13	9	1	4	0.005	23	4	1	0
ICA	6	5	1	0	0.468	8	3	1	0
Posterior circulation	3	3	0	0	0.045	1	0	3	1
<i>Final results§</i>									
All aneurysms	40 (76.9%)	10 (19.2%)	2 (3.9%)	0 (0.0%)	0.413	49 (86.0%)	7 (12.3%)	0 (0.0%)	1 (1.7%)
Anterior circulation									
MCA	5	2	0	0	0.523	11	1	0	0
ACA	23	4	0	0	1.000	24	4	0	0
ICA	7	3	2	0	0.212	10	2	0	0
Posterior circulation	5	1	0	0	0.727	4	0	0	1

Note: p-value indicates statistical significance between treatment groups.

MCA = middle cerebral artery, ACA = anterior cerebral artery, anterior communicating artery, pericallosal artery, ICA = internal carotid artery, ophthalmic artery, posterior communicating artery, anterior choroidal artery

†Primary result is the result achieved with intended modality of treatment during the first hospitalization.

§Final result is the last angiographic result available, including the patients with cross-over treatment and the patients who died.

The results improved significantly in both surgical ($p=0.016$) and endovascular ($p=0.001$) groups

during the primary hospitalization. The patient selection for crossover treatment at different points of time and the outcomes according to the final modality of treatment are presented in Figure 1.

As a result of the technical complications in the endovascular treatment described above, five patients underwent a crossover from endovascular to surgical treatment. One of these five patients died and four made good recoveries (Table 9). In addition, three patients had subsequent open surgery after failed attempts at endovascular treatment, the neck of the aneurysm proving to be too wide to retain the coils. These patients had their aneurysms completely occluded with clipping except for one patient with a wide-necked MCA aneurysm whose aneurysm was left with a neck remnant. All three patients with their wide-necked aneurysms subsequently ligated made good recoveries.

One patient (2%) with an incompletely clipped ACoA aneurysm underwent embolization resulting in total occlusion. This patient required a permanent shunt-device, but initially made a good recovery. However, two months after SAH, the patient died because of a large spontaneous intracerebral hematoma on a location remote from the ruptured aneurysm.

6. Gastric tonometry

In the whole Study III population, the mean pH_i did not change between the first and second measurement periods (7.28 ± 0.12 and 7.29 ± 0.08 , respectively) (Table 2, Study III). Furthermore, the pH_i did not differ either between patients in endovascular and surgical groups or between patients with Hunt&Hess grades I-II and grades III-V (Table 2, Study III). In the whole Study III population the pCO₂ gap also remained stable during the study period, 1.5 ± 1.9 kPa and 1.7 ± 1.2 kPa, respectively. No statistically significant difference was found in pCO₂ gap between the different treatment groups (endovascular 2.2 ± 2.5 kPa vs. 1.9 ± 1.3 kPa, surgical 0.8 ± 0.5 kPa vs. 1.5 ± 1 kPa), and the pre-treatment Hunt&Hess grade groups (Gr I-II 1.2 ± 2.6 kPa vs. 1.8 ± 0.7 kPa, Gr III-V 1.7 ± 1.5 kPa vs. 1.7 ± 1.4 kPa) (Table 2, Study III). Individual changes in the pCO₂ gap are shown in Figures 2 and 3.

	57 patients randomized to surgical treatment				52 patients randomized to endovascular treatment			
	Surgery		Crossover		Coiling		Surgery	
	n (%)	n		n (%)	n (%)	n		n (%)
First hospitalization	57	1	→	1 (1.8)	52	8	→	8 (15.4)
Three month follow-up	56	2	→	3 (5.3)	44	2	→	10 (19.2)
Twelve month follow-up	54	1	→	4 (7.0)	42	2	→	12 (23.1)
Clinical grade of the patient (Hunt & Hess)	Gr I-II 32 Gr III 14 Gr IV 7			Gr I-II 4 Gr III Gr IV	Gr I-II 20 Gr III 12 Gr IV 8			Gr I-II 11 Gr III Gr IV 1
Aneurysm site	ICA 11 MCA 12 ACA 27 VBA 3			ICA 1 MCA ACA 1 VBA 2	ICA 11 MCA 3 ACA 20 VBA 6			ICA 1 MCA 4 ACA 7 VBA
Latest clinical outcome (GOS)	GR 37 (69.8) MD 4 (7.5) SD 3 (5.7) VS 1 (1.9) Dead 8 (15.1)			GR 1 (25.0) MD 1 (25.0) SD 1 (25.0) VS Dead 1 (25.0)	GR 30 (75.0) MD 1 (2.5) SD 2 (5.0) VS 1 (2.5) Dead 6 (15.0)			GR 9 (75.0) MD SD 1 (8.3) VS Dead 2 (16.6)
Total	53 (100)			4 (100)	40 (100)			12 (100)

Note: GOS = Glasgow outcome scale

GR = good recovery, MD = moderate recovery, SD = severe disability and VS = vegetative state

MCA = middle cerebral artery, ACA = anterior cerebral artery, anterior communicating artery, pericallosal artery, ICA = internal carotid artery, ophthalmic artery, posterior communicating artery, anterior choroidal artery, VBA = vertebrobasilar artery

Figure 1. Cumulative chronological flow chart of patient selection for crossover treatment. The preoperative clinical grades, sites of the ruptured aneurysms and last available clinical outcomes are presented according to the final modality of treatment.

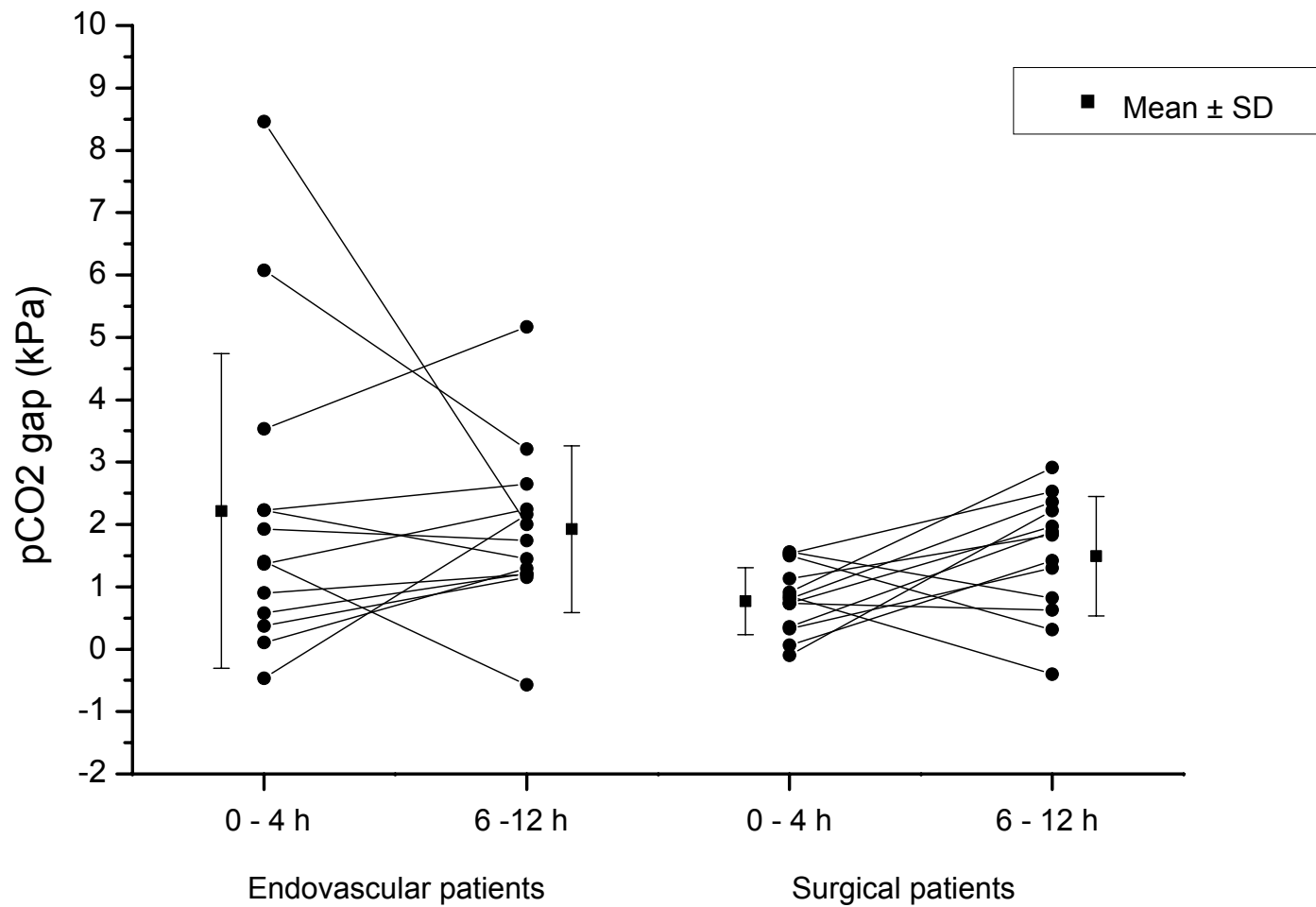


Figure 2. Individual changes in the difference between intramucosal and arterial pCO₂ (pCO₂ gap) within 4 hours and 6-12 hours after aneurysm treatment subdivided according to the treatment groups. The mean values (\pm Standard deviation) of measurements are included.

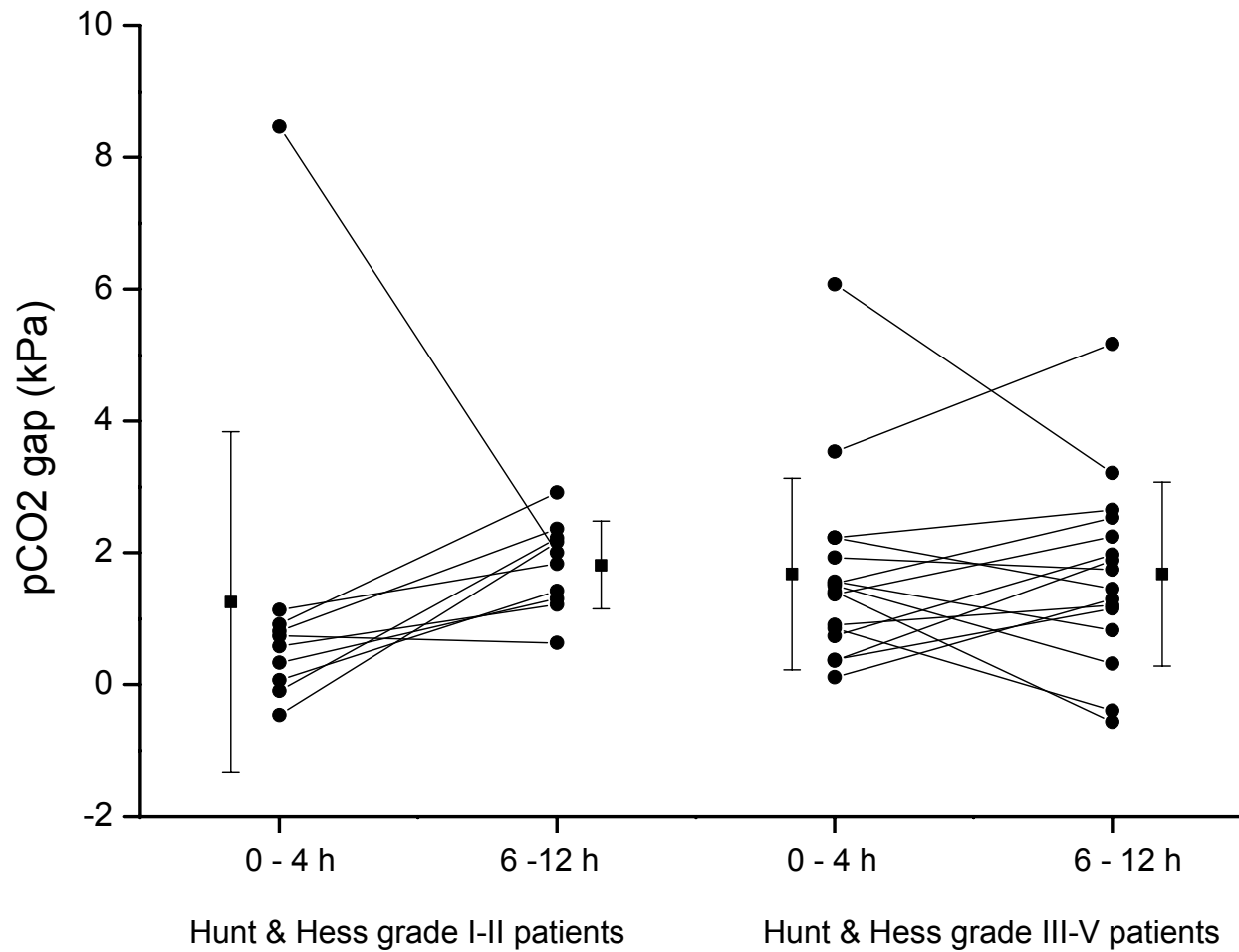


Figure 3. Individual changes in the difference between intramucosal and arterial pCO₂ (pCO₂ gap) within 4 hours and 6-12 hours after aneurysm treatment subdivided according to Hunt&Hess grades. The mean values (± Standard deviation) of measurements are included.

6.1. Hemodynamic and oxygen transport data

In the whole study III population, hemodynamic variables remained stable during the study but the plasma hemoglobin concentration decreased ($p < 0.001$) (Table 3, Study III). Only for lactate was there any statistically significant time and treatment group interaction ($p = 0.012$) as well as a time and Hunt&Hess grade interaction ($p = 0.020$). However, the changes in hemoglobin and lactate concentrations were within the normal range. At the time of the first measurement, the Hunt&Hess grade I-II patients had lower arterial blood pHs (aBpH) than the Hunt&Hess grade III-V patients ($p = 0.013$) (Table 2, Study III). At the time of second measurement, the surgical patients had lower saturated venous oxygen (SvO₂) values than the endovascular patients ($p = 0.017$) (Table 3, Study III).

6.2. Clinical problems associated with subarachnoid hemorrhage

No statistically significant difference between the treatment groups was observed in the number of patients with possible or probable clinical symptoms of VSP either in the whole study population or in the Study IV population (Table 8). Patients with probable VSP had extended fluid therapy and maximized medical therapy (nimodipine infusion) in addition to ward observation or triple-H therapy in the ICU. In the most severe cases angioplasty was applied with or without superselective injection of papaverine. All of the patients with possible VSP routinely underwent hypervolemic fluid therapy in the ward.

In the whole study population, a permanent shunt-device because of hydrocephalus was required more frequently ($p = 0.045$) in the surgical group ($n = 11$; 19%) than in the endovascular treatment group ($n = 3$; 6%).

There was no statistically significant difference in the frequency of extracerebral complications occurring in the course of treatment in ICU between the treatment groups in the Study III population. In the endovascular group, four patients each developed one extracerebral complication: sepsis, multiple organ failure, pneumonia and renal failure. In the surgical group, one patient developed pulmonary edema and one patient suffered from septic urinary infection.

7. Single photon emission computed tomography

7.1. Visual analysis of single photon emission tomography

In the SPECT performed before treatment there were only 8 (36.4%) patients without cerebral perfusion deficits in the endovascular group and 5 (20.8%) patients in the surgical treatment group ($P=0.243$) (Table 4, Study IV). Acute perfusion deficits preceding the treatment were thus common in both treatment groups and there was no significant difference in their size ($P=0.380$), severity ($P=0.094$), anatomical location ($P=0.318$) or lateralization ($P=0.128$).

In the whole study population visual comparison between the SPECT 1 and SPECT 2 revealed that the perfusion deficits had increased in size ($P=0.007$) and become more profound ($P=0.044$) in SPECT 2. When the treatment groups were compared, there were no statistically significant differences in sizes, severity or locations of the perfusion deficits in the SPECT 1 or SPECT 2 (Table 4, Study IV). Within the surgical treatment group, comparison of the findings between the first and the second SPECT revealed that perfusion deficits increased in size ($P=0.006$) and became more often bilateral ($P=0.020$). In the endovascular treatment group, this comparison revealed no significant changes (Table 4, Study IV).

7.2. Semiquantitative regional analysis of single photon emission tomography

Twenty-two patients in the endovascular treatment group and 21 patients in the surgical group had sufficiently high quality of SPECT images to be included in the semiquantitative regional analysis. The comparison between treatment groups revealed no significant differences in CCRs in the SPECT 1 (Table 5, Study IV). In the left temporal apex, patients in both the endovascular ($P=0.004$) and the surgical ($P=0.002$) treatment groups had lower CCRs than the individuals in the control group.

In the SPECT 2, surgical patients had decreased CCRs in the right frontobasal cortex ($P=0.012$) when compared to the CCRs in the endovascular patients. In the comparison between the control group and the treatment group, statistically significant differences in CCRs were detected only in the surgical group: in the left temporal apex ($P=0.010$) and in the right frontobasal cortex ($P=0.014$) (Table 5, Study IV).

In the surgical treatment group, but not in the endovascular group, comparison between the first and second SPECT revealed decreases in CCRs: in the right frontobasal cortex ($P=0.003$), right frontal cortex ($P=0.012$) and right pericallosal area ($p < 0.001$) (Table 5, Study IV) (Figure 4).

7.3. Laterality of the ruptured aneurysm and regional cerebral perfusion

The sides of the ROIs were further recoded as ipsilateral or contralateral according to the sides of the ruptured aneurysms. Twenty patients were included in each treatment group after exclusion of the midline basilar bifurcation aneurysms (Table 6, Study IV). No statistically significant differences were found between the ipsilateral and contralateral CCRs in the first SPECT in either treatment group (Table 6, Study IV).

In the second SPECT in the surgical group, the ipsilateral CCRs were significantly lower in the frontobasal cortex ($P=0.002$), temporal apex ($P=0.002$) and the whole ipsilateral hemisphere ($P=0.007$) when compared with the contralateral CCRs (Table 6, Study IV). In the surgical group, the decrease in the ipsilateral CCRs between the first and second SPECT was statistically significant in the frontobasal cortex ($P=0.000$), frontal cortex ($P=0.011$), pericallosal area ($P=0.002$), and the whole hemisphere ($P=0.003$) (Figure 5). A statistically significant increase in the contralateral CCRs was found in the temporal apex ($P=0.004$) (Table 6, Study IV) in the endovascular treatment group.

7.4. Association between single photon emission tomography and vasospasm

Visually evaluated SPECT 2 scans were used in determining possible agreement between SPECT findings and clinical VSP. The SPECT findings were dichotomized according to size (no lesion or small lesion / intermediate or large lesion), and clinical VSP was dichotomized as no symptoms / possible or probable symptoms. The visually evaluated SPECT proved to have a sensitivity of 96% (95% CI, 88% to 100%), specificity of 55% (95% CI, 34% to 75%), PPV of 70% (95% CI, 54% to 85%),

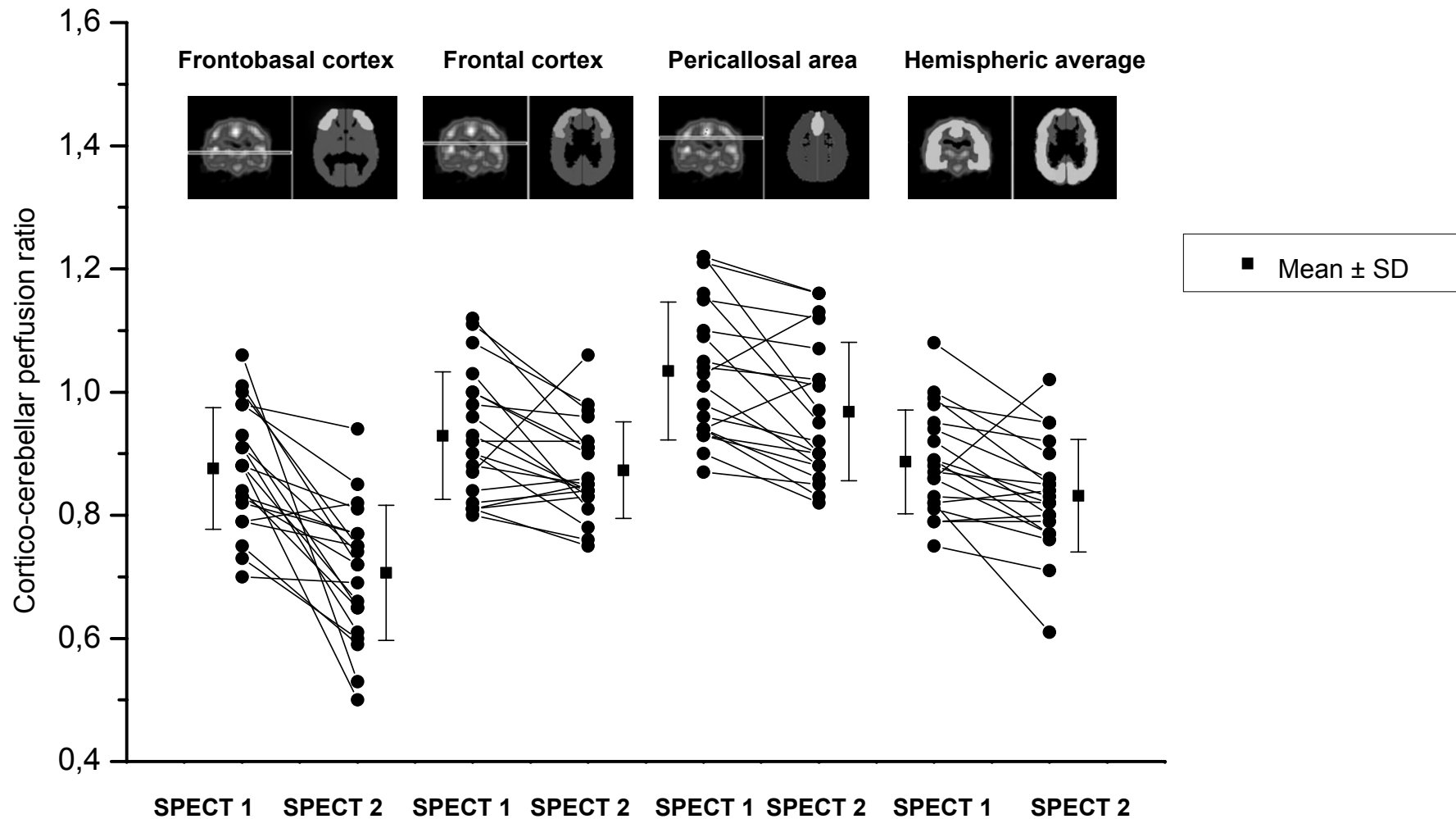


Figure 4. The regions of interest with statistically significant differences in cerebro-cerebellar perfusion rates between the first and the second SPECT study within the surgical treatment group. Individual measurements with mean \pm standard deviation are presented.

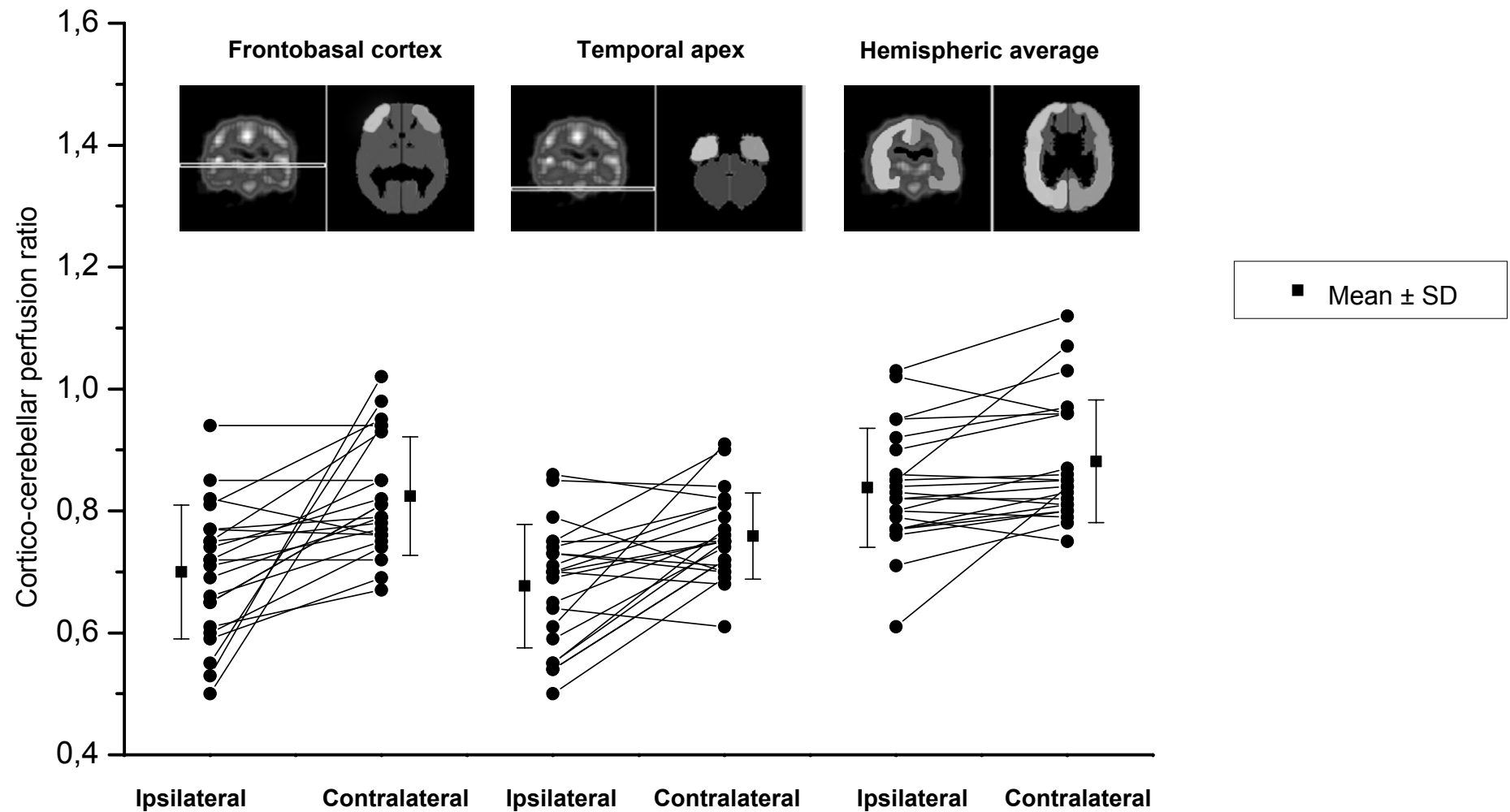


Figure 5. The regions of interest with statistically significant differences in cerebro-cerebellar perfusion rates between the ipsilateral and contralateral sides in relation to the ruptured aneurysm in the second SPECT study within the surgical treatment group. Individual measurements with mean \pm standard deviation are presented.

NPV of 92% (95% CI, 78% to 100%) and overall accuracy of 76% (95% CI, 64% to 88%) for clinical VSP. The 2 x 2 contingency table used to calculate the diagnostic accuracy of SPECT in corroboration of the clinical diagnosis of VSP is shown in Table 7, Study IV.

8. Angiographic follow-up

8.1. Endovascular treatment group

Altogether 39 patients treated exclusively endovascularly out of the 52 patients randomly assigned for endovascular treatment underwent control angiography at three months, and 34 corresponding patients at twelve months. Within the first twelve months six exclusively endovascularly treated patients had died, a total of 10 patients (19%) assigned for endovascular treatment had been operated on and one of them had died as well. Two patients refused to undergo the 12-month control angiography. The 12-month angiographic results of 34 patients treated by only endovascular means, included the assisted successful results of the complementary second embolization performed in 3 patients (twice in one case) and the results in 7 cases with spontaneous thrombosis of the neck remnant. In 26 (76%) cases, the aneurysm was angiographically totally obliterated, and a small neck remnant remained in 7 (21%) aneurysms. In one (3%) aneurysm there was significant filling of the aneurysmal sac.

Refilling of the aneurysm occurred in altogether 12 of 39 (31%) endovascularly treated patients during the first 12 months after the initial embolization. Spontaneous thrombosis of the aneurysm remnant occurred in 7 of 39 cases. In one patient, the aneurysm rest had spontaneously thrombosed in the three-month angiography, but this was found to have recanalized by the 12-month angiography.

8.2. Surgical treatment group

In the surgical treatment group, complete ligation of the aneurysm was ascertained with control angiography during the first hospitalization in 37 patients. These patients had no further angiographic follow-up. In two patients, complete ligation of the aneurysm was ascertained at the three-month angiography, in one patient in autopsy

(after early death), in one patient with magnetic resonance angiography in addition to the perioperative estimation and in one patient with peroperative estimation only.

Incomplete surgical occlusion of the aneurysm was angiographically confirmed in 13 patients during the first hospitalization. One patient had autopsy after early death attributable to a failed ligation of the aneurysm and occlusion of the main vessels. In one patient the aneurysm was perioperatively estimated to be only partially occluded, but in the 12-month angiography the aneurysm proved to be totally occluded. One patient had autopsy after early death attributable to a failed ligation of the aneurysm and occlusion of the main vessels. In one patient the aneurysm was perioperatively estimated to be only partially occluded, but in the 12-month angiography the aneurysm proved to be totally occluded. One patient had resurgery with poor clinical outcome after 3-month angiography. In one patient, the aneurysm had undergone complete spontaneous thrombosis within the first three months. In five patients, a minor neck remnant remained unchanged in the 12-month angiography. One elderly patient refused to undergo the control angiography and one patient with nearly complete occlusion of the aneurysm died before the control angiography and had no autopsy

Altogether four patients in the surgical treatment group had no control angiography. Eleven patients with incompletely clipped aneurysms underwent repeated angiography. One residual aneurysm had spontaneously thrombosed during the first three months. There was one residual of a basilar bifurcation aneurysm that increased in size during the follow-up. The reason why most of the surgical aneurysm remnants were followed-up without intervention was that those remnants were either very small or carried a high risk for either resurgery or endovascular crossover treatment.

9. Delayed cross-over treatment

Four patients underwent a delayed crossover from endovascular to surgical treatment and three patients underwent a delayed crossover from surgical to endovascular treatment. The overall frequency for crossover treatment was significantly higher in the endovascular group (n=12; 23%) than in the surgical group (n=4; 7%) ($P=0.028$) (Figure 1).

In the endovascular treatment group, one MCA aneurysm with an initial total occlusion was found to have recanalized by the three-month angiography. The residual aneurysm was successfully ligated and the patient made a good recovery. One patient had a minor neck remnant of the pericallosal artery aneurysm observed. In the three-month angiography, the aneurysm showed significant filling of the fundus and was successfully ligated. The patient made a good recovery. One ACoA aneurysm remained totally occluded for the first three months, but in the 12-month angiography neck of the aneurysm had been recanalized and the aneurysm was successfully operated on. The patient made a good recovery. An ICA bifurcation aneurysm with a small neck remnant increased in size during the first three months, and was found to be partly recanalized in the 12-month angiography. Attempted open surgical ligation did not succeed because the stiff coil mass hindered the appropriate clip positioning. Soon after operation, the patient developed a massive MCA infarction, which resulted in his demise.

One patient with only a partially ligated basilar bifurcation aneurysm was observed at the beginning. The residual aneurysm remained stable for the first three months but eventually increased in size during the next nine months. Embolization of the residual aneurysm resulted in a total occlusion and the patient made a good recovery. In another patient with a basilar bifurcation aneurysm only partially ligated, the three-month control angiography showed no change in the size of filling portion of the aneurysm. Embolization of the aneurysm remnant was, however, performed with a result of total occlusion. The patient remained severely disabled. The previously described patient who underwent immediate craniotomy because of the clip obstructing the PCoA showed up with a stable neck remnant in the three-month angiography. This neck remnant was embolized resulting in total occlusion. The patient made a good recovery.

10. Final morphological results according to intended modality of treatment

The final morphological results are the last results available verified by angiography or by other means as described earlier. The final morphological occlusion rates include the results of 12 patients with the crossover treatment in the endovascular group and four patients with crossover treatment in the surgical group. The results

include also the results of the three patients with reemboization and the two patients with resurgery (Table 10).

In comparison between the treatment groups, there were no statistically significant differences in either the overall final morphological occlusion rates or in the final morphological occlusion rates according to the sites of the aneurysms (Table 10). The aneurysmal sac was completely obliterated in 40 (77 %) of the endovascularly treated patients. Subtotal occlusion with a small neck remnant was achieved in an additional 10 cases (19 %) and some filling of the fundus of the aneurysm remained in 2 (4 %) cases (Table 10). The ruptured aneurysm was surgically totally occluded in 49 (86%) cases (Table 10). A small neck remnant was detected in 7 (12%) aneurysms. In one (2%) case, the ligation was unsuccessful and the patient died before further attempts at securing the aneurysm (Table 10).

11. Twelve-month clinical outcomes

Neither treatment group significantly improved their clinical outcome between 3 and 12 months after treatment (Table 11). According to the intention to treat, the twelve-month clinical recovery of the patients in the endovascular and the surgical treatment groups was comparable according to the GOS ($p=0.319$) (Table 11). Forty-one (79%) patients initially randomized to the endovascular treatment group and 43 (75 %) patients randomized to the surgical treatment showed good or moderate recovery. Severe disability or vegetative state remained in 4 endovascular (8 %) and 5 surgical (9 %) patients, respectively. Seven patients (13%) died in the endovascular treatment group and 9 (16 %) in the surgical treatment group. There were no statistically significant differences in the outcome when the subgroups of patients with different anatomic aneurysm locations or initial Hunt&Hess or Fisher grades were analyzed separately (Table 11).

In univariate analysis, the intended treatment modality, gender of the patient, crossover treatment and multiplicity of the intracranial aneurysms were not statistically significant determining factors of good recovery (GOS V). Since Hunt&Hess grade ($p<0.001$), postoperative symptomatic VSP ($p<0.001$), need for permanent shunt creation ($P<0.001$), Fisher grade ($p=0.001$), size of the aneurysm ($p=0.003$), age ($p=0.015$), size of the aneurysmal neck ($p=0.024$), and hydrocephalus in the preoperative CT ($p=0.027$) were significantly associated with clinical outcome,

Table 11. Twelve-month clinical outcomes (Glasgow Outcome Scale) of patients with early endovascular vs. surgical treatment (according to the intention to treat) of recently ruptured aneurysms by the initial Hunt & Hess grade, Fisher grade and aneurysm site.

	Endovascular treatment (n = 52)					p	Surgical treatment (n = 57)				
	GR	MD	SD	VS	Death		GR	MD	SD	VS	Death
Total	40	1	3	1	7	0.319	38	5	4	1	9
Hunt&Hess grade											
I – II	28		2		1	0.283	29	3	1		3
III	9	1			2	0.421	8	2	1		3
IV - V	3		1	1	4	0.823	1		2		3
Fisher grade											
0 - 2	18		1		1	0.361	17	2			3
3 - 5	22	1	2	1	6	0.628	21	3	4	1	6
Aneurysm site											
Anterior circulation											
MCA	5		1		1	0.845	7	2	1	1	1
ACA	22	1		1	3	0.698	21	2	2		3
ICA	9		2		1	0.604	8	1			3
Posterior circulation	4				2	0.740	2		1		2

Note: p-value indicates statistical significance between treatment groups.

GR = good recovery, MD = moderate recovery, SD = severe disability and VS = vegetative state

MCA = middle cerebral artery, ACA = anterior cerebral artery, anterior communicating artery, pericallosal artery

ICA = internal carotid artery, ophthalmic artery, posterior communicating artery, anterior choroidal artery

they were further included in a backward stepwise multiple logistic regression analysis as independent variables. Postoperative symptomatic VSP (OR, 2.47; 95% CI, 1.45 to 4.19; $p < 0.001$), poorer Hunt&Hess grade (OR, 2.50; 95% CI, 1.31 to 4.75; $p = 0.005$), need for permanent shunt creation (OR, 8.90; 95% CI, 1.80 to 44.15; $p = 0.008$) and larger size of the ruptured aneurysm (OR, 1.22; 95% CI, 1.02 to 1.45; $p = 0.032$) proved to be independent predictors of poorer clinical outcome. The R^2 for the final model was 0.514.

In univariate analyses among the whole study IV population ($n = 46$) probable VSP ($P = 0.011$), poor preoperative H&H Grade ($P = 0.001$), higher Fisher Grade ($P = 0.013$), larger size of the perfusion deficit in the second SPECT ($P = 0.002$) and more profound perfusion deficit in the second SPECT ($P = 0.031$) were significantly associated with clinical outcome. They were further included in a backward stepwise multiple logistic regression analysis as independent variables. The GOS was dichotomized as good outcome (GOS V) versus worse than good outcome (GOS I-IV). Only poor H&H grade (OR, 7.75; 95% CI, 1.64 to 36.70; $P = 0.001$) proved to be an independent predictor of poor clinical outcome. The R^2 for the final model was 0.564.

12. Neuropsychological outcomes

The number of patients completing all the neuropsychological tests, their ages, gender and years of formal education were equal in both treatment groups. Only patients who completed all of the tasks were included in the analysis. Of these patients, the number of patients with moderate or severe disability (GOS) was small and unequally distributed between the surgical and endovascular groups at both the 3- (7 vs. 3) and 12-month (7 vs. 1) assessments. The number of tasks not performed did not significantly differ between the groups.

Patients with good clinical outcome (GOS) in both treatment groups did not show any significant differences in any of their neuropsychological test scores, and both groups generally improved their performance between the 3- and 12-month assessments (Table 4, Study II).

13. Twelve-month magnetic resonance imaging of the brain

Forty endovascular and 47 surgical patients ($p=0.808$) underwent MRI of the brain 12 months after treatment (Table 8). Claustrophobia prohibited MRI examination in 4 cases, and two patients refused to undergo the procedure. Altogether 16 patients had died before the 12-month MRI study was scheduled.

Superficial brain retraction injury was more commonly ($P<0.001$) seen in surgical patients ($n=21$; 45%) than in endovascular patients ($n=4$; 10%) who had these lesions because of additional surgical treatments. Surgical patients also showed significantly more ($P=0.018$) ischemic lesions in the parent artery territory of the ruptured aneurysm ($n=21$; 45% vs. $n=8$; 20%), but not at remote locations (Table 8). No statistically significant difference was found in the frequency of lesions caused by hematoma, lesions already present in the initial CT examination or in ventricular-to-intracranial width ratios between the treatment groups (Table 8).

In univariate analysis, ischemic lesions in the parent artery territory were associated with clinical symptoms of VSP ($p=0.001$). Ischemic lesions in other locations were associated with clinical symptoms of VSP ($p<0.001$), with higher Fisher grade ($p=0.001$) and with ischemic lesions in the parent artery territory ($p=0.001$).

In univariate analysis, the following MRI variables revealed a significant association with poorer clinical outcome: size of the ischemic lesion in the parent artery territory ($p<0.001$) or in another location ($p=0.001$); presence of an ischemic lesion in the parent artery territory ($p=0.003$) or in another location ($p=0.005$); deficit due to preoperative intracerebral hematoma ($p=0.035$) and higher ventricular-intracranial width ratio ($p=0.040$). These were included in a backward stepwise multiple logistic regression analysis as independent variables. In the final model, the presence of an ischemic lesion in the parent artery territory (OR, 6.20; 95% CI, 1.67 to 23.05; $p=0.006$) and a deficit due to preoperative intracerebral hematoma (OR, 4.23; 95% CI, 1.16 to 15.39; $p=0.029$) proved to be independent predictors of poorer clinical outcome. The R^2 of the final model was 0.249.

In contrast to the MRI findings in the whole study population, the 12-month MRI in the study IV population ($n=40$) revealed no significant difference in the number of ischemic deficits between the endovascular ($n = 6 / 19$) and surgical ($n = 7 / 21$)

groups but the mean size of the deficits was larger in the surgical group ($P=0.018$) (Table 3, Study IV).

In the whole study IV population, dichotomized visual SPECT 2 findings (no deficit / visually detectable deficit) and MRI findings (no ischemic deficit / ischemic deficit) were used in the analysis of diagnostic accuracy of SPECT 2 in predicting late ischemic deficits. A visually detectable lesion in the second SPECT proved to have a sensitivity of 92% (95% CI, 78% to 100%), specificity of 26% (95% CI, 9% to 43%), PPV of 38% (95% CI, 21% to 54%), NPV of 86% (95% CI, 65% to 100%) and overall accuracy of 48% (95% CI, 32% to 63%) for a corresponding late ischemic deficit in MRI. The 2 x 2 contingency table used to calculate the diagnostic accuracy of SPECT in predicting late ischemic deficits is shown in Table 8, Study IV.

14. Survival analysis

Survival analysis is based on the data obtained by telephone interview in April 2000. All patients were included in the follow-up. There were no late rebleedings during the follow-up. There was no significant difference in cumulative survival times between the endovascular (mean survival time 1575 days, 95% CI, 1403 to 1746 days) and surgical (1572 days, 95% CI, 1400 to 1745 days) treatment groups ($p=0.882$). The patients with a preoperative Hunt&Hess grade I-II (1716 days, 95% CI, 1600 to 1832 days) had a significantly lower risk of cumulative mortality ($p=0.013$) than the patients with grade III-V (1344 days, 95% CI, 1104 to 1583 days) (Figure 6).

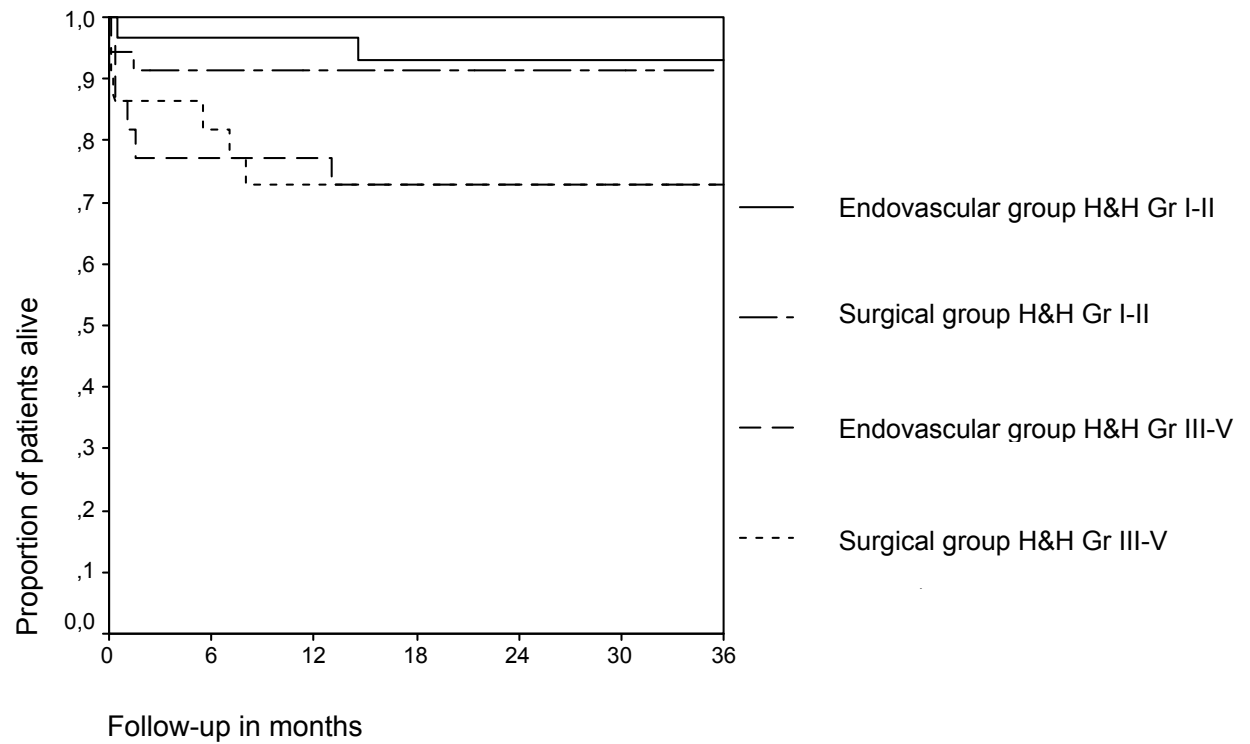


Figure 6. Kaplan-Meier survival analysis according to intended modality of treatment adjusted with the preoperative clinical Hunt & Hess grades of the patients.

DISCUSSION

This is the first prospective randomized study to compare the outcomes of treatment of acutely ruptured intracranial aneurysms with either endovascular GDC occlusion or conventional open surgical neck clipping. The direct comparison between the previous observational studies of endovascular treatment (24, 27, 34, 145, 216, 285) and surgical clipping (96, 101, 135, 136, 198, 236, 238) of ruptured intracranial aneurysms is difficult because of the heterogeneity of the aneurysm and patient populations. The present study population in both treatment groups (Table 6) compares well with the populations of patients and aneurysms in previous large surgical and management outcome studies (101, 135, 136, 236, 238).

1. Safety of the treatment

There were more technical problems (17%) related to primary endovascular therapy than to surgical treatment (7%), and failure in attempting coiling was more common than failure in clipping. However, technique related morbidity (1.9% vs. 0.0%) and mortality (1.9% vs. 3.5%) were comparable in the endovascular and surgical groups. The procedure related morbidity and mortality figures in the present series are comparable with the figures reported in literature. In the previous endovascular series of patients with ruptured intracranial aneurysms, rates of 3.6% to 8.9% for morbidity and 1.7% to 6.4% for mortality have been reported (27, 34, 44, 145, 216, 285). However, direct comparison with the previous endovascular series is difficult because in those series patients with posterior circulation aneurysms were over-represented, as were aneurysms that were considered to be inoperable, some of those giant aneurysms. Furthermore, all aneurysms in the present study were treated within 3 days following SAH unlike most aneurysms in the earlier endovascular series.

In the surgical series with comparable patients populations, reported rates of technique related morbidity varied from 2.6% to 6.9% (101, 238) and mortality from 2.6% to 3.9% (101, 198, 238). Some reports contain only combined figures of morbidity and mortality varying from 3.5% to 10 % (136, 236). The results in the present series compare favorable with the results in a recent prospective series where intraoperative complications in aneurysm surgery occurred in 30% of patients. Intraoperative aneurysm rupture accounted for 60% and inadvertent ligation of main

vessel 12% of all technical problems. Complications related to surgery accounted for 27% of all morbidity and 8% of all deaths resulting in poor outcome in 7.9% of all patients (74).

2. Feasibility of the selected treatment in the acute stage of subarachnoid hemorrhage

The morphological criteria for inclusion to the study were liberal because we did not exclude the aneurysms with wide necks unless the dome-to-neck ratio was less than one. Others have recognized that in aneurysms with necks wider than 4 mm (62) or with dome-to-neck ratio less than two (44), complete occlusion is unlikely to be achieved. Even with our liberal inclusion criteria, it is apparent that with the current limitations of GDC treatment a ruptured aneurysm is more often suitable for surgical treatment than for coiling. The reason for excluding from randomization was large hematoma necessitating immediate evacuation in 35 of 242 patients with aneurysmal SAH (14%), aneurysm morphology not suitable for coiling in 33 patients (14 %), coil therapy not available in 6 patients (2%) and aneurysm causing a mass effect in 2 patients (1%), whereas only 2 patients (1%) were excluded because the aneurysm was not considered feasible for clipping. Since only one exclusion criteria has been selected for each individual patient, there may be some overlap in the exclusion criteria applicable for individual patient. Thus, it is not possible to directly derive conclusions on how many of the excluded patients would have primarily been suitable for either treatment

As a result of technical complications in the endovascular group, five patients (9.6%) underwent a crossover from the endovascular to the surgical group. Additionally in three cases (5.8%) coiling resulted in failure because the necks of the aneurysms proved to be too wide to retain the coils and the patients underwent subsequent surgical treatment. Only one patient (1.8%) with incompletely clipped aneurysm underwent crossover to endovascular group during the first hospitalization.

Raftopoulos et al. (210) conducted a prospective analysis of the treatment options of 103 consecutive patients with 127 intracranial aneurysms; of those 59 were ruptured. They considered endovascular treatment as a first option for all aneurysms. Predefined reasons for selecting surgical treatment were compressive hematoma necessitating surgical evacuation or unlikelihood to achieve a complete

coil occlusion (i.e. neck/sack ratio > 1:3). Only 64 (50%) of the aneurysms could be included to the endovascular group, the most frequent reasons for exclusion being wide neck in 27 aneurysms (21%), atheromatosis in 16 aneurysms (13%) and vessel leaving from the neck of the aneurysm in six aneurysms (5%). Finally the endovascular group contained more VBA aneurysms (14 versus 1), more ICA aneurysms (19 versus 12), less MCA aneurysms (19 versus 28) and fewer ACA aneurysms (12 versus 22) than the surgical group.

The crossover rates in the study of Raftopoulos et al. (210) were approximately the same than in the present study with respect to both endovascular (16% versus 15%) and surgical (2% versus 2%) groups respectively. Consistently with these results, in the series of Debrun et al. (44), coil therapy in 49 ruptured aneurysms initially selected for treatment on the basis of morphological criteria (dome-to-neck ratio at least 2 or absolute neck diameter less than 5 mm) was found to be unsuitable in 7 aneurysms (14%) and technical failure occurred in 3 aneurysms (6%) (44). Our finding that MCA aneurysms were seldom suitable for coiling (successful in only 3 of 7) is consistent with the observation that configurations unfavorable to successful coiling include those locations where multiple branches arise, such as the MCA trifurcation. Giving the above figures, and assuming that in the present study the failure rate would have been equal if the patients randomized to the surgical group had instead been assigned for coil treatment and vice versa, it can be estimated that approximately half of the ruptured intracranial aneurysms seem to be suitable for coiling.

In the series of Cognard et al. (34) of a total of 150 ruptured intracranial aneurysms smaller than 15 mm in diameter, 132 (88%) were successfully treated with GDCs. Lot et al. (165) reported a series of 395 consecutive cases of intracranial aneurysms (287 of those ruptured) managed either with GDCs, surgical clipping or both. Two hundred and ninety three (74%) of all aneurysms underwent coil treatment with 25 (9%) unsatisfactory occlusions. MCA was the only location for which more cases were treated by surgery than by coils. Only 2 aneurysms (1%) underwent crossover treatment to surgical clipping, whereas 21 unsatisfactory cases could be successfully treated with either re-embolization (n=19) or endovascular parent vessel occlusion (n=2). Furthermore, four of the seven failed surgical cases were successfully treated with coils. The differences detected in the feasibility of coil treatment between the French series (34, 165) and the present series as well as the

Raftopoulos series (210) may at least partly be explained by more active use of the “remodeling technique” (6, 166, 180) in treating the aneurysms with unfavorable geometry.

3. Efficacy of the treatment

3.1. Morphological results

The overall initial aneurysm occlusion rates were significantly better in the surgical group than in the endovascular group. Only 50% of the endovascular patients had their aneurysms completely occluded, whereas 74% of the surgically clipped aneurysms were considered to be perfectly ligated. The rate of primary endovascular occlusion achieved is in accordance with the results from other endovascular series of ruptured intracranial aneurysms (20, 145, 187, 216). It is well known that the size and geometry of the aneurysm strongly affects the morphological result achieved by GDC treatment (44, 62, 108). In the present series of small aneurysms with a small neck, 61% were totally obliterated in the first session. Correspondingly, the initial total occlusion rate achieved in the small aneurysms (<10 mm) was 71% in the largest to date series of Vinuela et al (285). and 66% in the series of Byrne et al. (24). On the other hand, surgical occlusion rates in the present series were clearly worse than those reported by others. There were only 5% of incompletely clipped intracranial aneurysms in a recent systematic review of the surgical series (256). The difference may partly be explained by our strict policy in determining the morphological results of treatment. Even the slightest 1 to 2 mm “dog ear” was considered as a neck remnant. Such neck remnants may not be recognized on routine control angiograms (53, 55). Furthermore, postoperative control angiography is not routinely performed in many institutions. The few institutions having presented their excellent postoperative morphological results may not represent the average results achieved by surgery (39, 63, 160, 242).

In the aneurysms located in the posterior circulation, the primary angiographic results were significantly better in the endovascular treatment group, whereas in the ACA aneurysms, the morphological results were significantly better in the surgical group. Posterior circulation aneurysms, especially distal basilar artery aneurysms are the easiest to reach from the endovascular route, thus a high success rate by

endovascular treatment in these aneurysms has been reported (60, 89, 157, 217). Aneurysms in posterior circulation represent less than 10% of an average aneurysm population (135, 236, 238), thus surgical experience in these cases is difficult to achieve. The best surgical results of VBA aneurysms in the literature, however, are superior to those achieved by GDC treatment (55). Configuration of the ACoA aneurysm may be angiographically difficult to define, although good and stable occlusion rates have also been achieved by coil occlusion in this location (35, 181). Pericallosal artery aneurysms have only anecdotally been described as being suitable for coiling (176). In the present series, the ACoA aneurysms and the pericallosal aneurysms were combined and analyzed as ACA aneurysms, which may influence the interpretation of the results.

According to the intention to treat analysis, the final occlusion grades of the aneurysms after additional endovascular or surgical treatments were satisfactory in both treatment groups. In the surgical treatment group, 86% of the aneurysms were completely obliterated and 12 % were left with a small neck remnant, while in the endovascular group 77% of the aneurysms were completely occluded, 19% were left with a minor residual and in one aneurysm there were some residual filling of the fundus.

3.2. Risk of rebleeding

One early rebleeding occurred in an incompletely coil-occluded MCA aneurysm, and one intracerebral bleeding occurred in an anesthized patient, probably before the successful coiling of a MCA aneurysm. The latter event might have happened in a patient under general anesthesia before craniotomy as well. However, in that case it would have been possible to evacuate the hematoma without delay. In the patient in question, a hematoma was suspected because he woke up slowly and was found to be hemiparetic. Thus, there was an inevitable delay in the diagnosis of this hematoma, which perhaps had some influence on the poor outcome of the patient.

An early rebleeding of a coiled ruptured aneurysm is rarely described in the endovascular literature. Byrne et al. (22) described one fatal rebleeding of incompletely occluded ICA bifurcation aneurysm 24 h after embolization. They have since then avoided staged procedures. In their report of the early treatment of patients in very poor condition after aneurysmal SAH, van Loom et al. (271) had 2

rebleedings (18%) in 11 coiled aneurysms. One rebleeding occurred at 5 days after an apparently complete occlusion of a large ICA aneurysm and the other event at 2 months after SAH. They suggested that the earlier rebleeding was related to their prolonged postembolization heparinization (24h), which is at the present time rarely used. Although no rebleedings were detected among surgical patients with incomplete clipping, such events are occasionally seen after improper clip placement during the very first days after treatment. The frequency of that kind of event in general surgical population is unknown. Since control angiograms immediately or early after surgical clipping of the aneurysm are routinely performed only in a few institutions (256), it might be assumed that in endovascular patients with known occlusion rates after embolization, the risk of rebleeding would be easier to identify. However, the earlier described rebleeding 5 days after treatment (271) occurred in a supposedly totally occluded aneurysm, which makes the interpretation more difficult.

No late rebleedings occurred in the present series during the follow-up. In their 5-year follow-up study of ruptured intracranial aneurysms treated with GDCs, Byrne et al. (24) reported a rate of 7.9% of rebleeding in aneurysms with an unstable occlusion within a median of 22.3 months follow-up. The overall annual rebleeding rates were 0.8% in the first year, 0,6% in the second year, and 2,4% in the third year. Malish et al. (167) found a low risk of recurrent hemorrhage after successful coiling, whereas the risks for large and giant aneurysms were as high as 4 and 33%, respectively. Raymond et al. (216) observed subsequent rebleeding in 4 of 75 patients after treatment of acutely ruptured intracranial aneurysms, 75% of rebleedings occurred in aneurysms that were initially incompletely occluded. In surgically treated intracranial aneurysms, the risk of hemorrhage of an aneurysm remnant is estimated to be 0.4% to 1.9% / year (39, 63). Tsutsumi et al. (263) calculated a 9.0% cumulative recurrence rate at 20 years after SAH. In their series, 2 out of 6 rebleedings were from de novo aneurysms, which had not been visible in the original angiography.

3.3. Refilling of the aneurysms and angiographic follow-up

In the present series 1 of the 11 (9%) surgical neck remnants that were angiographically followed-up increased in size and 1 (9%) spontaneously thrombosed. Even the completely clipped aneurysms have been reported to regrow

in 1.5% to 2.4% of cases (39, 262). Others have reported regrowth from a surgical aneurysm rest in 5% to 25% of cases (39, 63, 262). However, the time interval from treatment to refilling has been suggested to be several years (39, 53, 55, 75, 262). Therefore, one-year control angiography was not scheduled for the patients with completely clipped aneurysms.

The long-term stability of GDC occlusion is of some concern. In the present series refilling of the aneurysm occurred in 12 of 39 (31%) endovascularly treated patients during the first 12 months after initial embolization. Spontaneous thrombosis of the aneurysm remnant occurred in 7 of 39 (18%) cases. In one patient, the aneurysm remnant had spontaneously thrombosed in the three-month angiography, but was found to have recanalized in the 12-month angiography. Others have reported intracranial aneurysms with initial total occlusion after coil embolization to show a rate of 1.8% to 37% of refilling (24, 35, 44, 145, 187, 257). Recanalization of the incompletely occluded aneurysms has been reported to occur in 28% to 46% of cases (98, 257). Thus, results reported in literature are in accordance with the results achieved in the present series.

Long-term angiographic follow-up (> 5 years after initial treatment) has been previously suggested for the patients with incompletely clipped aneurysms (53, 63, 75, 160). Given the annual risk of 0.9% to 1.8% of de novo aneurysm formation (39, 262), and the possibility of aneurysm regrowth after apparently complete clipping, late angiographic follow-up might be recommendable for young patients, even with complete clipping of the aneurysm. In the institution of Cognard et al. (36), the patients with total endovascular occlusion at second follow-up angiography (at least 15 months after the procedure) are scheduled for final follow-up angiography 3 years thereafter. On the other hand, in patients with incomplete occlusion the angiography is repeated after 1 or 2 years depending on the morphology of the aneurysm rest. They consider it too premature to estimate when repeat angiography is no longer needed. Thornton et al. (257) recommend follow-up angiography at 6 months, 1 year, 2 years, 4 or 5 years, and thereafter at different times when indicated. Ng et al. (187) were able to demonstrate a reduction from the overall recanalization rate of 27% during the first year to 20% over the second year to 14% over the third year. However, they suggested at least a 3-year angiographic follow-up for all coiled aneurysms. It is apparent that no consensus of the frequency of the angiographical follow-up needed can be obtained before there is more data available of the natural

history of the coiled aneurysms. A frequent angiographic follow-up inevitably causes high stress for the patient. The newly developed 3D-TOF MRA with postprocessing using targeted MIP reconstructions is promising noninvasive method for long-term monitoring of the stability of occluded aneurysms (19, 129).

4. Aneurysm retreatment after embolization or surgical ligation

Development of endovascular techniques and the current protocol of routine postoperative control angiography in surgically treated patients have lead to the frequent need for consideration of retreatment of partially occluded aneurysms. In the literature, the technical aspects of retreatment of surgically ligated aneurysms are well defined. Reoperations may be technically demanding at the acute stage of SAH because the brain is still tight and swollen and the acutely ruptured aneurysm still nonsecured due to improper previous clip placement. Increasing technical difficulties are encountered as the time interval from the initial operation to the reoperation increases because of scar formation. The complex anatomy and previously placed clips or material used in “wrapping” the aneurysms are factors that need to be considered in the planning of the reoperation (53, 75). In the present series, one patient had clip replacement during the primary hospitalization with a good outcome. However, in a second patient, resurgery 3 months after initial treatment resulted in a poor outcome, ultimately in death.

Surgical ligation of the previously embolized aneurysms is often difficult with a risk of parent artery damage or occlusion. The coils may be incorporated into the vessel or aneurysm wall as soon as 2 week after coiling (110). Many authors suggest that there should be attempts to treat subtotally occluded or recanalized aneurysms initially treated with embolization with the same method before considering surgical treatment (91, 110, 165). However, this is not always possible because the geometry of the residual aneurysm cannot feasibly retain the coils. In the present series only three patients (6%) underwent reembolization. Surgical clipping of previously coiled aneurysm is technically difficult if the coils protrude to the neck of the aneurysm, hindering the proper clip placement over the neck. In such cases, some authors consider coil extraction as being necessary to enable the proper clip placement, thus favoring an early operation after the initial embolization (91, 110). Others suggest

delaying the operation beyond three weeks after embolization and clip placement over the coils in the aneurysm neck (30).

In the present series 8 patients had early surgical treatment after incomplete or failed endovascular treatment without any major technical difficulties. Four patients underwent a delayed crossover from endovascular to surgical treatment. Additional surgical treatment was successful in three patients. However, in one patient, surgery one year after initial embolization resulted in fatal complications. Thus, surgical treatment of both previously clipped and embolized aneurysms in the present series was found to be risky. On the other hand, embolization of the residuals of incompletely clipped aneurysms was successful with no morbidity or mortality. These figures suggest that combined endovascular and surgical treatment may provide good anatomical results, however, with an increased risk of morbidity and mortality related to the delayed surgery.

5. Clinical outcomes

Although there was a trend towards better clinical outcomes in the endovascular group, the difference was not significant. The outcomes in both treatment groups are well comparable with the outcomes achieved in recent surgical series with comparable patient and aneurysm populations (101, 135, 236, 238). The comparison with the present series and the previous endovascular series is not straightforward because of the differences in timing of the treatment as well as in the aneurysm and patient populations (20, 34, 44, 145, 217, 285). Our main findings that the severity of the bleeding and the pre-treatment clinical condition of the patient are the major determinants for outcome are in accordance with the previous studies (136, 189). Although an individual not involved in the surgery or endovascular treatment (TK) performed the twelve-month clinical outcome evaluation, the clinical evaluation of outcome was complemented by subsequent neuropsychological evaluations and by late MRI study of the brain.

5.1. Hydrocephalus

Unexpectedly the endovascularly treated patients developed a chronic hydrocephalus significantly less frequently than the surgically treated patients. Three

patients (6%) in the endovascular treatment group and 11 patients (19%) in the surgical group developed a shunt-dependent hydrocephalus. The incidence of chronic hydrocephalus in the surgical group is clearly higher than the rate of 8% to 10% reported in previous surgical series (135, 236, 252). Such a difference between the figures in the surgical and endovascular treatment groups in the present study might suggest that surgery itself somehow disturbs the normal cerebrospinal fluid flow. However, the previous retrospective studies comparing surgical and endovascular treatment of ruptured intracranial aneurysms have not detected differences in the frequency of chronic shunt-dependent hydrocephalus (83) or the frequency of interventions needed for treatment of hydrocephalus (240) between the treatment groups. In accordance with our results, Gruber et al. (83) found the frequency of chronic shunt-dependent hydrocephalus of 23% in their surgical treatment group. On the other hand the incidence of chronic hydrocephalus was 18% in the endovascular treatment group. These discrepant results may be explained by the relatively small number of patients examined in the present study.

6. Twelve-month magnetic resonance imaging of the brain

MRI is a sensitive method for detecting and characterizing permanent deficits in brain tissue as a consequence of SAH or treatment. A recent study showed that an unexpectedly large number of late MRI detectable lesions is found several years after treatment, especially in the frontal lobes among patients who undergo early surgery for aneurysmal SAH. All of these lesions cannot be revealed by CT (140). However, MRI findings do not necessarily correlate with the findings in neuropsychological tests (94, 226), although correlation of cognitive impairment and localization of cerebral infarcts in CT after clipping of ruptured intracranial aneurysms has been shown (283).

Superficial brain retraction injury was frequently seen in surgical patients (n=21; 45%). Four endovascular patients had these lesions because of additional surgical treatments. Surgical patients also showed significantly more ischemic lesions in the parent artery territory of the ruptured aneurysm (n=21; 45% vs. n=8; 20%), but not at remote locations. These findings suggest that surgical manipulation of the arteries does provoke local VSP leading to ischemic deficits, but surgery itself combined with rinsing of the basal cisterns neither produces nor prevents general VSP, as previously suggested (85).

The results in the present study are almost identical with the results in the study of Hadjivassiliou et al. (94) where surgically treated patients had a significantly higher incidence of MRI-detectable small infarcts within the parent artery territory, but endovascularly and surgically treated patients had equal incidences of large infarcts and global ischemic damage.

7. Neuropsychological outcomes

Being aware of the limitations of crude and subjective clinical estimation of outcome we employed a battery of standardized and widely used tests for neuropsychological evaluations. The importance of weighting outcome after SAH by neuropsychological factors has been emphasized after recognizing many patients with no clinical evidence of disability after SAH do suffer from subtle cognitive impairments (17, 115, 162, 193). On the other hand, in some studies there have been few subtle signs of impairment of cognition and memory detected in patients with good neurological outcome (18, 174). In the present study, only a few patients with moderate or severe disability were able to perform all the neuropsychological tests. Thus, the comparison of scoring between treatment groups in these patients was not possible. Only patients with good clinical outcome were included in the final analysis of neuropsychological test scores.

No difference in the neuropsychological test scores could be detected between the patients in the treatment groups. However, the patients in both groups improved their performance in many tests between the 3- and 12-month assessments, while the clinical outcome evaluation failed to show any improvement, indicating the value of neuropsychological evaluation. It is obvious that cognitive dysfunctions could have been found if the patients had been compared with individuals with no history of SAH. However, the aim of the present study was to determine the differences in neuropsychological outcome occurring after endovascular or surgical treatment of the intracranial aneurysms.

It seems that the severity of initial SAH mainly determines the neurological and neuropsychological outcomes, explaining why the treatment groups showed similar patterns of impairment, as suggested by others (17). However, the paired case-match study of Hadjivassiliou et al. (94) suggested that endovascular treatment might cause less MRI detectable structural brain damage than surgery. Furthermore,

endovascularly treated patients seemed to have a more favorable cognitive outcome based on comprehensive neuropsychological tests performed one year after treatment. The results in the present study might have shown a similar trend with a larger sample of patients since the presence of an ischemic lesion in the parent artery territory, more commonly found in the surgical group, proved to be an independent predictor of poorer clinical outcome.

8. Future prospects in aneurysm treatment

During the present study period, both the endovascular and surgical techniques remained stable, with the exception of introduction of the new “soft” GDC coils. Comparing the endovascular and surgical treatment modalities will probably be more difficult in the future because endovascular techniques are under constant and rapid evolution. Aneurysms with unfavorable geometry and morphology may be successfully treated with the remodeling technique of balloon assisted GDC placement (6, 156, 166, 180). The new generation of flexible stents allow more distal application in the intracranial vessels and tight coil packing through the stent (148, 177). Endovascular coils with three-dimensional geometry (32), and neck-bridging devices (214) may improve long-term anatomic results through reduction in coil compaction and aneurysm re-formation. The biologically active covered coils or radioactive coils may accelerate aneurysm fibrosis and intensify neck neointima formation (2, 183, 184, 215). Embolization of wide-necked intracranial aneurysms with new liquid embolic agents combined with protective devices has proved useful in treating giant aneurysms previously considered unsuitable to coil endovascular treatment (170).

The results of ongoing large randomized multicenter study of endovascular versus surgical treatment of ruptured intracranial aneurysms (ISAT) (179) will probably modify the future guidelines for treating ruptured aneurysms. The results of the present study and the development of the endovascular treatment have already modified the current protocol of aneurysm treatment in our own center. Three-D angiography has facilitated the evaluation of aneurysm morphology, especially the definition of the neck. If the aneurysm geometry is suitable for GDC-treatment, this modality of treatment is preferred in patients with posterior circulation aneurysms, in patients with very proximal carotid aneurysms, in patients with poor Hunt&Hess

grades (Gr IV-V) or with severe illnesses, and in elderly patients with no definite age limit. However, in most aneurysms, surgical ligation is still considered to be the treatment of choice. In the subgroup of patients with complex aneurysm geometry and a high risk related to surgery, endovascular treatment with “remodeling”-technique or stenting with or without coiling is considered. Sometimes combined endovascular and surgical treatment (staged procedure) is considered as the best option for treatment.

The evolution of surgical treatment is not as expeditious since the surgical standards have been developed during several decades achieving their current high standards (289, 290). However, one important issue will be how to maintain the surgical expertise. Interventional neuroradiologists are gaining experience and thus an increasing number of aneurysms will be treated by endovascular means. The ones left for open surgical treatment are those with most complex anatomy, or those having already undergone failed endovascular treatment. One possible way to improve surgical results might be reserving open surgery to the care of microvascular subspecialists. Endovascular therapists do not touch the brain, and those continuing to perform open microsurgery should be able to do nearly so with atraumatic techniques. The current impressions and opinions in the literature of the limitations and advantages of endovascular or surgical treatment of ruptured intracranial aneurysms are presented in Table 12.

9. Medical complications and splanchnic tissue perfusion after subarachnoid hemorrhage

Medical complications after aneurysmal SAH may significantly contribute to the overall mortality rate (101, 149, 244, 293). Gruber et al. (84) noted a 29% SIRS rate among SAH patients and found that 77% of extracerebral organ system failures (OSFs) occurred in conjunction with SIRS. The mortality rate was 40.2% in patients with systemic inflammatory response syndrome (SIRS). The results were in accordance with a recent study by Yoshimoto et al. (293) who also stated that there was an association between admission SIRS score and subsequent neurological deterioration. These findings gave rise to speculation that some mechanism of central dysregulation secondary to intracranial aneurysm rupture could contribute to the development and progression of extracerebral organ dysfunction by promoting a

state of systemic inflammation with the potential for systemic organ dysfunction (84, 293). In the present study, 23% of the patients had extracerebral complications during their ICU stay. However, the number of patients was small. Therefore, it is difficult to compare the type and rate of complications in the present study with the complications reported in other related studies.

Table 12. Current impressions and opinions in the literature of the limitations and advantages of endovascular or surgical treatment of ruptured intracranial aneurysms.

Feature	Endovascular treatment	Surgical treatment
Safety	++	++
Morphological aneurysm occlusion	+	++
Short term efficacy in preventing rebleeding	++	+++
Shown long term efficacy in preventing rebleeding	+	++
Applicability in aneurysms with complex geometry	- / +	- / +
Applicability in posterior circulation aneurysms	+++	++
Applicability in anterior circulation aneurysms	++	+++
Need for angiographic follow-up	--	+
Cost (including the follow-up)	--	-
Availability	++	+++
Learning curve duration	--	---
Stress for the patient	++	-
Evolution of the technique	+++	-

*Note: + means minor benefit, ++ moderate benefit and +++ remarkable benefit
- means minor limitation, -- moderate limitation and --- remarkable limitation*

9.1. Splanchnic tissue perfusion, assessed by gastric tonometry

Insufficient splanchnic tissue perfusion has been regarded as one of the possible mechanisms responsible for the SIRS (7) and multiple organ dysfunction syndrome (155). Pulmonary dysfunction caused either by central dysregulation and high-permeability pulmonary edema or by secondary aspiration pneumonia is one of the most common organ dysfunctions related to SAH (84, 244). Although SAH patients commonly present with hypovolemia (186), the volume correction under these circumstances is difficult. Further, high levels of catecholamine in plasma have been found in patients with SAH (47). Increased levels of catecholamines or cytokines may cause vasoconstriction in the splanchnic area and lead to deterioration of splanchnic tissue perfusion (241, 279).

Although splanchnic hypoperfusion may be induced by central dysregulation, correlating with the severity of the CNS trauma in acute low flow states, splanchnic blood volume and flow redistributes from less vital to vital organs such as heart and the brain (56, 155). Therefore gastrointestinal hypoperfusion may be the first sign of insufficient systemic oxygen delivery and in fact may reflect the neurological deterioration. There is evidence that splanchnic ischemia occurs commonly in isolated neurotrauma, there being a trend toward development of mucosal ischemia with decreased cerebral perfusion (279). However, there are no studies about this issue in the patients with SAH.

The mean values (\pm SD) of pCO₂ gap in the grouped data of the present study were 1.5 \pm 1.9 kPa and 1.7 \pm 1.2 at the time of the first and the second measurements, respectively. These results suggest that splanchnic tissue perfusion may be insufficient after SAH. The proposed upper limits for a normal pCO₂ gap have varied from 1.2 kPa (141), to values as high as 3.2 kPa in healthy volunteers (119). Although plasma levels of norepinephrine or epinephrine correlate with the severity of SAH (21, 47), we found no correlation between the pCO₂ gap and the severity of hemorrhage. There was also no difference in the levels of pCO₂ gap between the two treatment groups. However, the results are in accordance with the study by Venkatesh (279). They found no clear correlation between the development of mucosal ischemia and the decrease in cerebral perfusion in patients with traumatic brain injury.

Several problems accompanied this substudy. First of all, a high number of patients could not tolerate the stiff nasogastric tube, and thus the majority of the patients enrolled to the randomized study could not be included in this substudy. Although the aim of this substudy was to evaluate the early response of SAH and the modality of treatment on splanchnic tissue perfusion, the time period for measurements was too short to detect the changes in the pCO₂ gap, possibly occurring with the post-treatment clinical deterioration frequently observed during the ICU treatment. Furthermore, there are several problems associated with pHi measurements. The measurements of PCO₂ from saline samples can introduce errors in pHi values because of the low stability of PCO₂ in saline and the extensive variation in the quality of the different gas analyzers (222, 249). Due to the equilibration period needed, rapid changes in splanchnic tissue perfusion cannot be promptly detected (155). These drawbacks could be avoided by applying a new automated gas tonometric technique (37).

10. Vasospasm and cerebral perfusion

In the present study the incidence of symptoms that were regarded as probable symptoms of VSP did not significantly differ between the treatment groups. However, only in half of the patients in both treatment groups were the symptoms of VSP considered to be definitely absent. Although the incidence of probable or possible VSP was high, these findings are in accordance with the incidence of VSP reported in previous surgical series (135, 236). Recent endovascular series have reported somewhat lower frequencies of 21% to 23% of VSP (182, 216). The nonrandomized series by Gruber et al. (85) comparing treatment of acutely rupture intracranial aneurysms by GDC coils or surgical neck clipping found a higher incidence of delayed ischemic infarctions in the endovascular treatment group. However, the treatment groups were imbalanced, and in patients with Fisher grade 3, where the treatment groups were comparable, the endovascularly treated patients had fewer infarcts.

The diagnosis of VSP should be accurately set at the very early phase of VSP when the ischemic changes still can be reversed e.g. by the application of the “Triple-H therapy” (10, 132, 197) or balloon angioplasty (58, 69, 151, 159, 204). Since the

clinical diagnosis of VSP is based on the time of onset, the nature and course of the deficits, and the exclusion of other factors that may cause gradual deterioration of the patient or focal neurological signs (133), it is difficult to define in patients with impaired consciousness (48, 144, 152). Angiography is the standard method for assessing the degree of arterial narrowing caused by cerebral VSP (70), however it is invasive with a risk for permanent complications (31). A TCD technique has been proposed for noninvasive evaluation of cerebral VSP (1). On the other hand, TCD or angiography do not directly address the effects of VSP on the rCBF in the associated vascular territories (33, 41, 69).

It has been shown that after SAH there is a fall in cerebral blood flow to a degree which depends on the severity of VSP (120, 288). Powers et al. (206) were able to demonstrate a range of rCBF for reversible ischemia ($12 \text{ ml/ } 100\text{g/ min} < \text{CBF} < 20 \text{ ml/ } 100 \text{ g/ min}$) and irreversible infarction ($\text{CBF} \leq 12 \text{ ml/ } 100 \text{ g/ min}$). However, the authors suggest that cerebral VSP is not a static process, thus it may be impossible to set absolutely consistent thresholds for reversible ischemia and irreversible infarction. Therefore there may not be a need for quantitative measurements of CBF after SAH. Detection of the existence of disturbances in cerebral perfusion might help to identify those patients who are at risk for developing DID.

10.1. Cerebral perfusion before and after treatment, assessed by single photon emission tomography

SPECT is widely available and in clinical use, it has provided useful data for detecting VSP (40, 207, 245). In the present study it was decided to use SPECT as a qualitative method for detecting the differences in cerebral perfusion occurring before and after endovascular or surgical treatment of ruptured aneurysms. The original idea was to use the first SPECT study as a baseline study in which disturbances in cerebral perfusion caused either by VSP or treatment would not yet have developed. Perfusion deficits were frequently seen before treatment. In the SPECT performed before treatment, there were only 5 (20.8%) patients without cerebral perfusion deficits in the surgical treatment group and 8 (36.4%) patients in the endovascular group. Another study found that the reduction in CBF and CMRO occurred at the very early stage of SAH possibly as a consequence of elevated ICP at the time of

aneurysm rupture (99). Other possible causes for early CBF reduction after SAH may be early microvascular vasoconstriction (15), hydrocephalus (97) or reduced metabolic demands of the brain because of the initial effects of SAH on brain tissue (25, 81, 286). Thus, our observation of a variety of abnormalities in the first SPECT is in agreement with the findings reported in the literature.

In the visual comparison between the first and second SPECT, the number of new or enlarged deficits, and deficits which expanded from being unilateral to bilateral significantly increased in the surgical group. The comparison between the first and second SPECT revealed significant decreases in cortico-cerebellar perfusion ratios (CCRs): in the right frontobasal cortex, right frontal cortex and right pericallosal area in the surgical group. In the second SPECT, surgical patients had decreased CCRs in the right frontobasal cortex when compared to the endovascular patients and in the ipsilateral frontobasal cortex and ipsilateral temporal when compared to contralateral side of the ruptured aneurysm. These findings, not demonstrated in the endovascular group, suggest that surgery has a greater impact on cerebral perfusion than endovascular treatment. Although most of the perfusion deficits seen in the second SPECT were transient and not detectable in the late MRI of the brain, the results in the present study are in accordance with the results in the study by Hadjivassiliou et al. (94), where endovascular treatment was found to cause less permanent structural brain damage than surgical treatment.

Many authors have detected decreased perfusion near the site of the ligated aneurysm not correlating with the patients' neurological condition, possibly being related to the use of brain retractors or just manipulation of the brain causing postoperative edema (111, 112, 232). Hosono et al. (112) found disturbances in cerebral perfusion near the operative site in 29 of the consecutive 35 patients with SAH already on day 1 after surgery. Only the deficits which appeared newly on day 7 after surgery were considered to be caused by VSP. A similar interpretation of the SPECT studies was suggested by Rosen et al. (232) who found abnormalities of rCBF observed near the operative site in 17 of 20 SPECT studies, performed on patients without clinical VSP. According to these workers, only rCBF abnormalities remote from the operative site should be interpreted as indicating VSP. The postoperative decreases in perfusion in the ROIs of temporal apex and frontobasal cortex ipsilateral to the ligated aneurysm might have been caused by surgical manipulation. However in the visual interpretation, the abnormal findings were

bilateral in 14 (64%) of the 22 abnormal SPECT studies in the surgical group indicative of global VSP in conjunction with the changes possibly caused by surgical manipulation. In the present study many of the perfusion deficits near the operative site were seen already before treatment. Furthermore, surgically treated patients commonly developed permanent ischemic deficits in the vascular territory of the parent artery. This may indicate that some of the regions of diminished postoperative perfusion in the frontal and temporal lobes probably have been caused by VSP, although not distinguished from the deficits with other etiology. Acute hydrocephalus may explain some findings, especially in the basal parts of the brain (97), but we could not confirm that hypothesis.

10.2. Vasospasm and single photon emission tomography

Good correlation between postoperative changes in SPECT and the occurrence of VSP has been demonstrated in many studies (40, 41, 207, 245, 259). In the present study, we could not ensure the proximity of SPECT and the onset of clinical VSP. However, the visually evaluated SPECT proved to have good sensitivity (96%), but low specificity (55%) for clinical VSP. These results are in accordance with the results achieved in previous studies (sensitivity of 85% to 89% and specificity of 71% to 88%), indicating that SPECT could accurately corroborate the clinical suspicion of VSP (41, 207). Discordantly with the results in most studies, Hosono et al. (112) found visual interpretation of TCD-SPECT to have a very low sensitivity (33%) in indicating VSP confirmed by angiography or CT. On the other hand, they found noninvasive measurement of mean CBF (decrease over 10% between the two studies) using ^{99m}Tc -ECD as a tracer to indicate VSP with good sensitivity (78%) and specificity (89%). The discordant results may partly be explained by the fact that in visual interpretation of the results they considered only the newly developed deficits between the SPECT studies performed on day 1 and 7 after SAH as being indicative of VSP.

According to the results of the present study, static SPECT may not be very useful for routine guidance in the treatment of patients with aneurysmal SAH, although it may rule out VSP in some problematic cases. Recognition that parenchymal vessels distal to arteries with angiographic spasm after SAH do not show normal autoregulatory vasodilatation (206, 294), has encouraged authors to

devise dynamic studies utilizing SPECT or other qualitative methods to identify patients at increased risk for DID. Acetazolamide challenge of the cerebrovascular reserve as studied by SPECT has been accurately found to preclude the patients with clinically irrelevant deficits in cerebral perfusion (138). However with the current limitations, dynamic SPECT cannot serve as a real bedside method for observation of the patients during the time course of VSP. A transient hyperemic response test (THRT) in conjunction with the TCD evaluation may provide a simple, noninvasive bedside technique for frequent examination of the autoregulatory reserve in SAH patients (147, 213). A promising new, although invasive, method for bedside monitoring of brain ischemia is intracerebral microdialysis. Nilson et al. (188) found that changes in extracellular biochemical parameters actually preceded both the increased blood flow velocities as measured by TCD and the subsequent clinical deterioration of the patient.

CONCLUSIONS

1. Endovascular treatment of acutely ruptured intracranial aneurysms with GDC coils is technically feasible in a selected group of patients with the procedure related morbidity and mortality rates equal to those seen with surgical ligation. However, failure in coil treatment is more common than failure in surgical clipping, thus subsequent surgical treatment is frequently required. Surgery provides better primary angiographic occlusion rates in most anterior circulation aneurysms while aneurysms in posterior circulation are better treated with coils.

2. The severity of the initial SAH is the most important factor determining the outcome of the patients. Although endovascular treatment is less often associated with MRI-detectable brain injury, both modalities of treatment result in equal clinical and neuropsychological outcomes. Angiographic follow-up reveals often unstable occlusion in the endovascularly treated intracranial aneurysms. Thus, the long-term efficacy of endovascular treatment in preventing rebleeding remains open. Developments in endovascular techniques may improve the morphological results and reduce the frequency and need for angiographic follow-up.

3. Splanchnic tissue perfusion, as assessed by gastric tonometry, may be insufficient after SAH. However, neither surgical or endovascular treatment nor the severity of initial SAH seem to affect splanchnic tissue perfusion as evaluated by measuring the pCO₂ gap. Use of gastric tonometry as a therapeutic tool in SAH patients cannot be recommended without a further development in technique.

4. Disturbances in regional cerebral perfusion both before and after treatment of ruptured intracranial aneurysms are common as evaluated by ECD-SPECT. Progression of perfusion deficits was more common in the surgical group. However, the clinical importance of these findings is unclear since MRI of the brain revealed an equal number of ischemic deficits in the treatment groups. Although SPECT findings are associated with clinical VSP and late ischemic deficits on MRI, the positive predictive value of SPECT is low.

REFERENCES

1. Aaslid R, Huber P, Nornes H: Evaluation of cerebrovascular spasm with transcranial Doppler ultrasound. *J Neurosurg* 60:37-41, 1984.
2. Abrahams JM, Diamond SL, Hurst RW, Zager EL, Grady MS: Topic review: surface modifications enhancing biological activity of Guglielmi detachable coils in treating intracranial aneurysms. *Surg Neurol* 54:34-41, 2000.
3. Adams WM, Laitt RD, Jackson A: The role of MR angiography in the pretreatment assessment of intracranial aneurysms: a comparative study. *AJNR Am J Neuroradiol* 21:1618-1628, 2000.
4. Ahola K, Vilkki J, Servo A: Frontal tests do not detect frontal infarctions after ruptured intracranial aneurysm. *Brain Cogn* 31:1-16, 1996.
5. Alberico RA, Patel M, Casey S, Jacobs B, Maguire W, Decker R: Evaluation of the circle of Willis with three-dimensional CT angiography in patients with suspected intracranial aneurysms. *AJNR Am J Neuroradiol* 16:1571-1580, 1995.
6. Aletich VA, Debrun GM, Misra M, Charbel F, Ausman JI: The remodeling technique of balloon-assisted Guglielmi detachable coil placement in wide-necked aneurysms: experience at the University of Illinois at Chicago. *J Neurosurg* 93:388-396, 2000.
7. American College of Chest Physicians/Society of Critical Care Medicine Consensus Conference: definitions for sepsis and organ failure and guidelines for the use of innovative therapies in sepsis. *Crit Care Med* 20:864-874, 1992.
8. Anderson GB, Ashforth R, Steinke DE, Findlay JM: CT angiography for the detection of cerebral vasospasm in patients with acute subarachnoid hemorrhage. *AJNR Am J Neuroradiol* 21:1011-1015, 2000.
9. Asenbaum S, Brucke T, Pirker W, Pietrzyk U, Podreka I: Imaging of cerebral blood flow with technetium-99m-HMPAO and technetium-99m-ECD: a comparison. *J Nucl Med* 39:613-618, 1998.
10. Awad IA, Carter LP, Spetzler RF, Medina M, Williams FC, Jr.: Clinical vasospasm after subarachnoid hemorrhage: response to hypervolemic hemodilution and arterial hypertension. *Stroke* 18:365-372, 1987.
11. Bailes JE, Spetzler RF, Hadley MN, Baldwin HZ: Management morbidity and mortality of poor-grade aneurysm patients. *J Neurosurg* 72:559-566, 1990.
12. Barquist E, Kirton O, Windsor J, Hudson-Civetta J, Lynn M, Herman M, Civetta J: The impact of antioxidant and splanchnic-directed therapy on persistent uncorrected gastric mucosal pH in the critically injured trauma patient. *J Trauma* 44:355-360, 1998.

13. Batjer H, Samson D: Intraoperative aneurysmal rupture: incidence, outcome, and suggestions for surgical management. *Neurosurgery* 18:701-707, 1986.
14. Bavinzski G, Talazoglu V, Killer M, Richling B, Gruber A, Gross CE, Plenk H, Jr.: Gross and microscopic histopathological findings in aneurysms of the human brain treated with Guglielmi detachable coils. *J Neurosurg* 91:284-293, 1999.
15. Bederson JB, Levy AL, Ding WH, Kahn R, DiPerna CA, Jenkins AL, 3rd, Vallabhajosyula P: Acute vasoconstriction after subarachnoid hemorrhage. *Neurosurgery* 42:352-360, 1998.
16. Berenstein A, Ransohoff J, Kupersmith M, Flamm E, Graeb D: Transvascular treatment of giant aneurysms of the cavernous carotid and vertebral arteries. Functional investigation and embolization. *Surg Neurol* 21:3-12, 1984.
17. Berry E, Jones RA, West CG, Brown JD: Outcome of subarachnoid haemorrhage. An analysis of surgical variables, cognitive and emotional sequelae related to SPECT scanning. *Br J Neurosurg* 11:378-387, 1997.
18. Bornstein RA, Weir BK, Petruk KC, Disney LB: Neuropsychological function in patients after subarachnoid hemorrhage. *Neurosurgery* 21:651-654, 1987.
19. Boulin A, Pierot L: Follow-up of intracranial aneurysms treated with detachable coils: comparison of gadolinium-enhanced 3D time-of-flight MR angiography and digital subtraction angiography. *Radiology* 219:108-113, 2001.
20. Brilstra EH, Rinkel GJ, van der Graaf Y, van Rooij WJ, Algra A: Treatment of intracranial aneurysms by embolization with coils: a systematic review. *Stroke* 30:470-476, 1999.
21. Brouwers PJ, Westenberg HG, Van Gijn J: Noradrenaline concentrations and electrocardiographic abnormalities after aneurysmal subarachnoid haemorrhage. *J Neurol Neurosurg Psychiatry* 58:614-617, 1995.
22. Byrne JV, Adams CB, Kerr RS, Molyneux AJ: Endosaccular treatment of inoperable intracranial aneurysms with platinum coils. *Br J Neurosurg* 9:585-592, 1995.
23. Byrne JV, Molyneux AJ, Brennan RP, Renowden SA: Embolisation of recently ruptured intracranial aneurysms. *J Neurol Neurosurg Psychiatry* 59:616-620, 1995.
24. Byrne JV, Sohn MJ, Molyneux AJ, Chir B: Five-year experience in using coil embolization for ruptured intracranial aneurysms: outcomes and incidence of late rebleeding. *J Neurosurg* 90:656-663, 1999.

25. Carpenter DA, Grubb RL, Jr., Tempel LW, Powers WJ: Cerebral oxygen metabolism after aneurysmal subarachnoid hemorrhage. *J Cereb Blood Flow Metab* 11:837-844, 1991.
26. Carter BS, Buckley D, Ferraro R, Rordorf G, Ogilvy CS: Factors associated with reintegration to normal living after subarachnoid hemorrhage. *Neurosurgery* 46:1326-1334, 2000.
27. Casasco AE, Aymard A, Gobin YP, Houdart E, Rogopoulos A, George B, Hodes JE, Cophignon J, Merland JJ: Selective endovascular treatment of 71 intracranial aneurysms with platinum coils. *J Neurosurg* 79:3-10, 1993.
28. Chiang VL, Claus EB, Awad IA: Toward more rational prediction of outcome in patients with high-grade subarachnoid hemorrhage. *Neurosurgery* 46:28-36, 2000.
29. Chyatte D, Fode NC, Sundt TM, Jr.: Early versus late intracranial aneurysm surgery in subarachnoid hemorrhage. *J Neurosurg* 69:326-331, 1988.
30. Civit T, Auque J, Marchal JC, Bracard S, Picard L, Hepner H: Aneurysm clipping after endovascular treatment with coils: a report of eight patients. *Neurosurgery* 38:955-961, 1996.
31. Cloft HJ, Joseph GJ, Dion JE: Risk of cerebral angiography in patients with subarachnoid hemorrhage, cerebral aneurysm, and arteriovenous malformation: a meta-analysis. *Stroke* 30:317-320, 1999.
32. Cloft HJ, Joseph GJ, Tong FC, Goldstein JH, Dion JE: Use of three-dimensional Guglielmi detachable coils in the treatment of wide-necked cerebral aneurysms. *AJNR Am J Neuroradiol* 21:1312-1314, 2000.
33. Clyde BL, Resnick DK, Yonas H, Smith HA, Kaufmann AM: The relationship of blood velocity as measured by transcranial doppler ultrasonography to cerebral blood flow as determined by stable xenon computed tomographic studies after aneurysmal subarachnoid hemorrhage. *Neurosurgery* 38:896-904, 1996.
34. Cognard C, Weill A, Castaings L, Rey A, Moret J: Intracranial berry aneurysms: angiographic and clinical results after endovascular treatment. *Radiology* 206:499-510, 1998.
35. Cognard C, Weill A, Spelle L, Piotin M, Castaings L, Rey A, Moret J: Long-term angiographic follow-up of 169 intracranial berry aneurysms occluded with detachable coils. *Radiology* 212:348-356, 1999.
36. Cognard C, Weill A, Tovi M, Castaings L, Rey A, Moret J: Treatment of distal aneurysms of the cerebellar arteries by intraaneurysmal injection of glue. *AJNR Am J Neuroradiol* 20:780-784, 1999.

37. Creteur J, De Backer D, Vincent JL: Monitoring gastric mucosal carbon dioxide pressure using gas tonometry: in vitro and in vivo validation studies. *Anesthesiology* 87:504-510, 1997.
38. Dandy WE: Intracranial aneurysms of the internal carotid artery: cured by operation. *Ann Surg* 107:654-659, 1938.
39. David CA, Vishteh AG, Spetzler RF, Lemole M, Lawton MT, Partovi S: Late angiographic follow-up review of surgically treated aneurysms. *J Neurosurg* 91:396-401, 1999.
40. Davis S, Andrews J, Lichtenstein M, Kaye A, Tress B, Rossiter S, Salehi N, Binns D: A single-photon emission computed tomography study of hypoperfusion after subarachnoid hemorrhage. *Stroke* 21:252-259, 1990.
41. Davis SM, Andrews JT, Lichtenstein M, Rossiter SC, Kaye AH, Hopper J: Correlations between cerebral arterial velocities, blood flow, and delayed ischemia after subarachnoid hemorrhage. *Stroke* 23:492-497, 1992.
42. de Gans K, Nieuwkamp DJ, Rinkel GJ, Algra A: Timing of aneurysm surgery in subarachnoid hemorrhage: a systematic review of the literature. *Neurosurgery* 50:336-342, 2002.
43. Debrun G, Fox A, Drake C, Peerless S, Girvin J, Ferguson G: Giant unclippable aneurysms: treatment with detachable balloons. *AJNR Am J Neuroradiol* 2:167-173, 1981.
44. Debrun GM, Aletich VA, Kehrli P, Misra M, Ausman JI, Charbel F: Selection of cerebral aneurysms for treatment using Guglielmi detachable coils: the preliminary University of Illinois at Chicago experience. *Neurosurgery* 43:1281-1297, 1998.
45. Debrun GM, Aletich VA, Thornton J, Alazzaz A, Charbel FT, Ausman JI, Bashir Q: Techniques of coiling cerebral aneurysms. *Surg Neurol* 53:150-156, 2000.
46. Devous MD, Sr.: Instrumentation, Radiopharmaceuticals, and Technical Factors, in Van Heertum RL, Tikofsky RS (eds): *Cerebral SPECT Imaging*. New York, Raven Press, Ltd., 1995, pp 3-19.
47. Dilraj A, Botha JH, Rambiritch V, Miller R, van Dellen JR: Levels of catecholamine in plasma and cerebrospinal fluid in aneurysmal subarachnoid hemorrhage. *Neurosurgery* 31:42-51, 1992.
48. Disney L, Weir B, Grace M: Factors influencing the outcome of aneurysm rupture in poor grade patients: a prospective series. *Neurosurgery* 23:1-9, 1988.
49. Disney L, Weir B, Petruk K: Effect on management mortality of a deliberate policy of early operation on supratentorial aneurysms. *Neurosurgery* 20:695-701, 1987.

50. Dott NM: Intracranial aneurysms: cerebral arterio-radiography: surgical treatment. *Edinburgh Med J* 40:219-240, 1933.
51. Dowd CF, Halbach VV, Higashida RT, Barnwell SL, Hieshima GB: Endovascular coil embolization of unusual posterior inferior cerebellar artery aneurysms. *Neurosurgery* 27:954-961, 1990.
52. Drake CG: Progress in cerebrovascular disease. Management of cerebral aneurysm. *Stroke* 12:273-283, 1981.
53. Drake CG, Friedman AH, Peerless SJ: Failed aneurysm surgery. Reoperation in 115 cases. *J Neurosurg* 61:848-856, 1984.
54. Drake CG, Peerless SJ, Ferguson GF: Hunterian proximal arterial occlusion for giant aneurysms of the carotid circulation. *J Neurosurg* 81:656-665, 1994.
55. Drake CG, Peerless SJ, Hernesniemi JA: Surgery of vertebrobasilar aneurysms: London Ontario experience on 1,767 patients. Berlin Heidelberg New York Tokyo, Springer-Verlag, 1996.
56. Edouard AR, Degremont AC, Duranteau J, Pussard E, Berdeaux A, Samii K: Heterogeneous regional vascular responses to simulated transient hypovolemia in man. *Intensive Care Med* 20:414-420, 1994.
57. Egge A, Waterloo K, Sjöholm H, Solberg T, Ingebrigtsen T, Romner B: Prophylactic hyperdynamic postoperative fluid therapy after aneurysmal subarachnoid hemorrhage: a clinical, prospective, randomized, controlled study. *Neurosurgery* 49:593-606, 2001.
58. Elliott JP, Newell DW, Lam DJ, Eskridge JM, Douville CM, Le Roux PD, Lewis DH, Mayberg MR, Grady MS, Winn HR: Comparison of balloon angioplasty and papaverine infusion for the treatment of vasospasm following aneurysmal subarachnoid hemorrhage. *J Neurosurg* 88:277-284, 1998.
59. Eskridge JM, McAuliffe W, Song JK, Deliganis AV, Newell DW, Lewis DH, Mayberg MR, Winn HR: Balloon angioplasty for the treatment of vasospasm: results of first 50 cases. *Neurosurgery* 42:510-517, 1998.
60. Eskridge JM, Song JK: Endovascular embolization of 150 basilar tip aneurysms with Guglielmi detachable coils: results of the Food and Drug Administration multicenter clinical trial. *J Neurosurg* 89:81-86, 1998.
61. Feigin VL, Rinkel GJ, Algra A, Vermeulen M, van Gijn J: Calcium antagonists for aneurysmal subarachnoid haemorrhage. *Cochrane Database Syst Rev*:CD000277, 2000.
62. Fernandez Zubillaga A, Guglielmi G, Vinuela F, Duckwiler GR: Endovascular occlusion of intracranial aneurysms with electrically detachable coils: correlation of aneurysm neck size and treatment results. *AJNR Am J Neuroradiol* 15:815-820, 1994.

63. Feuerberg I, Lindquist C, Lindqvist M, Steiner L: Natural history of postoperative aneurysm rests. *J Neurosurg* 66:30-34, 1987.
64. Fiddian-Green RG, Baker S: Predictive value of the stomach wall pH for complications after cardiac operations: comparison with other monitoring. *Crit Care Med* 15:153-156, 1987.
65. Fiddian-Green RG, Pittenger G, Whitehouse WM, Jr.: Back-diffusion of CO₂ and its influence on the intramural pH in gastric mucosa. *J Surg Res* 33:39-48, 1982.
66. Findlay JM: Current management of aneurysmal subarachnoid hemorrhage guidelines from the Canadian Neurosurgical Society. *Can J Neurol Sci* 24:161-170, 1997.
67. Findlay JM, Macdonald RL, Weir BK: Current concepts of pathophysiology and management of cerebral vasospasm following aneurysmal subarachnoid hemorrhage. *Cerebrovasc Brain Metab Rev* 3:336-361, 1991.
68. Findlay JM, Weir BK, Kanamaru K, Espinosa F: Arterial wall changes in cerebral vasospasm. *Neurosurgery* 25:736-746, 1989.
69. Firlik AD, Kaufmann AM, Jungreis CA, Yonas H: Effect of transluminal angioplasty on cerebral blood flow in the management of symptomatic vasospasm following aneurysmal subarachnoid hemorrhage. *J Neurosurg* 86:830-839, 1997.
70. Fisher CM, Kistler JP, Davis JM: Relation of cerebral vasospasm to subarachnoid hemorrhage visualized by computerized tomographic scanning. *Neurosurgery* 6:1-9, 1980.
71. Fogelholm R: Subarachnoid hemorrhage in middle-Finland: incidence, early prognosis and indications for neurosurgical treatment. *Stroke* 12:296-301, 1981.
72. Fogelholm R, Hernesniemi J, Vapalahti M: Impact of early surgery on outcome after aneurysmal subarachnoid hemorrhage. A population-based study. *Stroke* 24:1649-1654, 1993.
73. Folstein MF, Folstein SE, McHugh PR: "Mini-mental state". A practical method for grading the cognitive state of patients for the clinician. *J Psychiatr Res* 12:189-198, 1975.
74. Fridriksson S, Säveland H, Jakobsson KE, Edner G, Zygmunt S, Brandt L, Hillman J: Intraoperative complications in aneurysm surgery: a prospective national study. *J Neurosurg* 96:515-522, 2002.
75. Giannotta SL, Litofsky NS: Reoperative management of intracranial aneurysms. *J Neurosurg* 83:387-393, 1995.

76. Gomersall CD, Joynt GM, Freebairn RC, Hung V, Buckley TA, Oh TE: Resuscitation of critically ill patients based on the results of gastric tonometry: a prospective, randomized, controlled trial. *Crit Care Med* 28:607-614., 2000.
77. Grandin CB, Cosnard G, Hammer F, Duprez TP, Stroobandt G, Mathurin P: Vasospasm after subarachnoid hemorrhage: diagnosis with MR angiography. *AJNR Am J Neuroradiol* 21:1611-1617, 2000.
78. Graves VB, Partington CR, Rufenacht DA, Rappe AH, Strother CM: Treatment of carotid artery aneurysms with platinum coils: an experimental study in dogs. *AJNR Am J Neuroradiol* 11:249-252, 1990.
79. Griffiths PD, Wilkinson ID, Mitchell P, Patel MC, Paley MN, Romanowski CA, Powell T, Hodgson TJ, Hoggard N, Jellinek D: Multimodality MR imaging depiction of hemodynamic changes and cerebral ischemia in subarachnoid hemorrhage. *AJNR Am J Neuroradiol* 22:1690-1697, 2001.
80. Groden C, Kremer C, Regelsberger J, Hansen HC, Zeumer H: Comparison of operative and endovascular treatment of anterior circulation aneurysms in patients in poor grades. *Neuroradiology* 43:778-783, 2001.
81. Grubb RL, Jr., Raichle ME, Eichling JO, Gado MH: Effects of subarachnoid hemorrhage on cerebral blood volume, blood flow, and oxygen utilization in humans. *J Neurosurg* 46:446-453, 1977.
82. Gruber A, Killer M, Bavinzski G, Richling B: Clinical and angiographic results of endosaccular coiling treatment of giant and very large intracranial aneurysms: a 7-year, single-center experience. *Neurosurgery* 45:793-804, 1999.
83. Gruber A, Reinprecht A, Bavinzski G, Czech T, Richling B: Chronic shunt-dependent hydrocephalus after early surgical and early endovascular treatment of ruptured intracranial aneurysms. *Neurosurgery* 44:503-512, 1999.
84. Gruber A, Reinprecht A, Illievich UM, Fitzgerald R, Dietrich W, Czech T, Richling B: Extracerebral organ dysfunction and neurologic outcome after aneurysmal subarachnoid hemorrhage. *Crit Care Med* 27:505-514, 1999.
85. Gruber A, Ungersbock K, Reinprecht A, Czech T, Gross C, Bednar M, Richling B: Evaluation of cerebral vasospasm after early surgical and endovascular treatment of ruptured intracranial aneurysms. *Neurosurgery* 42:258-268, 1998.
86. Gruber DP, Zimmerman GA, Tomsick TA, van Loveren HR, Link MJ, Tew JM, Jr.: A comparison between endovascular and surgical management of basilar artery apex aneurysms. *J Neurosurg* 90:868-874, 1999.
87. Guglielmi G: Endovascular treatment of intracranial aneurysms. *Neuroimaging Clinics of North America* 2:269-278, 1992.

88. Guglielmi G, Vinuela F, Dion J, Duckwiler G: Electrothrombosis of saccular aneurysms via endovascular approach. Part 2: Preliminary clinical experience. *J Neurosurg* 75:8-14, 1991.
89. Guglielmi G, Vinuela F, Duckwiler G, Dion J, Lylyk P, Berenstein A, Strother C, Graves V, Halbach V, Nichols D, et al.: Endovascular treatment of posterior circulation aneurysms by electrothrombosis using electrically detachable coils. *J Neurosurg* 77:515-524, 1992.
90. Guglielmi G, Vinuela F, Sepetka I, Macellari V: Electrothrombosis of saccular aneurysms via endovascular approach. Part 1: Electrochemical basis, technique, and experimental results. *J Neurosurg* 75:1-7, 1991.
91. Gurian JH, Martin NA, King WA, Duckwiler GR, Guglielmi G, Vinuela F: Neurosurgical management of cerebral aneurysms following unsuccessful or incomplete endovascular embolization. *J Neurosurg* 83:843-853, 1995.
92. Gurian JH, Vinuela F, Guglielmi G, Gobin YP, Duckwiler GR: Endovascular embolization of superior hypophyseal artery aneurysms. *Neurosurgery* 39:1150-1156, 1996.
93. Gutierrez G, Palizas F, Doglio G, Wainsztein N, Gallesio A, Pacin J, Dubin A, Schiavi E, Jorge M, Pusajo J, et al.: Gastric intramucosal pH as a therapeutic index of tissue oxygenation in critically ill patients. *Lancet* 339:195-199, 1992.
94. Hadjivassiliou M, Tooth CL, Romanowski CA, Byrne J, Battersby RD, Oxbury S, Crewswell CS, Burkitt E, Stokes NA, Paul C, Mayes AR, Sagar HJ: Aneurysmal SAH: cognitive outcome and structural damage after clipping or coiling. *Neurology* 56:1672-1677, 2001.
95. Haley EC, Jr., Kassell NF, Apperson-Hansen C, Maile MH, Alves WM: A randomized, double-blind, vehicle-controlled trial of tirilazad mesylate in patients with aneurysmal subarachnoid hemorrhage: a cooperative study in North America. *J Neurosurg* 86:467-474, 1997.
96. Haley EC, Jr., Kassell NF, Torner JC: The International Cooperative Study on the Timing of Aneurysm Surgery. The North American experience. *Stroke* 23:205-214, 1992.
97. Hasan D, van Peski J, Loeve I, Krenning EP, Vermeulen M: Single photon emission computed tomography in patients with acute hydrocephalus or with cerebral ischaemia after subarachnoid haemorrhage. *J Neurol Neurosurg Psychiatry* 54:490-493, 1991.
98. Hayakawa M, Murayama Y, Duckwiler GR, Gobin YP, Guglielmi G, Vinuela F: Natural history of the neck remnant of a cerebral aneurysm treated with the Guglielmi detachable coil system. *J Neurosurg* 93:561-568, 2000.

99. Hayashi T, Suzuki A, Hatazawa J, Kanno I, Shirane R, Yoshimoto T, Yasui N: Cerebral circulation and metabolism in the acute stage of subarachnoid hemorrhage. *J Neurosurg* 93:1014-1018, 2000.
100. Hernesniemi J, Vapalahti M, Niskanen M, Kari A: Management outcome for vertebrobasilar artery aneurysms by early surgery. *Neurosurgery* 31:857-862, 1992.
101. Hernesniemi J, Vapalahti M, Niskanen M, Tapaninaho A, Kari A, Luukkonen M, Puranen M, Saari T, Rajpar M: One-year outcome in early aneurysm surgery: a 14 years experience. *Acta Neurochir (Wien)* 122:1-10, 1993.
102. Hieshima GB, Higashida RT, Halbach VV, Cahan L, Goto K: Intravascular balloon embolization of a carotid-ophthalmic artery aneurysm with preservation of the parent vessel. *AJNR Am J Neuroradiol* 7:916-918, 1986.
103. Higashida RT, Halbach VV, Barnwell SL, Dowd C, Dormandy B, Bell J, Hieshima GB: Treatment of intracranial aneurysms with preservation of the parent vessel: results of percutaneous balloon embolization in 84 patients. *AJNR Am J Neuroradiol* 11:633-640, 1990.
104. Higashida RT, Halbach VV, Dowd CF, Barnwell SL, Hieshima GB: Intracranial aneurysms: interventional neurovascular treatment with detachable balloons--results in 215 cases. *Radiology* 178:663-670, 1991.
105. Hillman J, Säveland H, Jakobsson KE, Edner G, Zygmunt S, Fridriksson S, Brandt L: Overall management outcome of ruptured posterior fossa aneurysms. *J Neurosurg* 85:33-38, 1996.
106. Hop JW, Rinkel GJ, Algra A, van Gijn J: Case-fatality rates and functional outcome after subarachnoid hemorrhage: a systematic review. *Stroke* 28:660-664, 1997.
107. Hop JW, Rinkel GJ, Algra A, van Gijn J: Quality of life in patients and partners after aneurysmal subarachnoid hemorrhage. *Stroke* 29:798-804, 1998.
108. Hope JK, Byrne JV, Molyneux AJ: Factors influencing successful angiographic occlusion of aneurysms treated by coil embolization. *AJNR Am J Neuroradiol* 20:391-399, 1999.
109. Hope JK, Wilson JL, Thomson FJ: Three-dimensional CT angiography in the detection and characterization of intracranial berry aneurysms. *AJNR Am J Neuroradiol* 17:439-445, 1996.
110. Horowitz M, Purdy P, Kopitnik T, Dutton K, Samson D: Aneurysm retreatment after Guglielmi detachable coil and nondetachable coil embolization: report of nine cases and review of the literature. *Neurosurgery* 44:712-720, 1999.
111. Hosoda K, Fujita S, Kawaguchi T, Shose Y, Hamano S, Iwakura M: Effect of clot removal and surgical manipulation on regional cerebral blood flow and delayed

- vasospasm in early aneurysm surgery for subarachnoid hemorrhage. *Surg Neurol* 51:81-88, 1999.
112. Hosono M, Machida K, Matsui T, Honda N, Takahashi T, Dei S, Kashimada A, Shimizu Y, Osada H, Ohmichi M, Asano T: Non-invasive quantitative monitoring of cerebral blood flow in aneurysmal subarachnoid haemorrhage with ^{99m}Tc-ECD. *Nucl Med Commun* 23:5-11, 2002.
 113. Houkin K, Kuroda S, Takahashi A, Takikawa S, Ishikawa T, Yoshimoto T, Itamoto K: Intra-operative premature rupture of the cerebral aneurysms. Analysis of the causes and management. *Acta Neurochir (Wien)* 141:1255-1263, 1999.
 114. Hunt WE, Hess RM: Surgical risk as related to time of intervention in the repair of intracranial aneurysms. *J Neurosurg* 28:14-20, 1968.
 115. Hutter BO, Gilsbach JM: Which neuropsychological deficits are hidden behind a good outcome (Glasgow = 1) after aneurysmal subarachnoid hemorrhage? *Neurosurgery* 33:999-1005, 1993.
 116. Hutter BO, Kreitschmann-Andermahr I, Gilsbach JM: Cognitive deficits in the acute stage after subarachnoid hemorrhage. *Neurosurgery* 43:1054-1065, 1998.
 117. Inagawa T, Tokuda Y, Ohbayashi N, Takaya M, Moritake K: Study of aneurysmal subarachnoid hemorrhage in Izumo City, Japan. *Stroke* 26:761-766, 1995.
 118. Ishii R: Regional cerebral blood flow in patients with ruptured intracranial aneurysms. *J Neurosurg* 50:587-594, 1979.
 119. Jakob S, Ruokonen E, Takala J: Assessment of the adequacy of systemic and regional perfusion after cardiac surgery. *Br J Anaesth* 84:571-577, 2000.
 120. Jakobsen M, Overgaard J, Marcussen E, Enevoldsen EM: Relation between angiographic cerebral vasospasm and regional CBF in patients with SAH. *Acta Neurol Scand* 82:109-115, 1990.
 121. Jakobsson KE, Säveland H, Hillman J, Edner G, Zygmunt S, Brandt L, Pellettieri L: Warning leak and management outcome in aneurysmal subarachnoid hemorrhage. *J Neurosurg* 85:995-999, 1996.
 122. Jennet B, Bond M: Assessment of outcome after severe brain damage: a practical scale. *Lancet* 1:480-484, 1975.
 123. Johnson DW, Stringer WA, Marks MP, Yonas H, Good WF, Gur D: Stable xenon CT cerebral blood flow imaging: rationale for and role in clinical decision making. *AJNR Am J Neuroradiol* 12:201-213, 1991.
 124. Johnston SC, Selvin S, Gress DR: The burden, trends, and demographics of mortality from subarachnoid hemorrhage. *Neurology* 50:1413-1418, 1998.

125. Juvela S: Minor leak before rupture of an intracranial aneurysm and subarachnoid hemorrhage of unknown etiology. *Neurosurgery* 30:7-11, 1992.
126. Juvela S, Hillbom M, Numminen H, Koskinen P: Cigarette smoking and alcohol consumption as risk factors for aneurysmal subarachnoid hemorrhage. *Stroke* 24:639-646, 1993.
127. Juvela S, Porras M, Poussa K: Natural history of unruptured intracranial aneurysms: probability of and risk factors for aneurysm rupture. *J Neurosurg* 93:379-387, 2000.
128. Kähärä VJ, Seppanen SK, Kuurne T, Laasonen EM: Patient outcome after endovascular treatment of intracranial aneurysms with reference to microsurgical clipping. *Acta Neurol Scand* 99:284-290, 1999.
129. Kähärä VJ, Seppanen SK, Ryymin PS, Mattila P, Kuurne T, Laasonen EM: MR angiography with three-dimensional time-of-flight and targeted maximum-intensity-projection reconstructions in the follow-up of intracranial aneurysms embolized with Guglielmi detachable coils. *AJNR Am J Neuroradiol* 20:1470-1475, 1999.
130. Kassell NF, Haley EC, Jr., Apperson-Hansen C, Alves WM: Randomized, double-blind, vehicle-controlled trial of tirilazad mesylate in patients with aneurysmal subarachnoid hemorrhage: a cooperative study in Europe, Australia, and New Zealand. *J Neurosurg* 84:221-228, 1996.
131. Kassell NF, Helm G, Simmons N, Phillips CD, Cail WS: Treatment of cerebral vasospasm with intra-arterial papaverine. *J Neurosurg* 77:848-852, 1992.
132. Kassell NF, Peerless SJ, Durward QJ, Beck DW, Drake CG, Adams HP: Treatment of ischemic deficits from vasospasm with intravascular volume expansion and induced arterial hypertension. *Neurosurgery* 11:337-343, 1982.
133. Kassell NF, Sasaki T, Colohan AR, Nazar G: Cerebral vasospasm following aneurysmal subarachnoid hemorrhage. *Stroke* 16:562-572, 1985.
134. Kassell NF, Torner JC: Aneurysmal rebleeding: a preliminary report from the Cooperative Aneurysm Study. *Neurosurgery* 13:479-481, 1983.
135. Kassell NF, Torner JC, Haley EC, Jr., Jane JA, Adams HP, Kongable GL: The International Cooperative Study on the Timing of Aneurysm Surgery. Part 1: Overall management results. *J Neurosurg* 73:18-36, 1990.
136. Kassell NF, Torner JC, Jane JA, Haley EC, Jr., Adams HP: The International Cooperative Study on the Timing of Aneurysm Surgery. Part 2: Surgical results. *J Neurosurg* 73:37-47, 1990.
137. Keranen T, Tapaninaho A, Hernesniemi J, Vapalahti M: Late epilepsy after aneurysm operations. *Neurosurgery* 17:897-900, 1985.

138. Kimura T, Shinoda J, Funakoshi T: Prediction of cerebral infarction due to vasospasm following aneurysmal subarachnoid haemorrhage using acetazolamide-activated 123I-IMP SPECT. *Acta Neurochir Wien* 123:125-128, 1993.
139. Kistler JP, Crowell RM, Davis KR, Heros R, Ojemann RG, Zervas T, Fisher CM: The relation of cerebral vasospasm to the extent and location of subarachnoid blood visualized by CT scan: a prospective study. *Neurology* 33:424-436, 1983.
140. Kivisaari RP, Salonen O, Servo A, Autti T, Hernesniemi J, Öhman J: MR imaging after aneurysmal subarachnoid hemorrhage and surgery: a long-term follow-up study. *AJNR Am J Neuroradiol* 22:1143-1148, 2001.
141. Kolkman JJ, Steverink PJ, Groeneveld AB, Meuwissen SG: Characteristics of time-dependent PCO₂ tonometry in the normal human stomach. *Br J Anaesth* 81:669-675, 1998.
142. Kongable GL, Lanzino G, Germanson TP, Truskowski LL, Alves WM, Torner JC, Kassell NF: Gender-related differences in aneurysmal subarachnoid hemorrhage. *J Neurosurg* 84:43-48, 1996.
143. Kosnik EJ, Hunt WE: Postoperative hypertension in the management of patients with intracranial arterial aneurysms. *J Neurosurg* 45:148-154, 1976.
144. Kremer C, Groden C, Hansen HC, Grzyska U, Zeumer H: Outcome after endovascular treatment of Hunt and Hess grade IV or V aneurysms: comparison of anterior versus posterior circulation. *Stroke* 30:2617-2622, 1999.
145. Kuether TA, Nesbit GM, Barnwell SL: Clinical and angiographic outcomes, with treatment data, for patients with cerebral aneurysms treated with Guglielmi detachable coils: a single-center experience. *Neurosurgery* 43:1016-1025, 1998.
146. Laloux P: SPECT Imaging in Transient Ischaemic Attacks and Subarachnoid Haemorrhage, in De Deyn P, Dierckx R, Alavi A, Pickut B (eds): *A Textbook of: SPECT in Neurology and Psychiatry*. London, John Libbey & Company Ltd, 1997, pp 323-334.
147. Lam JM, Smielewski P, Czosnyka M, Pickard JD, Kirkpatrick PJ: Predicting delayed ischemic deficits after aneurysmal subarachnoid hemorrhage using a transient hyperemic response test of cerebral autoregulation. *Neurosurgery* 47:819-826, 2000.
148. Lanzino G, Wakhloo AK, Fessler RD, Hartney ML, Guterman LR, Hopkins LN: Efficacy and current limitations of intravascular stents for intracranial internal carotid, vertebral, and basilar artery aneurysms. *J Neurosurg* 91:538-546, 1999.
149. Le Roux PD, Elliott JP, Downey L, Newell DW, Grady MS, Mayberg MR, Eskridge JM, Winn HR: Improved outcome after rupture of anterior circulation

- aneurysms: a retrospective 10-year review of 224 good-grade patients. *J Neurosurg* 83:394-402, 1995.
150. Le Roux PD, Elliott JP, Newell DW, Grady MS, Winn HR: Predicting outcome in poor-grade patients with subarachnoid hemorrhage: a retrospective review of 159 aggressively managed cases. *J Neurosurg* 85:39-49, 1996.
 151. Le Roux PD, Newell DW, Eskridge J, Mayberg MR, Winn HR: Severe symptomatic vasospasm: the role of immediate postoperative angioplasty. *J Neurosurg* 80:224-229, 1994.
 152. Le Roux PD, Winn HR: Intracranial aneurysms and subarachnoid hemorrhage management of the poor grade patient. *Acta Neurochir Suppl* 72:7-26, 1999.
 153. Leber KA, Klein GE, Trummer M, Eder HG: Intracranial aneurysms: a review of endovascular and surgical treatment in 248 patients. *Minim Invasive Neurosurg* 41:81-85, 1998.
 154. Lebuffe G, Robin E, Vallet B: Gastric tonometry. *Intensive Care Med* 27:317-319, 2001.
 155. Lebuffe G, Robin E, Vallet B: Gastric tonometry, in Vincent JI (ed) 2001 Yearbook of Intensive Care and emergency Medicine. Berlin Heidelberg New York, Springer Verlag, 2001, pp 245-250.
 156. Lefkowitz MA, Gobin YP, Akiba Y, Duckwiler GR, Murayama Y, Guglielmi G, Martin NA, Vinuela F: Ballonn-assisted Guglielmi detachable coiling of wide-necked aneurysma: Part II--clinical results. *Neurosurgery* 45:531-538, 1999.
 157. Lempert TE, Malek AM, Halbach VV, Phatouros CC, Meyers PM, Dowd CF, Higashida RT: Endovascular treatment of ruptured posterior circulation cerebral aneurysms. Clinical and angiographic outcomes. *Stroke* 31:100-110, 2000.
 158. Lennihan L, Mayer SA, Fink ME, Beckford A, Paik MC, Zhang H, Wu YC, Klebanoff LM, Raps EC, Solomon RA: Effect of hypervolemic therapy on cerebral blood flow after subarachnoid hemorrhage : a randomized controlled trial. *Stroke* 31:383-391, 2000.
 159. Lewis DH, Eskridge JM, Newell DW, Grady MS, Cohen WA, Dalley RW, Loyd D, Grothaus King A, Young P, Winn HR: Brain SPECT and the effect of cerebral angioplasty in delayed ischemia due to vasospasm. *J Nucl Med* 33:1789-1796, 1992.
 160. Lin T, Fox AJ, Drake CG: Regrowth of aneurysm sacs from residual neck following aneurysm clipping. *J Neurosurg* 70:556-560, 1989.
 161. Linn FH, Rinkel GJ, Algra A, van Gijn J: Incidence of subarachnoid hemorrhage: role of region, year, and rate of computed tomography: a meta-analysis. *Stroke* 27:625-629, 1996.

162. Ljunggren B, Sonesson B, Säveland H, Brandt L: Cognitive impairment and adjustment in patients without neurological deficits after aneurysmal SAH and early operation. *J Neurosurg* 62:673-679, 1985.
163. Locksley HB: Natural history of subarachnoid hemorrhage, intracranial aneurysms and arteriovenous malformations. *J Neurosurg* 25:321-368, 1966.
164. Longstreth WT, Nelson LM, Koepsell TD, van Belle G: Subarachnoid hemorrhage and hormonal factors in women. A population-based case-control study. *Ann Intern Med* 121:168-173, 1994.
165. Lot G, Houdart E, Cophignon J, Casasco A, George B: Combined management of intracranial aneurysms by surgical and endovascular treatment. Modalities and results from a series of 395 cases. *Acta Neurochir (Wien)* 141:557-562, 1999.
166. Malek AM, Halbach VV, Phatouros CC, Lempert TE, Meyers PM, Dowd CF, Higashida RT: Balloon-assist technique for endovascular coil embolization of geometrically difficult intracranial aneurysms. *Neurosurgery* 46:1397-1407, 2000.
167. Malisch TW, Guglielmi G, Vinuela F, Duckwiler G, Gobin YP, Martin NA, Frazee JG: Intracranial aneurysms treated with the Guglielmi detachable coil: midterm clinical results in a consecutive series of 100 patients. *J Neurosurg* 87:176-183, 1997.
168. Maroon JC, Nelson PB: Hypovolemia in patients with subarachnoid hemorrhage: therapeutic implications. *Neurosurgery* 4:223-226, 1979.
169. Masdeu JC, Brass LM, Holman BL, Kushner MJ: Brain single-photon emission computed tomography. *Neurology* 44:1970-1977, 1994.
170. Mawad ME, Cekirge S, Ciceri E, Saatci I: Endovascular treatment of giant and large intracranial aneurysms by using a combination of stent placement and liquid polymer injection. *J Neurosurg* 96:474-482, 2002.
171. Mayberg MR: Intracranial Arterial Spasm, in Wilkins RH, Rengachary SS (eds): *Neurosurgery*. St. Louis, McGraw-Hill, 1996, pp 2245-2254.
172. Mayberg MR, Batjer HH, Dacey R, Diringer M, Haley EC, Heros RC, Sternau LL, Torner J, Adams HP, Jr., Feinberg W, et al.: Guidelines for the management of aneurysmal subarachnoid hemorrhage. A statement for healthcare professionals from a special writing group of the Stroke Council, American Heart Association. *Stroke* 25:2315-2328, 1994.
173. McDougall CG, Halbach VV, Dowd CF, Higashida RT, Larsen DW, Hieshima GB: Causes and management of aneurysmal hemorrhage occurring during embolization with Guglielmi detachable coils. *J Neurosurg* 89:87-92, 1998.

174. McKenna P, Willison JR, Phil B, Lowe D, Neil-Dwyer G: Cognitive outcome and quality of life one year after subarachnoid haemorrhage. *Neurosurgery* 24:361-367, 1989.
175. McKissock W, Paine PWE, Walsh LS: An analysis of the results of treatment of ruptured intracranial aneurysms. Report of 772 consecutive cases. *Journal of Neurosurgery* 17:762-776, 1960.
176. Menovsky T, van Rooij WJ, Sluzewski M, Wijnalda D: Coiling of Ruptured Pericallosal Artery Aneurysms. *Neurosurgery* 50:11-15, 2002.
177. Mericle RA, Lanzino G, Wakhloo AK, Guterman LR, Hopkins LN: Stenting and secondary coiling of intracranial internal carotid artery aneurysm: technical case report. *Neurosurgery* 43:1229-1234, 1998.
178. Meyer CH, Lowe D, Meyer M, Richardson PL, Neil-Dwyer G: Progressive change in cerebral blood flow during the first three weeks after subarachnoid hemorrhage. *Neurosurgery* 12:58-76, 1983.
179. Molyneux A, Kerr R: International Subarachnoid Aneurysm Trial. *J Neurosurg* 91:352-353, 1999.
180. Moret J, Cognard C, Weill A, Castaings L, Rey A: The "Remodelling technique" in the treatment of wide neck intracranial aneurysms. Angiographic results and clinical follow-up in 56 cases. *Interventional Neuroradiology* 3:21-35, 1997.
181. Moret J, Pierot L, Boulin A, Castaings L, Rey A: Endovascular treatment of anterior communicating artery aneurysms using Guglielmi detachable coils. *Neuroradiology* 38:800-805, 1996.
182. Murayama Y, Malisch T, Guglielmi G, Mawad ME, Vinuela F, Duckwiler GR, Gobin YP, Klucznick RP, Martin NA, Frazee J: Incidence of cerebral vasospasm after endovascular treatment of acutely ruptured aneurysms: report on 69 cases. *J Neurosurg* 87:830-835, 1997.
183. Murayama Y, Vinuela F, Suzuki Y, Do HM, Massoud TF, Guglielmi G, Ji C, Iwaki M, Kusakabe M, Kamio M, et al.: Ion implantation and protein coating of detachable coils for endovascular treatment of cerebral aneurysms: concepts and preliminary results in swine models. *Neurosurgery* 40:1233-1243, 1997.
184. Murayama Y, Vinuela F, Tateshima S, Song JK, Gonzalez NR, Wallace MP: Bioabsorbable polymeric material coils for embolization of intracranial aneurysms: a preliminary experimental study. *J Neurosurg* 94:454-463, 2001.
185. Murayama Y, Vinuela F, Tateshima S, Vinuela F, Jr., Akiba Y: Endovascular treatment of experimental aneurysms by use of a combination of liquid embolic agents and protective devices. *AJNR Am J Neuroradiol* 21:1726-1735, 2000.

186. Nelson RJ, Roberts J, Rubin C, Walker V, Ackery DM, Pickard JD: Association of hypovolemia after subarachnoid hemorrhage with computed tomographic scan evidence of raised intracranial pressure. *Neurosurgery* 29:178-182, 1991.
187. Ng P, Khangure MS, Phatouros CC, Bynevelt M, ApSimon H, McAuliffe W: Endovascular treatment of intracranial aneurysms with Guglielmi detachable coils: analysis of midterm angiographic and clinical outcomes. *Stroke* 33:210-217, 2002.
188. Nilsson OG, Brandt L, Ungerstedt U, Säveland H: Bedside detection of brain ischemia using intracerebral microdialysis: subarachnoid hemorrhage and delayed ischemic deterioration. *Neurosurgery* 45:1176-1185, 1999.
189. Niskanen MM, Hernesniemi JA, Vapalahti MP, Kari A: One-year outcome in early aneurysm surgery: prediction of outcome. *Acta Neurochir Wien* 123:25-32, 1993.
190. Noguchi K, Ogawa T, Inugami A, Toyoshima H, Sugawara S, Hatazawa J, Fujita H, Shimosegawa E, Kanno I, Okudera T, et al.: Acute subarachnoid hemorrhage: MR imaging with fluid-attenuated inversion recovery pulse sequences. *Radiology* 196:773-777, 1995.
191. Norman G, Steiner D: *Biostatistics The bare essentials*. St. Louis, 1994.
192. Ogawa T, Inugami A, Fujita H, Hatazawa J, Shimosegawa E, Noguchi K, Okudera T, Kanno I, Uemura K, Suzuki A, et al.: MR diagnosis of subacute and chronic subarachnoid hemorrhage: comparison with CT. *AJR Am J Roentgenol* 165:1257-1262, 1995.
193. Ogden JA, Mee EW, Henning M: A prospective study of impairment of cognition and memory and recovery after subarachnoid hemorrhage. *Neurosurgery* 33:572-586, 1993.
194. Ogden JA, Utley T, Mee EW: Neurological and psychosocial outcome 4 to 7 years after subarachnoid hemorrhage. *Neurosurgery* 41:25-34, 1997.
195. Öhman J, Heiskanen O: Timing of operation for ruptured supratentorial aneurysms: a prospective randomized study. *J Neurosurg* 70:55-60, 1989.
196. Öhman J, Servo A, Heiskanen O: Effect of intrathecal fibrinolytic therapy on clot lysis and vasospasm in patients with aneurysmal subarachnoid hemorrhage. *J Neurosurg* 75:197-201, 1991.
197. Origitano TC, Wascher TM, Reichman OH, Anderson DE: Sustained increased cerebral blood flow with prophylactic hypertensive hypervolemic hemodilution ("triple-H" therapy) after subarachnoid hemorrhage. *Neurosurgery* 27:729-740, 1990.
198. Osawa M, Hongo K, Tanaka Y, Nakamura Y, Kitazawa K, Kobayashi S: Results of direct surgery for aneurysmal subarachnoid haemorrhage: outcome of 2055

- patients who underwent direct aneurysm surgery and profile of ruptured intracranial aneurysms. *Acta Neurochir (Wien)* 143:655-664, 2001.
199. Pakarinen S: Incidence, aetiology, and prognosis of primary subarachnoid haemorrhage. A study based on 589 cases diagnosed in a defined urban population during a defined period. *Acta Neurol Scand* 29:1-28, 1967.
 200. Pargger H, Hampf KF, Christen P, Staender S, Scheidegger D: Gastric intramucosal pH-guided therapy in patients after elective repair of infrarenal abdominal aneurysms: is it beneficial? *Intensive Care Med* 24:769-776, 1998.
 201. Parviainen I: Gastric tonometry in the assessment of splanchnic perfusion: Methodological aspects and evaluation of simultaneous regional blood flow measurements and gastric tonometry after coronary artery bypass grafting. Kuopio, Kuopio University Publications D. Medical Sciences, 1997, vol 123.
 202. Payner TD, Tew JM: Aneurysm Clips, in Wilkins RH, Rengachary SS (eds): *Neurosurgery*. St. Louis, McGraw-Hill, 1996, pp 2271-2276.
 203. Peerless SJ, Hernesniemi JA, Gutman FB, Drake CG: Early surgery for ruptured vertebrobasilar aneurysms. *J Neurosurg* 80:643-649, 1994.
 204. Polin RS, Coenen VA, Hansen CA, Shin P, Baskaya MK, Nanda A, Kassell NF: Efficacy of transluminal angioplasty for the management of symptomatic cerebral vasospasm following aneurysmal subarachnoid hemorrhage. *J Neurosurg* 92:284-290, 2000.
 205. Polin RS, Hansen CA, German P, Chaddock JB, Kassell NF: Intra-arterially administered papaverine for the treatment of symptomatic cerebral vasospasm. *Neurosurgery* 42:1256-1267, 1998.
 206. Powers WJ, Grubb RL, Jr., Baker RP, Mintun MA, Raichle ME: Regional cerebral blood flow and metabolism in reversible ischemia due to vasospasm. Determination by positron emission tomography. *J Neurosurg* 62:539-546, 1985.
 207. Powsner RA, LA OT, Jabre A, Melhem ER: SPECT imaging in cerebral vasospasm following subarachnoid hemorrhage. *J Nucl Med* 39:765-769, 1998.
 208. Qureshi AI, Luft AR, Sharma M, Guterman LR, Hopkins LN: Prevention and treatment of thromboembolic and ischemic complications associated with endovascular procedures: Part II--Clinical aspects and recommendations. *Neurosurgery* 46:1360-1376, 2000.
 209. Qureshi AI, Luft AR, Sharma M, Guterman LR, Hopkins LN: Prevention and treatment of thromboembolic and ischemic complications associated with endovascular procedures: Part I--Pathophysiological and pharmacological features. *Neurosurgery* 46:1344-1359, 2000.

210. Raftopoulos C, Mathurin P, Boscherini D, Billa RF, Van Boven M, Hantson P: Prospective analysis of aneurysm treatment in a series of 103 consecutive patients when endovascular embolization is considered the first option. *J Neurosurg* 93:175-182, 2000.
211. Rajendran JG, Lewis DH, Newell DW, Winn HR: Brain SPECT used to evaluate vasospasm after subarachnoid hemorrhage: correlation with angiography and transcranial Doppler. *Clin Nucl Med* 26:125-130, 2001.
212. Rankin J: Cerebral vascular accidents in patients over age 60. II. Prognosis. *Scott Med J* 2:200-215, 1957.
213. Ratsep T, Asser T: Cerebral hemodynamic impairment after aneurysmal subarachnoid hemorrhage as evaluated using transcranial doppler ultrasonography: relationship to delayed cerebral ischemia and clinical outcome. *J Neurosurg* 95:393-401, 2001.
214. Raymond J, Guilbert F, Roy D: Neck-bridge device for endovascular treatment of wide-neck bifurcation aneurysms: initial experience. *Radiology* 221:318-326, 2001.
215. Raymond J, Leblanc P, Desfaits AC, Salazkin I, Morel F, Janicki C, Roorda S: In situ beta radiation to prevent recanalization after coil embolization of cerebral aneurysms. *Stroke* 33:421-427, 2002.
216. Raymond J, Roy D: Safety and efficacy of endovascular treatment of acutely ruptured aneurysms. *Neurosurgery* 41:1235-1246, 1997.
217. Raymond J, Roy D, Bojanowski M, Moumdjian R, G LE: Endovascular treatment of acutely ruptured and unruptured aneurysms of the basilar bifurcation. *J Neurosurg* 86:211-219, 1997.
218. Report of World Federation of Neurological Surgeons Committee on a Universal Subarachnoid Hemorrhage Grading Scale. *J Neurosurg* 68:985-986, 1988.
219. Reul J, Weis J, Spetzger U, Konert T, Fricke C, Thron A: Long-term angiographic and histopathologic findings in experimental aneurysms of the carotid bifurcation embolized with platinum and tungsten coils. *AJNR Am J Neuroradiol* 18:35-42, 1997.
220. Richling B, Bavinzski G, Gross A, Gruber A, Killer M: Early Clinical Outcome of Patients with Ruptured Cerebral Aneurysms Treated by Endovascular (GDC) or Microsurgical Techniques. A Single Center Experience. *Interventional Neuroradiology* 1:19-27, 1995.
221. Ricolfi F, Le Guerinel C, Blustajn J, Combes C, Brugieres P, Melon E, Gaston A: Rupture during treatment of recently ruptured aneurysms with Guglielmi electrodetachable coils. *AJNR Am J Neuroradiol* 19:1653-1658, 1998.

222. Riddington D, Venkatesh B, Clutton-Brock T, Bion J, Venkatesh KB: Measuring carbon dioxide tension in saline and alternative solutions: quantification of bias and precision in two blood gas analyzers. *Crit Care Med* 22:96-100, 1994.
223. Rinkel GJ, Wijndicks EF, Vermeulen M, Ramos LM, Tanghe HL, Hasan D, Meiners LC, van Gijn J: Nonaneurysmal perimesencephalic subarachnoid hemorrhage: CT and MR patterns that differ from aneurysmal rupture. *AJNR Am J Neuroradiol* 12:829-834, 1991.
224. Rinne J, Hernesniemi J, Niskanen M, Vapalahti M: Management outcome for multiple intracranial aneurysms. *Neurosurgery* 36:31-37, 1995.
225. Rinne J, Hernesniemi J, Puranen M, Saari T: Multiple intracranial aneurysms in a defined population: prospective angiographic and clinical study. *Neurosurgery* 35:803-808, 1994.
226. Romner B, Sonesson B, Ljunggren B, Brandt L, Säveland H, Holtas S: Late magnetic resonance imaging related to neurobehavioral functioning after aneurysmal subarachnoid hemorrhage. *Neurosurgery* 25:390-396, 1989.
227. Romodanov AP, Shcegllov VI: Intravascular occlusion of saccular aneurysms of the cerebral arteries by means of a detachable balloon catheter, in Krayenbuhl H, Sweet WH (eds): *Advances and Technical Standards in Neurosurgery*. New-York, Springer-Verlag, 1982, pp 25-49.
228. Ronkainen A, Hernesniemi J: Subarachnoid haemorrhage of unknown aetiology. *Acta Neurochir (Wien)* 119:29-34, 1992.
229. Ronkainen A, Hernesniemi J, Ryyanen M: Familial subarachnoid hemorrhage in east Finland, 1977-1990. *Neurosurgery* 33:787-797, 1993.
230. Ronkainen A, Miettinen H, Karkola K, Papinaho S, Vanninen R, Puranen M, Hernesniemi J: Risk of harboring an unruptured intracranial aneurysm. *Stroke* 29:359-362, 1998.
231. Rordorf G, Koroshetz WJ, Copen WA, Gonzalez G, Yamada K, Schaefer PW, Schwamm LH, Ogilvy CS, Sorensen AG: Diffusion- and perfusion-weighted imaging in vasospasm after subarachnoid hemorrhage. *Stroke* 30:599-605, 1999.
232. Rosen JM, Butala AV, Oropello JM, Sacher M, Rudolph SH, Goldsmith SJ, Holan V, Stritzke P: Postoperative changes on brain SPECT imaging after aneurysmal subarachnoid hemorrhage. A potential pitfall in the evaluation of vasospasm. *Clin Nucl Med* 19:595-597, 1994.
233. Roski RA, Spetzler RF: Carotid Ligation, in Wilkins RH, Rengachary SS (eds): *Neurosurgery*. St. Louis, McGraw-Hill, 1996, pp 2333-2340.

234. Roy D, Raymond J, Bouthillier A, Bojanowski MW, Moumdjian R, L'Esperance G: Endovascular treatment of ophthalmic segment aneurysms with Guglielmi detachable coils. *AJNR Am J Neuroradiol* 18:1207-1215, 1997.
235. Sarti C, Tuomilehto J, Salomaa V, Sivenius J, Kaarsalo E, Narva EV, Salmi K, Torppa J: Epidemiology of subarachnoid hemorrhage in Finland from 1983 to 1985. *Stroke* 22:848-853, 1991.
236. Säveland H, Hillman J, Brandt L, Edner G, Jakobsson KE, Algers G: Overall outcome in aneurysmal subarachnoid hemorrhage. A prospective study from neurosurgical units in Sweden during a 1-year period. *J Neurosurg* 76:729-734, 1992.
237. Schievink WI: Intracranial aneurysms. *N Engl J Med* 336:28-40, 1997.
238. Seiler RW, Reulen HJ, Huber P, Grolimund P, Ebeling U, Steiger HJ: Outcome of aneurysmal subarachnoid hemorrhage in a hospital population: a prospective study including early operation, intravenous nimodipine, and transcranial Doppler ultrasound. *Neurosurgery* 23:598-604, 1988.
239. Serbinenko FA: Balloon catheterization and occlusion of major cerebral vessels. *J Neurosurg* 41:125-145, 1974.
240. Sethi H, Moore A, Dervin J, Clifton A, MacSweeney JE: Hydrocephalus: comparison of clipping and embolization in aneurysm treatment. *J Neurosurg* 92:991-994, 2000.
241. Silva E, DeBacker D, Creteur J, Vincent JL: Effects of vasoactive drugs on gastric intramucosal pH. *Crit Care Med* 26:1749-1758, 1998.
242. Sindou M, Acevedo JC, Turjman F: Aneurysmal remnants after microsurgical clipping: classification and results from a prospective angiographic study (in a consecutive series of 305 operated intracranial aneurysms). *Acta Neurochir (Wien)* 140:1153-1159, 1998.
243. Sluzewski M, Bosch JA, van Rooij WJ, Nussen PC, Wijnalda D: Rupture of intracranial aneurysms during treatment with Guglielmi detachable coils: incidence, outcome, and risk factors. *J Neurosurg* 94:238-240, 2001.
244. Solenski NJ, Haley EC, Jr., Kassell NF, Kongable G, Germanson T, Truskowski L, Torner JC: Medical complications of aneurysmal subarachnoid hemorrhage: a report of the multicenter, cooperative aneurysm study. Participants of the Multicenter Cooperative Aneurysm Study. *Crit Care Med* 23:1007-1017, 1995.
245. Soucy JP, McNamara D, Mohr G, Lamoureux F, Lamoureux J, Danais S: Evaluation of vasospasm secondary to subarachnoid hemorrhage with technetium-99m-hexamethyl-propyleneamine oxime (HM-PAO) tomoscintigraphy. *J Nucl Med* 31:972-977, 1990.

246. Steinberg GK, Drake CG, Peerless SJ: Deliberate basilar or vertebral artery occlusion in the treatment of intracranial aneurysms. Immediate results and long-term outcome in 201 patients. *J Neurosurg* 79:161-173, 1993.
247. Sturaitis MK, Rinne J, Chaloupka JC, Kaynar M, Lin Z, Awad IA: Impact of Guglielmi detachable coils on outcomes of patients with intracranial aneurysms treated by a multidisciplinary team at a single institution. *J Neurosurg* 93:569-580, 2000.
248. Svensson E, Starmark JE, Ekholm S, von Essen C, Johansson A: Analysis of interobserver disagreement in the assessment of subarachnoid blood and acute hydrocephalus on CT scans. *Neurol Res* 18:487-494, 1996.
249. Takala J, Parviainen I, Siloaho M, Ruokonen E, Hamalainen E: Saline PCO₂ is an important source of error in the assessment of gastric intramucosal pH. *Crit Care Med* 22:1877-1879, 1994.
250. Taneda M: Effect of early operation for ruptured aneurysms on prevention of delayed ischemic symptoms. *J Neurosurg* 57:622-628, 1982.
251. Tanoue S, Kiyosue H, Kenai H, Nakamura T, Yamashita M, Mori H: Three-dimensional reconstructed images after rotational angiography in the evaluation of intracranial aneurysms: surgical correlation. *Neurosurgery* 47:866-871, 2000.
252. Tapaninaho A, Hernesniemi J, Vapalahti M, Niskanen M, Kari A, Luukkonen M, Puranen M: Shunt-dependent hydrocephalus after subarachnoid haemorrhage and aneurysm surgery: timing of surgery is not a risk factor. *Acta Neurochir (Wien)* 123:118-124, 1993.
253. Teasdale G, Jennett B: Assessment and prognosis of coma after head injury. *Acta Neurochir (Wien)* 34:45-55, 1976.
254. Teunissen LL, Rinkel GJ, Algra A, van Gijn J: Risk factors for subarachnoid hemorrhage: a systematic review. *Stroke* 27:544-549, 1996.
255. Thielen KR, Nichols DA, Fulgham JR, Piepgras DG: Endovascular treatment of cerebral aneurysms following incomplete clipping. *J Neurosurg* 87:184-189, 1997.
256. Thornton J, Bashir Q, Aletich VA, Debrun GM, Ausman JI, Charbel FT: What percentage of surgically clipped intracranial aneurysms have residual necks? *Neurosurgery* 46:1294-1300, 2000.
257. Thornton J, Debrun GM, Aletich VA, Bashir Q, Charbel FT, Ausman J: Follow-up Angiography of Intracranial Aneurysms Treated with Endovascular Placement of Guglielmi Detachable Coils. *Neurosurgery* 50:239-250, 2002.
258. Thornton J, Dovey Z, Alazzaz A, Misra M, Aletich VA, Debrun GM, Ausman JI, Charbel FT: Surgery following endovascular coiling of intracranial aneurysms. *Surg Neurol* 54:352-360, 2000.

259. Tranquart F, Ades PE, Groussin P, Rieant JF, Jan M, Baulieu JL: Postoperative assessment of cerebral blood flow in subarachnoid haemorrhage by means of ^{99m}Tc-HMPAO tomography. *Eur J Nucl Med* 20:53-58, 1993.
260. Treggiari-Venzi MM, Suter PM, Romand JA: Review of medical prevention of vasospasm after aneurysmal subarachnoid hemorrhage: a problem of neurointensive care. *Neurosurgery* 48:249-262, 2001.
261. Troupp H, af Bjorkesten G: Results of a controlled trial of late surgical versus conservative treatment of intracranial arterial aneurysms. *J Neurosurg* 35:20-24., 1971.
262. Tsutsumi K, Ueki K, Morita A, Usui M, Kirino T: Risk of aneurysm recurrence in patients with clipped cerebral aneurysms: results of long-term follow-up angiography. *Stroke* 32:1191-1194, 2001.
263. Tsutsumi K, Ueki K, Usui M, Kwak S, Kirino T: Risk of recurrent subarachnoid hemorrhage after complete obliteration of cerebral aneurysms. *Stroke* 29:2511-2513, 1998.
264. Tu RK, Cohen WA, Maravilla KR, Bush WH, Patel NH, Eskridge J, Winn HR: Digital subtraction rotational angiography for aneurysms of the intracranial anterior circulation: injection method and optimization. *AJNR Am J Neuroradiol* 17:1127-1136, 1996.
265. Tummala RP, Chu RM, Madison MT, Myers M, Tubman D, Nussbaum ES: Outcomes after Aneurysm Rupture during Endovascular Coil Embolization. *Neurosurgery* 49:1059-1067, 2001.
266. Ukkola V, Heikkinen ER: Epilepsy after operative treatment of ruptured cerebral aneurysms. *Acta Neurochir Wien* 106:115-118, 1990.
267. van der Jagt M, Hasan D, Bijvoet HW, Pieterman H, Dippel DW, Vermeij FH, Avezaat CJ: Validity of prediction of the site of ruptured intracranial aneurysms with CT. *Neurology* 52:34-39, 1999.
268. van Gijn J, Bromberg JE, Lindsay KW, Hasan D, Vermeulen M: Definition of initial grading, specific events, and overall outcome in patients with aneurysmal subarachnoid hemorrhage. A survey. *Stroke* 25:1623-1627, 1994.
269. van Gijn J, Rinkel GJ: Subarachnoid haemorrhage: diagnosis, causes and management. *Brain* 124:249-278, 2001.
270. Van Laere K, Dumont F, Koole M, Dierckx R: Non-invasive methods for absolute cerebral blood flow measurement using ^{99m}Tc-ECD: a study in healthy volunteers. *Eur J Nucl Med* 28:862-872, 2001.

271. van Loon J, Waerzeggers Y, Wilms G, Van Calenbergh F, Goffin J, Plets C: Early endovascular treatment of ruptured cerebral aneurysms in patients in very poor neurological condition. *Neurosurgery* 50:457-465, 2002.
272. Vapalahti M, Ljunggren B, Säveland H, Hernesniemi J, Brandt L, Tapaninaho A: Early aneurysm operation and outcome in two remote Scandinavian populations. *J Neurosurg* 60:1160-1162, 1984.
273. Wardlaw JM, Offin R, Teasdale GM, Teasdale EM: Is routine transcranial Doppler ultrasound monitoring useful in the management of subarachnoid hemorrhage? *J Neurosurg* 88:272-276, 1998.
274. Weir B: The pathophysiology of cerebral vasospasm. *Br J Neurosurg* 9:375-390, 1995.
275. Weir B: Unruptured intracranial aneurysms: a review. *J Neurosurg* 96:3-42, 2002.
276. Weir B, Grace M, Hansen J, Rothberg C: Time course of vasospasm in man. *J Neurosurg* 48:173-178, 1978.
277. Weir B, MacDonald L: Cerebral vasospasm. *Clin Neurosurg* 40:40-55, 1993.
278. Weir B, Macdonald L: Intracranial aneurysms and subarachnoid hemorrhage: an overview, in Wilkins RH, Rengachary SS (eds): *Neurosurgery*. St. Louis, McGraw-Hill, 1996, pp 2191-2213.
279. Venkatesh B, Townsend S, Boots RJ: Does splanchnic ischemia occur in isolated neurotrauma? A prospective observational study. *Crit Care Med* 27:1175-1180, 1999.
280. Vermeulen M, Hasan D, Blijenberg BG, Hijdra A, van Gijn J: Xanthochromia after subarachnoid haemorrhage needs no revisitation. *J Neurol Neurosurg Psychiatry* 52:826-828, 1989.
281. Whisnant JP, Sacco SE, O'Fallon WM, Fode NC, Sundt TM, Jr.: Referral bias in aneurysmal subarachnoid hemorrhage. *J Neurosurg* 78:726-732, 1993.
282. Wiebers D: Unruptured intracranial aneurysms--risk of rupture and risks of surgical intervention. International Study of Unruptured Intracranial Aneurysms Investigators. *N Engl J Med* 339:1725-1733, 1998.
283. Vilkki J, Holst P, Öhman J, Servo A, Heiskanen O: Cognitive deficits related to computed tomographic findings after surgery for a ruptured intracranial aneurysm. *Neurosurgery* 25:166-172, 1989.
284. Winn HR, Richardson AE, Jane JA: The long-term prognosis in untreated cerebral aneurysms: I. The incidence of late hemorrhage in cerebral aneurysm: a 10-year evaluation of 364 patients. *Ann Neurol* 1:358-370, 1977.

285. Vinuela F, Duckwiler G, Mawad M: Guglielmi detachable coil embolization of acute intracranial aneurysm: perioperative anatomical and clinical outcome in 403 patients. *J Neurosurg* 86:475-482, 1997.
286. Voldby B, Enevoldsen EM, Jensen FT: Regional CBF, intraventricular pressure, and cerebral metabolism in patients with ruptured intracranial aneurysms. *J Neurosurg* 62:48-58, 1985.
287. Vora YY, Suarez-Almazor M, Steinke DE, Martin ML, Findlay JM: Role of transcranial Doppler monitoring in the diagnosis of cerebral vasospasm after subarachnoid hemorrhage. *Neurosurgery* 44:1237-1248, 1999.
288. Yamakami I, Isobe K, Yamaura A, Nakamura T, Makino H: Vasospasm and regional cerebral blood flow (rCBF) in patients with ruptured intracranial aneurysm: serial rCBF studies with the xenon-133 inhalation method. *Neurosurgery* 13:394-401, 1983.
289. Yasargil MG: *Microsurgical anatomy of the basal cisterns and vessels of the brain, diagnostic studies, general operative techniques and pathological considerations of the intracranial aneurysms*. New York, Georg Thieme Verlag Stuttgart - New York, 1984, vol 1.
290. Yasargil MG: *Clinical considerations, surgery of the intracranial aneurysms and results*. New York, Georg Thieme Verlag Stuttgart - New York, 1984, vol 2.
291. Yasargil MG: *A legacy of microneurosurgery: memoirs, lessons, and axioms*. *Neurosurgery* 45:1025-1092, 1999.
292. Yonas H, Pindzola RP, Johnson DW: Xenon/computed tomography cerebral blood flow and its use in clinical management. *Neurosurg Clin N Am* 7:605-616, 1996.
293. Yoshimoto Y, Tanaka Y, Hoya K: Acute systemic inflammatory response syndrome in subarachnoid hemorrhage. *Stroke* 32:1989-1993, 2001.
294. Yundt KD, Grubb RL, Jr., Diringner MN, Powers WJ: Autoregulatory vasodilation of parenchymal vessels is impaired during cerebral vasospasm. *J Cereb Blood Flow Metab* 18:419-424, 1998.
295. Zouaoui A, Sahel M, Marro B, Clemenceau S, Dargent N, Bitar A, Faillot T, Capelle L, Marsault C: Three-dimensional computed tomographic angiography in detection of cerebral aneurysms in acute subarachnoid hemorrhage. *Neurosurgery* 41:125-130, 1997.
296. Zubkov YN, Nikiforov BM, Shustin VA: Balloon catheter technique for dilatation of constricted cerebral arteries after aneurysmal SAH. *Acta Neurochir Wien* 70:65-79, 1984.

ORIGINAL PUBLICATIONS I-IV

Reprinted with permission

I

II

III

IV