

Technical Note

Usefulness of repetitive intraoperative indocyanine green-based videoangiography to confirm complete obliteration of micro-arteriovenous malformations

Soichi Oya, Takahide Nejo, Naoaki Fujisawa, Tsukasa Tsuchiya, Masahiro Indo, Takumi Nakamura, Toru Matsui

Department of Neurosurgery, Saitama Medical Center, Saitama Medical University, 1981 Kamoda, Kawagoe, Saitama 350-8550, Japan

E-mail: *Soichi Oya - sooya-tky@umin.ac.jp; Takahide Nejo - nejoooo@gmail.com; Naoaki Fujisawa - naoaki@saitama-med.ac.jp; Tsuchiya Tsukasa - tsukasa-t@nifty.com; Masahiro Indo - clea_danes@yahoo.co.jp; Takumi Nakamura - tnakamur@saitama-med.ac.jp; Toru Matsui - matsui@saitama-med.ac.jp

*Corresponding Author

Received: 05 December 14 Accepted: 04 March 15 Published: 21 May 15

This article may be cited as:

Oya S, Nejo T, Fujisawa N, Tsuchiya T, Indo M, Nakamura T, et al. Usefulness of repetitive intraoperative indocyanine green-based videoangiography to confirm complete obliteration of micro-arteriovenous malformations. *Surg Neurol Int* 2015;6:85.

Available FREE in open access from: <http://www.surgicalneurologyint.com/text.asp?2015/6/1/85/157445>

Copyright: © 2015 Oya S. This is an open-access article distributed under the terms of the Creative Commons Attribution License, which permits unrestricted use, distribution, and reproduction in any medium, provided the original author and source are credited.

Abstract

Background: It is difficult to intraoperatively confirm the total disappearance of arteriovenous (AV) shunts during surgery for microarteriovenous malformations (micro-AVMs), especially when the nidus is extremely small or diffuse on preoperative angiography. Although intraoperative angiography is effective for evaluating residual shunts, procedure-related risks raise important concerns. The purpose of this study was to assess the usefulness of intraoperative indocyanine green-based videoangiography (ICG-VA) to determine complete disappearance of micro-AVMs during surgery.

Methods: We retrospectively analyzed eight patients with ruptured micro-AVMs who were treated using craniotomy with ICG-VA at our institution.

Results: Two patients underwent emergency partial evacuation of hematoma and external decompression before the diagnostic angiography. While three patients had a nidus smaller than 1 cm, five patients had only early draining veins without an appreciable nidus. The draining veins were superficial in six cases and deep in two cases. The average interval from onset to surgery was 33 days (range, 2–57). ICG-VA was repetitively conducted until disappearance of the AV shunt was confirmed. No residual AV shunt was observed on postoperative radiological examinations. In all cases, the diagnosis of AVM was confirmed from the results of postoperative pathological examination.

Conclusions: ICG-VA could detect early draining veins more clearly *in situ* than diagnostic angiography. Although it is not as effective for visualizing lesions with deep draining veins, repetitive ICG-VA was safe and effective for confirming the disappearance of AV shunts with superficial drainage.

Key Words: Arteriovenous malformation, hematoma, indocyanine green-based videoangiography, microarteriovenous malformation

Video Available on :
www.surgicalneurologyint.com

Access this article
online

Website:

www.surgicalneurologyint.com

DOI:

10.4103/2152-7806.157445

Quick Response Code:



INTRODUCTION

Since Margolis emphasized small cerebrovascular malformations as an important cause of intracerebral hemorrhage (ICH),^[35,36] such small vascular lesions as a cause of cerebral hemorrhage have been the focus of much debate. Small vascular malformations that are not appreciable on angiography have been referred to as “cryptic”^[7] or “occult.”^[5,18,30] Yaşagil differentiated cerebral microarteriovenous malformations (micro-AVMs) from such angiographically occult arteriovenous malformations (AVMs) and defined them as AVMs with a nidus of 1 cm or smaller.^[54] However, the clinical characteristics, namely, (i) significant neurological deficits despite the small lesion size, (ii) frequent incidence in young and previously healthy individuals, and (iii) difficulty in diagnosis,^[1,2,6,36,44,51] and treatment strategies for angiographically occult AVMs and micro-AVMs are rather similar. With regard to diagnosis, visualization of these small lesions partly depends on the quality of imaging,^[51] and the lesions may be transiently invisible under the influence of temporary local conditions around hematomas, such as compression or thrombosis.^[11,33,51] These problems can lead to difficulties in intraoperative confirmation of arteriovenous (AV) shunt obliteration. Although intraoperative angiography has been recommended for AVM resection in general,^[4,16,20,32,34] to our knowledge, its usefulness for micro-AVMs has not been discussed in the literature. Indocyanine green-based videoangiography (ICG–VA) has been recently used widely as a safe and simple method to intraoperatively evaluate vascular flow *in situ*,^[3,19,31] and its use in AVM surgery has been reported.^[14,15,21,25,28,38,40,45,46,55] We have been using intraoperative ICG–VA to identify the early filling vein in the case of micro-AVMs. Our experience led us to believe that ICG–VA will be particularly useful during micro-AVM surgery. In the present study, we present our observations on the use of ICG–VA to confirm AV shunt obliteration during micro-AVM surgery.

METHODS

Patients, diagnosis, and treatment strategies

This study was approved by the Saitama Medical Center Institutional Review Board (No. 954). Between January 2011 and April 2014, 19 patients with AVM were treated at the Saitama Medical Center: There were 2 cases of unruptured AVM and 17 of ruptured AVM. In the present study, micro-AVM was angiographically defined as an AVM with a nidus smaller than 1 cm or as an early draining vein without an angiographically appreciable nidus.^[1,42] An early draining vein was characterized as a vein identified in the capillary phase or earlier that have connections to larger veins in the drainage route. Micro-AVMs were

detected in 10 of the 19 cases mentioned above, and all 10 patients showed hemorrhagic onset. The nidus or feeders were located in the deep white matter, close to the lateral ventricle in two patients, who were treated with stereotactic radiation; therefore, they could not be included in the study. In the present series, no patient with micro-AVM underwent endovascular embolization. The intracerebral hematoma volume was calculated from computed tomographic (CT) scan slices using the formula $a \times b \times c/2$.

Our policy regarding the treatment of ICH in young patients or atypically located hypertensive ICH is to investigate the pathology of the hemorrhage using angiography as well as 3D-CT angiography and magnetic resonance (MR) imaging. When the patients' condition is critical because of the mass effect of the hematoma, emergency partial evacuation of the hematoma and external decompression are conducted before the angiography. Because a small nidus may not be visible even on angiograms recorded in the acute phase of hemorrhage, we carefully examined digital subtraction angiography images, especially for cases of lobar hemorrhage in young patients with no history of hypertension. If the result of the initial angiography performed immediately after onset is negative, angiography is repeated 4–6 weeks after hematoma onset. To delineate the early draining vein clearly on angiography, we obtain images with a short serial duration (12 shots per second) and a double dose of contrast medium. Patients diagnosed with micro-AVMs were scheduled for craniotomy and resection of superficial micro-AVMs.

Surgical technique and intraoperative ICG–VA

The patient's head was fixed in a 3-pin Mayfield headholder. The Stealth Navigation system (Medtronic, Surgical Navigation Technologies, Louisville, CO) was set up to confirm the location of the small nidus in the operative field. After standard craniotomy was performed to create ample space for surgery, ICG–VA was routinely conducted, and early draining veins were visualized. To compare early draining veins and normally irrigating veins, it was important to adequately expose the cortex. ICG dye diluted to 2.5 mg/mL was injected intravenously as a bolus (0.1 mg/kg of ICG dye, followed by 20 mL of saline). Vessels were visualized using surgical microscopes integrated with a video camera (OPMI PENTERO with INFRARED 800 microscope [Carl Zeiss, Oberkochen, Germany] or M720 OH5 [Leica Microsystems, Heerbrugg, Switzerland]). ICG–VA was performed to confirm the disappearance of the early draining vein when complete shunt obliteration was suspected. If the targeted early draining vein was still visualized on angiography, exploration of the small nidus remaining on the hematoma walls was continued. The ICG–VA was repeated until all the veins around the hematoma could be visualized in the normal venous phase. Postoperative

angiography or MR imaging was performed 1–2 weeks after the surgery to confirm total obliteration of AV shunts.

RESULTS

The patient characteristics and outcomes are summarized in [Table 1]. The mean age of the eight patients finally examined was 30.8 years (range, 6–79). The average interval from onset to surgery was 33 days (range, 2–57). The presentations of hemorrhage were ICH in five cases, ICH with intraventricular hemorrhage in two cases, and ICH with subarachnoid hemorrhage, and subdural hemorrhage in one case. The average volume of ICH was 23.4 mL (range, 5.4–59.2). Emergency partial evacuation of hematoma and external decompression before angiography were required in two of the eight cases since these two patients were in a deep coma because of the mass effect of the hematoma and urgently required hematoma evacuation. Per our policy regarding urgent surgery for life-threatening ICH accompanied by a high index of suspicion of AVM, the extent to which the hematoma was evacuated was adequate to reduce the intracranial pressure, and aggressive inspection of the hematoma cavity was avoided. In these two cases, angiography was conducted the day after the urgent partial hematoma evacuation, and definitive treatment for AVMs was administered 1 and 2 months after the first surgery. Only early draining veins without angiographically appreciable nidi were observed in five cases, while nidi of size <1 cm were identified in three cases. The draining veins were superficial in six cases and deep in two cases. No case showed two or more drainers on angiography. The location of the nidus was the frontal lobe in three patients and the parietal, temporal, occipital, temporoparietal lobes, and the cerebellum in one patient each. Intraoperatively, early draining veins could be identified in the initial ICG–VA, and changes in the timing of visualization (e.g. in the capillary or arterial phase) for all six cases of superficial drainers were repeatedly monitored. However, ICG–VA was not useful

for evaluating deep drainers in the brain parenchyma. The pathological diagnosis made from the specimens obtained during surgery was compatible with AVM in all cases.

Six patients showed complete recovery (modified Rankin Scale [mRS] 0), while two experienced moderate neurological deficits rated as mRS 2 and 3). The deficits were attributed to initial damage due to the hemorrhage and were not considered surgical complication. The average duration of follow-up was 5.2 months (range, 1.2–15.5). The disappearance of the AV shunt was postoperatively confirmed on angiography in seven cases and on MR images in one case.

Illustrative case

A 43-year-old male with no past medical history woke up one day with a severe headache, nausea, and subjective visual disturbance. On admission, neurological examination showed slight disturbance of consciousness and homonymous hemianopia on the left side. An emergency CT scan showed a 5.3 × 2.2 × 3.8 cm-sized ICH in the right parietal lobe [Figure 1a]. The patient underwent emergency angiography, which showed no definitive vascular abnormality [Figure 1b]. Time-of-flight MR angiography, however, showed a small but abnormally dilated vein near the hematoma [Figure 1c]. The angiography was therefore repeated in 2 weeks, and it clearly showed an early draining vein near the hematoma [Figure 1d]. On the basis of this finding, the hematoma was evacuated and the micro-AVM was explored. The patient was placed in the prone position, and right occipital craniotomy was performed. After the dura was opened, the first ICG–VA was conducted, and the early draining vein was detected in the cerebral cortex [Figure 2a and b]. ICG–VA in the late venous phase showed the hematoma cavity as a dark area [Figure 2c]. A small corticotomy was performed on the surface of this area to access the hematoma with minimal additional injury to the cortex. During hematoma removal, the surface of the brain parenchyma was meticulously examined under high magnification by rubbing the cavity

Table 1: Patient characteristics and outcome

Patient	Age (year), Sex	Location	Hematoma volume (ml)	Interval from the Onset to Resection of Micro-AVM (days)	Admission GCS	Spetzler & Martin Grade	Size of the Nidus	Drainer	Discharge mRS
1	7, M	Temporoparietal	52.8	57	6	2	EDV	Superficial	0
2	10, M	Temporal	8.1	5	14	1	EDV	Deep	0
3	6, M	Parietal	10.3	39	9	2	EDV	Superficial	0
4	43, M	Occipital	22.2	41	14	1	EDV	Superficial	0
5	79, F	Cerebellar	17.9	29	7	1	<1cm	Superficial	3
6	21, M	Frontal	59.2	39	9	2	<1cm	Superficial	2
7	38, M	Frontal	5.4	2	9	2	<1cm	Deep	0
8	42, M	Frontal	9.8	53	13	1	EDV	Superficial	0

EDV: Early draining vein; GCS: Glasgow Coma Scale; mRS: Modified Rankin Scale

wall with bipolar forceps, a suction tube, and cotton patties, with copious irrigation. Small tangled abnormal vessels were found on the hematoma wall and resected. When the inspection was largely considered complete, ICG-VA was repeated. In this second examination, the timing of early draining vein observation changed from the arterial phase to the normal venous phase [Figure 2d and e]. However, another vein near the hematoma that had not been recognized as abnormal was clearly identified as an early draining vein, indicating that AV shunts remained in the vicinity (see Supplemental Video, which demonstrates how the delineation of early draining veins varies as the obliteration of AV shunt proceeds, 1 min 37 s). The exploration was therefore

continued, and tiny, tangled thread-like vessels were found buried behind this vein. A final ICG-VA confirmed the complete disappearance of the early draining vein in the cortex [Figure 2f]. Postoperative angiography showed no residual nidus [Figure 2g]. The pathological diagnosis of abnormal vessels was AVM. The patient showed good recovery with no new neurological deficits and was discharged home.

DISCUSSION

In the present study, we examined the usefulness and limitations of ICG-VA during surgical treatment for micro-AVMs. We highlighted some diagnostic and operative tips specific for micro-AVMs and not large AVMs. Our technique using ICG-VA seem especially useful for intraoperative confirmation of complete AV shunt obliteration.

Problems related to the preoperative diagnosis of micro-AVMs and the importance of in situ evaluation of early venous drainage using ICG-VA

Despite their small size, micro-AVM can cause large hematomas, leading to serious neurological impairments.^[1,2,6,44,51] In our series as well, the average hematoma volume was high enough to cause significant symptoms. Surgical resection is critical to treat ruptured micro-AVMs.^[44] Many investigators have emphasized that the diagnosis of micro-AVMs requires a high index of suspicion;^[1,2,6,18,44] yet, various conditions inherent to acute-stage hematomas opacify the AV shunt on imaging, whereby this indicator can be missed.^[1,2,22,41] Increased local pressure may cause collapse of the nidus. Further, the partial thrombosis that occurred during hemostasis or posthemorrhagic vasospasm may also lead to obscuration of micro-AVMs. Therefore, a

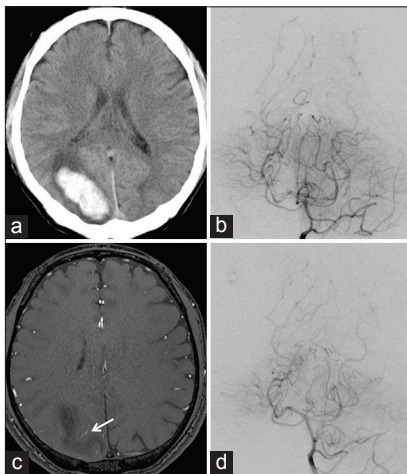


Figure 1: (a) CT scan at admission showing an intracerebral hemorrhage in the right parietal lobe. (b) A left internal carotid angiogram on admission showing no definitive vascular abnormality. (c) A time-of-flight MR image showing a small but abnormally dilated vein (arrow) near the hematoma. (d) A left internal carotid angiogram repeated in 2 weeks clearly showing the early draining vein (arrowhead) near the hematoma

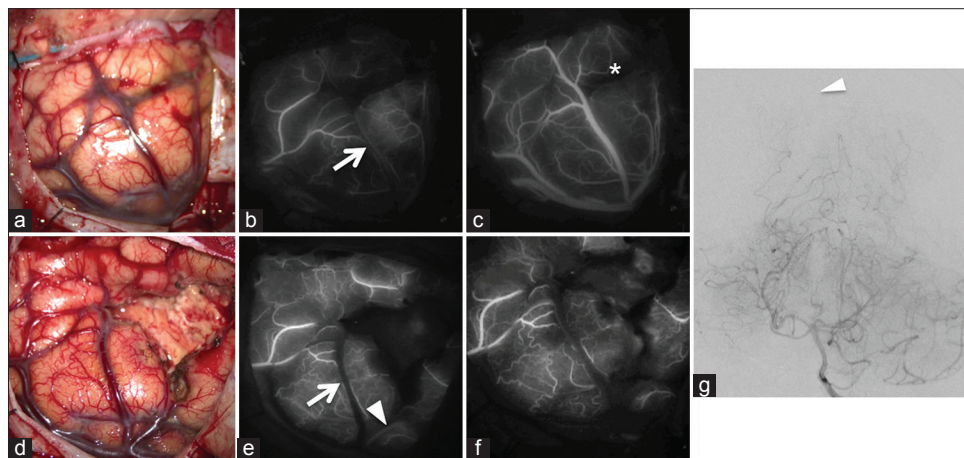


Figure 2: (a) A photograph showing cortical arteries and veins around the hematoma. (b) Initial ICG-VA showing an early draining vein (arrow) (c) ICG-VA in the late venous phase showing the hematoma cavity as a dark area (*). (d) A photograph showing that the evacuation was almost complete. (e) Second ICG-VA showing the disappearance of the early draining vein (arrowhead). However, another early draining vein (arrowhead) is visible near the hematoma cavity. (f) Final ICG-VA confirming the complete disappearance of all drainers. (g) Postoperative angiogram showing no residual nidus (arrowhead)

second angiography is important for seemingly common subcortical hemorrhage in order to identify occult vascular malformations undetected in the initial angiography.^[22,33,42] Superselective angiography has also been reported to be useful in the detection of micro-AVMs that cannot be discerned on conventional angiography.^[1,2,6,42,52] With recent innovations in imaging modalities, time-of-flight MR angiography^[1,53] or cone-beam CT angiography^[43] has also been reported to have equivalent or even better detection rates of micro-AVMs than conventional angiography. These preoperative radiological examinations and ICG-VA have not been compared previously. However, from our experience, *in situ* observation using ICG-VA is more sensitive than these imaging modalities to distinguish subtle differences between a normal vein and an early draining vein. This might be partly because of the lowering of local pressure after the dura is opened or increased shunt flow after evacuating the hematoma that results in better visualization. Elhammady *et al.* recommended elective surgical exploration to prevent re-bleeding in relatively young and healthy patients with unexplained ICH in accessible locations.^[11] We believe that intraoperative ICG-VA should be considered for these explorative surgeries because it might be able to better delineate superficial draining veins.

Effectiveness of ICG-VA in confirming total obliteration of AV shunts for micro-AVMs or diffuse AVMs

Localization of the nidus and drainer is of paramount importance in micro-AVM surgery in order to ensure complete AV shunt obliteration,^[6,44] and intraoperative navigation systems are helpful for identifying these lesions.^[1] However, considerable brain shift may occur after hematoma evacuation, which would reduce the accuracy of navigation. In addition, the nidus in micro-AVMs or diffuse AVMs is often diffusely distributed in the brain parenchyma, making it difficult for surgeons to be certain that all abnormal vessels have been eliminated. In such cases, normalization of the early draining vein is usually utilized as an important index of total obliteration. We believe that intraoperative ICG-VA is the most sensitive and precise technique available for detecting early draining vein normalization. However, the effectiveness of ICG-VA specifically for micro-AVMs has not been discussed enough even in a recent large series of AVM treated using ICG-VA.^[55]

In most cases of compact AVMs with a medium-to-large nidus, surgeons are usually able to find the lesion easily and ensure complete obliteration of AV shunts by visual confirmation of changes in the color of the drainer. This empirical judgment can be rationally reinforced by intraoperative angiography, which may also help improve the obliteration rate.^[4,19,34] With regard to micro-AVMs, however, the intraoperative visualization of AV shunts can be difficult because of the small size of these lesions. This

also makes it difficult to confirm complete obliteration of the targeted AV shunt.

To our knowledge, the clinical significance of intraoperative angiography for micro-AVMs has not been discussed previously, but given the preoperative difficulties in lesion delineation, its effectiveness would probably be limited. Identification of residual AV shunt after surgical resection is critical because partial resection of AVMs may increase the risk of hemorrhage.^[23,24,26,37] In the present study, we achieved complete obliteration of micro-AVMs in all eight cases without the formation of new neurological deficits, and this outcome seems to support the efficacy and safety of intraoperative ICG-VA.

Takagi *et al.* described the case of a 2-year-old patient with a diffuse AVM.^[45] In their experience, repetitive ICG-VA was effective to ensure complete removal of residual nidus. Our results are in agreement with theirs, and we consider ICG-VA to be useful for diffuse AVMs as well as for micro-AVMs. Diffuse AVMs are more common in children than in adults, accounting for 18–25% of all pediatric AVMs.^[12,27,32] Further, this high frequency of diffuse AVMs underlies the high recurrence rate of pediatric AVMs.^[27,32] We speculate that this is partly related to the difficulty in intraoperatively confirming the complete obliteration of AV shunts in diffuse AVMs. We previously treated a 6-year-old girl with frontoparietal lobar hemorrhage, when ICG-VA was not available [Figure 3a]. Angiography failed to reveal any abnormal vessels [Figure 3b]. The hematoma was evacuated, but no apparent abnormal vessels were found during surgery. The patient underwent a second

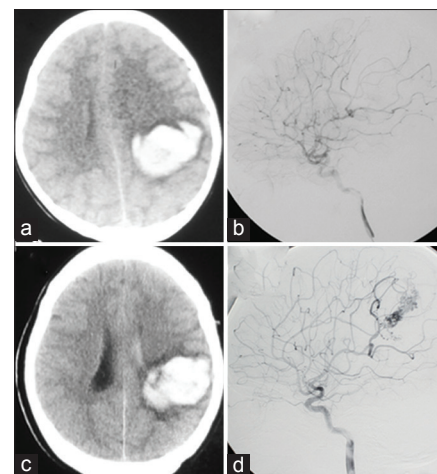


Figure 3: (a) CT scan at admission showing an intracerebral hematoma in the left frontoparietal region. (b) A left internal carotid angiogram at admission showing no abnormal findings that could explain the hemorrhage. (c) A CT scan captured 8 years after the initial episode showing hematoma recurrence at the same location as that when the patient first presented with disturbed consciousness. (d) A left internal carotid angiogram showing a diffuse AVM

angiography 1 month after surgery, and again, no lesion was found. Eight years after the initial attack, she had recurrent hemorrhage in the same location [Figure 3c], and angiography at this time finally showed a diffuse AVM [Figure 3d]. After a thorough discussion of treatment options, she and her parents selected stereotactic radiosurgery. Complete obliteration of AV shunt was confirmed 2 years after radiosurgery. We believe that ICG–VA might be helpful in cases like this one, but its effectiveness to prevent recurrent AVM from micro-AVM and diffuse AVM that are frequently seen among young and pediatric populations should be carefully verified by additional studies with long-term follow-up.

If the early draining vein had been detected on ICG–VA *in situ* during the evacuation surgery, we could have followed the vein and rigorously searched for hidden AV shunts. Zaidi *et al.* recently reported that the significance of intraoperative ICG–VA alone did not improve the identification of residual nidus and clinical outcome based on the data of 56 patients with AVM treated using ICG.^[55] However, their study cohort consisted of mostly patients with larger AVMs, not micro-AVMs. In our experience, ICG–VA provides superior visual intelligence to differentiate an arterialized vein from a normal vein, and this may contribute to the discovery of indistinct AV shunts. We also recommend that ICG–VA be repetitively performed until all the veins around the hematoma appear normalized, as described in the illustrative case in this paper. Although the safety and usefulness of intraoperative angiography in AVM resection has been established,^[4,8,9,17,29,39,49] the reported procedure-related complication rate is slightly high in pediatric cases (3.3%^[13] and 4.8%^[16]). From this aspect as well, pediatric cases or surgeries conducted with the patient in the prone position would benefit greatly from ICG–VA.

Limitations of ICG–VA

There are some limitations regarding the use of ICG–VA. Deep-seated lesions are not visualized on ICG–VA.^[15,55] In fact, we were unable to identify the early draining veins on ICG–VA in two cases because they were buried in the brain parenchyma. If the lesion has only a deep draining vein, the role of ICG–VA for confirming the disappearance of AV shunt would be minimal. Another limitation is that ICG–VA would find limited use if urgent surgery is required. Some patients with ruptured AVMs certainly require life-saving urgent surgeries before diagnostic angiography. It is recommended that if a vascular abnormality is suspected, the hematoma wall should be explored for ICH to reduce the risk of rebleeding.^[10,47,48,50] However, we think that this approach is advocated after the possibilities of other high-risk hemorrhagic lesions are excluded by preoperative imaging studies. Nonspecific exploration without any information on the lesion may

lead to bleeding and further injuries to the surrounding brain. Intraoperative ICG–VA may compensate for the limitations of preoperative angiography, but it provides little data on the overall angioarchitecture of vascular lesions. In our opinion, AVM resection during urgent operation should not be attempted based on ICG–VA findings alone, and angiography is essential. This should especially be avoided when the bleeding occurs in eloquent areas. Rebleeding rarely occurs between the initial hematoma evacuation and the subsequent curative resection of micro-AVM.^[1] In our series, two patients (25%) required urgent hematoma evacuation and subsequently underwent curative surgery on days 29 and 57 after onset, without suffering from re-bleeding. We agree with Elhammady *et al.*,^[10] who recommended explorative surgery be planned 2–4 weeks after onset, if the patients' condition allows it, when the hematoma is semi-liquefied and can be easily evacuated without inducing further bleeding.

CONCLUSIONS

ICG–VA is a powerful tool for *in situ* localization of AV shunts of micro-AVMs with superficial drainage. It is also extremely useful for confirming complete obliteration of AV shunts for such micro-AVMs. We believe that repetitive ICG–VA contributes to reducing the chances of residual AV shunts, especially micro-AVMs.

REFERENCES

- Alén JF, Lagares A, Paredes I, Campollo J, Navia P, Ramos A, *et al.* Cerebral microarteriovenous malformations: A series of 28 cases. *J Neurosurg* 2013;119:594-602.
- Andreou A, Ioannidis I, Laloo S, Nickolaos N, Byrne JV. Endovascular treatment of intracranial microarteriovenous malformations. *J Neurosurg* 2008;109:1091-7.
- Balamurugan S, Agrawal A, Kato Y, Sano H. Intra operative indocyanine green video-angiography in cerebrovascular surgery: An overview with review of literature. *Asian J Neurosurg* 2011;6:88-93.
- Barrow DL, Boyer KL, Joseph GJ. Intraoperative angiography in the management of neurovascular disorders. *Neurosurgery* 1992;30:153-9.
- Becker DH, Townsend JJ, Kramer RA, Newton TH. Occult cerebrovascular malformations. A series of 18 histologically verified cases with negative angiography. *Brain* 1979;102:249-87.
- Cellerini M, Mangiafico S, Villa G, Nistri M, Pandolfo C, Noubari H, *et al.* Cerebral microarteriovenous malformations: Diagnostic and therapeutic features in a series of patients. *AJNR Am J Neuroradiol* 2002;23:945-52.
- Crawford JV, Russell DS. Cryptic arteriovenous and venous hamartomas of the brain. *J Neurol Neurosurg Psychiatr* 1956;19:1-11.
- Dehdashti AR, Thines L, Da C, Leodante B, terBrugge KG, Willinsky RA, *et al.* Intraoperative biplanar rotational angiography during neurovascular surgery. Technical note. *J Neurosurg* 2009;111:188-92.
- Derdeyn CP, Moran CJ, Cross DT, Grubb RL, Dacey RG. Intraoperative digital subtraction angiography: A review of 112 consecutive examinations. *AJNR Am J Neuroradiol* 1995;16:307-18.
- Elhammady MS, Heros RC. Microarteriovenous malformations. *J Neurosurg* 2013;119:591-3.
- Elhammady MS, Baskaya MK, Heros RC. Early elective surgical exploration of spontaneous intracerebral hematomas of unknown origin. *J Neurosurg* 2008;109:1005-11.

12. Ellis MJ, Armstrong D, Vachhrajani S, Kulkarni AV, Dirks PB, Drake JM, et al. Angioarchitectural features associated with hemorrhagic presentation in pediatric cerebral arteriovenous malformations. *J Neurointerv Surg* 2012;5:191-5.
13. Ellis MJ, Kulkarni AV, Drake JM, Rutka JT, Armstrong D, Dirks PB. Intraoperative angiography during microsurgical removal of arteriovenous malformations in children. *J Neurosurg Pediatr* 2010;6:435-43.
14. Faber F, Thon N, Fesl G, Rachinger W, Guckler R, Tonn JC, et al. Enhanced analysis of intracerebral arteriovenous malformations by the intraoperative use of analytical indocyanine green videoangiography: Technical note. *Acta Neurochir* 2011;153:2181-7.
15. Ferroli P, Acerbi F, Broggi M, Broggi G. Arteriovenous micromalformation of the trigeminal root: Intraoperative diagnosis with indocyanine green videoangiography: Case report. *Neurosurgery* 2010;67:onsE309-10.
16. Gaballah M, Storm PB, Rabinowitz D, Ichord RN, Hurst RV, Krishnamurthy G, et al. Intraoperative cerebral angiography in arteriovenous malformation resection in children: A single institutional experience. *J Neurosurg Pediatr* 2014;13:222-8.
17. Ghosh S, Levy ML, Stanley P, Nelson M, Giannotta SL, McComb JG. Intraoperative angiography in the management of pediatric vascular disorders. *Pediatr Neurosurg* 1999;30:16-22.
18. Golden JB, Kramer RA. The angiographically occult cerebrovascular malformation. Report of three cases. *J Neurosurg* 1978;48:292-6.
19. Goren O, Monteith SJ, Hadani M, Bakon M, Harnof S. Modern intraoperative imaging modalities for the vascular neurosurgeon treating intracerebral hemorrhage. *Neurosurg Focus* 2013;34:E2.
20. Grossart KW, Turner JW. Operative angiography in cerebral vascular surgery. *Br J Radiol* 1973;46:401-2.
21. Häggi D, Ertman N, Steiger HJ. The impact of microscope-integrated intraoperative near-infrared indocyanine green videoangiography on surgery of arteriovenous malformations and dural arteriovenous fistulae. *Neurosurgery* 2010;67:1094-103.
22. Hino A, Fujimoto M, Yamaki T, Iwamoto Y, Katsumori T. Value of repeat angiography in patients with spontaneous subcortical hemorrhage. *Stroke* 1998;29:2517-21.
23. Hoh BL, Carter BS, Ogilvy CS. Incidence of residual intracranial AVMs after surgical resection and efficacy of immediate surgical re-exploration. *Acta Neurochir (Wien)* 2004;146:1-7.
24. Kader A, Young WL, Pile-Spellman J, Mast H, Sciacca RR, Mohr JP, et al. The influence of hemodynamic and anatomic factors on hemorrhage from cerebral arteriovenous malformations. *Neurosurgery* 1994;34:801-7.
25. Killory BD, Nakaji P, Gonzales LF, Ponce FA, Wait SD, Spetzler RF. Prospective evaluation of surgical microscope-integrated intraoperative near-infrared indocyanine green angiography during cerebral arteriovenous malformation surgery. *Neurosurgery* 2009;65:456-62.
26. Kiriş T, Sencer A, Sahinbaş M, Sencer S, Imer M, Izgi N. Surgical results in pediatric Spetzler-Martin grades I-III intracranial arteriovenous malformations. *Childs Nerv Syst* 2005;21:69-74.
27. Klimo P, Rao G, Brockmeyer D. Pediatric arteriovenous malformations: A 15-year experience with an emphasis on residual and recurrent lesions. *Childs Nerv Syst* 2007;23:31-7.
28. Kono K, Uka A, Mori M, Haga S, Hamada Y, Nagata S. Intra-arterial injection of indocyanine green in cerebral arteriovenous malformation surgery. *Turk Neurosurg* 2013;23:676-9.
29. Kotowski M, Sarrafzadeh A, Schatlo B, Boex C, Narata AP, Pereira VM, et al. Intraoperative angiography reloaded: A new hybrid operating theater for combined endovascular and surgical treatment of cerebral arteriovenous malformations: A pilot study on 25 patients. *Acta Neurochir* 2013;155:2071-8.
30. Kramer RA, Wing SD. Computed tomography of angiographically occult cerebral vascular malformations. *Radiology* 1977;123:649-52.
31. Lane BC, Cohen-Gadol AA. A prospective study of microscope-integrated intraoperative fluorescein videoangiography during arteriovenous malformation surgery: Preliminary results. *Neurosurg Focus* 2014;36:E15.
32. Lang SS, Beslow LA, Bailey RL, Vossough A, Ekstrom J, Heuer GG, et al. Follow-up imaging to detect recurrence of surgically treated pediatric arteriovenous malformations. *J Neurosurg Pediatr* 2012;9:497-504.
33. Lobato RD, Perez C, Rivas JJ, Cordobes F. Clinical, radiological, and pathological spectrum of angiographically occult intracranial vascular malformations. Analysis of 21 cases and review of the literature. *J Neurosurg* 1988;68:518-31.
34. Loop JW, Foltz EL. Applications of angiography during intracranial operation. *Acta Radiol Diagn (Stockh)* 1966;5:363-7.
35. Margolis G, Odom GL, Woodhall B. Further experiences with small vascular malformations as a cause of massive intracerebral bleeding. *J Neuropathol Exp Neurol* 1961;20:161-7.
36. Margolis G, Odom GL, Woodhall B, Bloor BM. The role of small angiomatous malformations in the production of intracerebral hematomas. *J Neurosurg* 1951;8:564-75.
37. Miyamoto S, Hashimoto N, Nagata I, Nozaki K, Morimoto M, Taki W, et al. Posttreatment sequelae of palliatively treated cerebral arteriovenous malformations. *Neurosurgery* 2000;46:589-94.
38. Moon HS, Joo SP, Seo BR, Jang JW, Kim JH, Kim TS. Value of indocyanine green videoangiography in deciding the completeness of cerebrovascular surgery. *J Korean Neurosurg Soc* 2013;53:349-55.
39. Munshi I, Macdonald RL, Weir BK. Intraoperative angiography of brain arteriovenous malformations. *Neurosurgery* 1999;45:491-7.
40. Ng YP, King NK, Wan KR, Wang E, Ng I. Uses and limitations of indocyanine green videoangiography for flow analysis in arteriovenous malformation surgery. *J Clin Neurosci* 2013;20:224-32.
41. Ogilvy CS, Heros RC, Ojemann RG, New PF. Angiographically occult arteriovenous malformations. *J Neurosurg* 1988;69:350-5.
42. Perrini P, Scollato A, Cellerini M, Mangiàfico S, Ammannati F, Mennonna P, et al. Results of surgical and endovascular treatment of intracranial micro-arteriovenous malformations with emphasis on superselective angiography. *Acta Neurochir (Wien)* 2004;146:755-66.
43. Rahal JP, Malek AM. Benefit of cone-beam computed tomography angiography in acute management of angiographically undetectable ruptured arteriovenous malformations. *J Neurosurg* 2013;119:1015-20.
44. Stiver SI, Ogilvy CS. Micro-arteriovenous malformations: Significant hemorrhage from small arteriovenous shunts. *Neurosurgery* 2000;46:811-8.
45. Takagi Y, Kikuta K, Nozaki K, Sawamura K, Hashimoto N. Detection of a residual nidus by surgical microscope-integrated intraoperative near-infrared indocyanine green videoangiography in a child with a cerebral arteriovenous malformation. *J Neurosurg* 2007;107:416-8.
46. Takagi Y, Sawamura K, Hashimoto N, Miyamoto S. Evaluation of serial intraoperative surgical microscope-integrated intraoperative near-infrared indocyanine green videoangiography in patients with cerebral arteriovenous malformations. *Neurosurgery* 2012;70:34-42.
47. Tanaka Y, Furuse M, Iwasa H, Masuzawa T, Saito K, Sato F, et al. Lobar intracerebral hemorrhage: Etiology and a long-term follow-up study of 32 patients. *Stroke* 1986;17:51-7.
48. Tung H, Giannotta SL, Chandrasoma PT, Zee CS. Recurrent intraparenchymal hemorrhages from angiographically occult vascular malformations. *J Neurosurg* 1990;73:174-80.
49. Vitaz TW, Gaskill-Shiple M, Tomsick T, Tew JM. Utility, safety, and accuracy of intraoperative angiography in the surgical treatment of aneurysms and arteriovenous malformations. *AJNR Am J Neuroradiol* 1999;20:1457-61.
50. Wakai S, Ueda Y, Inoh S, Nagai M. Angiographically occult angiomas: A report of thirteen cases with analysis of the cases documented in the literature. *Neurosurgery* 1985;17:549-56.
51. Willinsky R, Lasjaunias P, Comoy J, Pruvost P. Cerebral micro arteriovenous malformations (mAVMs). Review of 13 cases. *Acta Neurochir (Wien)* 1988;91:37-41.
52. Willinsky R, Terbrugge K, Montanera W, Wallace C, Aggarwal S. Micro-arteriovenous malformations of the brain: Superselective angiography in diagnosis and treatment. *AJNR Am J Neuroradiol* 1992;13:325-30.
53. Wong GK, Siu DY, Ahuja AT, King AD, Yu SC, Zhu XL, et al. Comparisons of DSA and MR angiography with digital subtraction angiography in 151 patients with subacute spontaneous intracerebral hemorrhage. *J Clin Neurosci* 2010;17:601-5.
54. Yaşagil MG. *Microneurosurgery. Volume IIIA. AVM of the Brain, History, Embryology, Pathological Considerations, Hemodynamics, Diagnostic Studies, Microsurgical Anatomy.* New York: Thieme; 1987.
55. Zaidi HA, Abl AA, Nakaji P, Chowdhry SA, Albuquerque FC, Spetzler RF. Indocyanine green angiography in the surgical management of cerebral arteriovenous malformations: Lessons learned in 130 consecutive cases. *Neurosurgery* 2014;10 Suppl 2:246-51.