

Case Report

Primary intramedullary neurocytoma: Case report and literature analysis

Nicola Montano, Rina Di Bonaventura, Antonella Coli¹, Eduardo Fernandez, Mario Meglio²Department of Neurosurgery, Institute of Neurosurgery, Catholic University, ¹Department of Pathology, Institute of Pathology, Catholic University, Rome, ²Department of Neurosurgery, Institute of Neurosurgery, University of Verona, Verona, Italy

E-mail: *Nicola Montano - nicolamontanomd@yahoo.it; Rina Di Bonaventura - rina.di.bonaventura@hotmail.it; Antonella Coli - antonella.coli@rm.unicatt.it; Eduardo Fernandez - e.fernandez@rm.unicatt.it; Mario Meglio - mario.meglio@univr.it

*Corresponding author

Received: 28 July 15 Accepted: 10 August 15 Published: 25 November 15

Abstract

Background: Primary intramedullary neurocytoma is extremely rare. Due to its rarity, it is difficult to collect a wide series in a single institution to perform a survival analysis and give indications about prognosis and treatment.

Case Description: Here, we report on a case of a 37-year-old woman with primary intramedullary neurocytoma and perform a systematic statistical analysis of cases reported in the literature. Of 21 articles found, 15 studies and the present case (22 patients) were eligible for the analysis. We studied the impact of age, sex, number of involved levels (≤ 2 vs. >2), entity of resection, postoperative radiotherapy (RT), proliferation index (Ki67) on the neurological outcome of patients, and on the recurrence of the tumor. Comparison of categorical variables was performed by the χ^2 statistic. The Kaplan–Meier curves were plotted to calculate the progression-free survival (PFS) of these patients. $P < 0.05$ was considered as statistically significant. The 1-year PFS was 95.45% and the 2-year PFS was 86.36%. A gross total resection was associated to a worsening of the neurological function with no impact on the tumor recurrence. Adjuvant RT significantly improved the neurological function. A lower Ki67 was strongly associated with a lower tumor recurrence.

Conclusions: We think that the goal of the surgery should be to preserve a good neurological function even if a residual tumor has to be left. Ki67 should be always evaluated due to its impact on the prognosis. Although adjuvant RT significantly improved the neurological function, its role in preventing the tumor recurrence is not clearly defined.

Key Words: Adjuvant radiotherapy, intramedullary neurocytoma, Ki67, progression-free survival, surgery

Access this article online**Website:**www.surgicalneurologyint.com**DOI:**

10.4103/2152-7806.170477

Quick Response Code:**INTRODUCTION**

Primary intramedullary neurocytoma, first described by Coca *et al.*,^[3] is extremely rare. It has been hypothesized that intramedullary neurocytoma can originate from the primitive neuroectodermal cells surrounding the central canal region in fetal life. Due to the rarity of this pathology, only a few cases have been reported in the literature.^[1-3,5,9-19] Moreover, it is difficult to collect

This is an open access article distributed under the terms of the Creative Commons Attribution-NonCommercial-ShareAlike 3.0 License, which allows others to remix, tweak, and build upon the work non-commercially, as long as the author is credited and the new creations are licensed under the identical terms.

For reprints contact: reprints@medknow.com

How to cite this article: Montano N, Di Bonaventura R, Coli A, Fernandez E, Meglio M. Primary intramedullary neurocytoma: Case report and literature analysis. *Surg Neurol Int* 2015;6:178.
<http://surgicalneurologyint.com/Primary-intramedullary-neurocytoma:-Case-report-and-literature-analysis/>

a wide series in a single institution in order to perform a survival analysis and give indications about prognosis and treatment. Thus, the aim of this study was to report a case of primary intramedullary neurocytoma and to perform a systematic statistical analysis of cases reported in the literature in order to identify potentially prognostic factors on neurological outcome and recurrence risk.

CASE REPORT

A 37-year-old woman was admitted because of a 9 months history of diffuse axial and low back pain. The neurological examination showed a hypesthesia in the left lower limb and bilateral hyperactive deep tendon reflexes. Spinal magnetic resonance imaging (MRI) with gadolinium showed an intramedullary lesion at T8–T9 level, with solid and cystic components, hypo- and hyper-intense on T2-weighted images and with dishomogeneous contrast enhancement after gadolinium administration associated to the cranial syrinx [Figure 1]. Under neurophysiological intraoperative monitoring, the patient was submitted to T8–T9 laminotomy and total lesion removal. On histology, the lesion was composed of round to the oval cells with finely dispersed chromatin and small nucleoli; ganglion cell differentiation was commonly present among the neurocytic cells. Hyalinized vessels were also observed [Figure 2a]. “Atypical” histological features (mitotic activity, microvascular proliferation, and necrosis) were not present. Immunohistochemically, the neoplastic cells were positive for synaptophysin [Figure 2b]. The MIB-1 labeling index was 1%. The histological diagnosis of extraventricular neurocytoma with ganglion cell differentiation was made.

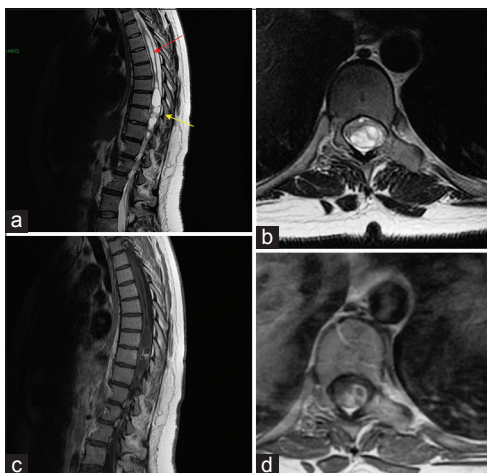


Figure 1: Spinal magnetic resonance imaging. (a) T2-weighted sagittal sequences showing the intramedullary lesion at T8–T9 level (yellow arrow), with solid (hypointense) and cystic (hyperintense) components. The cranial syrinx is evident (red arrow). (b) T2-weighted axial sequences demonstrating that the tumor is mainly located on the left spinal cord. (c) T1-weighted sagittal and (d) axial after gadolinium administration sequences showing the dishomogeneous contrast enhancement of the lesion

Postoperative course was uneventful. The patient is in good neurological conditions after 1-year follow-up.

DISCUSSION

A literature search was made in the PubMed database including the following terms: Neurocytoma, spinal neurocytoma, neurocytoma of the spinal cord, intramedullary neurocytoma, and extraventricular neurocytoma. Twenty-one articles were found. We excluded from the analysis articles with a follow-up fewer than 6 months or with no information about the follow-up. Fifteen articles^[1-3,5,9-19] and the present case (22 patients, 15/male, 7/female) were eligible for the analysis. The clinical and outcome data are reported in Table 1. We studied the impact of age, sex, number of involved levels (≤ 2 vs. >2), entity of resection (subtotal vs. gross total), postoperative radiotherapy (RT), and proliferation index (Ki67) on the neurological outcome of the patients and on the recurrence of the tumor. Comparison of categorical variables was performed by the χ^2 statistic. The Kaplan–Meier curves were plotted to calculate the progression-free survival (PFS) of these patients. $P < 0.05$ was considered as statistically significant. The mean age of the selected patients was 36.45 ± 17.77 years with a mean follow-up of 38.18 ± 58.46 months. A subtotal resection (STR) was achieved in 14 (64%)^[1,2,5,11,12,16,17,19] while a gross total resection (GTR) was feasible only in 7 cases^[3,9,10,13-15,18] and in the present case (36%). Adjuvant RT was performed only in 7 patients (31.81%)^[1,12,16,17]. The clinical outcome at follow-up was reported stable in 4 cases^[1,11,12] and improved in the present case and in 11^[2,3,5,10,11,14-17] from the literature, with an overall good functional outcome in 72.72% of patients. The mean PFS was 22.65 ± 1.11 months [Figure 3] with a 1-year PFS of 95.45% and a 2-year PFS of 86.36%.

Among the considered potentially prognostic factors, we found a statistically significant better neurological outcome in the patients who underwent adjuvant RT ($P = 0.04$). All the patients with a number of involved levels ≤ 2 [Table 1] reported a stable or improved

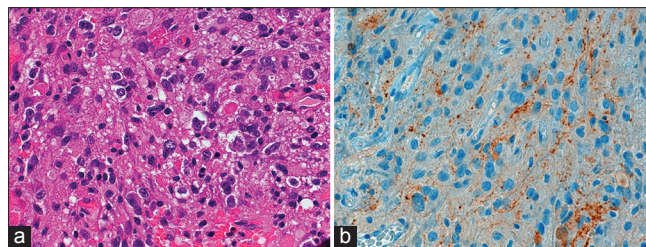


Figure 2: (a, ×400) H and E stain of the lesion showing a neoplasm composed of round to oval cells with finely speckled chromatin pattern and small nucleoli. Ganglion cell differentiation was commonly present among neurocytic cells. (b, ×400) Immunohistochemically, the neoplastic cells were positive for synaptophysin. The MIB-1 labeling index was 1% (not showed)

Table 1: Clinical and outcome findings of primary intramedullary neurocytoma studies included in the analysis

Author, year	Age	Sex	Location	Resection	RT	Ki-67 (%)	PFS (months)	Follow-up (months)	Recurrence	Neurological function at follow-up
Tatter <i>et al.</i> , 1994 ^[17]	65	Male	C2-C6	STR	Yes	NA	120	120	Not	Improved
	49	Male	C3-C4	STR	Yes	NA	24	60	Yes	Improved
Coca <i>et al.</i> , 1994 ^[3]	67	Male	T11-T12	GTR	Not	NA	30	30	Not	Improved
Stapleton <i>et al.</i> , 1997 ^[14]	12	Male	C4-T1	GTR	Not	NA	24	24	Not	Improved
Stephan <i>et al.</i> , 1999 ^[15]	46	Female	T12-L1	GTR	Not	1	12	12	Not	Improved
Ashkan <i>et al.</i> , 2000 ^[2]	12	Male	C6-T1	STR	Not	NA	33	33	Not	Improved
Martin <i>et al.</i> , 2002 ^[9]	50	Male	T2-T5	GTR	Not	2	24	24	Not	Worsened
Sharma <i>et al.</i> , 2005 ^[13]	24	Male	C5-T1	GTR	Not	9	10	24	Yes	Worsened; dead for intracranial metastasis
Gokhan <i>et al.</i> , 2008 ^[5]	49	Female	C3-C6	STR	Not	1	7	7	Not	Improved
Marucci <i>et al.</i> , 2009 ^[10]	51	Male	T10-T11	GTR	Not	1	12	12	Not	Improved
Polli <i>et al.</i> , 2009 ^[12]	6	Male	C1-C7	STR	Not	1	276	276	Not	Worsened
	15	Male	C1-T11	STR	Not	1	24	24	Not	Worsened
	37	Female	T12-L1	STR	Yes	5	15	27	Yes	Stable
Tsai <i>et al.</i> , 2011 ^[18]	54	Female	T3-T5	GTR	Not	1	6	6	Not	Worsened
Agarwal <i>et al.</i> , 2011 ^[11]	16	Male	NA	STR	Yes	NA	6	6	Not	Stable
	25	Male	NA	STR	Yes	NA	6	6	Not	Stable
Wu <i>et al.</i> , 2014 ^[19]	48	Female	Medulla-T1	STR	Not	NA	18	18	Not	Worsened
Patil <i>et al.</i> , 2014 ^[11]	26	Male	Medulla-T4	STR	Not	NA	24	24	Not	Improved
	39	Male	T9-L1	STR	Not	NA	44	44	Not	Stable
Sun <i>et al.</i> , 2015 ^[16]	26	Male	Medulla-T4	STR	Yes	NA	24	24	Not	Improved
	48	Female	Medulla-T2	STR	Yes	NA	24	24	Not	Improved
Present case	37	Female	T8-T10	GTR	Not	1	15	15	Not	Improved

RT: Radiotherapy, PFS: Progression free survival, STR: Subtotal resection, GTR: Gross total resection, NA: Not available

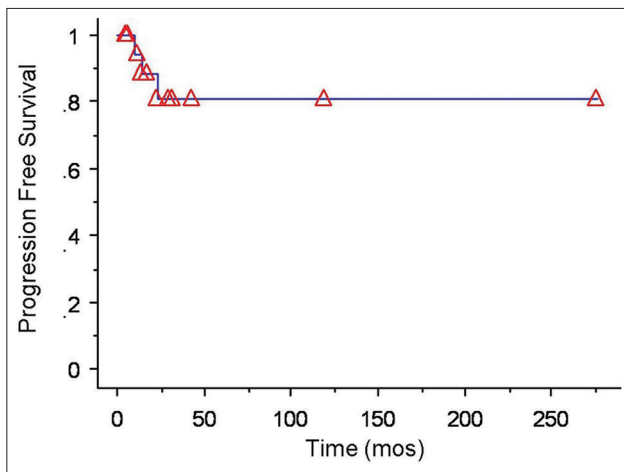


Figure 3: The Kaplan-Meier analysis of progression-free survival of cases included in this review

clinical outcome at follow-up but this data did not reach statistical significance on the analysis ($P = 0.05$). Considering the recurrence risk, a Ki67 (MIB-1) lower than 2% was associated with a statistically significant lower risk of recurrence ($P = 0.0157$).

The primary intramedullary neurocytoma represents a challenge for a neurosurgeon. Preoperative radiological diagnosis can be difficult due to the rarity of this pathology.

Moreover, the extremely variable features on MRI make the differential diagnosis very hard. Likewise astrocytoma, its signal can range from iso- to hypo-intensity on T1-weighted images and iso- to hyper-intensity on T2-weighted images, with homo- or hetero-geneous contrast enhancement.^[4] Moreover, it can show cystic components or intratumoral hemorrhage similarly to ependymomas and hemangioblastomas and can display the exophytic growth mimicking a meningioma.^[17,18] From a surgical point of view, from our literature analysis, it appears evident how it usually involves more spinal segment (70% of reported cases, Table 1) and that a GTR is very difficult to achieve (only 36% of cases). Thus, the preservation of a good functional outcome with a STR instead of a GTR should be kept in mind approaching an intramedullary neurocytoma. In fact, from our analysis, we found a worsening of the neurological function in 3 out of 5 patients (60%) submitted to GTR and only in 3 out of 14 cases (21.42%) who underwent a STR. Moreover, a GTR did not significantly decrease the risk of the recurrence being a lower Ki67 (MIB-1) the factor more strongly related to a lower tumor recurrence. Thus, the histopathological examination is crucial both to make the diagnosis (based on some peculiarities, such as the presence of ganglion cell differentiation, lower cell density and immunoreactivity for glial fibrillary acidic

protein, synaptophysin, and NeuN, markers for glial and neuronal differentiation^[6-8]) and to get the proliferative index (MIB-1). Due to its importance for the prognosis, this data should be routinely investigated (in our analysis it was available only in 10 out of 22 cases [45.45%]). However, the future research should clarify if a higher proliferative index should be considered as an indication for RT. In our analysis, RT seems to play a role in improving the neurological outcome at follow-up but not in preventing the tumor recurrence.

We tried to obtain some indications about the management of the primary intramedullary neurocytoma making an analysis of available cases in the literature. Although our study has some limitations, due to the heterogeneous nature of data, we think that the goal of the surgery should be to preserve a good neurological function even if a residual tumor has to be left. In fact, a GTR did not seem affect the tumor recurrence but is associated to a worsening of the neurological function in most of the cases. Moreover, the Ki67 (MIB-1) should be always evaluated because it seems strongly associated with the tumor recurrence. Further studies should clarify the role of adjuvant RT.

Financial support and sponsorship

Nil.

Conflicts of interest

There are no conflicts of interest.

REFERENCES

- Agarwal S, Sharma MC, Sarkar C, Suri V, Jain A, Sharma MS, et al. Extraventricular neurocytomas: A morphological and histogenetic consideration. A study of six cases. *Pathology* 2011;43:327-34.
- Ashkan K, Casey AT, D'Arrigo C, Harkness WF, Thomas DG. Benign central neurocytoma. *Cancer* 2000;89:1111-20.
- Coca S, Moreno M, Martos JA, Rodriguez J, Barcena A, Vaquero J. Neurocytoma of spinal cord. *Acta Neuropathol* 1994;87:537-40.
- Do-Dai DD, Brooks MK, Goldkamp A, Erbay S, Bhadelia RA. Magnetic resonance imaging of intramedullary spinal cord lesions: A pictorial review. *Curr Probl Diagn Radiol* 2010;39:160-85.
- Gokhan GA, Gurer IE, Akyuz M, Tuncer R. A case of extraventricular neurocytoma of the spinal cord. *Neuropathology* 2008;28:322-5.
- Han L, Niu H, Wang J, Wan F, Shu K, Ke C, et al. Extraventricular neurocytoma in pediatric populations: A case report and review of the literature. *Oncol Lett* 2013;6:1397-405.
- Hassoun J, Gambarelli D, Grisoli F, Pellet W, Salamon G, Pellissier JF, et al. Central neurocytoma. An electron-microscopic study of two cases. *Acta Neuropathol* 1982;56:151-6.
- Louis DN, Ohgaki H, Wiestler OD, Cavenee WK, Burger PC, Jouvet A, et al. The 2007 WHO classification of tumours of the central nervous system. *Acta Neuropathol* 2007;114:97-109.
- Martin AJ, Sharr MM, Teddy PJ, Gardner BP, Robinson SF. Neurocytoma of the thoracic spinal cord. *Acta Neurochir (Wien)* 2002;144:823-8.
- Marucci G, Barbanera A, Serchi E, Andreoli A. Ganglioneurocytoma of the spinal cord: Report of a case and review of literature. *Eur Spine J* 2009;18 Suppl 2:183-5.
- Patil AS, Menon G, Easwer HV, Nair S. Extraventricular neurocytoma, a comprehensive review. *Acta Neurochir (Wien)* 2014;156:349-54.
- Polli FM, Salvati M, Miscusi M, Delfini R, Giangaspero F. Neurocytoma of the spinal cord: Report of three cases and review of the literature. *Acta Neurochir (Wien)* 2009;151:569-74.
- Sharma S, Sarkar C, Gaikwad S, Suri A, Sharma MC. Primary neurocytoma of the spinal cord: A case report and review of literature. *J Neurooncol* 2005;74:47-52.
- Stapleton SR, David KM, Harkness WF, Harding BN. Central neurocytoma of the cervical spinal cord. *J Neurol Neurosurg Psychiatry* 1997;63:119.
- Stephan CL, Kepes JJ, Arnold P, Green KD, Chamberlin F. Neurocytoma of the cauda equina. Case report. *J Neurosurg* 1999;90 2 Suppl: 247-51.
- Sun Z, Yuan D, Cui Z, Sun Y, Yang J, Yan P, et al. Intramedullary neurocytomas in the craniocervical spinal cord: A report of two cases and a literature review. *Oncol Lett* 2015;9:86-90.
- Tatter SB, Borges LF, Louis DN. Central neurocytomas of the cervical spinal cord. Report of two cases. *J Neurosurg* 1994;81:288-93.
- Tsai CY, Tsai TH, Lin CH, Cheng YH, Lieu AS. Unusual exophytic neurocytoma of thoracic spine mimicking meningioma: A case report and review of the literature. *Eur Spine J* 2011;20 Suppl 2:S239-42.
- Wu L, Deng X, Yang C, Zhao L, Yang T, Xu Y. Primary spinal neurocytoma involving the medulla oblongata: Two case reports and a literature review. *Neurol Med Chir (Tokyo)* 2014;54:417-22.