

Case Report

Stent-assisted coil embolization for anterior cerebral artery dissection presented with cerebral infarction

Mitsuhiro Iwasaki, Itaro Hattori, Makoto Sasaki, Hisatsugu Ishimori, Akihiro Nemoto, Chiyo Hikita, Junko Sato, Shinya Fukuta, Masafumi Morimoto

Department of Neurosurgery, Yokohama Shintoshin Neurosurgical Hospital, Yokohama, Japan

E-mail: Mitsuhiro Iwasaki - imitsu1209@gmail.com; Itaro Hattori - ambitaro@hotmail.com; Makoto Sasaki - makoto.alfa.z@gmail.com; Hisatsugu Ishimori - morizou@sa2.so-net.ne.jp; Akihiro Nemoto - akihiro.nemoto0925@gmail.com; Chiyo Hikita - chiyo117@yahoo.co.jp; Junko Sato - jsbac306@yahoo.co.jp; Shinya Fukuta - s_fukuta112@yahoo.co.jp; *Masafumi Morimoto - gnsmasafumi@gmail.com; *Corresponding author

Received: 08 May 15 Accepted: 27 September 15 Published: 07 December 15

Abstract

Background: Compared to those found in the vertebrobasilar system, intracranial dissection in the anterior circulation is relatively rare, especially in the anterior cerebral artery (ACA). Moreover, only several cases of ACA dissection that underwent endovascular treatment have been reported. Here we present a rare case of gradually developing ACA dissecting aneurysm causing cerebral infarction, successfully treated by stent-assisted coil embolization.

Case Description: A 36-year-old man was admitted with sudden right hemiparesis. Diffusion-weighted magnetic resonance (MR) imaging showed cerebral infarction in the left ACA territory, and MR angiography showed segmental stenosis at the A2 portion of the left ACA. Three-dimensional digital subtraction angiogram showed segmental dilatation and stenosis at the left A2 portion. We diagnosed ACA dissection causing acute cerebral infarction and treated the patient conservatively. Five months after the onset, the dissecting artery at the left A2 portion formed a gradually dilating aneurysm, suggesting increased risk for aneurysmal rupture. We attempted endovascular treatment entailing coil embolization of an aneurysm while preserving the left A2 with stent assistance. The patient remained neurologically stable 6 months after the procedure.

Conclusions: Although there are few reported cases of ACA dissection where endovascular treatment was attempted, we consider stent-assisted embolization for gradually developing ACA dissecting aneurysm as an alternative method to prevent bleeding and recurrent infarction.

Key Words: Anterior cerebral artery, dissecting aneurysm, stent-assisted coil embolization

Access this article online

Website:

www.surgicalneurologyint.com

DOI:

10.4103/2152-7806.171240

Quick Response Code:

INTRODUCTION

Spontaneous intracranial dissection is a major cause of hemorrhage or ischemic stroke.^[16,21] Compared to those found in the vertebrobasilar system, intracranial dissection in the anterior circulation is relatively rare, especially in the anterior cerebral artery (ACA).^[5,9,15,16,21,22,26] ACA dissections are regularly found in unruptured form and

This is an open access article distributed under the terms of the Creative Commons Attribution-NonCommercial-ShareAlike 3.0 License, which allows others to remix, tweak, and build upon the work non-commercially, as long as the author is credited and the new creations are licensed under the identical terms.

For reprints contact: reprints@medknow.com

How to cite this article: Iwasaki M, Hattori I, Sasaki M, Ishimori H, Nemoto A, Hikita C, et al. Stent-assisted coil embolization for anterior cerebral artery dissection presented with cerebral infarction. *Surg Neurol Int* 2015;6:182.

<http://surgicalneurologyint.com/Stent-assisted-coil-embolization-for-anterior-cerebral-artery-dissection-presented-with-cerebral-infarction/>

in ischemic cases.^[3,10] Therefore, patients are generally treated conservatively, and the prognosis of ACA dissection is considered to be well.^[3,4,19] Consequently, very few cases of ACA dissection that underwent endovascular treatment have been reported.^[6,7] Here we present a rare case of gradually developing ACA dissecting aneurysm causing cerebral infarction, successfully treated by stent-assisted coil embolization.

CASE HISTORY

A 36-year-old man was admitted with sudden right hemiparesis. He had no abnormal history and had suffered no injury. On admission, diffusion-weighted magnetic resonance (MR) imaging showed cerebral infarction in the territory of the left ACA, and MR angiography revealed segmental stenosis at the A2 portion of the left ACA [Figure 1]. A day after the onset, three-dimensional digital subtraction angiogram (3D-DSA) showed segmental dilatation at the left A2 portion and narrowing at the left A3 portion [Figure 2]. These findings lead to a diagnosis of ACA dissection causing acute cerebral infarction, and the patient was initially treated conservatively. Thirteen days after the onset, DSA revealed slight aneurysmal dilatation and the disappearance of the left pericallosal artery. A pearl string

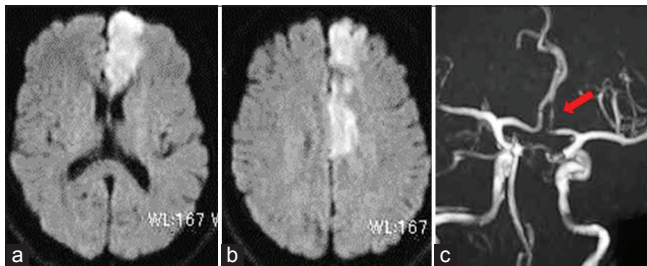


Figure 1: (a and b) Initial head diffusion-weighted magnetic resonance image showed cerebral infarction in the left anterior cerebral artery. (c) The magnetic resonance angiogram showed segmental stenosis on the A2 portion of the left anterior cerebral artery (arrow)

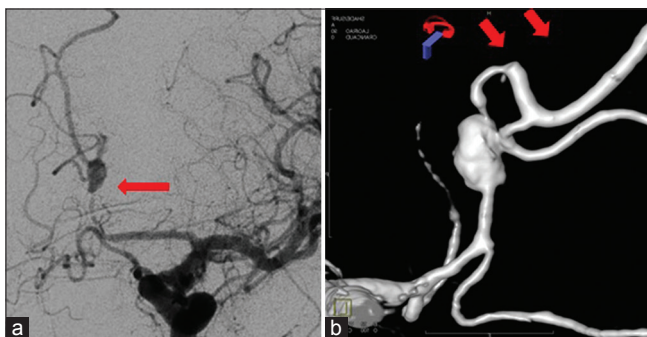


Figure 3: (a) The digital subtraction angiogram and (b) three-dimensional digital subtraction angiogram on day 13 revealed that the progress of aneurysmal dilatation causing pearl and string sign on the left A2 portion (a: Arrow), and disappearance of the left pericallosal artery (b: Arrows)

sign caused by the narrowing of the A2 portion was examined [Figure 3]. Signs of favorable leptomenigeal collateral circulation were found from the left middle cerebral artery and posterior cerebral artery through the left ACA territory. The patient remained neurologically stable; therefore, we continued conservative therapy and rehabilitation for 110 days until his discharge being able to walk without assistance. Five months after the onset, DSA revealed an enlarged protruding dilatation of the left A2 portion [Figure 4] suggesting increased risk for aneurysmal rupture. Based on these findings, we attempted endovascular treatment entailing coil embolization while preserving the left A2 with stenting. This procedure was performed 7 months after the onset.

Transfemoral transarterial stent-assisted coil embolization of a dissecting aneurysm was performed under general anesthesia and heparinization. The left carotid artery was catheterized with a guiding catheter (Launcher, Medtronic, Inc., Minneapolis, MN, USA). Working angle for embolization was obtained using 3D rotational angiography [Figure 5a]. First, the

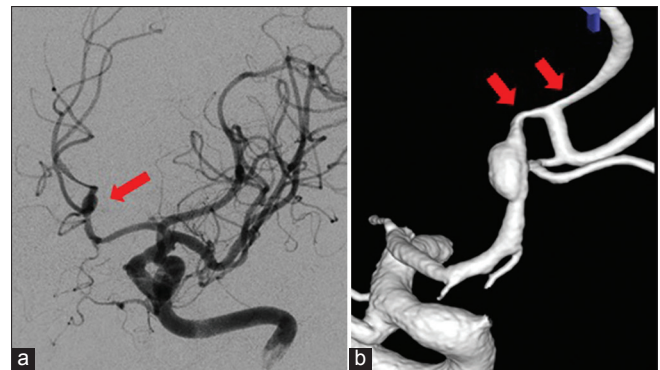

Figure 2: (a) The digital subtraction angiogram on day 1 revealed segmental dilatation at the left A2 portion (arrow). (b) Three-dimensional digital subtraction angiogram showed segmental dilatation and narrowing sign (arrows) in the left A2-A3 portion

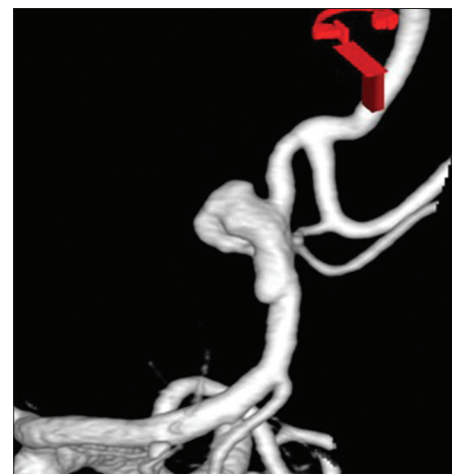


Figure 4: Three-dimensional digital subtraction angiogram showed enlarged protruding dilatation at the left A2

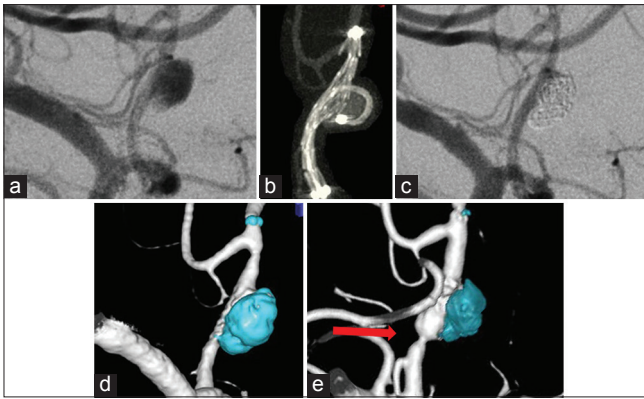


Figure 5: (a) The digital subtraction angiogram in the operative view showed the aneurysm in the left A2 portion. (b) The cone-beam computed tomography revealed the stent covering the aneurysm neck and microcatheter inserted into the aneurysm. (c) The digital subtraction angiogram and (d) three-dimensional digital subtraction angiogram after stent-assisted embolization showed obliteration of the aneurysm and preservation of the left A2. (e) Follow-up three-dimensional digital subtraction angiogram performed 6 months after the operation showed moderate in-stent stenosis

microcatheter (Excelcior SL-10, Stryker, MI, USA) was navigated carefully with a microguidewire (Chikai 14, Asahi Intecc, Aichi, Japan) through the dissected segment. Angiography from the microcatheter completely showed the distal portions of the ACA, identifying this pathway as the true lumen. Microcatheter (Excelcior SL-10, Stryker, MI, USA) was navigated with a microguidewire (Chikai 14, Asahi Intecc, Aichi, Japan) into the aneurysmal fundus and the stent (Neuroform EZ 2.5 mm × 20 mm, Stryker) was placed at the true lumen of the aneurysmal dilatation to cover its neck [Figure 5b]. The first coil (Target 360 soft 3 mm × 8 cm, Stryker) formed a basket, where three coils (ED Extra soft Type R, Kaneka Medics, Ohsaka, Japan) were placed. The dilated portion outside the stent was successfully obliterated, and the ACA inside the stent remained patent [Figure 5c and d].

The patient remained neurologically stable after the procedure and was discharged 5 days into admission. To this day, he continues to take two antiplatelet drugs (aspirin and clopidogrel) starting a week before the operation. Follow-up 3D-DSA performed 6 months after the operation showed moderate in-stent stenosis, but no neurological symptoms were observed a year after the operation [Figure 5e].

DISCUSSION

Dissection in the ACA is rare compared to those found in the vertebrobasilar systems.^[5,9,13,15,16] Several angiographic studies on ACA dissection claimed that arterial stenosis without dilatation occurred mainly in ischemic cases, whereas stenosis with dilatation occurred predominantly in hemorrhagic cases.^[16,21] ACA dissections with cerebral

infarction are frequently reported, and almost all cases have a good prognosis.^[16] Therefore, such patients with ACA dissection are generally treated conservatively.^[16,24,25] Surgical treatment is often selected for patients with progressive dilatation suggesting the risk of future rupture.^[14] In addition, some reports described that dissecting aneurysms with cerebral infarction found in the ACA have a higher tendency of being followed by hemorrhagic events compared to those in other regions.^[12,17,23] We initially treated our patient conservatively, but follow-up angiography revealed progressed dilatation of the ACA dissecting aneurysm which may lead to aneurysmal rupture. Therefore, we decided to treat the dissecting aneurysm by stent-assisted coil embolization to prevent bleeding and preserve the ACA. In addition, both stenting and coil embolization may help prevent recurring ischemia by averting extension of the dissection and preserving the parent A2 artery.

There are few reported cases of ACA dissection where trapping and bypass surgery were attempted,^[7,18] as bypass surgery for A2–A3 portion is technically demanding, and occasionally, trapping the recipient vessel can be time-consuming. For these reasons, the application of such methods to ACA dissection is relatively risky, thus coil embolization with the use of a stent to preserve the parent artery could be considered a safer approach. The present-day neurovascular self-expanding intracranial stents are easy to deliver and seem to have enough radial force to expand the collapsed lumen in dissection without balloon angioplasty. Even though the procedure may risk vessel perforation, there have been some reports on intracranial stenting for dissecting lesions in the internal carotid artery or middle cerebral artery with favorable outcomes.^[11,2,8,11,20] To our knowledge, there has been no report demonstrating ACA dissection treated by stent-assisted coil embolization. In our case, the 6 months postprocedure follow-up angiography showed moderate in-stent stenosis, indicating the requirement for further evaluation.

Recently, several reports were written on fusiform aneurysms successfully treated using the flow diverter stent. Although this stent may be useful in future treatments for lesions in the internal carotid and vertebral arteries, its application for distal ACA dissection will remain technically difficult. Here, we considered stent-assisted coil embolization as an alternative treatment option for dissecting ACA aneurysms.

Acknowledgment

We thank Yu Murano for excellent assistance with article revision.

Financial support and sponsorship

Nil.

Conflicts of interest

There are no conflicts of interest.

REFERENCES

- Binning MJ, Khalessi AA, Siddiqui AH, Hopkins LN, Levy EI. Stent placement for the treatment of a symptomatic intracranial arterial dissection in an adolescent. *J Neurosurg Pediatr* 2010;6:154-8.
- Biondi A, Katz JM, Vallabh J, Segal AZ, Gobin YP. Progressive symptomatic carotid dissection treated with multiple stents. *Stroke* 2005;36:e80-2.
- Caplan LR. Dissections of brain-supplying arteries. *Nat Clin Pract Neurol* 2008;4:34-42.
- Chaves C, Estol C, Esnaola MM, Gorson K, O'Donoghue M, De Witt LD, et al. Spontaneous intracranial internal carotid artery dissection: Report of 10 patients. *Arch Neurol* 2002;59:977-81.
- Guridi J, Gállego J, Monzón F, Aguilera F. Intracerebral hemorrhage caused by transmural dissection of the anterior cerebral artery. *Stroke* 1993;24:1400-2.
- Inoue T, Fujimura M, Matsumoto Y, Kondo R, Inoue T, Shimizu H, et al. Simultaneous occurrence of subarachnoid hemorrhage and cerebral infarction caused by anterior cerebral artery dissection treated by endovascular trapping. *Neurol Med Chir (Tokyo)* 2010;50:574-7.
- Inoue T, Tsutsumi K, Ohno H, Shinozaki M. Revascularization of the anterior cerebral artery with an A3-A3 anastomosis and a superficial temporal artery bypass using an A3-radial artery graft to trap a giant anterior communicating artery aneurysm: Technical case report. *Neurosurgery* 2005;57 Suppl: E207.
- Jeon P, Kim BM, Kim DI, Shin YS, Kim KH, Park SI, et al. Emergent self-expanding stent placement for acute intracranial or extracranial internal carotid artery dissection with significant hemodynamic insufficiency. *AJNR Am J Neuroradiol* 2010;31:1529-32.
- Kato N, Yamada Y, Hyodo A, Nose T. A case of anterior cerebral artery dissection presenting subarachnoid hemorrhage and cerebral infarction. *Jpn J Neurosurg* 2000;9:157-61.
- Kim BM, Kim SH, Kim DI, Shin YS, Suh SH, Kim DJ, et al. Outcomes and prognostic factors of intracranial unruptured vertebrobasilar artery dissection. *Neurology* 2011;76:1735-41.
- Kim DJ, Kim BM, Suh SH, Kim DI. Self-expanding stent placement for anterior circulation intracranial artery dissection presenting with ischemic symptoms. *Neurosurgery* 2015;76:158-64.
- Leach JC, Mitchell PJ, Siu K. Subarachnoid haemorrhage due to a dissecting aneurysm of the anterior cerebral artery: A case report. *J Clin Neurosci* 2004;11:334-7.
- Minematsu K, Matsuoka H, Kasuya J. Cervicocephalic arterial dissection in Japan: Analysis of 454 patients in the spontaneous cervicocephalic arterial dissection study I (SCADS-I) (abstract). *Stroke* 2008;39:566.
- Mizutani T. Natural course of intracranial arterial dissections. *J Neurosurg* 2011;114:1037-44.
- Mori K, Yamamoto T, Maeda M. Dissecting aneurysm confined to the anterior cerebral artery. *Br J Neurosurg* 2002;16:158-64.
- Ohkuma H, Suzuki S, Kikkawa T, Shimamura N. Neuroradiologic and clinical features of arterial dissection of the anterior cerebral artery. *AJNR Am J Neuroradiol* 2003;24:691-9.
- Ohkuma H, Suzuki S, Ogane K; Study Group of the Association of Cerebrovascular Disease in Tohoku, Japan. Dissecting aneurysms of intracranial carotid circulation. *Stroke* 2002;33:941-7.
- Okawa M, Abe H, Iwaasa M, Nonaka M, Higashi T, Inoue T. A case of STA-A3 bypass with a STA interposition graft and endovascular trapping for a ruptured A2 dissecting aneurysm. *No Shinkei Geka* 2014;42:47-52.
- Pessin MS, Adelman LS, Barbas NR. Spontaneous intracranial carotid artery dissection. *Stroke* 1989;20:1100-3.
- Surdell DL, Bernstein RA, Hage ZA, Batjer HH, Bendok BR. Symptomatic spontaneous intracranial carotid artery dissection treated with a self-expanding intracranial nitinol stent: A case report. *Surg Neurol* 2009;71:604-9.
- Suzuki I, Nishino A, Nishimura S, Numagami Y, Suzuki H, Utsunomiya A, et al. Nontraumatic arterial dissection of the anterior cerebral artery: Six cases report. *No To Shinkei* 2005;57:509-15.
- Thines L, Zairi F, Taschner C, Leclerc X, Lucas C, Bourgeois P, et al. Subarachnoid hemorrhage from spontaneous dissection of the anterior cerebral artery. *Cerebrovasc Dis* 2006;22:452-6.
- Uozumi Y, Katoh H, Tsuzuki N, Toyooka T, Miyazawa T, Nawashiro H, et al. Revascularization for anterior cerebral artery dissecting aneurysms – Three case reports. *Neurol Med Chir (Tokyo)* 2010;50:49-53.
- Yamaura A, Ono J, Hirai S. Clinical picture of intracranial non-traumatic dissecting aneurysm. *Neuropathology* 2000;20:85-90.
- Yamamura A, Yoshimoto T, Hashimoto N, Ono J. Nationwide study of nontraumatic intracranial arterial dissection: Treatment and its result. *Surg Cereb Stroke* 1998;26:87-95.
- Yasukawa K, Kamiyo Y, Momose G, Kobayashi S, Ikeda A. A case of anterior cerebral artery dissecting aneurysm presenting subarachnoid hemorrhage and cerebral infarction at the same time. *Surg Cereb Stroke* 1993;21:461-6.