

## Original Article

## Fenestration of bone flap during decompressive craniotomy for subdural hematoma

Ha Son Nguyen, Ninh Doan, Christopher Wolfla, Glen Pollock

Department of Neurosurgery, Medical College of Wisconsin, Milwaukee, WI, USA

E-mail: \*Ha Son Nguyen - [hsnguyen@mcw.edu](mailto:hsnguyen@mcw.edu); Ninh Doan - [ndoan@mcw.edu](mailto:ndoan@mcw.edu); Christopher Wolfla - [cwolfla@mcw.edu](mailto:cwolfla@mcw.edu); Glen Pollock - [gpolloc1@hotmail.com](mailto:gpolloc1@hotmail.com)

\*Corresponding author

Received: 03 November 15 Accepted: 05 January 16 Published: 08 February 16

**Abstract**

**Background:** Persistent/recurrent extra-axial hemorrhage may occur after decompression of a subdural hematoma (SDH) followed by an immediate replacement of bone flap. A fenestration of the bone flap may encourage extra-axial fluid absorption; however, the literature has not explored this technique.

**Methods:** Forty-four consecutive patients who underwent surgical decompression of SDH with immediate replacement of bone flap were divided into two groups: Fenestration (F),  $n = 33$ , and no fenestration (NF),  $n = 11$ . Fenestration involves placement of twist drill holes 1–2 cm apart throughout the bone flap. Clinical data (age, sex, history of antiplatelet/anticoagulation [AA], and presence of drains) were collected. The size of bone flap, postoperative volume, and midline shift (MLS) were measured. A univariate analysis was performed for continuous variables; Fisher's exact test was performed for categorical variables.

**Results:** For postoperative volume, NF group exhibited  $94.4 \pm 15.5 \text{ cm}^3$ , while F group exhibited  $47.3 \pm 15.5 \text{ cm}^3$  ( $P = 0.04$ ); no AA exhibited  $62.9 \pm 12.3 \text{ cm}^3$ , while AA exhibited  $100.5 \pm 19.0 \text{ cm}^3$  ( $P = 0.07$ ); no drains exhibited  $110.1 \pm 29.6 \text{ cm}^3$ , while drains exhibited  $63.0 \pm 9.1 \text{ cm}^3$  ( $P = 0.14$ ). For postoperative MLS, NF group exhibited  $4.8 \pm 1.1 \text{ mm}$ , while F group exhibited  $2.5 \pm 1.1 \text{ mm}$  ( $P = 0.16$ ); no AA exhibited  $2.3 \pm 1.0 \text{ mm}$ , while AA exhibited  $5.8 \pm 1.4 \text{ mm}$  ( $P = 0.048$ ); no drains exhibited  $4.6 \pm 2.2 \text{ mm}$ , while drains exhibited  $3.8 \pm 0.7 \text{ mm}$  ( $P = 0.70$ ). Accounting for fenestration status and AA status: For F group, AA status did not correlate with postoperative volume or MLS significantly; for NF group, history of AA exhibited higher postoperative value  $129.2 \pm 26.5 \text{ cm}^3$ , compared to no history of AA at  $59.5 \pm 16.2 \text{ cm}^3$  ( $P = 0.03$ ).

**Conclusion:** Our results suggest that fenestration prior to the immediate replacement of bone flap after surgical decompression of SDH has the potential to reduce extra-axial fluid accumulation.

**Key Words:** Bone flap fenestration, reoperation, subdural hematoma

## Access this article online

## Website:

[www.surgicalneurologyint.com](http://www.surgicalneurologyint.com)

## DOI:

10.4103/2152-7806.175899

## Quick Response Code:



## INTRODUCTION

The decision for an immediate replacement of the bone flap after surgical decompression of a subdural hematoma (SDH) is typically based on the personal experience of the operating surgeon. A significant concern after immediate replacement is a higher potential for intracranial hypertension, attributable to cerebral edema, contusions, and persistent intracranial hemorrhage and/or recurrence

This is an open access article distributed under the terms of the Creative Commons Attribution-NonCommercial-ShareAlike 3.0 License, which allows others to remix, tweak, and build upon the work non-commercially, as long as the author is credited and the new creations are licensed under the identical terms.

**For reprints contact:** [reprints@medknow.com](mailto:reprints@medknow.com)

**How to cite this article:** Nguyen HS, Doan N, Wolfla C, Pollock G. Fenestration of bone flap during decompressive craniotomy for subdural hematoma. *Surg Neurol Int* 2016;7:16.

<http://surgicalneurologyint.com/Fenestration-of-bone-flap-during-decompressive-craniotomy-for-subdural-hematoma/>

of hemorrhage. The latter may require reoperation, with reported incidences ranging up to 6–16%.<sup>[5,10,17]</sup> The application of drains, either deep or superficial to the bone flap, has been utilized to moderate this issue. At our hospital, we have also fenestrated the bone flap to encourage drainage of extra-axial fluid into the subgaleal (SG) space, where fluid absorption can occur. This technique has not been described during decompressive craniotomy (DC).

## METHODS

The approval of the institutional board review at our hospital was obtained prior to the study.

Between fall 2012 and spring 2015, 44 patients underwent surgical decompression for SDH with immediate replacement of the bone flap at our institution. A standard fronto-temporo-parietal craniotomy is performed, and the dura is opened in a stellate fashion. Once the hematoma is evacuated and hemostasis is achieved, the dural leaves of the stellate opening are loosely reflected back over the brain and a sizeable layer of nonsuturable Duragen is applied to cover the entire dural opening. No attempt is made to create a watertight duraplasty. A drain is frequently placed superficial to the Duragen and is referred to as an epidural (ED) drain. In addition, a SG drain may also be placed.

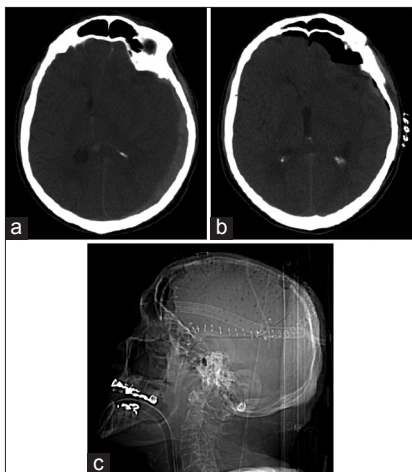
Eight neurosurgeons performed the surgeries. The patients were divided into two groups: Fenestration (F) and no fenestration (NF). The fenestration involves placement of twist drill holes 1–2 cm apart throughout the bone flap [Figure 1a-c]. Patient clinical data (age, sex, history of antiplatelet/anticoagulation [AA]) was collected via chart review. The patient demographics are listed in Table 1. The size of bone flap was calculated from postoperative lateral scout films as an ellipse with

the longest axis being  $2a$  and the  $90^\circ$  short axis being  $2b$  with the formula:  $\pi \times a \times b$ .<sup>[12]</sup> For patients who did not require reoperation, the postoperative computed tomography (CT) head (obtained within 1 day) was evaluated for postoperative volume and midline shift (MLS) using a picture archiving and communication system. For patients who did require reoperation, the CT prior to reoperation was evaluated. The postoperative volume was calculated based on the XYZ/2 method as previously described.<sup>[14]</sup> Briefly, this method involves using the product of the widest (X), longest (Y), and thickest (Z) dimensions of the extra-axial fluid collection, divided by 2. The thickest dimension was calculated by multiplying the slices on which the collection was visible by the slice thickness (5 mm). Postoperative volume includes both hematoma and pneumocephalus. MLS was calculated at the axial CT slice that visualizes the foramen of Monro.

Data were entered into SPSS version 22 (IBM Corporation, Armonk, NY, USA) for analysis. Results were expressed as the means  $\pm$  standard error for all descriptive continuous variables. A univariate analysis and Fisher's exact test were performed for continuous variables and categorical variables respectively. A  $P < 0.05$  was considered statistically significant.

## RESULTS

Table 1 summarizes the patient demographics. NF group consisted of 33 patients (22 males, 11 females); F group consisted of 11 patients (8 males, 3 females). Average age was 61.2 and 69.7 years ( $P = 0.20$ ); average size of bone flap was 55.7 and 67.3 cm<sup>3</sup> ( $P = 0.32$ ). Fifteen patients had a history of AA usage in the NF group, while six patients had such a history in the F group. Three patients underwent reoperation due to extra-axial fluid accumulation/re-hemorrhage underneath their bone



**Figure 1:** Example patient with preoperative computed tomography (a), postoperative computed tomography (b), and lateral skull film (c)

**Table 1: Patient demographics**

	No fenestration	Fenestration
Age (years)	61.2	69.7
Total patients	33	11
Males	22	8
Females	11	3
History of AA	15	6
Reoperation	3	1
Size of bone flap (cm <sup>3</sup> )	55.7	67.3
Drains	29	11
ED drain	12	0
SG drain	9	8
SG/SDD (SG drain/ED drain)	8	3
Traumatic	25	6
Spontaneous	4	5

ED: Epidural, SG: Subgaleal, SDD: Subdural drain, AA: Antiplatelet/anticoagulation

flap in the NF group; one required reoperation in the F group ( $P = 1.00$ ). For drain placement, NF group had 29 patients with drains (12 with a ED drain, 9 with a SG drain, and 8 with a SG drain and an ED drain); F group had 8 patients with SG drain only and 3 with both drains.

Table 2 summarizes the overall results. For postoperative volume, NF group exhibited  $94.4 \pm 15.5 \text{ cm}^3$ ; F group exhibited  $47.3 \pm 15.5 \text{ cm}^3$  ( $P = 0.04$ ); no AA exhibited  $62.9 \pm 12.3 \text{ cm}^3$ ; AA exhibited  $100.5 \pm 19.0 \text{ cm}^3$  ( $P = 0.07$ ); no drains exhibited  $110.1 \pm 29.6 \text{ cm}^3$ ; drains exhibited  $63.0 \pm 9.1 \text{ cm}^3$  ( $P = 0.14$ ). For postoperative MLS, NF group exhibited  $4.8 \pm 1.1 \text{ mm}$ ; F group exhibited  $2.5 \pm 1.1 \text{ mm}$  ( $P = 0.16$ ); no AA exhibited  $2.3 \pm 1.0 \text{ mm}$ ; AA exhibited  $5.8 \pm 1.4 \text{ mm}$  ( $P = 0.048$ ); no drains exhibited  $4.6 \pm 2.2 \text{ mm}$ ; drains exhibited  $3.8 \pm 0.7 \text{ mm}$  ( $P = 0.70$ ). Tables 3 and 4 summarize univariate analysis for MLS and postoperative volume, respectively, accounting for fenestration status and AA status. For F group, AA status did not correlate with postoperative volume or MLS significantly. For NF group, a history of AA exhibited higher postoperative value  $129.2 \pm 26.5 \text{ cm}^3$ , compared to no history of AA at  $59.5 \pm 16.2 \text{ cm}^3$  ( $P = 0.03$ ).

## DISCUSSION

DC for SDH, where the bone flap is replaced after surgical decompression, excludes the need for an interval cranioplasty. In particular, an additional procedure puts patients at risk for complications (hydrocephalus, infection, seizures, and hemorrhage). However, a risk after immediate bone flap replacement is a higher potential for intracranial hypertension, attributable to cerebral edema, contusions, and persistent/recurrent extra-axial hemorrhage. These factors may require reoperation with reported incidences ranging up to 6–16%.<sup>[5,10,17]</sup> Several modifications to DC have been employed to address this concern. Instead of rigid fixation via titanium plating, bone flaps have been left “floating” or lightly attached with sutures.<sup>[7]</sup> Moreover, the “hinge craniotomy” was introduced in 2007, where a Y-shaped titanium plate along an edge of the bone flap serves as a hinge for the flap to move outward if intracranial hypertension exists.<sup>[11]</sup> A few retrospective reviews highlight the finding that the modification provides postoperative ICP control similar to that observed with decompressive craniectomy.<sup>[4,5]</sup> A modification utilizes the temporalis muscle as the “hinge”.<sup>[1]</sup> A recent, similar variant is the “in-window” craniotomy, where the bone flap is divided and each partition has its own hinge.<sup>[16]</sup>

To our knowledge, the modification for fenestration of bone flap during DC has not been reported. On the other hand, fenestration has been employed with synthetic implants for interval cranioplasty, including

**Table 2: Results**

	Postoperative volume (cm <sup>3</sup> )			MLS (mm)		
	Value	SE	P	Value	SE	P
No fenestration	94.4	15.5	0.04	4.8	1.1	0.16
Fenestration	47.3	15.5		2.5	1.1	
No AA	62.9	12.3	0.07	2.3	1.0	0.048
AA	100.5	19.0		5.8	1.4	
No drains	110.1	29.6	0.14	4.6	2.2	0.70
Drains	63.0	9.1		3.8	0.7	

MLS: Midline shift, SE: Standard error, AA: Antiplatelet/anticoagulation

**Table 3: Midline shift results**

Fenestration	MLS (mm)		
	AA	Mean ± SE	P
Yes	Yes	3.4 ± 1.5	0.46
	No	1.7 ± 1.7	
No	Yes	7.0 ± 1.9	0.06
	No	2.7 ± 1.2	

MLS: Midline shift, SE: Standard error, AA: Antiplatelet/anticoagulation

**Table 4: Postoperative volume results**

Fenestration	Postoperative volume (cm <sup>3</sup> )		
	AA status	Mean ± SE	P
Yes	Yes	43.0 ± 20.9	0.79
	No	51.5 ± 22.9	
No	Yes	129.2 ± 26.5	0.03
	No	59.5 ± 16.2	

SE: Standard error, AA: Antiplatelet/anticoagulation

polyether ether ketone implants and titanium mesh; unfortunately, limited data exist with respect to extra-axial fluid accumulation and subsequent reoperation.<sup>[9,15]</sup> We recently reported this technique for interval autologous cranioplasty, with promising results regarding postoperative MLS and postoperative volume. Seemingly, the fenestrations augment surface area for drainage of extra-axial fluid through the bone flap, where fluid can be absorbed through a SG drain. Since the galea also has potential for fluid absorption, as evident with ventriculo-SG shunts,<sup>[8]</sup> fluid absorption may continue after drains are discontinued. In our study, the F group exhibited lower values for postoperative volume and MLS, reaching statistical significance for the former parameter. The results imply that fenestration of the bone flap may reduce the potential for accumulation of extra-axial fluid.

Several studies have evaluated the influence of oral antithrombotic therapy during the management of acute SDH. Panczykowski *et al.*<sup>[10]</sup> noted that pre-morbid oral antithrombotic therapy did not significantly increase the risk for reoperation or volume of SDH re-accumulation.

Similarly, Senft *et al.*<sup>[13]</sup> found no association between worse outcome or death with oral antithrombotic use. On the other hand, Bershad *et al.*<sup>[2]</sup> found that coagulopathy is independently associated with in-hospital death in patients with acute SDH. Our results suggest that postoperative extra-axial fluid accumulation may be higher in patients with a history of AA therapy. However, reoperation rates were not significantly different, which is difficult to interpret with low sample sizes. A comparison with Senft *et al.*<sup>[13]</sup> is challenging since final outcomes were not evaluated in our study. Moreover, a direct comparison to Panczykowski *et al.*<sup>[10]</sup> is also problematic since the latter did not account for bone flap status (craniotomy vs. craniectomy) and did not employ bone flap fenestration.

The contribution of drains during DC has not been widely explored. Data regarding the use of drains during interval cranioplasty is conflicting.<sup>[3,6]</sup> Our data does suggest that drains help reduce postoperative fluid accumulation without reaching statistical significance. A relationship is difficult to decipher since only four patients in our study had no drains postoperatively, compared to forty patients who did.

The limitations of this study include the retrospective analysis, entailing possible selection bias and loss of patient data. Moreover, the study was purely a radiological study, where outcome data (including mortality, morbidity, Glasgow scale outcome scores) were not evaluated. Moreover, operative techniques were varied among surgeons. On the other hand, the patients in the two groups appeared comparable, given that the age and bone flap size were not significantly different.

## CONCLUSION

Our results suggest that fenestration prior to immediate replacement of bone flap after surgical decompression of SDH has the potential to reduce extra-axial fluid accumulation. To our knowledge, the modification for fenestration of bone flap during DC has not been reported. Theoretically, the fenestrations provide a more surface area for drainage of extra-axial fluid through the bone flap. Moreover, history of AA therapy may increase the risk of postoperative fluid accumulation. Randomized control studies should evaluate this technique as a modification to DC procedure. This technique may help moderate intracranial hypertension.

## Financial support and sponsorship

Nil.

## Conflicts of interest

There are no conflicts of interest.

## REFERENCES

1. Adeleye AO, Azeez AL. Decompressive craniectomy bone flap hinged on the temporalis muscle: A new inexpensive use for an old neurosurgical technique. *Surg Neurol Int* 2011;2:150.
2. Bershad EM, Farhadi S, Suri MF, Feen ES, Hernandez OH, Selman WR, *et al.* Coagulopathy and in-hospital deaths in patients with acute subdural hematoma. *J Neurosurg* 2008;109:664-9.
3. Chang V, Hartzfeld P, Langlois M, Mahmood A, Seyfried D. Outcomes of cranial repair after craniectomy. *J Neurosurg* 2010;112:1120-4.
4. Kenning TJ, Gandhi RH, German JW. A comparison of hinge craniotomy and decompressive craniectomy for the treatment of malignant intracranial hypertension: Early clinical and radiographic analysis. *Neurosurg Focus* 2009;26:E6.
5. Kenning TJ, Gooch MR, Gandhi RH, Shaikh MP, Boulos AS, German JW. Cranial decompression for the treatment of malignant intracranial hypertension after ischemic cerebral infarction: Decompressive craniectomy and hinge craniotomy. *J Neurosurg* 2012;116:1289-98.
6. Klinger DR, Madden C, Beshay J, White J, Gambrell K, Rickert K. Autologous and acrylic cranioplasty: A review of 10 years and 258 cases. *World Neurosurg* 2014;82:e525-30.
7. Mezue WC, Ndubuisi C, Ohaegbulam SC, Chikani M, Erechukwu U. Cranial bony decompressions in the management of head injuries: Decompressive craniotomy or craniectomy? *Niger J Clin Pract* 2013;16:343-7.
8. Nagy A, Bogner L, Pataki I, Barta Z, Novak L. Ventriculobulbale shunt in the treatment of posthemorrhagic and postinfectious hydrocephalus of premature infants. *Childs Nerv Syst* 2013;29:413-8.
9. Ng ZY, Ang WJ, Nawaz I. Computer-designed polyetheretherketone implants versus titanium mesh ( $\pm$  acrylic cement) in alloplastic cranioplasty: A retrospective single-surgeon, single-center study. *J Craniofac Surg* 2014;25:e185-9.
10. Panczykowski DM, Okonkwo DO. Premorbid oral antithrombotic therapy and risk for reaccumulation, reoperation, and mortality in acute subdural hematomas. *J Neurosurg* 2011;114:47-52.
11. Schmidt JH 3<sup>rd</sup>, Reyes BJ, Fischer R, Flaherty SK. Use of hinge craniotomy for cerebral decompression. Technical note. *J Neurosurg* 2007;107:678-82.
12. Schoekler B, Trummer M. Prediction parameters of bone flap resorption following cranioplasty with autologous bone. *Clin Neurol Neurosurg* 2014;120:64-7.
13. Senft C, Schuster T, Forster MT, Seifert V, Gerlach R. Management and outcome of patients with acute traumatic subdural hematomas and pre-injury oral anticoagulation therapy. *Neurol Res* 2009;31:1012-8.
14. Sucu HK, Gokmen M, Gelal F. The value of XYZ/2 technique compared with computer-assisted volumetric analysis to estimate the volume of chronic subdural hematoma. *Stroke* 2005;36:998-1000.
15. Thien A, King NK, Ang BT, Wang E, Ng I. Comparison of polyetheretherketone and titanium cranioplasty after decompressive craniectomy. *World Neurosurg* 2015;83:176-80.
16. Valença MM, Martins C, da Silva JC. "In-window" craniotomy and "bridgelike" duraplasty: An alternative to decompressive hemicraniectomy. *J Neurosurg* 2010;113:982-9.
17. Zanaty M, Chalouhi N, Starke RM, Chitale R, Hann S, Bovenzi CD, *et al.* Predictors of infections following cranioplasty: A retrospective review of a large single center study. *Scientific World Journal* 2014;2014:356042.