

Fundamental Neurosurgery

A tale of two acute extradural hematomas

Amos Olufemi Adeleye, Ikechi E. Jite¹, Omolara A. Smith¹Department of Surgery, Division of Neurological Surgery, College of Medicine, University College Hospital, University of Ibadan, ¹Department of Family Medicine, Molly Specialist Hospital, Ibadan, Nigeria

E-mail: *Amos Olufemi Adeleye - femdoy@yahoo.com; Ikechi E. Jite - emjitechrist@gmail.com; Omolara A. Smith - omolarasmith@yahoo.com

*Corresponding author

Received: 22 December 15 Accepted: 03 March 16 Published: 06 May 16

Abstract

Background: In much of the Western hemisphere, mortality from traumatic acute extradural hematomas (AEDH) has been drastically brought down toward 0%. This is still not the case however in most developing countries.

Case Description: This report represents a tragi-comic tale of two cases of traumatic AEDH managed by an academic neurosurgeon in a neurosurgically ill-resourced private health facility during a nationwide industrial strike action preventing clinical-surgical care in the principal author's University Teaching Hospital. A young man presented with altered consciousness, Glasgow Coma Score (GCS) 14/15, following a road accident. The cranial computed tomography (CT) scan was obtained only 9 h after its request, long after the man had actually deteriorated to GCS 7/15 with pupillary changes. The neurosurgeon, summoned from the nearby University Teaching Hospital for the operative care of this man, arrived on-site and was about moving the patient into the operative room when he took the final breaths and died, all within 2 h of the belated neuroimaging. This scenario repeated itself in the same health facility just 24 h later with another young man who presented GCS 7/15 and another identical CT evidence of traumatic AEDH. With more financially able relations, the diagnostic/surgical care of this second patient was much more prompt. He made a very brisk recovery from neurosurgical operative intervention. He is alive and well, 5-month postoperative.

Conclusions: In most low-resourced health systems of the developing countries, a significant proportion of potentially salvageable cases of AEDH still perish from this disease condition.

Key Words: Developing countries, poor health systems, poor outcome, talked and died head injured, traumatic acute extradural hematomas

Access this article online**Website:**www.surgicalneurologyint.com**DOI:**

10.4103/2152-7806.181905

Quick Response Code:

This is an open access article distributed under the terms of the Creative Commons Attribution-NonCommercial-ShareAlike 3.0 License, which allows others to remix, tweak, and build upon the work non-commercially, as long as the author is credited and the new creations are licensed under the identical terms.

For reprints contact: reprints@medknow.com

How to cite this article: Adeleye AO, Jite IE, Smith OA. A tale of two acute extradural hematomas. *Surg Neurol Int* 2016;7:54.
<http://surgicalneurologyint.com/A-tale-of-two-acute-extradural-hematomas/>

EDITOR IN CHIEF'S NOTE

I decided to publish this case report over the objections of six reviewers, many from the developing world because I believed there was a story here for all to know. I knew the doctor involved as an educated and well-trained neurosurgeon.

There is a larger issue here that is recorded in this editorial. It is about health care in the developing world and in general around the world. I have been an antagonist of government controlled health care, as many of you know. Yet, in this editorial, a very strong case is made for some central regulation of care and facilities to provide at least the basics of care to the population. Yet, in governments there is corruption as there is in health care systems in which the money intended for the patient never reaches the patient or so little as to compromise their care. It is true all over the world and physicians are witness to this corruption that affects their patients. Yet, what do they do to stop this corrupt behavior. We see this situation now happening in the USA as the government makes a major effort to centralize the control of health care. Inevitably, such systems incentivize corruption with administrators and consultants taking the money collected for the patient so that the patient receives less quality of care. Physicians, who are employed by the governments, salaries are regulated. On top of that there are a huge number of forms a physician must fill out to justify his/her care under the bureaucratic regulations imposed by such a system in the USA.

Hence, from the developing to the developed world there is a challenge in producing a system of health care that serves the public. As in any system that is developed for the good of the people be it free-market or collectivist,

there needs to be physician oversight of other physicians or administrators or politicians who are abusing the system for their own benefit. It is a people problem. It is a moral and ethical problem learned in religious teachings or other forms of civilization guided by principles based on the differences between what is right and wrong. When a society abandons those principles, the disastrous results occur in either the developing or developed world. The anger expressed by the reviewers should not be directed at the physicians and personnel who tried to save these lives, but at ones-self for not asking: "What can I do to make my health care system better?" Doctors have abandoned their role of being the advocate for the patient, which is our duty by the Hippocratic oath. That is what separates medicine from other professions. It is devotion to the patient, not to money, which the doctor and people involved tried to do. Greed has displaced the desire to help the poor and sick. Making more money is not the answer but is the curse that killed the first patient. This is not just a problem in Africa but exists worldwide. As physicians, it is our duty to solve this problem which should not be left to those whose goal is making money including governments, administrations, consultants, and others who were not raised as physicians to think of the "Patient Comes First." It is even worse if physicians become addicted to the pursuit of money over what is best for the patient. Physicians with such behavior do not deserve to belong to the profession of medicine.

James I. Ausman, MD, PhD

Editor-in-Chief
jia@surgicalneurologyint.com

INTRODUCTION

Traumatic acute extradural hematoma (AEDH) was a uniformly fatal lesion in the early era of neurological surgery killing at least four of five victims in some reports.^[4] But in the modern era of computed brain imaging affording prompt, precise diagnosis in the trauma patients, AEDH has since become one of the disease conditions that may truly be called the delight of a neurosurgeon. Outcome from prompt neurosurgical intervention is so fairly assured that a target of zero mortality has been set for it.^[3]

Quite unfortunately, however, the outlook for this neurosurgical condition is still far from this latter-day target in many developing countries. In these regions, a sizeable proportion of cases presenting in-hospital still perishes from AEDH.^[7,9] This is due to many factors not

the least of which is the quite weak, and harsh health systems of most developing countries.

In this report, we present a very instructive recent clinical experience in our neurosurgical practice in Nigeria that may cast some of the issues involved in stark relief. It involved two cases of traumatic AEDH seen in a spate of 24 h. Although the two had very similar clinical-radiological characteristics, their in-hospital outcomes were starkly different: The one bad and the other good.

CASE ILLUSTRATIONS

Case 1

One day recently, during an industrial strike action preventing full clinical duties in our University Teaching Hospital, a 35-year-old young man presented at 9:00 am

following a rider motorcycle accident in a nearby private health facility. He was conscious but drowsy (Glasgow Coma Score [GCS] 14/15), telling some of the story of his trauma. He bled briefly (<2 h) from the nostrils and apart from some scalp bruises had no significant extracranial systemic injuries. He deteriorated 2 h (11:30 am) into the admission: Vomited and became restless; then lapsed into coma (GCS 7/15). A brain computed tomographic (CT) had been requested but it took the relations many hours to raise the money for this study. The CT was obtained, about 11 h after trauma and 9 h after it was requested, in a private diagnostic imaging center, newly-opened in another part of the town. Time now was about 6:30 pm in the evening. A neurosurgeon from the University Teaching Hospital was invited to evaluate the patient and the imaging findings. Pronto, the neurosurgeon made his way there, (on his way home). And his review at 7:00 pm showed a young man in deep coma (GCS 4/15), pulse 65/min; calm regular breathing, respiratory rate (RR) 28/min, and blood pressure 180/70 mmHg. The pupils were 5 mm each, reacting sluggishly to light. The cranial CT, Figure 1, showed a left frontotemporal scalp contusion, linear skull fracture, and an underlying left frontal 30 mm-thick AEDH with associated marked pressure effects: Effaced gray-white differentiation, effacement/shift of the left lateral/third ventricles, complete effacement of the basal cisterns, and midline shift >10 mm. The homeward journey of the neurosurgeon was canceled there and then, and a life-threatening emergency was called, the neurosurgeon declaring “this patient is not likely to be alive by daybreak if not operated on tonight.” This private hospital was not necessarily used to the military commando kind of operation the neurosurgeon swung into. Moreover, there were financial implications for

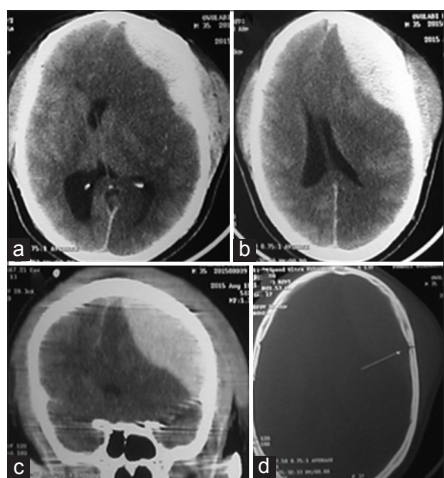


Figure 1: The cranial computed tomography scan of the first patient (a and b) axial and (c) coronal reconstruction of the brain scan showing the left frontotemporal acute extradural hematoma and the significant pressure effects on the brain (d) the linear skull fracture, frontotemporal overlying the hematoma

mobilizing the hospital resources to support the proposed operative neurosurgical interventions: The patient's relations needed to put some amount of money down if only as part payment of the final total cost. Nevertheless, the hospital took up the challenge, waived all the fees in the interim and mobilized its resources/personnel in readiness for the surgery. The neurosurgeon also called out, on a mobile phone, his trusted neuroanesthetic, neurosurgical operating room nurses, and some of his senior residents from his university hospital to site. By 8:00 pm, just 1½ h after the neurosurgeons' arrival, all the critical members of this team had already shown up, mobilizing the materials, and preparing the OR. But the patient, while being “pumped” with a fast infusion of 20% mannitol in readiness to move him to the OR, suddenly vomited once again and started gasping. He was certified dead at 8:20 pm, just 2 h after the belated brain CT scanning. It was so painful for all the team members. The cry and bitter agony by all of us were what might have been if only the brain CT had been available much earlier.

Case 2

Exactly 24 h later, this neurosurgeon got another call from the same private hospital concerning another young man, a 21-year-old victim of a pedestrian-motor vehicle accident occurring 6 h earlier. The patient suffered immediate and persistent loss of consciousness and associated right humeral fracture. This patient had more capable family support; hence, he obtained the cranial CT requested without delay just ½ h into his admission. The neurosurgeon was called to evaluate this patient and the CT by 7:40 pm and he (the neurosurgeon) got to the patient, again on his way home, at 8:30 pm. The young man was found unconscious (GCS 7/15); the right and left pupils were 3 mm and 4 mm, respectively, both brisk to light. There were mild craniofacial soft-tissue contusions and punctate lacerations and an associated closed right humeral fracture. The cranial CT 7 h posttrauma showed findings remarkably similar in major respects to the previous day's: Left frontotemporal scalp contusion, linear skull fracture, and left frontotemporal AEDH with marked pressure effects—effacement of the cerebral gray-white differentiation, shift of the left lateral/third ventricles and the midline, and effacement of basal cisterns, Figure 2.

Again the neurosurgeon canceled his homeward journey, declaring once more that “this patient is not likely to be alive by daybreak if not operated on tonight.” The team was once again mobilized, the hospital prevailed upon to waive financial considerations to allow the emergency surgery. The hospital acquiesced and put all their resources down, as yet for free just like in the previous day's experience, and a mini-craniotomy under total intravenous anesthesia commenced by 10:55 pm was completed 1 h

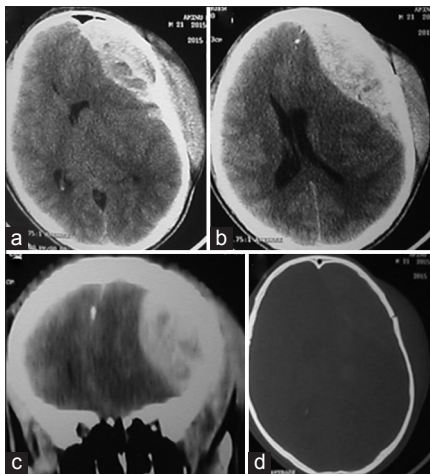


Figure 2:The cranial computed tomography scan of the second patient (a, b) brain image in the axial and (c) coronal reconstruction views (d) axial bone window. These show features of severe brain injury that were remarkably almost mirror image of the first patient's scan

25 min later at 12:10 am. The patient was moved back to the hospital regular ward—there was no intensive care/high dependency care facility in this private clinic. By 11:00 am, 10 h postoperative, the patient was fully awake and oriented (GCS 15/15). He was mobilized out of bed, tolerating normal diet by the 1st postoperative day.

The humeral fracture was eventually surgically fixed by an orthopedic surgeon in the same private hospital. The patient was discharged home on the postoperative day 26 (the prolonged hospital stay due mainly to the time it took for a tolerable fraction of the total hospital bills to be settled by the family). He remained well, Glasgow Outcome Scale, normal, at the last outpatient visit 3 months postoperative.

DISCUSSION

This short report is a tragi-comic tale that affords some glimpse into the real-world imperatives of delivering tolerable health care in general, and operative neurosurgical care in particular,^[1] in much of the world's developing countries. The tragic part of the tale involved one case of AEDH, posttrauma, that perished due essentially to financial constraints to the prompt delivery of the necessary diagnostic neuroimaging, and hence, neurosurgical intervention in a sub-Saharan African developing country. The comic part was an almost totally identical situation 24 h later in the same practice, with a gratifying outcome following more prompt delivery of the essential diagnostic health care.

Traumatic AEDH was a highly fatal neurosurgical condition in the early era of brain surgical diagnosis and treatment more than 100 years ago.^[10,11] The mortality rate was reportedly as high as 86% then.^[4] This is in contrast with what obtains in the modern era where

mortality rates reported are in the region of 10%, much of this being contributed by cases presenting as severe head injury.^[5] In cases with mild head injury, modern neurosurgical care affords mortality as low as 1%, or even 0%, for traumatic extradural hematoma.^[3] Hence, any patient with traumatic AEDH who dies, after presenting with GCS 13–15, as in the first case in this report is an example of the classic “talked and died” patient whom the health care system can be deemed to have failed.^[7]

It is some 40 years since Reilly *et al.* first described the phenomenon of the patient with a head injury who talked and died. It was a landmark paper.^[11] Moreover, the critical significance of the clinical observations made in it is the fact of a sub-set of the head injured who, although presumed *ab initio* by the unwary treating physicians to suffer only mild/insignificant brain injury, subsequently die from potentially salvageable causes. Such salvageable causes can be intra- or extra-cranial. The advent of brain CT postdating the paper by Reilly *et al.* has since cast that observation in more poignant relieve. In one series in the CT era, four of every five patients who talked and died had potentially surgically salvageable intracranial mass lesions; extra-/sub-dural hematoma accounted for close to half of these.^[8] With increasing availability of CT scanning for evaluation of brain injury, the trend has since been one of progressive decline in the percentage of the “head injured who talked and died.”^[8,10]

Sadly, however, this salutary trend holds true in only the health systems of the developed countries. As illustrated in this tale there are still many areas of “organic disease” in the health systems of the world's low-middle income countries. These include dysfunctional, crisis-ridden and poorly-infrastuctured public health institutions, and a health care financing model, out-of-pocket payment^[2] that must qualify as one of the most impractical solutions ever proffered by man for an identified problem.^[6] This may perhaps be the real “neglected tropical disease” (NTD). This “NTD” continues to rampage untrammelled mowing down significant members of the working class each year in most developing countries.

Financial support and sponsorship

Nil.

Conflicts of interest

There are no conflicts of interest.

REFERENCES

1. Adeleye AO, Fasunla JA, Young PH. Skull base surgery in a large, resource-poor, developing country with few neurosurgeons: Prospects, challenges, and needs. *World Neurosurg* 2012;78:35-43.
2. Adewole DA, Adebayo AM, Udeh EI, Shaahu VN, Dairo MD. Payment for health care and perception of the national health insurance scheme in a rural area in Southwest Nigeria. *Am J Trop Med Hyg* 2015;93:648-54.
3. Bricolo AP, Pasut LM. Extradural hematoma: Toward zero mortality. A prospective study. *Neurosurgery* 1984;14:8-12.

4. Cheung PS, Lam JM, Yeung JH, Graham CA, Rainer TH. Outcome of traumatic extradural haematoma in Hong Kong. *Injury* 2007;38:76-80.
5. Heinzelmann M, Platz A, Imhof HG. Outcome after acute extradural haematoma, influence of additional injuries and neurological complications in the ICU. *Injury* 1996;27:345-9.
6. Kim JY, Chan M. Poverty, health, and societies of the future poverty, health, and societies of the future view point. *JAMA* 2013;310:901-2.
7. Liu JT, Tyan YS, Lee YK, Wang JT. Emergency management of epidural haematoma through burr hole evacuation and drainage. A preliminary report. *Acta Neurochir (Wien)* 2006;148:313-7.
8. Lobato RD, Rivas JJ, Gomez PA, Castañeda M, Cañizal JM, Sarabia R, et al. Head-injured patients who talk and deteriorate into coma. Analysis of 211 cases studied with computerized tomography. *J Neurosurg* 1991;75:256-61.
9. Mezue WC, Ndubuisi CA, Chikani MC, Achebe DS, Ohaegbulam SC. Traumatic extradural hematoma in Enugu, Nigeria. *Niger J Surg* 2012;18:80-4.
10. Ratanalert S, Chompikul J, Hirunpat S. Talked and deteriorated head injury patients: How many poor outcomes can be avoided? *J Clin Neurosci* 2002;9:640-3.
11. Reilly PL, Graham DI, Adams JH, Jennett B. Patients with head injury who talk and die. *Lancet* 1975;2:375-7.

Commentary

During the course of the peer review for a manuscript (a tale of two acute extradural hematomas [AEDH]) that we submitted to *Surgical Neurology International*, some of the reviewers expressed great outrage, actually righteous indignation, at what they considered suboptimal care given by us the managing team to the fatal one in the two cases reported. This has to do with the delay in procuring the required diagnostic brain computed tomography (CT) scan which when eventually done revealed an otherwise salvageable AEDH. The young victim had walked into and talked in the hospital at admission. He was GCS 14/15. The said reviewers' outrage, by no means offensive to us, compelled us to do this editorial. It is an attempt to put things in their practical perspective, against the backdrop of the health system in place at that time.

The prevalent health indicators in most developing countries, otherwise known as low-middle income countries (LMICs), and certainly in Nigeria, are still far below the minimum levels recommended globally.^[4,10] Hence, universal health coverage even for most basic human maladies is still something of a pipe dream in these impoverished regions of the world. The reasons for this dismal state are many but few salient ones include poor health infrastructures, extreme poverty among the population, inequality in access to health care, and dearth of qualified medical and paramedical personnel in the health systems.^[3,4,10] Important as these factors are, however, our on-the-field experience practicing neurological surgery, even subspecialized neurosurgery, skull base surgery, in an LMIC makes one to say without any equivocation that the most significant impediment to a tolerably adequate health care is the health care financing model that obtains in most developing countries.^[1] This model is the privately funded, out-of-pocket (OOP) settling of the bills for health care.^[4,10,12] It is also known as a payment at the point of service (POS), model. It is what is prevalent in most sub-Saharan African countries, including Nigeria.^[7,10,12] It is virtually a death-dealing solution for health system financing. It not only empties the pockets of the patients and their relations when most vulnerable, it is actually

said to push some 250 million people yearly in the developing countries to extreme poverty.^[7]

At present, although Nigeria is a major global crude-oil exporting nation of some 170 million people, most of her socioeconomic metrics are far from salutary.^[11] The minimum wage is a paltry 18,000 Nigerian Naira (60 USD) and more than half the people live below 2 USD a day. The health care system is also only organized on paper. With a highly dysfunctional health care pyramid, partly due to lack of qualified personnel, especially in the rural areas where majority of the population resides, the few University Teaching Hospitals, located as a rule in the urban centers, are daily inundated with human maladies of sheer imponderable proportions. These range from the mild, mundane (cold and catarrh, or "flu") to the severe-advanced stages of sundry systemic malignancies. On top of all these is a daily deluge of multisystem trauma, victims of the untrammelled carnage on the roads.

Thus, when a sick person, suffering from either a chronic illness or an acute/traumatic condition, comes from this poor hapless pool of people to the average Nigerian public hospital, he is likely to meet fairly self-well-motivated health care personnel (admittedly there are some few bad ones) whose salaries have been paid by the government subventions/grants. This is about the only significant contribution the government makes to the cost of his in-hospital health care: Payment of personnel salaries in the government hospitals. The patient or the relations however have to pay for every other aspect of their care including registration in the hospital records, laboratory/radiological investigations, ward admission costs, drugs, and in-hospital consumables including needles and syringes, and even swabs of cotton wool, and so on.^[9,10] He must also bear all the costs of the surgical/anesthetic care, OOP, be it minor procedures like incision and drainage of skin abscesses, or obstetric cesarean section, or complicated/exorbitantly expensive neurosurgical procedures.^[5,6,8,9,12] There are usually "indigents' funds" set apart, more so in the University Teaching Hospitals, for the care of the extremely poor

or for dire emergencies, but these are usually no more than few drops of water in the oceans of the compelling/competing demands. There are also some arrangements for payment deferments, whereby a sick person may be given all the in-hospital services desired, diagnostic and therapeutic, in lieu of payment later. But extreme poverty, making the eventual hospital bill too imponderable to bear to the victims, or just arrant mischief by those who are otherwise able but refuse to settle the hospital bills so incurred, also frustrate this measure many times.

However, the government-subsidized public general or University Teaching Hospitals are not the only players in the health care delivery. Indeed, they are not the major players in many developing countries.^[10] There are private health facilities who also attend to the health needs of the people.^[10] They are usually called private hospitals but most are not worth the name really. They are mere consulting clinics but they go as far as offering in-house medical and surgical inpatient services. Many lack the minimum basic tools for a college first-aid facility. This is especially so in the rural areas and the urban slums. Whatever they are, however, five-star health facilities or ramshackle structures ill-manned in the middle of nowhere, they are strictly for-profit ventures. They receive no government subvention whatever. If anything, they actually are required to pay significant administrative fees to the government. These fees, some of them unverifiable, are sometimes so exorbitant they actually raise the costs of doing these businesses, which cost would eventually be transferred to their clients.

Only very small proportion of such private health facilities dares to attempt treating anything neurosurgical. Even some of them that you would think appear well-furnished enough to try would rather refer a mild head injured, GCS 15, no neurological deficits, all other systems normal to the neurosurgeons in the academic centers. The result, many times, includes what have actually been considered needless referrals across hundreds of kilometers of dangerous national roads for the neurosurgical care of mild head injury in our practice.^[2]

In the as-yet crisis-ridden health system of Nigeria, however, there are times when even this not-too-good pattern breaks down. At the most extreme of such bad times, the public University Teaching Hospitals are completely shut down for months (hospital wards actually gather dusts and cobwebs) by industrial conflicts and stalemates called by one or a group of the health workers' unions. Some neurosurgical patients, even with severe head injury and complex brain tumors, would then end up in some of these private clinics, who would have no option but to take them in. These are usually a few of these health facilities that have some basic requirements for life-saving surgical treatments. It is needless to say however that only the upper middle class and above are

the ones able to bear the cost of care in these private entities.

It is in one such facility that the drama told in the tale of two AEDHs took place in Ibadan, Nigeria. But the impression we are compelled to not let the reviewers get away with is that any of the health care workers, physicians, and all involved in that frontline battle experience failed to live up to their professional calling in any way. If anything, they actually put way, way beyond their calling into those cases. It is just that the socioeconomic limitations of the health care system of this typical developing country failed us in the first case, and only barely salvaged the second.

The outrage of some of the reviewers to that tale, as it pertains to the tragic loss of the first patient is therefore understandable. It is the same with us. Indeed, it is the reason we told this tragic (we never intended it a comic) tale. There was a total, some 3-month-or-so-long, breakdown of health care in the country's university public teaching hospitals, one of which we work in. This was due to a protracted strike action by some hospital workers' union and it was a most disheartening situation.

There being nowhere else to go in that extreme situation, the patients ended up in this one private hospital, somewhat abler to offer the basic resuscitative care needed for such patients. The physicians there knew they had the benefit of the cover of an academic neurosurgeon (myself) in a nearby University Teaching Hospital, in the same metropolis. They had had the benefits of consulting with me in similar situations in the past. Moreover, we have together pulled off some highly gratifying miraculous feats saving near-death situations on some of those occasions. They quickly reviewed the traumatic brain injury cases in that tale; appropriately requested brain CT imaging for them, and waited for the relations to raise the funds to procure these tests.

Two salient points are necessary at this juncture. One, this hospital although a private, for-profit venture, actually was giving all the initial in-hospital care to the patients without yet demanding for payments, indeed waiving most of it. Two, CT scanner was not available in this hospital, could only be procured in another private imaging center in another part of the town. Even this imaging center opened shop only a couple of months earlier. It was the search by the patients' relation for the funds to take to this other facility, the imaging center, for the brain CT that caused the fatal delay at issue in the first case of that tale. And even when the brain CT was eventually procured, the for-profit private hospital put so much of its resources down, no payment insisted on, to help facilitate the possible surgical cure. They got a neurosurgeon, who got all OR teams, (anesthetic and nursing) all mobilized to site, no fee demanded yet, to,

albeit sadly much belatedly, try salvage a most desperate situation. Surely, these workers should not be the subject of this justifiable outrage, but the health system of the country concerned at that time.

Curiously, and most dramatically, a pretty much identical situation (please take another look at the brain CT images of the two cases) repeated itself in the same health facility in just 24 h later, but this time with a more positive outcome. And the difference? Just one of the points being made: The relations of the second patient were a little more fortunate, somewhat more financially able to pay for the same neuroimaging faster than the first. Even so, the costs of the surgical care, operative/perioperative and administrative, of this salvaged case also had to be waived by this hospital for the life-saving surgery to take place in the middle of the night. These hospital bills were settled by the relations only months later, and that only instalmentally.

One is therefore compelled to assert that the fatal delay in obtaining the life-saving neuroimage for the first case surely has nothing to do, except one be sorely mistaken, with the treating hospital. They did not own this imaging facility. They could not be expected to take their own money to go pay for imaging study in another section of the town for the same patient they already were treating, as-yet for free, in their own facility!

This is indeed the reason we wrote that report. It was our own outrage at an inhuman health system that is modeled after a POS financing, for a population of people majority of which live below the poverty line.^[11,12] We were not enthused, a bit, about this case.

It is therefore hoped that cases like the ones in the said tale would compel a global rethink, actually a revolution, in the way the health care needs of the LMICs are addressed. That the OOP payment for health care model is too inhuman a health financing solution to last another decade in any region of the world.^[6,12] And our own penny-worth opinion for a start is that an emergency

be declared, calling for the World Health Assembly if necessary, to undertake, forthwith, a holistic diagnostic evaluation and treatment of this neglected disease of the health systems of most developing countries.

Dr. A. Olufemi Adeleye

Department of Neurological Surgery, University College Hospital,
UCH, Ibadan, Nigeria.
E-mail: femdoy@yahoo.com

REFERENCES

1. Adeleye AO, Fasunla JA, Young PH. Skull base surgery in a large, resource-poor, developing country with few neurosurgeons: Prospects, challenges, and needs. *World Neurosurg* 2012;78:35-43.
2. Adeleye AO, Okonkwo DO. Inter-hospital transfer for neurosurgical management of mild head injury in a developing country: A needless use of scarce resources? *Indian J Neurotrauma* 2011;8:1-6.
3. Adewole DA, Adebayo AM, Udeh EI, Shaahu VN, Dairo MD. Payment for health care and perception of the national health insurance scheme in a rural area in Southwest Nigeria. *Am J Trop Med Hyg* 2015;93:648-54.
4. Adewole DA. The impact of political institution and structure on health policy making and implementation: Nigeria as a case study. *Afr J Med Med Sci* 2015;44:101-5.
5. Dienye PO, Brisibe SF, Eke R. Sources of healthcare financing among surgical patients in a rural Niger Delta practice in Nigeria. *Rural Remote Health* 2011;11:1577.
6. Ir P, Bigdeli M. Removal of user fees and universal health-care coverage. *Lancet* 2009;374:608.
7. Kim JY, Chan M. Poverty, health, and societies of the future poverty, health, and societies of the future view point. *JAMA* 2013;310:901-2.
8. Mansouri A, Ibrahim GM. Moving forward together: The lancet commission on global surgery report and its implications for neurosurgical procedures. *Br J Neurosurg* 2015;29:751-2.
9. Raykar NP, Bowder AN, Liu C, Vega M, Kim JH, Boye G, et al. Geospatial mapping to estimate timely access to surgical care in nine low-income and middle-income countries. *Lancet* 2015;385 Suppl 2:S16.
10. WHO Global Health Observatory: World Health Statistics; 2013. Available from: http://www.who.int/gho/publications/world_health_statistics/en/index.html. [Last accessed on 2013 Nov 26].
11. World Bank, Nigeria: The World Development Indicators; 2013. Available from: <http://www.data.worldbank.org/country/Nigeria>. [Last accessed on 2013 Nov 28].
12. Yates R. Universal health care and the removal of user fees. *Lancet* 2009;373:2078-81.