

Case Report

CT-negative, MRI GRE-positive primary motor cortex contusion causing isolated foot drop

Alexander M. Tucker, Tianyi Niu, Daniel T. Nagasawa, Richard Everson, Shaina Sedighim, Manuel M. Buitrago Blanco

Department of Neurosurgery, University of California-Los Angeles, Los Angeles, California, USA

E-mail: *Alexander M. Tucker - ATucker@mednet.ucla.edu; Tianyi Niu - TNiu@mednet.ucla.edu; Daniel T. Nagasawa - DNagasawa@mednet.ucla.edu; Richard Everson - REverson@mednet.ucla.edu; Shaina Sedighim - ssedighim@gmail.com; Manuel M. Buitrago Blanco - mblanco@mednet.ucla.edu
*Corresponding author

Received: 09 June 16 Accepted: 24 June 16 Published: 09 November 16

Abstract**Background:** Isolated acute foot drop due to traumatic brain injury is exceedingly rare and is often misdiagnosed during initial evaluation. Here, we present the case of a patient who presented with left foot drop after falling off a bicycle.**Case Description:** The patient is a 55-year-old male who was mountain biking when he fell, hit his head, and lost consciousness. Neurologic examination of the left leg revealed foot drop, no sensory deficits, and 3+ reflexes at the knee and ankle with clonus. Electroencephalography, computed tomography (CT) of the head, magnetic resonance imaging (MRI) of the lumbar spine, and CT of the lower extremities were all negative. Only MRI of the brain with a gradient echo sequence revealed microhemorrhages focused around the right precentral gyrus. The patient underwent physical therapy, and by 3 months had regained full strength in his left leg.**Conclusion:** Central causes of foot drop are exceptionally rare, however, they should be considered in all cases of post-traumatic dorsiflexion paresis. The key to the accurate diagnosis is a high index of suspicion as well as thorough and careful physical examination including reflex and sensory testing. Selective imaging modalities such as MRI or CT can then be used to verify the diagnosis.**Key Words:** Computed tomography, contusion, foot drop, motor cortex, magnetic resonance imaging, traumatic brain injury**Access this article online****Website:**www.surgicalneurologyint.com**DOI:**

10.4103/2152-7806.193727

Quick Response Code:**INTRODUCTION**

Post-traumatic acute foot drop is most commonly the result of direct peripheral nerve injury at the level of the fibular head or secondary to intervertebral disc herniation causing L5 nerve root compression.^[8,11] Traumatic injuries that involve the brain parenchyma of primary motor cortex often extend to adjacent areas and result in hemiplegia or paresis. Cases of isolated motor weakness in a distal extremity due to a concussive traumatic brain injury are rare and often misdiagnosed during initial evaluation.^[1] Other central causes of foot drop have been

described, including indolent cerebral and spinal tumors, penetrating injuries to the brain or spine, infection, metastases, and post-traumatic diffuse axonal injury.^[3,12]

This is an open access article distributed under the terms of the Creative Commons Attribution-NonCommercial-ShareAlike 3.0 License, which allows others to remix, tweak, and build upon the work non-commercially, as long as the author is credited and the new creations are licensed under the identical terms.

For reprints contact: reprints@medknow.com

How to cite this article: Tucker AM, Niu T, Nagasawa DT, Everson R, Sedighim S, Buitrago Blanco MM. CT-negative, MRI GRE-positive primary motor cortex contusion causing isolated foot drop. *Surg Neurol Int* 2016;7:S756-8.
<http://surgicalneurologyint.com/CT-negative,-MRI-GRE-positive-primary-motor-cortex-contusion-causing-isolated-foot-drop/>

Here, we present a patient who presented with left lower extremity weakness and isolated foot drop after falling off a bicycle. Work-up included a computerized tomography (CT) of the brain which was negative for acute injury and magnetic resonance imaging (MRI) of the brain which revealed a localized area of hemorrhagic contusion in the right precentral gyrus.

CASE HISTORY

A 55-year-old male was mountain biking and fell 15 feet, hitting his head and losing consciousness. Neurologic examination of the left leg revealed MRC

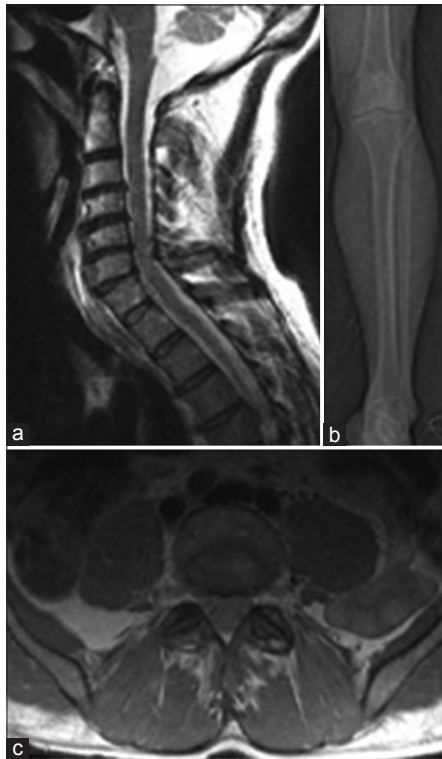

Figure 1: (a) Sagittal T2-weighted magnetic resonance imaging (MRI) showing degenerative spondylosis without significant cord compression. (b) Computed tomography scout image of left leg demonstrating fibular head without evidence of fracture. (c) Axial proton-density-weighted turbo spin echo MRI showing the L5 nerve roots exiting the spinal canal, no foraminal stenosis, or disc herniation

grade 2/5 strength of dorsiflexion (tibialis anterior), MRC grade 1/5 strength distally (extensor digitorum longus, extensor hallucis), no sensory deficits were noted (normal light touch, two-point discrimination, temperature and vibratory sensation modalities), 3+ tendon reflexes at the knee and ankle, and positive sustained clonus. He reported a headache, but was oriented to name, place, and date. Upon work-up, electroencephalogram (EEG) showed no evidence seizures, CT of the head showed no ischemia or hemorrhage, and MRI of the lumbar spine was negative for acute pathology [Figure 1]. However, a gradient echo sequence (GRE) of MRI of the brain revealed a discrete area of microhemorrhage centered in the right precentral gyrus [Figure 2]. The patient received a 1 week course of levetiracetam (Keppra) for seizure prophylaxis and underwent 3 weeks of targeted physical therapy, both during his acute hospitalization and after discharge. At the 3 month follow-up, he regained complete, MRC grade 5/5, strength throughout all left lower extremity muscle groups.

DISCUSSION

Foot drop or dorsiflexion paresis is typically the result of a lower motor neuron injury, such as a lumbar 4-5 disc herniation or a common peroneal nerve injury at the fibular head.^[2] In cases of discogenic foot drop, patients often report additional pain in their back, posterior thigh, calf, and foot (L5 radiculopathy). Similarly, common peroneal neuropathy can result in referred pain to the hip or ankle and mimic radiculopathy; although a detailed history and physical exam can generally reveal the pain to be nondermatomal. Those patients, however, generally do not possess exam findings including hyperreflexia or clonus. Isolated unilateral dorsiflexion weaknesses secondary to an intracranial lesion is exceedingly rare and has only been reported in a small number of case reports.^[3,10,12,13]

Despite a low prevalence, we believe that central etiologies of foot drop must be included in the differential diagnosis of all patients presenting with head trauma and unilateral lower extremity weakness. When examining such patients, particular attention should be paid to upper

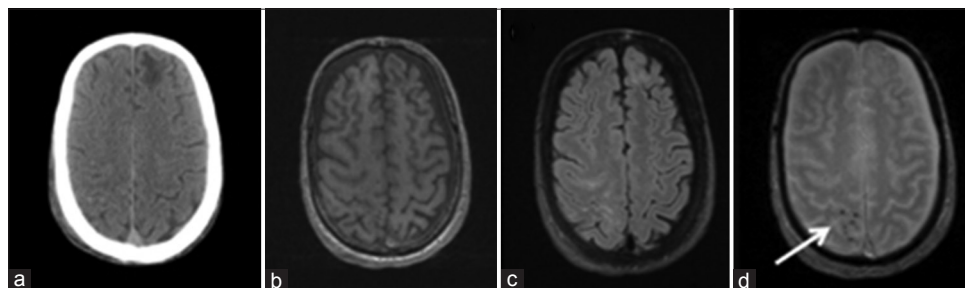


Figure 2: (a) Computed tomography showing chronic left frontal encephalomalacia, but no acute intracranial blood. (b) T1-magnetization prepared rapid gradient echo unremarkable. (c) Fluid-attenuated inversion recovery revealing right frontoparietal hyperintensity. (d) T2-gradient recall echo showing punctate pre and post-central intraparenchymal hemorrhage (white arrow)

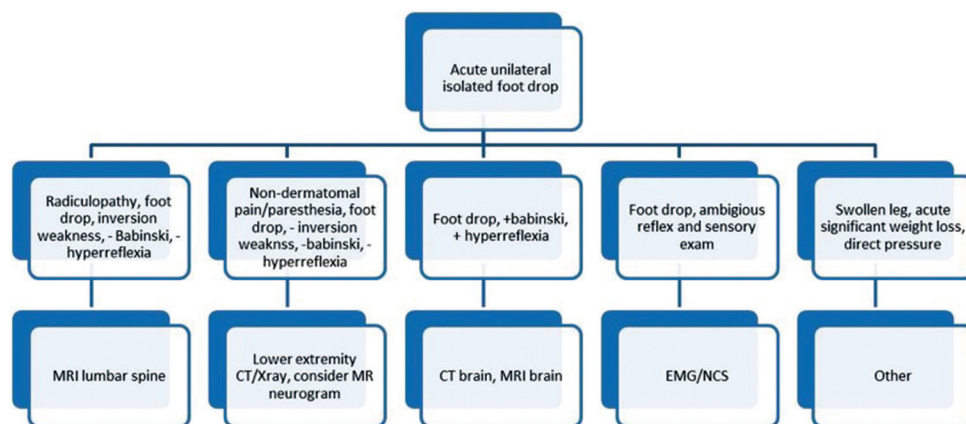


Figure 3: Diagnostic workup algorithm for patients with acute unilateral isolated foot drop. Decisions regarding the appropriate imaging/testing modality are guided primarily by physical examination findings (second row)

motor neuron signs; Babinski's sign, hyper-reflexia, and clonus. A detailed sensory exam should also be carefully conducted to determine the existence of sensory changes within a dermatomal distribution. In individuals with clear discogenic or peroneal etiology, MRI of the lumbar spine or CT of the lower extremity in question should be readily obtained to establish the correct diagnosis and treatment. If these imaging studies are nondiagnostic, electrophysiologic studies and cranial evaluation should be considered.

Although the quality of CT imaging of the brain continues to advance, MRI remains the most sensitive neurodiagnostic imaging modality for the evaluation of intracranial hemorrhage.^[7,9] MRI, particularly GRE/susceptibility weighted imaging (SWI) sequences, is more sensitive to heme-products than CT and often necessary to accurately diagnose discrete traumatic parenchymal injuries.^[5] However, the speed, relative lower cost, and availability of CT makes it the ideal screening tool for traumatic injury. In patients for whom the etiology of symptoms remains dubious following appropriate neuroimaging, electromyography and nerve conduction studies can be of valuable assistance [Figure 3].

Other rare causes of foot drop include deep venous thrombosis, rapid weight loss after bariatric surgery, severe diabetic neuropathy, Hansen's disease, nerve compression during sleep, surgery, or while in stirrups during gynecologic procedures, as well as orthopedic injuries such as hip dislocation, acetabular fractures, proximal fibular fractures, or tight plaster casts.^[4,6]

CONCLUSION

While central causes of foot drop are exceptionally rare,^[14] it is important for all clinicians to include them in the differential diagnosis of lower extremity weakness. Here, we present a case of unilateral foot drop in a traumatic brain injury patient, as well as our recommended diagnostic algorithm. In trauma cases, where the etiology of lower extremity weakness is unclear, MRI with a GRE/

SWI sequence should be considered because it may provide greater visualization of small hemorrhages than CT alone.^[9]

Financial support and sponsorship

Nil.

Conflicts of interest

There are no conflicts of interest.

REFERENCES

- Atac K, Ulas UH, Erdogan E, Gokcil Z. Foot drop due to cranial gunshot wound. *Mil Med* 2004;169:568-9.
- Baima J, Krivickas L. Evaluation and treatment of peroneal neuropathy. *Curr Rev Musculoskelet Med* 2008;1:147-53.
- Djekidel M, Harb W. A case of foot drop as an expression of brain metastases? *Neurologist* 2006;12:274-5.
- Elias WJ, Nader P, Oskouisan RJ, Schirmer B, Burns T. Peroneal neuropathy following successful bariatric surgery. *J Neurosurg* 2006;105:631-5.
- Fazekas F, Kleinert R, Roob G, Kleinert G, Kapeller P, Schmidt R, et al. Histopathologic analysis of foci of signal loss on gradient-Echo T2*-weighted MR images in patients with spontaneous intracerebral hemorrhage: Evidence of microangiopathy-related microbleeds. *AJNR Am J Neuroradiol* 1999;20:637-42.
- Fukada H. Bilateral peroneal nerve palsy caused by intermittent pneumatic compression. *Int Med* 2006;45:93-4.
- Gentry LR, Godersky JC, Thompson B. MR imaging of head trauma: Review of the distribution and radiopathologic features of traumatic lesions. *AJR Am J Roentgenol* 1988;150:663-72.
- Katirji MB, Wilbourn AJ. Common peroneal mononeuropathy: A clinical and electrophysiologic study of 116 lesions. *Neurology* 1988;38:1723-8.
- Kidwell CS, Chalela JA, Saver JL, Starkman S, Hill MD, Demchuk AM, et al. Comparison of MRI and CT for detection of acute intracerebral hemorrhage. *JAMA* 2004;292:1823-30.
- Oktem NB, Tari R, Kotil K, Bilge T. Cerebral contusion as a rare cause of foot drop: Case report. *Turk Neurosurg* 2012;22:99-101.
- Ozdemir N, Citak G, Acar UD. Spastic foot drop caused by a brain tumour: A case report. *Br J Neurosurg* 2004;18:314-5.
- Ozdemir N, Gelal MF, Oguzoglu S, Minoglu M. Unilateral acute foot drop due to diffuse axonal injury after head trauma. *J Clin Neurosci* 2008;15:1051-3.
- Ricarte IF, Figueiredo MM, Fukuda TG, Pedrosa JL, Silva GS. Acute foot drop syndrome mimicking peroneal nerve injury: An atypical presentation of ischemic stroke. *J Stroke Cerebrovasc Dis* 2014;23:1229-31.
- Westhout FD, Pare LS, Linskey ME. Central causes of foot drop: Rare and underappreciated differential diagnoses. *J Spinal Cord Med* 2007;30:62-6.