

## Original Article

## Safety of topical vancomycin powder in neurosurgery

Kalil G. Abdullah<sup>1</sup>, H. Isaac Chen<sup>2</sup>, Timothy H. Lucas<sup>1,2</sup><sup>1</sup>Department of Neurosurgery, Perelman School of Medicine, Hospital of the University of Pennsylvania, <sup>2</sup>Center for Neuroengineering and Therapeutics, University of Pennsylvania, Philadelphia, Pennsylvania, USAE-mail: \*Kalil G. Abdullah - [kalil.abdullah@uphs.upenn.edu](mailto:kalil.abdullah@uphs.upenn.edu); H. Isaac Chen - [isaac.chen@uphs.upenn.edu](mailto:isaac.chen@uphs.upenn.edu); Timothy H. Lucas - [timothy.lucas@uphs.upenn.edu](mailto:timothy.lucas@uphs.upenn.edu)

\*Corresponding author

Received: 02 February 16 Accepted: 28 March 16 Published: 05 December 16

**Abstract**

Surgical site infections (SSIs) remain an important cause of morbidity following neurosurgical procedures despite the best medical practices. In addition, hospital infection rates are proposed as a metric for ranking hospitals safety profiles to guide medical consumerism. Recently, the use of topical vancomycin, defined as the application of vancomycin powder directly into the surgical wound, has been described in both cranial and spinal surgeries as a method to reduce SSIs. Early results are promising. Here, we provide a concise primer on the pharmacology, bacterial spectrum, history, and clinical indications of topical vancomycin for the practicing surgeon.

**Key Words:** Cranial infection, spine infection, surgical site infection, vancomycin powder

## Access this article online

## Website:

[www.surgicalneurologyint.com](http://www.surgicalneurologyint.com)

## DOI:

10.4103/2152-7806.195227

## Quick Response Code:

**INTRODUCTION**

Surgical site infections (SSIs) adversely affect patients, providers, and hospitals. Despite the best practices of perioperative systemic antibiotics and sterile technique, SSIs persist. These adverse events, even in relatively low “acceptable” percentages, constitute a significant burden to clinical practice.

Beyond the obvious adverse consequences for patients and providers, SSIs are associated with significant cost and have been proposed as a metric to rank hospitals. These “safety rating” schemes pit hospitals and practices against one another without the benefit of contextual information, such as practice mix, patient demographics, and complexity of care.

It is incumbent upon practicing clinicians to reduce the incidence of SSI to the greatest extent possible. Further, surgeons must also be ready to counsel discerning patients who are increasingly savvy to the issue of hospital-acquired infections and SSI during preoperative visits. A growing body of literature surrounds the use of topical antibiotic administration as a surgical adjunct to

reduce SSI. Topical vancomycin has been examined in spine and, now recently, in cranial surgery. In this review, we summarize the pharmacology, bacterial spectrum, indications, and safety of topical vancomycin for practicing neurosurgeons.

**BASIC PHARMACOLOGY AND CLINICAL USE**

The compound, now known as vancomycin, was first isolated by Eli Lilly in soil samples collected from Borneo in 1953.<sup>[31]</sup> Produced by *Streptomyces orientalis*, compound “05865” was renamed vancomycin as a derivative of

This is an open access article distributed under the terms of the Creative Commons Attribution-NonCommercial-ShareAlike 3.0 License, which allows others to remix, tweak, and build upon the work non-commercially, as long as the author is credited and the new creations are licensed under the identical terms.

**For reprints contact:** [reprints@medknow.com](mailto:reprints@medknow.com)

**How to cite this article:** Abdullah KG, Chen HI, Lucas TH. Safety of topical vancomycin powder in neurosurgery. *Surg Neurol Int* 2016;7:S919-26. <http://surgicalneurologyint.com/Safety-of-topical-vancomycin-powder-in-neurosurgery/>

“vanquish” due to its ability to kill penicillin-resistant *Staphylococcus aureus*. Vancomycin is a glycopeptide produced by *Actinobacteria* (including *S. orientalis*). It is highly efficacious against Gram-positive bacteria,<sup>[32]</sup> such as *S. aureus*, which colonizes 20–30% of the population.<sup>[29]</sup> It acts as a bacteriocidal agent against most Gram-positive bacteria by inhibiting cell wall synthesis. Specifically, the glycopeptide bonds with moieties of the bacterial cell wall, thereby preventing cell wall elongation during cell division. Due in part to differences in the composition of the amino acid residues within the cell walls, this peptide blocks cell wall cross-linking in Gram-positive species, but not Gram-negative species.<sup>[21]</sup> Its antimicrobial spectrum covers *S. aureus*, *Streptococcus pneumoniae*, some enterococci, *Clostridium*, and *Actinomyces* as well as other less frequently encountered bacteria.

Resistance to vancomycin among enterococci colonies was first reported in the mid-1980s, with strains of *S. aureus* reported as either resistant (e.g., vancomycin-resistant *S. aureus* [VRSA]) or intermediately susceptible to vancomycin (e.g. vancomycin intermediate *S. aureus* [VISA]) in the late 1990s.<sup>[24]</sup> Among staphylococcal species, vancomycin’s minimal inhibitory concentration (MIC) determines its antibiotic sensitivity. An MIC between 4 and 8 µg/mL is considered an intermediate sensitivity bacterial strain. Strains with higher MIC’s are considered resistant. While the exact mechanism is unclear, resistance is thought to reflect a thickening of the bacterial cell wall.<sup>[12,24]</sup> This is a result of poor peptidoglycan cross-linking and an excess of the D-alanine termini precursors, which are the main peptidoglycan targets of vancomycin.<sup>[42]</sup> The drug then binds to these termini and is prevented from diffusing across the cell wall.<sup>[39]</sup> Between 2002 and 2011, only 12 cases of VRSA were reported in the United States, and none were thought to result from human-to-human transmission.<sup>[23]</sup> *Staphylococcus* resistance is hypothesized to have been acquired from concurrent host colonization by vancomycin-resistant enterococci (VRE) that possessed the *Van* gene. With passage of this gene to *S. aureus*, a change in the D-alanine precursor units occurs which prevents vancomycin’s peptidoglycan polymerase and transpeptidation reactions.<sup>[39]</sup>

Specific guidelines for vancomycin use are hospital-specific and tailored to the antibiotic spectrum and susceptibilities of the local patient population by hospital infection control programs. The Centers for Disease Control (CDC) provides guidance for the prevention of healthcare-associated infections (including SSI).<sup>[10]</sup> The Hospital of the University of Pennsylvania provides the following indications for the specific use of vancomycin based on these recommendations [Table 1].

Vancomycin has not received widespread adoption as a first-line treatment for infections despite its

**Table 1: Recommendations for the use of vancomycin at The Hospital of the University of Pennsylvania based on CDC recommendations**

Recommendations
The treatment of culture-proven serious infections caused by beta-lactam resistant microorganisms (e.g. methicillin resistant <i>S. aureus</i> , coagulase negative <i>staphylococcus</i> )
The treatment of culture proven infections caused by gram-positive organisms in patients with allergies to beta-lactam antimicrobials
The treatment of antibiotic-associated colitis that fails to respond to metronidazole or is potentially life threatening
Empiric therapy for serious infections in patients who are hemodynamically unstable
Empiric therapy in patients who are at risk for gram-positive infections with beta-lactam resistant microorganisms
Empiric therapy for suspected serious invasive infections caused by <i>Streptococcus pneumoniae</i> pending antimicrobial susceptibilities (e.g. meningitis)
Surgical prophylaxis for procedures involving implants of prosthetic materials or with serious allergies to beta-lactam antimicrobials. If these procedures last >6h, an additional dose is recommended
Prophylaxis for bacterial endocarditis as recommended by the American Heart Association

efficacy. This is due, in part, to the fact that has very poor bioavailability. No appreciable absorption occurs through the gastrointestinal system following oral administration. This aids in the treatment of *Clostridium difficile* infections which are sequestered in the gut. All other infections, however, require parenteral administration. Following infusion, the half-life of the drug is tri-exponential: The half-lives of the initial phase, second phase, and terminal phase are 7 min, 0.5–1 h, and 3–9 h, respectively.<sup>[35]</sup> It is the second phase half-life which governs the surgical recommendation of administering preoperative vancomycin 0.5–1 h before incision. An infusion of 1 g intravenous vancomycin creates a serum concentration that reaches a therapeutic window (15–30 µg/mL).<sup>[2]</sup> Approximately 80% of the drug is excreted by the kidney by glomerular filtration within 1 day. To maintain a stable concentration of peripheral drug levels and reach an effective MIC, redosing is necessary at 12 h intervals.<sup>[13]</sup> Vancomycin guidelines have been established based on the relationship between serum concentrations and treatment success against *S. aureus*. The consensus agreement between the Infectious Diseases Society of America, the American Society of Health System Pharmacists, and the Society of Infection Diseases Pharmacists was published in 2009.<sup>[40]</sup> Based on these guidelines, the committee established a primary predictive pharmacodynamics parameter for the efficacy of vancomycin against *S. aureus* infections. This parameter normalizes the concentration-independent activity of vancomycin against *S. aureus* (measured with the area under the concentration curve) against MIC. A target

AUC/MIC of 400 was recommended. The committee concluded that the potential benefit of increasing drug dosage was worth the risk of potential adverse effects, which are predominantly reversible.

Neurosurgeons encounter patients with infections within the cerebrospinal fluid (CSF). Vancomycin levels within the CSF levels are highly variable following parenteral administration. In general, they peak at <30% of the serum concentration. Accordingly, treating CSF-based infections requires higher systemic dosing.<sup>[13]</sup> Intrathecal vancomycin is safe and effective at treating CSF infections<sup>[11,36]</sup> but requires a ventricular drain or other direct intrathecal access.

### Systemic toxicity

The available toxicity data of this drug are primarily related to end-organ effects following parenteral administration. Vancomycin is well tolerated with appropriate dosing. The overall incidence of side effects is approximately 10%.<sup>[13]</sup> Common side effects are easily recognizable. The most apparent is “red man syndrome,” a nonimmune hypersensitivity reaction, mediated by direct histamine release within minutes of administration. The syndrome presents with generalized erythema, tachycardia, pruritis, and maculopapular rash. In cases of profound vasodilation, it may evolve into hypotensive shock.<sup>[2]</sup>

Management consists of discontinuation of the drug and administration of antihistamines, systemic steroids, intravenous fluids, and epinephrine as needed. More gradual administration of the drug over an hour may reduce to likelihood of red man syndrome. More common side effects include thrombophlebitis, fever, rash, and reversible neutropenia.<sup>[37]</sup>

Ototoxicity and nephrotoxicity are considered more serious, but rare, complications of vancomycin use. In limited studies, these hair cells appear to be sensitive to vancomycin. A study of vancomycin ear droplets showed an association between direct application of the compound and increased thresholds for high-frequency auditory detection.<sup>[7,44]</sup> Ototoxicity appears to be mediated by the peripheral effect of vancomycin on the cochlear hair cells.<sup>[2]</sup> Similarly, vancomycin-induced nephrotoxicity appears to be mediated by reactive oxygen species created within glomeruli following prolonged high-dose exposure (i.e. >4 g/day) with high serum concentrations (i.e., trough level >20 mg/L).<sup>[37]</sup>

In both instances of end-organ damage, hair cells and renal glomeruli, host susceptibility appears to be a factor. Older patients predisposed to high-frequency hearing loss are most susceptible to vancomycin-related ototoxicity, and patients with preexisting renal dysfunction or concurrent nephrotoxic medications are most susceptible to further renal injury.<sup>[37]</sup>

## TOPICAL APPLICATION OF VANCOMYCIN

### Historical precedent

The concept of direct application of antibiotics to surgical wounds has a long history. Over 60 years ago, surgeons experimented with antibiotic irrigation as a means to cleanse the wound. Subsequent decades witnessed significant decreases in SSIs with the routine application of antibiotic irrigation, laying the historical foundation for the modern practice of antibiotic irrigation in most operating rooms.<sup>[22]</sup> In 1958, British neurosurgeon Gibson found that the application of aerosolized neomycin, bacitracin, and polymixin during opening and closing reduced his infection rate from 7.2% to 0.4% in 480 consecutive cases.<sup>[19]</sup>

In its current formulation, topical vancomycin was first used in 1989 by cardiac surgeons applying the drug to the cut bone edges after sternotomy. In a randomized, controlled investigation, topical vancomycin significantly reduced infections when compared to a hemostatic placebo.<sup>[46]</sup> This was followed by additional investigations in both humans and animals for its use in cardiac surgery, and concurrent investigations into the use of bone and cement vehicles to release vancomycin for orthopedic use.<sup>[6,14,27,28,33,38,41,45]</sup> The use of topical vancomycin in spine surgery has been studied extensively and reported excellently in detail elsewhere.<sup>[4,25]</sup> In brief, pooled clinical data across randomized controlled trials and a number of case series confirm the safety and use of vancomycin to prevent SSIs in the setting of instrumented spinal fusion. The odds ratio of developing deep infection in the setting of vancomycin was 0.23 times the odds of infection without it (95% confidence interval 0.11–0.50,  $P < 0.05$ ).<sup>[4]</sup>

The use of topical vancomycin has only recently been extended to cranial surgery.<sup>[1]</sup> This use was supported on the well-documented safety profile of use of vancomycin in the setting spinal surgery, as well as intrathecal use in the setting of CSF infection.<sup>[11,36]</sup> Beyond its safe application in other neurosurgical indications, vancomycin is a logical choice for a topical antibiotic in cranial wounds as 75–85% of cranial infections are induced by Gram-positive bacteria.<sup>[11,18]</sup> Our group retrospectively examined 75 consecutive craniotomies receiving vancomycin powder applied to the bone flap at the time of closure.<sup>[1]</sup> Compared to 75 matched controls, vancomycin was associated with a 5% drop in infection rate from 6.7% to 1.3% with no adverse events related to the drug. No adverse events were identified related to drug use in cranial surgery.

These findings have motivated a prospective randomized controlled trial on cranial vancomycin use to provide Class I evidence on the matter.



**Figure 1: Vancomycin powder before placement into a cranial wound**

### Vancomycin powder - physical properties

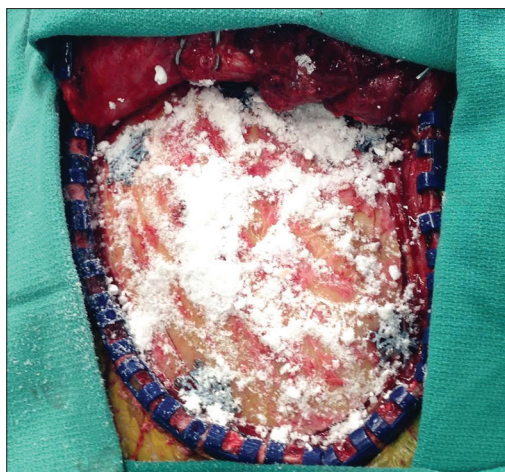
In crystallized form, vancomycin exists as vancomycin hydrochloride. This “powder” is supplied by pharmaceutical companies in a sterile vial and has the consistency of household baking soda [Figure 1]. The powder is sprinkled liberally over subfascial or suprafascial space.<sup>[25]</sup> In cranial surgery, the powder is applied directly to the bone flap in the subgaleal space [Figure 2]. In spine instrumentation cases, the powder is applied over the instrumentation.<sup>[9,26,43]</sup> In other cases, such as the implantation of baclofen pumps, the powder is applied directly over the device before closure.<sup>[18]</sup>

Cost is an important consideration. A 1 g vial of vancomycin hydrochloride has a direct cost between \$2 and \$12 for most institutions.<sup>[16,20,43]</sup> The cost of infection, conversely, can be exorbitant. Emohare *et al.* found that patients who experienced deep (subfacial) infections following spinal surgery incurred an average additional cost of >\$500,000.<sup>[16]</sup> In 2013, Godil *et al.* examined 110 patients treated with instrumented fusions following traumatic spine injuries. They found that use of vancomycin powder led to a significant reduction in infection rate (13% vs. 0%,  $P < 0.05$ ). Their estimated cost per patient for treatment of a postoperative infection was \$33,705, and their estimated cost savings was \$438,165 per 100 posterior spinal fusions. Available data strongly suggest that vancomycin usage may have important financial and socioeconomic benefits for both spinal and cranial neurosurgeries.

## SAFETY CONSIDERATIONS

### Local side effects following topical administration

Vancomycin is crystallized as a salt with hydrochloride. This preparation results in hydrogen ion disassociation in solution. When mixed with interstitial fluid or saline, the resultant pH varies with the volume of solution. Accordingly, wound pH has been monitored in a number of studies using wound drains to measure fluid acidity.<sup>[1,3]</sup>



**Figure 2: Placement of vancomycin powder above below the galea and above the craniotomy flap**

In cranial wounds, we noted that the wound fluid pH sampled from subgaleal space was within physiological range within an hour of the wound closure.<sup>[1]</sup> The local wound fluid appears to rapidly buffer any pH shift. In a pediatric population, Armaghani *et al.* examined the levels of vancomycin in local drains over several days and found that the levels of vancomycin in the wound dropped from 403  $\mu\text{g/mL}$  postoperatively to 115  $\mu\text{g/mL}$  on day 2.

Parental administration of vancomycin is associated with phlebitis at a rate of 0–18%.<sup>[8,30]</sup> Purported mechanisms of this venous reaction include irritation due to pH and direct endothelial cell toxicity.<sup>[15]</sup> Drouet *et al.* quantitated the lethal dose 50 (LD50) of vancomycin on endothelial cultures and found a dose- and time-dependent relationship. Toxicity was most pronounced at 48 and 72 h of continuous drug exposure above concentrations of 2.5 mg/mL. At 24 h of continuous infusion, LD50 was 5 mg/mL. In addition, pH itself did not have an independent effect on endothelial cell toxicity.<sup>[15]</sup> These levels in the study by Drouet are significantly higher than wound drain concentrations in the hours following clinical application.

No direct adverse effects of vancomycin were noted in the only published study in cranial surgery.<sup>[1]</sup> Vancomycin may be well suited for craniotomy indications as it has excellent safety precedent with intrathecal use.<sup>[11]</sup> At doses of 10 mg applied directly into the ventricular system concurrent with 1 g administered systemically, Chen *et al.* noted no adverse events (e.g., seizures, ototoxicity, nephrotoxicity). Further, pH and the osmotic pressure of CSF remained unchanged before and after administration. CSF concentrations following combined intraventricular and systemic administration peaked at  $3.8 \pm 4.2$  mg/mL at 0.25 h. Concentrations fell to  $0.15 \pm 0.11$  mg/mL at 12 h. There were no significant changes in CSF pH across the multiple time points in the study. These data suggest that vancomycin is safe in appropriate dosages for intradural and extradural applications at the studied dose ranges.

## Systemic side effects following topical administration

Systemic effects of topical vancomycin application have been most extensively studied in spinal surgery. Of the >2000 of vancomycin administration during spine surgery in the past several years, only two complications directly attributable to vancomycin application were reported, to the best of our knowledge.

These isolated case reports failed to meet inclusion criteria for the meta-analysis cited above and were therefore not included. Mariappan *et al.*<sup>[34]</sup> reported the case of a 52-year-old female undergoing a T10 vertebrectomy and fusion who experienced circulatory collapse following the application of vancomycin. During closure, the patient experienced tachycardia and a rapid drop in blood pressure. The vital signs normalized with supportive treatment during the event. The authors speculated that the patient experienced an anaphylactic reaction related to the application of 2 g of vancomycin powder in a small patient (45 kg). Additional contributing factors included of 2 L of acute blood loss, administration of colloids, red blood cells, and fresh frozen plasma during the vertebrectomy. These mitigating circumstances prevent objective validation that the hypotension was related to the antibiotic. In the second case,<sup>[47]</sup> a recurring seroma was noted in a patient who underwent multilevel anterior and posterior lumbar fusion for traumatic sacral fractures. The authors suggest that the recurrent seroma resulted from local hypersensitivity to vancomycin powder. Again, mitigating circumstances raise questions about any causality.

## Peripheral levels of vancomycin and antibiotic resistance

The use of antibiotics carries the incumbent risk of antibiotic resistance. Vancomycin-resistant strains of *Enterococcus*, for example, may colonize the intestine. For this reason, CDC generally advises against the routine use of vancomycin in irrigation solutions. To examine whether vancomycin penetrates the systemic circulation following topical application, serum levels of vancomycin have been measured. Following cranial application of 1 g in adults, serum vancomycin levels remain undetectable at numerous time points following surgery.<sup>[1]</sup> Serum vancomycin levels fail to reach clinically relevant levels even in pediatric patients with a mean body weight of only  $44.5 \pm 18$  kg.<sup>[3]</sup> Serum levels dropped from 2.5 to 1.1  $\mu\text{g/mL}$  over 3 days. By comparison, serum levels of 25  $\mu\text{g/mL}$  are considered toxic while the lower bound of detection at most clinical laboratories is 2.5  $\mu\text{g/mL}$ .<sup>[5]</sup>

Naturally, the question of antibiotic resistance must be considered when introducing additional prophylactic antibiotic exposure. Data on antibiotic resistance to vancomycin suggest that overuse of vancomycin alone does not breed vancomycin resistance. Vancomycin-resistant strains (VRSA) have been found only to occur in the

presence of a coinfection of enterococci.<sup>[23]</sup> In these cases, the bacterial resistance is mediated by a coinfection, and not as a result of vancomycin use alone. Strains that are intermediately resistant (VISA) are only resistant to concentrations between 4 and 8  $\mu\text{g/mL}$ . When vancomycin is applied directly to the wound, the intra-wound and drain concentrations are substantially high enough to be effective against intermediately resistant strains. This would suggest that given local drain concentrations of vancomycin in the range of 200–300  $\mu\text{g/mL}$ , persistent infection with a VISA strain is unlikely. In addition, without a very specific coinfection (which is itself rare), increased vancomycin resistance is unlikely to occur as a result of increasing topical vancomycin use.

The available evidence suggests that topical vancomycin significantly reduces the incidence of SSIs. Due to the peptide's selective action against Gram-positive cell wall assembly, one might logically hypothesize that the Gram-negative bacterial flora would account for a higher proportion of subsequent SSIs. While this question has not been rigorously examined in a prospective trial, Ghobrial *et al.*<sup>[17]</sup> attempted to answer this question in a retrospective case series by comparing wound cultures from spinal SSIs in a cohort of patients receiving topical vancomycin. These data were compared to historical controls accrued before the enrollment of the vancomycin cohort. There was no difference in the proportion of Gram-positive wound cultures in vancomycin and historical controls (86.3% vs. 80.1%,  $P = 0.446$ ). Similarly, the proportion of polymicrobial infections was no different (15% vs. 17%,  $P =$  not significant). Only one case of VRE was noted in vancomycin group (1/51) while there were five cases in the control group (5/57). This difference did not reach significance ( $P = 0.12$ ). Confirming their original hypothesis, the proportion of Gram-stain-negative organisms was higher in the vancomycin group (60.7% vs. 21%,  $P < 0.0001$ ). These bacterial species were most commonly *Escherichia coli*, *Klebsiella pneumoniae*, and *Proteus* in vancomycin group. The species from the 12 Gram-negative cases in the control group were not disclosed. The conclusions that can be drawn from these data, however, are limited. The lack of data concerning bacterial sensitivities, preoperative antibiotics, postoperative antibiotics exposure, treatment antibiotics, and accrual of nonoverlapping patient cohorts make it difficult to weigh the findings. Accordingly, the significance of the increase prevalence of Gram-negative flora within SSI is indeterminate. As the use of topical vancomycin in neurosurgical cases increases, additional data will shed light on this important issue.

## CONCLUSIONS

Vancomycin is a well-established antibiotic against Gram-positive bacterial strains. Its use in spine surgery,

and recently cranial surgery, provide convincing evidence that vancomycin is safe in neurosurgical procedures. SSI's are reduced when it is applied in addition to standard antibiotic prophylaxis. Known side effects associated with parenteral administration do not appear to occur when the drug is applied topically into a surgical wound. There is insufficient evidence to suggest that routine single-use vancomycin powder leads to antibiotic resistance. Routine use of vancomycin powder as a surgical adjunct is supported by the available literature and warrants further examination in randomized controlled trials.

## Financial support and sponsorship

Nil.

## Conflicts of interest

There are no conflicts of interest.

## REFERENCES

- Abdullah KG, Attiah MA, Olsen AS, Richardson A, Lucas TH. Reducing surgical site infections following craniotomy: Examination of the use of topical vancomycin. *J Neurosurg* 2015;123:1600-4.
- Aoki FY. Principles of antimicrobial therapy and the clinical pharmacology of antimicrobial drugs. In: *Principles of Critical Care*. 3<sup>rd</sup> ed. New York: The McGraw-Hill Companies; 2005.
- Armaghani SJ, Menge TJ, Lovejoy SA, Mencia GA, Martus JE. Safety of topical vancomycin for pediatric spinal deformity: Nontoxic serum levels with supratherapeutic drain levels. *Spine (Phila Pa 1976)* 2014;39:1683-7.
- Bakhsheshian J, Dahdaleh NS, Lam SK, Savage JW, Smith ZA. The use of vancomycin powder in modern spine surgery: Systematic review and meta-analysis of the clinical evidence. *World Neurosurg* 2015;83:816-23.
- Beckman Coulter Incorporated: Emit 2000 vancomycin assay. OSR4W229; 2010.
- Bibbo C, Patel DV. The effect of demineralized bone matrix-calcium sulfate with vancomycin on calcaneal fracture healing and infection rates: A prospective study. *Foot Ankle Int* 2006;27:487-93.
- Black FO, Gianna-Poulin C, Pesznecker SC. Recovery from vestibular ototoxicity. *Otol Neurotol* 2001;22:662-71.
- Caparas JV, Hu JP. Safe administration of vancomycin through a novel midline catheter: A randomized, prospective clinical trial. *J Vasc Access* 2014;15:251-6.
- Caroom C, Tullar JM, Benton EG Jr., Jones JR, Chaput CD. Intra-wound vancomycin powder reduces surgical site infections in posterior cervical fusion. *Spine (Phila Pa 1976)* 2013;38:1183-7.
- Centers for Disease Control: Top CDC Recommendations to Prevent Healthcare-associated Infections; 2013. Available from: <http://www.cdc.gov/HAI/prevent/top-cdc-recs-prevent-hai.html>. [Last accessed on 2014 Dec 11].
- Chen K, Wu Y, Wang Q, Wang J, Li X, Zhao Z, et al. The methodology and pharmacokinetics study of intraventricular administration of vancomycin in patients with intracranial infections after craniotomy. *J Crit Care* 2015;30:218. e1-5.
- Cui L, Ma X, Sato K, Okuma K, Tenover FC, Mamizuka EM, et al. Cell wall thickening is a common feature of vancomycin resistance in *Staphylococcus aureus*. *J Clin Microbiol* 2003;41:5-14.
- Deck DH, Winston LG. Beta-lactam & other cell wall & membrane-active antibiotics. In: *Basic and Clinical Pharmacology*. 12<sup>th</sup> ed. New York: The McGraw-Hill Companies; 2012.
- Desmond J, Lovering A, Harle C, Djorevic T, Millner R. Topical vancomycin applied on closure of the sternotomy wound does not prevent high levels of systemic vancomycin. *Eur J Cardiothorac Surg* 2003;23:765-70.
- Drouet M, Chai F, Barthélémy C, Lebuffe G, Debaene B, Décaudin B, et al. Influence of vancomycin infusion methods on endothelial cell toxicity. *Antimicrob Agents Chemother* 2015;59:930-4.
- Emohare O, Ledonio CG, Hill BW, Davis RA, Polly DW Jr., Kang MM. Cost savings analysis of intrawound vancomycin powder in posterior spinal surgery. *Spine J* 2014;14:2710-5.
- Ghobrial GM, Thakkar V, Andrews E, Lang M, Chitale A, Oppenlander ME, et al. Intraoperative vancomycin use in spinal surgery: Single institution experience and microbial trends. *Spine (Phila Pa 1976)* 2014;39:550-5.
- Ghobrial GM, Thakkar V, Singhal S, Oppenlander ME, Maulucci CM, Harrop JS, et al. Efficacy of intraoperative vancomycin powder use in intrathecal baclofen pump implantation procedures: Single institutional series in a high risk population. *J Clin Neurosci* 2014;21:1786-9.
- Gibson RM. Application of antibiotics (polybactrin) in surgical practice, using the aerosol technique. *Br Med J* 1958;1:1326-7.
- Godil SS, Parker SL, O'Neill KR, Devin CJ, McGirt MJ. Comparative effectiveness and cost-benefit analysis of local application of vancomycin powder in posterior spinal fusion for spine trauma: Clinical article. *J Neurosurg Spine* 2013;19:331-5.
- Guglielmo BJ. Anti-infective chemotherapeutic & antibiotic agents. In: Papadakis MA, McPhee SJ, editors. *CURRENT Medical Diagnosis and Treatment*. New York: The McGraw-Hill Companies; 2014.
- Halasz NA. Wound infection and topical antibiotics: The surgeon's dilemma. *Arch Surg* 1977;112:1240-4.
- Hayakawa K, Marchaim D, Vidailac C, Lephart P, Pogue JM, Sunkara B, et al. Growing prevalence of vancomycin-resistant *Enterococcus faecalis* in the region with the highest prevalence of vancomycin-resistant *Staphylococcus aureus*. *Infect Control Hosp Epidemiol* 2011;32:922-4.
- Howden BP, Davies JK, Johnson PD, Stinear TP, Grayson ML. Reduced vancomycin susceptibility in *Staphylococcus aureus*, including vancomycin-intermediate and heterogeneous vancomycin-intermediate strains: Resistance mechanisms, laboratory detection, and clinical implications. *Clin Microbiol Rev* 2010;23:99-139.
- Khan NR, Thompson CJ, DeCuyper M, Angotti JM, Kalobwe E, Muhlbauer MS, et al. A meta-analysis of spinal surgical site infection and vancomycin powder. *J Neurosurg Spine* 2014;21:974-83.
- Kim HS, Lee SG, Kim WK, Park CW, Son S. Prophylactic intrawound application of vancomycin powder in instrumented spinal fusion surgery. *Korean J Spine* 2013;10:121-5.
- Kim HW, Knowles JC, Kim HE. Hydroxyapatite porous scaffold engineered with biological polymer hybrid coating for antibiotic Vancomycin release. *J Mater Sci Mater Med* 2005;16:189-95.
- Klekamp J, Dawson JM, Haas DW, DeBoer D, Christie M. The use of vancomycin and tobramycin in acrylic bone cement: Biomechanical effects and elution kinetics for use in joint arthroplasty. *J Arthroplasty* 1999;14:339-46.
- Kluytmans J, van Belkum A, Verbrugh H. Nasal carriage of *Staphylococcus aureus*: Epidemiology, underlying mechanisms, and associated risks. *Clin Microbiol Rev* 1997;10:505-20.
- Lanbeck P, Odenholt I, Paulsen O. Antibiotics differ in their tendency to cause infusion phlebitis: A prospective observational study. *Scand J Infect Dis* 2002;34:512-9.
- Levine DP. Vancomycin: A history. *Clin Infect Dis* 2006;42 Suppl 1:S5-12.
- Levinson W. Antimicrobial drugs: Mechanism of action. In: *Review of Medical Microbiology and Immunology*. 13<sup>th</sup> ed. New York: The McGraw-Hill Companies; 2012.
- Lilikakis A, Sutcliffe MP. The effect of vancomycin addition to the compression strength of antibiotic-loaded bone cements. *Int Orthop* 2009;33:815-9.
- Mariappan R, Manninen P, Massicotte EM, Bhatia A. Circulatory collapse after topical application of vancomycin powder during spine surgery. *J Neurosurg Spine* 2013;19:381-3.
- Matzke GR, Zhanel GG, Guay DR. Clinical pharmacokinetics of vancomycin. *Clin Pharmacokinet* 1986;11:257-82.
- Ng K, Mabasa VH, Chow I, Ensom MH. Systematic review of efficacy, pharmacokinetics, and administration of intraventricular vancomycin in adults. *Neurocrit Care* 2014;20:158-71.
- Olyaei AJ, Bennett WM. Acute renal failure from therapeutic agents. In: *Current Diagnosis and Treatment: Nephrology and Hypertension*. New York: The McGraw-Hill Companies; 2009.
- Ozcan AV, Demir M, Onem G, Goksin I, Baltarli A, Topkara VK, et al. Topical versus systemic vancomycin for deep sternal wound infection caused

- by methicillin-resistant *Staphylococcus aureus* in a rodent experimental model. *Tex Heart Inst J* 2006;33:107-10.
39. Rubinstein E, Keynan Y. Vancomycin revisited – 60 years later. *Front Public Health* 2014;2:217.
  40. Rybak M, Lomaestro B, Rotschafer JC, Moellering R Jr., Craig WW, Billeter M, et al. Therapeutic monitoring of vancomycin in adult patients: A consensus review of the American Society of Health-System Pharmacists, the Infectious Diseases Society of America, and the Society of Infectious Diseases Pharmacists. *Am J Health Syst Pharm* 2009;66:82-98.
  41. Sakaguchi H, Marui A, Hirose K, Nomura T, Arai Y, Bir SC, et al. Less-invasive and highly effective method for preventing methicillin-resistant *Staphylococcus aureus* graft infection by local sustained release of vancomycin. *J Thorac Cardiovasc Surg* 2008;135:25-31.
  42. Stierman B. Vancomycin resistance in *Staphylococcus aureus*: A dangerous dent in our armamentarium? *NYU Langone Online J Med* 2012. Available from: <http://www.clinicalcorrelations.org/?p=5810>. [Last accessed on 2014 Dec 11].
  43. Sweet FA, Roh M, Sliva C. Intrawound application of vancomycin for prophylaxis in instrumented thoracolumbar fusions: Efficacy, drug levels, and patient outcomes. *Spine (Phila Pa 1976)* 2011;36:2084-8.
  44. Tange RA, Kieviet HL, von Marle J, Bagger-Sjögård D, Ring W. An experimental study of vancomycin-induced cochlear damage. *Arch Otorhinolaryngol* 1989;246:67-70.
  45. Urabe K, Naruse K, Hattori H, Hirano M, Uchida K, Onuma K, et al. *In vitro* comparison of elution characteristics of vancomycin from calcium phosphate cement and polymethylmethacrylate. *J Orthop Sci* 2009;14:784-93.
  46. Vander Salm TJ, Okike ON, Pasque MK, Pezzella AT, Lew R, Traina V, et al. Reduction of sternal infection by application of topical vancomycin. *J Thorac Cardiovasc Surg* 1989;98:618-22.
  47. Youssef JA, Orndorff DG, Scott MA, Ebner RE, Knewitz AP. Sterile seroma resulting from multilevel XLIF procedure as possible adverse effect of prophylactic vancomycin powder: A case report. *Evid Based Spine Care J* 2014;5:127-33.

## Commentary

### TOPICAL VANCOMYCIN IN NEUROSURGERY

The authors present a review on the topical use of vancomycin. They discuss its pharmacology and pharmacokinetics along with associated toxicity. This report makes a special note of the historical underpinnings of vancomycin in the operating room and major trials in neurological surgery. Given a recent increased trend in topical vancomycin use for surgical site infection (SSI) prophylaxis, this is an important topic to critically review.

As discussed in the current review, SSI remains a significant burden on patients, hospitals, and the broader healthcare system. In a recent prospective multicenter trial, the International Spine Study Group reviewed postoperative complications in adult deformity surgery over a two year period. In this cohort, 6% of 291 patients experienced deep wound SSIs.<sup>[6]</sup> In a similar fashion, a recent case-controlled study of 2919 craniotomies revealed a 4.1% infection rate.<sup>[3]</sup> Unfortunately, these infection rates remain a major impediment to the overall safety and cost-effectiveness in neurosurgery. SSIs account for 22% of healthcare-acquired infections and impose more than \$10 billion in annual costs to the healthcare system in the United States.<sup>[5]</sup> Emohare *et al.* determined that spine SSIs cost an average of \$88,000 per patient.<sup>[4]</sup>

SSI reduction may not only produce cost savings but also has growing implications for reimbursement. Recently, the Center for Medicare and Medicaid Services introduced Hospital-Acquired Condition Reduction and Hospital Value-Based Purchasing Programs. These initiatives link reimbursement rates to quality measures in an attempt to improve patient outcomes. In both programs, infection reduction is a direct quality indicator, and hence directly dictates reimbursement.<sup>[2]</sup>

Despite this apparent need for reduction of infection rates, a consensus among neurosurgeons regarding vancomycin is still lacking. Topical vancomycin use has been examined in over 20 reported studies to date, most of which are in the spine literature.<sup>[5]</sup> A systematic review performed by Kang *et al.* in 2015 described a trend toward significant SSI improvement in retrospective reviews<sup>[5]</sup> but an insignificant difference in a prospective trial.<sup>[8]</sup> The relative paucity of clinically-relevant evidence becomes more apparent in the cranial literature. The authors of the current review described their institutional experience in a retrospective trial of intraoperative vancomycin during cranial surgery. They reported a significant reduction of SSI incidence from 6.7 to 1.3%.<sup>[1]</sup>

Similarly, there is a trend toward cost-reduction with vancomycin use. In 2014, Theologis *et al.* retrospectively reviewed the cost of SSI in adult deformity reconstruction surgery with and without the use of vancomycin. Out of 250 patients, there was significant reduction in 90-day hospital readmissions (2.6% vs. 10.9%) and an overall reduced cost of \$244,402 per 100 spinal deformity cases.<sup>[7]</sup>

Even though the prospect of vancomycin use is encouraging, there are several barriers to widespread adoption. These barriers include lack of clarity regarding optimal dosage, lack of application guidelines, and the largely retrospective nature of the available data. More prospective data from appropriately designed clinical trials with consistent practice guidelines will help to further elucidate the role of vancomycin in neurosurgical practice.

Alexander Ksendzovsky<sup>1,2</sup>, I. Jonathan Pomeranic<sup>2</sup>,  
Justin S. Smith<sup>2</sup>

<sup>1</sup>Surgical Neurology Branch, National Institute of Neurological Disorders and Stroke, National Institutes of Health, Bethesda, MD,

<sup>2</sup>Department of Neurological Surgery, University of Virginia Health Sciences Center, Charlottesville, Virginia, USA

E-mail: ksendzovskya@ninds.nih.gov

### REFERENCES

1. Abdullah KG, Attiah MA, Olsen AS, Richardson A, Lucas TH. Reducing surgical site infections following craniotomy: Examination of the use of topical vancomycin. *J Neurosurg* 2015;123:1600-4
2. Center for Medicare & Medicaid Services Value-Based Payment Modifier: <https://www.cms.gov/medicare/medicare-fee-for-service-payment/physicianfeedbackprogram/valuebasedpaymentmodifier.html#Quality%20and%20Cost%20Measures%20Used%20in%20e%20Value%20Modifier>. [Last accessed on 2016 Apr 11].
3. Chiang HY, Kamath AS, Pottinger JM, Greenlee JD, Howard MA 3<sup>rd</sup>, Cavanaugh JE, *et al.* Risk factors and outcomes associated with surgical site infections after craniotomy or craniectomy. *Journal Neurosurg* 2014;120:509-21.
4. Emohare O, Ledonio CG, Hill BW, Davis RA, Polly DW Jr., Kang MM. Cost savings analysis of intrawound vancomycin powder in posterior spinal surgery. *Spine J* 2014;14:2710-5.
5. Kang DG, Holekamp TF, Wagner SC, Lehman RA, Jr. Intraspinal vancomycin powder for the prevention of surgical site infection in spine surgery: A systematic literature review. *Spine J* 2015;15:762-70.
6. Smith JS, Klineberg E, Lafage V, Shaffrey CI, Schwab F, Lafage R, *et al.* Prospective multicenter assessment of perioperative and minimum 2-year postoperative complication rates associated with adult spinal deformity surgery. *J Neurosurg Spine* 2016;1-14.
7. Theologis AA, Demirkiran G, Callahan M, Pekmezci M, Ames C, Deviren V. Local intrawound vancomycin powder decreases the risk of surgical site infections in complex adult deformity reconstruction: A cost analysis. *Spine (Phila Pa 1976)* 2014;39:1875-80.
8. Tubaki VR, Rajasekaran S, Shetty AP. Effects of using intravenous antibiotic only versus local intrawound vancomycin antibiotic powder application in addition to intravenous antibiotics on postoperative infection in spine surgery in 907 patients. *Spine (Phila Pa 1976)* 2013;38:2149-55.