

Case Report

Isolated oculomotor nerve palsy after lumbar epidural steroid injection in a diabetic patient

Yair M. Gozal¹, Kristine Atchley¹, Bradford A. Curt^{1,2}¹Department of Neurosurgery, University of Cincinnati (UC) College of Medicine, ²Mayfield Clinic, Cincinnati, Ohio, USAE-mail: *Yair M. Gozal - gozalyr@ucmail.uc.edu; Kristine Atchley - katchley@mayfieldclinic.com; Bradford A. Curt - bcurt@mayfieldclinic.com

*Corresponding author

Received: 21 April 16 Accepted: 19 August 16 Published: 26 December 16

Abstract

Background: In patients with diabetes mellitus, epidural steroid injections (ESI) have been noted to cause significant elevation of blood glucose levels, typically lasting 1–3 days. Here, we describe a previously unreported complication of a diabetic third nerve palsy associated with an ESI.

Case Description: A 66-year-old man with a history of coronary artery disease, hypertension, and insulin-dependent diabetes mellitus presented with low back pain and left lower extremity radiculopathy. The lumbar magnetic resonance imaging (MRI) revealed mild spondylosis, most severe at the L4-5 level, accompanied by a broad based disc protrusion resulting in mild central and moderate biforaminal stenosis. The patient underwent a left-sided L4-L5 transforaminal ESI resulting in transient elevation of his blood glucose levels. On post-procedure day 2, he developed a frontal headache and a complete right third nerve palsy with partial pupillary involvement. The MRI and MR angiography (MRA) of the brain revealed no compressive lesions or oculomotor abnormalities. Ophthalmoplegia and pupillary dysfunction resolved spontaneously over 4 months.

Conclusions: Although rare, a history of a recent ESI should be considered as the etiology of an isolated oculomotor palsy in diabetic patients.

Key Words: Diabetes mellitus, epidural steroid injections, oculomotor nerve palsy, ophthalmoplegia

Access this article online

Website:www.surgicalneurologyint.com**DOI:**

10.4103/2152-7806.196770

Quick Response Code:

INTRODUCTION

The use of epidural steroids in diabetic patients is controversial. Multiple studies have demonstrated an association between epidural steroid injections (ESI) and increased insulin-resistance, poor glycemic control, and an elevated risk of infection.^[1,9] Here, we present a diabetic patient in whom an ESI precipitated a transient oculomotor palsy.

This is an open access article distributed under the terms of the Creative Commons Attribution-NonCommercial-ShareAlike 3.0 License, which allows others to remix, tweak, and build upon the work non-commercially, as long as the author is credited and the new creations are licensed under the identical terms.

For reprints contact: reprints@medknow.com

How to cite this article: Gozal YM, Atchley K, Curt BA. Isolated oculomotor nerve palsy after lumbar epidural steroid injection in a diabetic patient. *Surg Neurol Int* 2016;7:S1099-101.

<http://surgicalneurologyint.com/Isolated-oculomotor-nerve-palsy-after-lumbar-epidural-steroid-injection-in-a-diabetic-patient/>

CASE REPORT

Clinical presentation

A 66-year-old male with a history of coronary artery disease, hypertension, and insulin-dependent diabetes mellitus (DM) presented with 2 months of low back pain, left buttock/leg pain radiating down to the calf, and numbness in the L5 distribution. The lumbar magnetic resonance imaging (MRI) revealed mild L4-5 spondylosis with moderate biforaminal stenosis, accompanied by left L5-S1 lateral recess stenosis.

Epidural steroid injection and post-injection course

The patient was referred for bilateral selective L4-5 foraminal ESIs utilizing Betamethasone (9 mg per injection) and Bupivacaine under fluoroscopic guidance. There were no immediate post-procedural complications. However, 2 days later, the patient progressively developed a frontal headache, right eye ptosis, and inferolateral displacement of gaze with mild mydriasis of the the right pupil (4 mm OD vs. 2 mm OS), consistent with a right third nerve palsy with partial pupillary involvement [Figure 1]. The right pupil remained sluggishly reactive to direct and consensual light, however, anisocoria was maintained during these maneuvers. Formal ophthalmologic evaluation revealed a stable proliferative diabetic retinopathy with steroid-induced central serous retinopathy, accompanied by blurred vision. MRI and MR angiography (MRA) of the brain were unremarkable. For 3 days following the ESI, the patient's OneTouch glucometer (LifeScan Inc., Wayne, PA) revealed transient elevation in his blood glucose levels [Figure 2]. Daily blood glucose averaged 236 mg/dL vs. 174 mg/dL for the remainder of the month. Within 4 months, the ophthalmoplegia and pupillary dysfunction resolved, and the patient was left with only a mild residual ptosis [Figure 3].

DISCUSSION

Diabetes-associated oculomotor palsy affects ~0.5% of all diabetic patients and accounts for 11–42% of all third nerve palsies.^[6,7,10] The predominant etiology underlying oculomotor mononeuropathy in these patients is microvascular ischemia. Older patients with long-standing glucose intolerance and poor glycemic control are particularly susceptible,^[10] as are patients with concurrent diabetic retinopathy or those with multiple cardiovascular risk factors.^[3] This patient's known vasculopathic risk factors and transient ESI-induced hyperglycemia likely precipitated his third nerve palsy. In addition, his deficit resolved over 4 months, in line with the typical 2 weeks to 9 months expected for resolution of diabetic

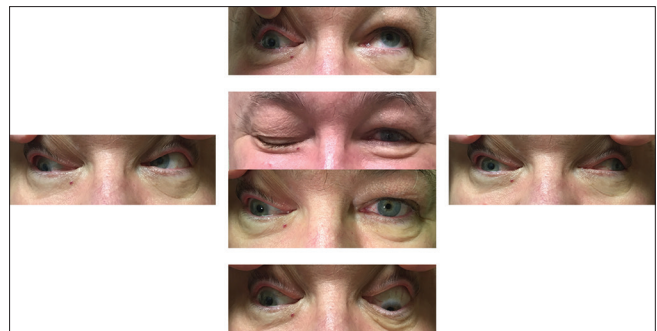

Figure 1: Photographs demonstrating ophthalmoplegia secondary to the right third nerve palsy with involvement of the pupil. The center panel demonstrates the extent of ptosis at rest and characteristic “down and out” position of the eye. Remaining images demonstrate eye position during voluntary gaze in each direction relative to the center panel

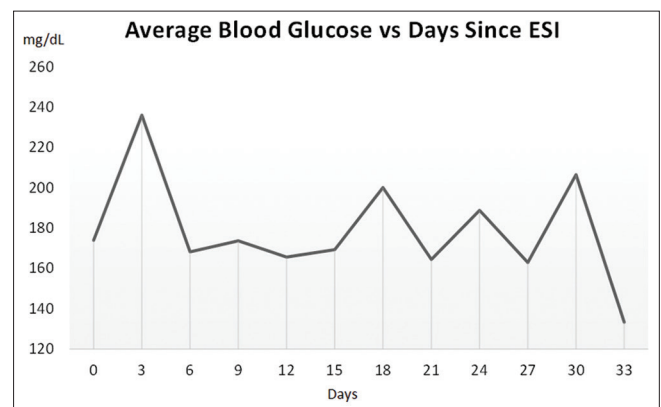


Figure 2: Post-procedure average recorded blood glucose (mg/dL) over 1 month after epidural steroid injection (ESI). Each point represents the average blood glucose obtained from the patient's personal glucometer calculated in 3-day bins. Initial value (day 0) reflects the blood glucose level recorded at the treatment center immediately before ESI

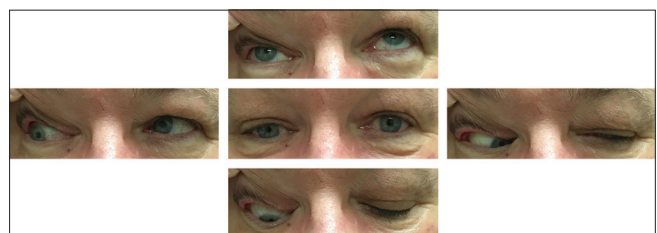

Figure 3: Photographs demonstrating resolution of the third nerve palsy 4 months after epidural spinal injection. The center panel demonstrates the position of the eye at rest. Remaining images demonstrate eye position during voluntary gaze in each direction relative to the center panel

mononeuropathies.^[8] Finally, although mild anisocoria was observed in association with ophthalmoplegia in this case, vascular imaging was negative for an aneurysmal or other compressive sources. Jacobson *et al.*^[5] reported a 38% incidence of pupillary involvement in 26 patients with diabetic third nerve palsy, whereas other retrospective series estimated pupillary involvement in 14–32% of patients.^[2,4]

Multiple studies have documented elevated mean blood glucose concentrations and insulin resistance lasting between 1–7 days following epidural steroids in diabetic patients.^[1] Even *et al.*^[1] suggested that nearly 85% of patients experience up to a 79% mean increase in blood glucose levels following intralaminar epidural injections of Betamethasone. Our patient's transient hyperglycemia, with a mean 36% increase of blood glucose levels after ESI, resolved spontaneously after 3 days. Additional investigation into the ideal composition of ESIs in diabetic patients is indicated.

DM affects more than a quarter of Americans over the age of 65 and is disproportionately common in patients with spinal stenosis.^[1] Diabetic patients are susceptible to disease-specific complications related to injection of epidural steroids in the treatment of spinal pathology. As in this case, a history of recent ESI should be considered in the diagnosis of oculomotor palsy in a diabetic patient.

Financial support and sponsorship

Nil.

Conflicts of interest

There are no conflicts of interest.

REFERENCES

1. Even JL, Crosby CG, Song Y, McGirt MJ, Devin CJ. Effects of epidural steroid injections on blood glucose levels in patients with diabetes mellitus. *Spine* 2012;37:E46-50.
2. Goldstein JE, Cogan DG. Diabetic ophthalmoplegia with special reference to the pupil. *Arch Ophthalmol* 1960;64:592-600.
3. Greco D, Gambina F, Maggio F. Ophthalmoplegia in diabetes mellitus: A retrospective study. *Acta Diabetol* 2009;46:23-6.
4. Green WR, Hackett ER, Schlezinger NS. Neuro-Ophthalmologic Evaluation of Oculomotor Nerve Paralysis. *Arch Ophthalmol* 1964;72:154-67.
5. Jacobson DM. Pupil involvement in patients with diabetes-associated oculomotor nerve palsy. *Arch Ophthalmol* 1998;116:723-727.
6. Keane JR. Third nerve palsy: Analysis of 1400 personally-examined inpatients. *Can J Neurol Sci* 2010;37:662-70.
7. Kwan ES, Laucella M, Hedges TR 3rd, Wolpert SM. A cliniconoradiologic approach to third cranial nerve palsies. *AJNR Am J Neuroradiol* 1987;8:459-68.
8. Shimizu H, Shimomura Y, Inukai T, Takahashi M, Uehara Y, Kobayashi I, *et al.* Immediate improvement of diabetic mononeuropathy after intravenous administration of prostaglandin E1. *Jpn J Med* 1990;29:222-5.
9. Simopoulos TT, Kraemer JJ, Glazer P, Bajwa ZH. Vertebral osteomyelitis: A potentially catastrophic outcome after lumbar epidural steroid injection. *Pain Physician* 2008;11:693-7.
10. Watanabe K, Hagura R, Akanuma Y, Takasu T, Kajinuma H, Kuzuya N, *et al.* Characteristics of cranial nerve palsies in diabetic patients. *Diabetes Res Clin Pract* 1990;10:19-27.