

## Case Report

## Ultra-delayed lumbar surgical wound hematoma

Merritt D. Kinon, Jonathan Nakhla, Kenroy Brown, Niketh Bhashyam, Reza Yassari

Department of Neurological Surgery, Montefiore Medical Center/Albert Einstein College of Medicine, Bronx, New York, USA

E-mail: Merritt D. Kinon - [mdkinon@gmail.com](mailto:mdkinon@gmail.com); \*Jonathan Nakhla - [jonathan.nakhla@gmail.com](mailto:jonathan.nakhla@gmail.com); Kenroy Brown - [kenroy.brown@gmail.com](mailto:kenroy.brown@gmail.com);  
Niketh Bhashyam - [nbhashya@mail.einstein.yu.edu](mailto:nbhashya@mail.einstein.yu.edu); Reza Yassari - [ryassari@montefiore.org](mailto:ryassari@montefiore.org)

\*Corresponding author

Received: 07 October 16 Accepted: 14 October 16 Published: 26 December 16

**Abstract**

**Background:** There exists an inherent risk of increased venous thromboembolism (VTE) in surgical spine patients, which is independent of their existing risk factors. Prophylaxis and treatment of VTE is an imprecise practice and may have serious complications even well after the initial surgery. Furthermore, there are no clear guidelines on how to manage postoperative spine patients with regards to the timing of anticoagulation.

**Case Description:** Here, we present the case of a middle-aged male, status post L2/3 laminectomy and discectomy who developed bilateral below the knee deep venous thrombosis. He was started on Enoxaparin and transitioned to Warfarin and returned with axial back pain, and was found to have a postoperative hematoma almost 3 weeks later in a delayed fashion.

**Conclusion:** Delayed surgical wound hematoma with neural compression is an important complication to identify and should remain high on the differential diagnosis in patients on warfarin who present with axial spinal pain.

**Key Words:** Anticoagulation, complication, spinal decompression, venous thromboembolism, wound hematoma

**Access this article online****Website:**[www.surgicalneurologyint.com](http://www.surgicalneurologyint.com)**DOI:**

10.4103/2152-7806.196766

**Quick Response Code:****INTRODUCTION**

The risk of venous thromboembolism (VTE) in a post-surgical spine patient can be increased due to existing comorbidities in addition to the inherent increased risk of the spine surgery itself. The current literature suggests that, although there are no specific recommendations for VTE, prophylaxis, elastic compression stockings, low molecular weight heparin (LMWH), low dose unfractionated heparin (LDUH), early ambulation, or intermittent pneumatic compression may help in VTE prevention in these patients.<sup>[2]</sup> Furthermore, when to start prophylactic or therapeutic treatment for VTE is not well-established and possesses a myriad of complications including spinal epidural hematoma and delayed surgical wound hematoma.<sup>[2,10]</sup>

Wound hematoma is an important differential diagnosis for patients on warfarin who have a “relatively” recent history of spinal surgery and present with axial spinal pain and swelling around their surgical wound. In general, such a complication occurs within a few days to a week after starting postoperative anticoagulation therapy.<sup>[2,9,11]</sup> Little evidence otherwise exists for wound hematoma

This is an open access article distributed under the terms of the Creative Commons Attribution-NonCommercial-ShareAlike 3.0 License, which allows others to remix, tweak, and build upon the work non-commercially, as long as the author is credited and the new creations are licensed under the identical terms.

**For reprints contact:** [reprints@medknow.com](mailto:reprints@medknow.com)

**How to cite this article:** Kinon MD, Nakhla J, Brown K, Bhashyam N, Yassari R. Ultra-delayed lumbar surgical wound hematoma. *Surg Neurol Int* 2016;7:S1089-91. <http://surgicalneurologyint.com/Ultra-delayed-lumbar-surgical-wound-hematoma/>

occurring after this usual time period. However, this report demonstrates that wound hematoma can occur well after its suspected time period, and up to 3 weeks after the index operation.

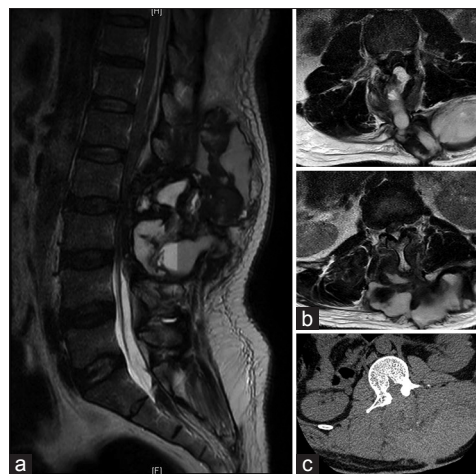
## CASE PRESENTATION

Our patient, a middle-aged male, status post L2-L3 laminectomy and discectomy for acute lower extremity weakness, developed bilateral below the knee deep venous thrombosis (DVT) on postoperative day 10 (POD) and was started on therapeutic Enoxaparin immediately. On POD 18, he was transitioned to Warfarin. Two days after starting Warfarin (POD 20), he developed terrible low back pain as well as worsening lower extremity weakness. At the time of arrival to our Emergency Department, his international normalized ratio (INR) was 2.8. His surgical wound was well healed, however, it was extremely tense and tender to touch. There was significant swelling that tracked from his lumbar wound out laterally to his flanks. Magnetic resonance (MR) imaging of the lumbar spine was done and showed a large, heterogeneous, multiloculated collection concerning for hematoma extending from the laminectomy defect to the overlying subcutaneous fat and dissecting out laterally to his flanks with significant epidural compression [Figure 1]. The collection measured 8.4 cm × 10 cm × 13 cm. The patient's INR was emergently corrected and he was taken to the operating room for surgical wound exploration. Intraoperatively, a large hematoma with varying stages of clot organization was encountered with extensive dissection into the adjacent soft tissues. The hematoma was evacuated and meticulous hemostasis was achieved. Anticoagulation was held after surgery and an IVC filter was placed.

## DISCUSSION

Little evidence exists supporting post-surgical delayed wound hematoma in a patient over a week after starting anticoagulation therapy.<sup>[2,9,11]</sup> Furthermore, there is little evidence documenting similar large wound hematomas occurring as late as 3 weeks post-surgery. However, this report documents an unusual and unique case of a large wound hematoma that occurred 3 weeks post-spine surgery, and over 1 week after starting anticoagulation therapy.

Large wound hematomas in a spine surgery patient can cause neural compression and also have symptoms consistent with acute spinal epidural hematomas. The symptoms of acute spinal epidural hematoma, as described in the medical literature, are sudden onset of severe pain along the spinal column lasting from a few minutes to a few hours, possibly with focal or evolving neurological symptoms such as flaccid



**Figure 1:** (a) Sagittal and (b) axial MRIT2-weighted images showing a large hematoma with severe compression of the thecal sac and spinal nerves. (c) Axial CT scan showing the decompression and a large hypodense collection

paralysis or loss of sphincter control.<sup>[14,17]</sup> Occasionally, there is transient improvement in the neurology.<sup>[8]</sup> Thus, acute spinal pain in a patient on anticoagulants should raise the suspicion of spinal epidural hematoma even before any neurological symptoms appear. The anticoagulants should be withheld immediately and coagulation abnormalities should be corrected. MRI is the investigation of choice to diagnose and to show the extent of epidural hematoma.<sup>[12]</sup> Gadolinium-enhanced MRI can localize spinal epidural hematoma preoperatively and can also show any underlying spinal vascular malformations.<sup>[5]</sup> The surgical approach is dictated by the location and extent of hematoma. The majority of epidural hematomas are located dorsally, therefore, decompressive laminectomy is the treatment of choice.<sup>[7]</sup> Ventral hematomas may require more extensive procedures.<sup>[4]</sup>

Certain conditions appear to predispose individuals to VTE. The American College of Chest Physicians Consensus Conference on Antithrombotic and Thrombolytic Therapy has a scoring to predict VTE, which includes the following as major risk factors: Age, bed confinement, history of malignancy, history of DVT, obesity, and spinal cord injury with paralysis.<sup>[1]</sup> Furthermore, patients undergoing spinal surgery alone are at risk of developing VTE when combined with other risk factors should be kept in mind preoperatively. Additional risk factors are prolonged immobilization postoperatively, incision pain, postoperative paralysis, and duration of surgery. The neurosurgeon is thus left to weigh the risks of postoperative hematoma formation against the benefits of protecting against DVT.<sup>[3]</sup>

As the complexity of spinal surgery has increased, so has the incidence of DVT and pulmonary embolism (PE). In spite of the use of different prophylactic methods, VTE

is still a significant complication following spinal surgery. In surgery of the lumbosacral spinal, the lowest quoted rates are 0.6% for DVT and 0.3% for PE.<sup>[15]</sup> The true incidence of VTE in spinal surgery remains unknown. Oda *et al.* reported evidence that the incidence of DVT after posterior spinal surgery is higher than appreciated, and that increased age and posterior lumbar surgery are risk factors.<sup>[16]</sup> Initial treatment with elastic compressive stockings, LMWH, LDUH, intermittent pneumatic compression, and early ambulation are the primary treatment measures.<sup>[2]</sup> A transition to Coumadin therapy for DVT is common, even in the postoperative period. However, there is no clear consensus in the current literature as when it is safe to start anticoagulation therapy after surgery.<sup>[2]</sup> Neurosurgical procedures, including spinal surgery procedures, carry an inherent high risk of postoperative bleeding because any compression of the neural elements can have significant morbidity.<sup>[6,13]</sup> Some authors recommend starting anticoagulation for thromboembolism 72 hours after surgery because the high risk of developing postoperative thromboembolism and complication associated with it are usually 3 to 5 days after surgery, whereas others recommend restarting anticoagulation after 7 days in patients who have suffered a spontaneous hemorrhage due to anticoagulation.<sup>[9,11]</sup> As such, no clear guidelines exist for DVT prophylaxis or postoperative treatment, and are still on a per patient basis. However, this report suggests careful postoperative follow-up and monitoring for complications, including delayed wound hematomas, in any patient who underwent spine surgery, and was subsequently started on prophylactic anticoagulant therapy is necessary even up to 3 weeks after the index surgery.

## CONCLUSION

The incidence of VTE has risen along with the rise of complexity in spinal surgery. Neurological procedures themselves have an inherent risk of VTE and there is no consensus as to when to begin anticoagulant therapy. With many unknowns and individual patient treatment needs, one should maintain high suspicion for wound hematoma even in patients 3 weeks out from surgery on anticoagulants.

## Financial support and sponsorship

Nil.

## Conflicts of interest

There are no conflicts of interest.

## REFERENCES

- Stein P, Goldhaber S, Gottschalk A, Hull R, Hyers T, Leeper K, *et al.* Opinions regarding the diagnosis and management of venous thromboembolic disease. ACCP Consensus Committee on Pulmonary Embolism. American College of Chest Physicians. *Chest* 1998;113:499-504.
- Brambilla S, Ruosi C, La Maida GA, Caserta S. Prevention of venous thromboembolism in spinal surgery. *Eur Spine J* 2004;13:1-8.
- Browd SR, Ragel BT, Davis GE, Scott AM, Skalabrin EJ, Couldwell WT. Prophylaxis for deep venous thrombosis in neurosurgery: A review of the literature. *Neurosurg Focus* 2004;17:E1.
- Carroll SG, Malhotra R, Eustace D, Sharr M, Morcos S. Spontaneous spinal extradural hematoma during pregnancy. *J Matern Fetal Med* 1997;6:218-9.
- Crisi G, Sorgato P, Colombo A, Scarpa M, Falasca A, Angiari P. Gadolinium-DTPA-enhanced MR imaging in the diagnosis of spinal epidural haematoma. Report of a case. *Neuroradiology* 1990;32:64-6.
- Daniels PR. Peri-procedural management of patients taking oral anticoagulants. *BMJ* 2015;351:h2391.
- Dziedzic T, Kunert P, Krych P, Marchel A. Management and neurological outcome of spontaneous spinal epidural hematoma. *J Clin Neurosci* 2015;22:726-9.
- Galzio RJ, Zenobii M, D'Ecclesia G. Spontaneous spinal epidural hematoma: Report of a case with complete recovery. *Surg Neurol* 1980;14:263-5.
- Hawryluk GW, Furlan JC, Austin JW, Fehlings MG. Individual characteristics and management decisions affect outcome of anticoagulated patients with intracranial hemorrhage. *World Neurosurg* 2014;81:742-51.
- Janku GV, Paiement GD, Green HD. Prevention of venous thromboembolism in orthopaedics in the United States. *Clin Orthop Relat Res* 1996;313-21.
- Kunkala MR, Kehl J, Zielinski MD. Spontaneous rectus sheath hematomas: When to restart anticoagulation? *World J Surg* 2013;37:2555-9.
- Lawton MT, Porter RV, Heiserman JE, Jacobowitz R, Sonntag VK, Dickman CA. Surgical management of spinal epidural hematoma: Relationship between surgical timing and neurological outcome. *J Neurosurg* 1995;83:1-7.
- Liao CC, Hsieh PC, Lin TK, Lin CL, Lo YL, Lee SC. Surgical treatment of spontaneous spinal epidural hematoma: A 5-year experience. *J Neurosurg Spine* 2009;11:480-6.
- Minato T, Miyagi M, Saito W, Shoji S, Nakazawa T, Inoue G, *et al.* Spinal Epidural Hematoma after Thoracolumbar Posterior Fusion Surgery without Decompression for Thoracic/Vertebral Fracture. *Case Rep Orthop* 2016;2016:6295817.
- Nicol M, Sun Y, Craig N, Wardlaw D. Incidence of thromboembolic complications in lumbar spinal surgery in 1,111 patients. *Eur Spine J* 2009;18:1548-52.
- Oda T, Fuji T, Kato Y, Fujita S, Kanemitsu N. Deep venous thrombosis after posterior spinal surgery. *Spine* 2000;25:2962-7.
- Rangwala SD, Birk DM, Tobin MK, Hahn YS, Nikas DC. Spontaneous Resolution of Spinal Epidural Hematoma Resulting from Domestic Child Abuse: Case Report. *Pediatr Neurosurg* 2016.