

## Case Report

**Abducent nerve palsy after microballoon compression of the trigeminal ganglion: Case report**Cassiano Marchi<sup>1</sup>, Paulo Henrique Pires de Aguiar<sup>2,3,4</sup>, Ana Maria Moura<sup>1</sup>, Giovanna Matricardi<sup>3</sup>, Carolina Utsunomya Muniz<sup>3</sup>, Rogério Aires<sup>4</sup>, Flávia Gehrke<sup>4</sup>, Natally Santiago<sup>1</sup>, Samuel Simis<sup>3</sup><sup>1</sup>Department of Neurosurgery, Hospital Santa Paula, São Paulo, <sup>2</sup>Department of Surgery, Post Graduation Section, Federal University of Rio Grande do Sul, <sup>3</sup>Department of Medicine, Division of Neurology, Catholic Pontifical University of São Paulo, <sup>4</sup>Section of Post Graduation of IAMSPE, São Paulo State Civil Servant Hospital, São Paulo, BrazilE-mail: \*Cassiano Marchi - [cassianomarchi1@gmail.com](mailto:cassianomarchi1@gmail.com); Paulo Henrique Pires de Aguiar - [phpaneurocir@gmail.com](mailto:phpaneurocir@gmail.com); Ana Maria Moura - [anamoura.med@ig.com.br](mailto:anamoura.med@ig.com.br); Giovanna Matricardi - [gmatricardi@gmail.com](mailto:gmatricardi@gmail.com); Carolina Utsunomya Muniz - [carolutsunomiya92@gmail.com](mailto:carolutsunomiya92@gmail.com); Rogério Aires - [caneaires@gmail.com](mailto:caneaires@gmail.com); Flávia Gehrke - [flaviagehrke@hotmail.com](mailto:flaviagehrke@hotmail.com); Natally Santiago - [natallysarturi@gmail.com](mailto:natallysarturi@gmail.com); Samuel Simis - [ssimis@limuspauling.com](mailto:ssimis@limuspauling.com)

\*Corresponding author

Received: 19 September 16 Accepted: 31 March 17 Published: 21 June 17

**Abstract****Background:** Trigeminal neuralgia (TN) is the most common type of facial neuralgia with incidence of 26.8/100,000 person year. In general, this scenario is characterized by a lancinating, unilateral, paroxysmal pain in the area of the fifth cranial nerve. Several treatment methods, including the injection of ethyl alcohol or butyl alcohol into the ganglion, the glycerol injection into the trigeminal cistern, peripheral nerve divisions, the radiofrequency thermocoagulation of the preganglionic fibers, and radiosurgery has been used for TN.**Case Description:** A case of a 74-year-old woman patient who undergone a treatment of TN through a compression of Meckel cave and developed a transient abducent palsy is presented. Complication regarding to a palsy of abducent nerve is discussed as well as the analysis of presumable evolving physiopathology. A critical review of literature was performed.**Conclusions:** Among the procedures, we mean that percutaneous microballoon compression (PMC) is the best choice for elderly frail patients, because it had a very low associated mortality-morbidity rate and does not damage permanent the Gasserian ganglion.**Key Words:** Abducent palsy, balloon compression, diplopia, Gasserian ganglion, percutaneous procedures, trigeminal neuralgia**Access this article online****Website:**[www.surgicalneurologyint.com](http://www.surgicalneurologyint.com)**DOI:**

10.4103/sni.sni\_375\_16

**Quick Response Code:****INTRODUCTION**Trigeminal neuralgia (TN) is the most common type of facial neuralgia with incidence of 26.8/100,000 person year according to Devor *et al.*<sup>[10]</sup> In general, this scenario is characterized by a lancinating, unilateral, paroxysmal pain in the area of the fifth cranial nerve.<sup>[7,10,11]</sup>The incidence rate of TN according to the gender is 2.5 and 5.7 per 100,000 per year respectively.<sup>[7,10,11]</sup>

This is an open access article distributed under the terms of the Creative Commons Attribution-NonCommercial-ShareAlike 3.0 License, which allows others to remix, tweak, and build upon the work non-commercially, as long as the author is credited and the new creations are licensed under the identical terms.

**For reprints contact:** [reprints@medknow.com](mailto:reprints@medknow.com)**How to cite this article:** Marchi C, de Aguiar PH, Moura AM, Matricardi G, Muniz CU, Aires R, et al. Abducent nerve palsy after microballoon compression of the trigeminal ganglion: Case report. *Surg Neurol Int* 2017;8:125. <http://surgicalneurologyint.com/Abducent-nerve-palsy-after-microballoon-compression-of-the-trigeminal-ganglion:-Case-report/>

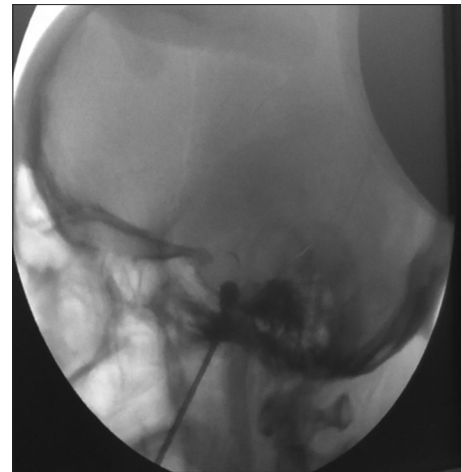
Several treatment methods, including the injection of ethyl alcohol or butyl alcohol into the ganglion, the glycerol injection into the trigeminal cistern, peripheral nerve divisions, the radiofrequency thermocoagulation of the preganglionic fibers, radiosurgery has been used for TN,<sup>[13,15,16,21,26]</sup> from which the patients may obtain relief from pain.

Percutaneous microballoon compression (PMC) was first reported by Mullan *et al.*<sup>[18]</sup> Mullan and Lichtor<sup>[19]</sup> whose earlier work compared a transformed open cordotomy with a percutaneous injury, developed the innovative percutaneous compressive technique by using a Fogarty embolectomy catheter to compress the ganglion and retrogasserian nerve.<sup>[19]</sup> This is a modification of Shelden's technique,<sup>[22,23]</sup> and after improvement has been used widely. The technique is more physiological without provoking a loss of facial sensory due to a minimal microinvasion. Usage of balloon compression of the pathways behind the trigeminal ganglion for the treatment of TN has become a popular method among functional neurosurgeons. In another hand, this method has neurological complications, including double vision caused by trochlear as well as abducent palsy. Although this complication being rare, diplopia may cause significant disability.<sup>[1,12,27]</sup> The authors discuss the physiopathology of abducent palsy.

## CASE REPORT

A 74-year-old woman patient presented with classic TN, mainly V1, V2 at the right side. First, she was treated clinically with carbamazepine 1200 mg per day, without any result. Due to the worsening of pain she was submitted to an injection of dexamethasone and bupivacaine in the extracranial course of maxillary division of trigeminal nerve with partial result. It was administrated gabapentin 600 mg per day also without results. The pre operative angio MRI did not show any important vascular looping over the right fifth nerve, and no lesions were identified in MRI. After 6 months of clinical treatment she underwent a PMC using the traditional technique: a #4 Fogarty balloon catheter with cannula and obturator, radiopaque contrast, and C-arm fluoroscopy unit were employed as the technique described by Burchiel.<sup>[7]</sup>

The patient is placed in supine position, sedated with propofol to describe better the exact place of pain (awake patient). As described above, the foramen ovale was cannulated and the balloon catheter was inserted with radiological guide into the Meckel's cave [Figure 1]. The catheter was inflated till 1 ml, in a desired pressure, and shape and dye was injected to confirm position. A small amount of Omnipaque® was slowly injected to inflate the balloon and compress the trigeminal ganglion and insufflation of balloon for 2 minutes,



**Figure 1: Radiological view shows that the foramen ovale was cannulated and the balloon catheter was inserted tenderly with radiological guide into the Meckel's cave. The catheter was inflated till 1 ml, in a desired pressure, and shape and dye was injected to confirm position**

guided by fluoroscopy and Omnipaque® as contrast. She presented during the procedure bradycardia about 25 beats/minute and total recovery after deflation of balloon. After the procedure, she developed severe diplopia, with paresis of abducent at right side and minimal effect in the pain. The paresis of abducent disappeared; however, the diplopia took 5 weeks to become better and disappear. She had undergone a control MRI, CT scan without any changing in comparison with the preoperative images.

## DISCUSSION

Initial pain relief through the compression of Gasserian ganglion with balloon is obtained in literature in 93% of the cases and recurrence in about 23% at 3 years as reported by Brown *et al.*<sup>[4,6]</sup> Skirving and Dan<sup>[25]</sup> reported a recurrence rate of 19.2% within 5 years and 31.9% over the entire follow-up period. Correa and Teixeira, 1998, presented 187 patients, in which series there were no deaths or serious complications after PMC, and the pain was relieved in all the patients.<sup>[9]</sup> Liu *et al.*<sup>[14]</sup> showed a recurrence of 5.2%.

Carbamazepine is beyond any doubt the first choice for TN and for the patients who had drug resistance or intolerance, the percutaneous procedures are necessary.<sup>[2-9]</sup> The percutaneous procedures are radiofrequency rhizotomy, glycerol rhizotomy, and balloon compression.<sup>[2-9,12-15,18-20,22-24,26]</sup>

Among the procedures, we mean that PMC is the best choice for elderly frail patients, because it had a very low associated mortality-morbidity rate and does not damage the Gasserian ganglion. Several surgical methods must be considered, if percutaneous procedures fail, it may

include partial sensory trigeminal rhizotomy, peripheral neurectomy, and stereotactic radiosurgery.<sup>[13,15-17,21,23,26,27]</sup> Even with the awareness that all of them can damage the nerves and result in considerable severe complications.

PMC may cause hypoesthesia, dysesthesia, masseter muscle weakness, anesthesia dolorosa, corneal anesthesia and absent corneal reflex, aseptic meningitis, transient sixth nerve palsy, otalgia, trochlear nerve palsy, and increased olfactory.<sup>[7,9,14,20,22-24,27,28]</sup> PMC may injure the myelinated fibers causing mediate the “trigger” to the lancinating pain of TN. As the corneal reflex is mediated by unmyelinated fibers, selective monitored compression of the myelinated fibers can preserve the corneal reflex when first divisive pain is present.<sup>[18-20]</sup>

Monitoring the compressive pressure and reducing the duration of compression, it is possible to diminish the incidence of dysesthesia, hypoesthesia, severe numbness, and masseter motor paresia after PMC without interference in the rate of recurrence of trigeminal pain.<sup>[22,23,25,26]</sup>

Fogarty balloon catheter was navigated into the Meckel’s cave tenderly, for 1 minute of inflation, but in literature we found groups that have been used to inflate for 3– 0 minutes with good results.<sup>[18,19]</sup> Mullan *et al.*<sup>[18]</sup> and Mullan and Lichtor<sup>[19]</sup> observed an increased incidence of dysesthesia and numbness, with longer compression time, and after the sixth procedure, they began using only 1 minute of compression.

The experiments at laboratory suggest that balloon compression relieves trigeminal pain by injuring the myelinated axons which are involved in the sensory trigger to the pain and they try to correlate with the lancinating pain in patients suffering from TN.<sup>[12,14,21,23]</sup>

Monitoring the heart rate and blood pressure during PMC due to trigeminal cardiac reflex show that the heart rate can fell abruptly to 60 or even less, and the mean arterial blood pressure can decrease transiently in one third.<sup>[4,7]</sup> Medication as atropine or nitroprusside sodium may be useful and a temporary pacemaker may be necessary in severe cases of cardiac diseases.

Sixth nerve palsy was described before in functional rhizotomy for TN by radiofrequency. Penetration of the foramen ovale by the proper trajectory and avoidance of excessive penetration (5 mm beyond the profile of the clivus) were described as factors to eliminate the ocular nerve complications. Tew *et al.*,<sup>[27]</sup> described that the abducens was the most frequent injured nerve, and it would be possible to avoid any damage to this nerve, if the electrode trajectory would be maintained between the 5 mm and 10 mm planes and the electrodes does not penetrate more than 10 mm deep into the clival line. They conclude that oculomotor and trochlear palsies rarely occur unless the needle penetrates the cavernous

sinus.<sup>[27]</sup> They found a 2% (seven cases) of transient diplopia in 400 cases, all of whom related to neuralgia of ophthalmic division. Abducent palsy was observed in five cases and trochlear in two cases. The period of recovery was from few weeks to 4 months.<sup>[27]</sup> Five weeks was the period of recovery observed in our patient.

Brown *et al.*<sup>[2]</sup> studying 141 consecutive patients treated by PMC observed one case with temporary sixth nerve palsy that spontaneously resolved. They thought that this was because of balloon over inflation and cavernous sinus compression, and concluded that this occurred before pressure monitoring was routinely done.

Bergenheim and Linderoth<sup>[1]</sup> reviewed their joint consecutive series of 193 patients with TN treated with balloon compression. After a meticulous analysis of records and the intraoperative x-ray images, they identified six patients with double vision postoperatively. In reviewing these occurrences, they found that the balloon was inflated outside Meckel’s cave in four patients, the balloon was initially inflated too deeply in one patient, and the anatomy of Meckel’s cave was probably aberrant in one patient. In five of the six patients, the symptoms disappeared within 5 months.<sup>[1]</sup>

Kefalopoulou *et al.*,<sup>[12]</sup> studied 79 patients who underwent a PMC and found two cases with sixth nerve palsy, both presenting a transient palsy, and concluded after reviewing all radiological records that the anatomic position and the pear shape of the inflated balloon, concluding that all represent key factors in determining the procedure’s benefit or risk of complications. In our case, the abducent nerve palsy was because the shape was not pear, and by the penetrate above the clival line.

By meticulous surgical technique with close attention to the anatomic position and the shape of the inflated balloon, most cases of postcompression diplopia should be avoided.

## Financial support and sponsorship

Nil.

## Conflicts of interest

There are no conflicts of interest.

## REFERENCES

1. Bergenheim AT, Linderoth B. Diplopia after balloon compression of retrogasserian ganglion rootlets for trigeminal neuralgia: Technical case report. *Neurosurgery* 2008;62:E533-4.
2. Brown JA, Chittum CJ, Sabol D, Gouda JJ. Percutaneous balloon compression of the trigeminal nerve for treatment of trigeminal neuralgia. *Neurosurg Focus* 1996;1:1-4.
3. Brown JA, Gouda JJ. Percutaneous balloon compression of the trigeminal nerve. *Neurosurg Clin N Am* 1997;8:53-62.
4. Brown JA, McDaniel MD, Weaver MT. Percutaneous trigeminal nerve compression for treatment of trigeminal neuralgia: Results in 50 patients. *Neurosurgery* 1993;32:570-3.
5. Brown JA, Piltitsis JG. Percutaneous balloon compression for the treatment

- of trigeminal neuralgia: Results in 56 patients based on balloon compression pressure monitoring. *Neurosurg Focus* 2005;18:E10.
6. Brown JA, Preul MC. Trigeminal depressor response during percutaneous microcompression of the trigeminal ganglion for trigeminal neuralgia. *Neurosurgery* 1988;23:745-8.
  7. Burchiel KJ. Neurosurgery for trigeminal neuralgia. In: Sindou M, editor. *Practical Handbook of Neurosurgery from Leading Neurosurgeons*. New York: Springer; 2009. p. 349-64.
  8. Campos WK, Linhares MN. A prospective study of 39 patients with trigeminal neuralgia treated with percutaneous balloon compression. *Arq Neuropsiquiatr* 2011;69:221-6.
  9. Correa CF, Teixeira MJ. Balloon compression of the Gasserian ganglion for the treatment of trigeminal neuralgia. *Stereotact Funct Neurosurg* 1998;71:83-9.
  10. Devor M, Amir R, Rappaport ZH. Pathophysiology of trigeminal neuralgia: The ignition hypothesis. *Clin J Pain* 2002;18:4-13.
  11. Edlich R, Winters KL, Britt LD, Long IWB. Trigeminal neuralgia. *J Long Term Eff Med Implants* 2006;16:185-92.
  12. Kefalopoulou Z, Markaki E, Constantoyannis C. Avoiding abducens nerve palsy during the percutaneous balloon compression procedure. *Stereotact Funct Neurosurg* 2009;87:101-4.
  13. Kondziolka D, Lunsford LD, Bissonette DJ. Long-term results after glycerol rhizotomy for multiple sclerosis-related trigeminal neuralgia. *Can J Neurol Sci* 1994;21:137-40.
  14. Liu HB, Ma Y, Zou JJ, Li XG. Percutaneous microballoon compression for trigeminal neuralgia. *Chin Med J* 2007;120:228-30.
  15. Lopez BC, Hamlyn PJ, Zakrzewska JM. Systematic review of ablative neurosurgical techniques for the treatment of trigeminal neuralgia. *Neurosurgery* 2004;54:973-82.
  16. Lunsford LD, Bennett MH. Percutaneous retrogasserian glycerol rhizotomy for tic douloureux: Part 1. Technique and results in 112 patients. *Neurosurgery* 1984;14:424-30.
  17. Maher CO, Pollock BE. Radiation induced vascular injury after stereotactic radiosurgery for trigeminal neuralgia: Case report. *Surg Neurol* 2000;54:189-93.
  18. Mullan S, Duda EE, Patronas NJ. Some examples of balloon technology in neurosurgery. *J Neurosurg* 1980;52:321-9.
  19. Mullan S, Lichtor T. Percutaneous microcompression of the trigeminal ganglion for trigeminal neuralgia. *J Neurosurg* 1983;59:1007-12.
  20. Natarajan M. Percutaneous trigeminal ganglion balloon compression: Experience in 40 patients. *Neurol India* 2000;48:330-2.
  21. Perkin GD. Trigeminal neuralgia. *Curr Treat Options Neurol* 1999;1:458-65.
  22. Sheldon CH, Crue BL, Coulter JA. Surgical treatment of trigeminal neuralgia and discussion of compression operation. *Postgrad Med* 1960;27:595-601.
  23. Sheldon CH, Pudenz RH, Freshwater DB, Crue BL. Compression rather than decompression for trigeminal neuralgia. *J Neurosurg* 1955;12:123-6.
  24. Siqueira SR, Nobrega JC, Teixeira MJ, Siqueira JT. Olfactory threshold increase in trigeminal neuralgia after balloon compression. *Clin Neurol Neurosurg* 2006;108:721-5.
  25. Skirving DJ, Dan NG. A 20-year review of percutaneous balloon compression of the trigeminal ganglion. *J Neurosurg* 2001;94:913-7.
  26. Taha JM, Tew JM Jr. Comparison of surgical treatments for trigeminal neuralgia: Reevaluation of radiofrequency rhizotomy. *Neurosurgery* 1996;38:865-71.
  27. Tew JM, Keller JT, Williams DS. Functional surgery of the trigeminal nerve: Treatment of trigeminal neuralgia. In: Rasmussen T, Marino R, editors. *Functional Neurosurgery*. New York: Raven Press; 1979. p. 129-42.
  28. Urculo E, Alfaro R, Arrazola M, Astudillo E, Rejas G. Trochlear nerve palsy after repeated percutaneous balloon compression for recurrent trigeminal neuralgia: Case report and pathogenic considerations. *Neurosurgery* 2004;54:505-8.