

Original Article

# Initial radiological findings utilizing titanium basket for cervical open door laminoplasty

Hidenori Matsuoka, Yukoh Ohara, Yoshiyuki Tomita, Nahoko Kikuchi, Yoshitaka Hirano<sup>1</sup>, Hisaaki Uchikado<sup>2</sup>, Junichi Mizuno

Center for Minimally Invasive Spinal Surgery, ShinYurigaoka General Hospital, Kawasaki, Kanagawa 215-0026, <sup>1</sup>Spine Section, Department of Neurosurgery, Southern Tohoku Research Institute for Neuroscience, Koriyama, <sup>2</sup>Uchikado Neuro-Spine Clinic, Fukuoka, Japan

E-mail: \*Hidenori Matsuoka - [matsuoka119@yahoo.co.jp](mailto:matsuoka119@yahoo.co.jp), Yukoh Ohara - [yukoh@juntendo.ac.jp](mailto:yukoh@juntendo.ac.jp); Yoshiyuki Tomita - [ytomita4@hotmail.com](mailto:ytomita4@hotmail.com); Nahoko Kikuchi - [nahoko@gmail.com](mailto:nahoko@gmail.com); Yoshitaka Hirano - [mth10yhirano@flute.ocn.ne.jp](mailto:mth10yhirano@flute.ocn.ne.jp); Hisaaki Uchikado - [uchikado@me.com](mailto:uchikado@me.com); Junichi Mizuno - [mizuno@shibire.com](mailto:mizuno@shibire.com)  
\*Corresponding author

Received: 05 June 17 Accepted: 24 June 17 Published: 07 September 17

## Abstract


**Background:** Cervical laminoplasty, utilizing different spacers to “keep the door open,” is the gold standard in Japan for treating ossification of the posterior longitudinal ligament (OPLL) and cervical spondylotic myelopathy (CSM). Here, we utilized a novel titanium “basket” spacer (Laminoplasty Basket: L-Basket; Ammtec, Tokyo) to perform open door cervical laminoplasty to keep the “door open” while also allowing for bony fusion across the open door.

**Methods:** Twenty-seven patients with/without OPLL were treated with open door laminoplasty utilizing the basket spacer. Patients were analyzed with preoperative/postoperative JOA scores, and X-rays/computed tomography (CT) at least 12 months (range, 12–19 months) postoperatively.

**Results:** Improvement from the preoperative JOA score of 10.3 points to the postoperative JOA of 14.8 points was noted 3 months postoperatively. There were no complications except one patient who had transient C5 palsy. Twelve months postoperatively, X-rays/CT documented fusion on both the open (62%) and hinge sides (90.2%); circumferential fusion was observed 59.8% of the time.

**Conclusion:** This titanium “basket” spacer (Laminoplasty Basket: L-Basket; Ammtec, Tokyo) promoted bone union between the spacer and both lamina, lateral masses following cervical laminoplasty without undue complications.

**Key Words:** Bone union, novel titanium spacer, open door laminoplasty

<b>Access this article online</b>
<b>Website:</b> <a href="http://www.surgicalneurologyint.com">www.surgicalneurologyint.com</a>
<b>DOI:</b> 10.4103/sni.sni_204_17
<b>Quick Response Code:</b>


## INTRODUCTION

Open door cervical laminoplasty is a well-established procedure for treating patients with multilevel cervical spondylotic myelopathy (CSM) and ossification of the posterior longitudinal ligament (OPLL) in Japan. There are many types of artificial hydroxyapatite (HA) spacers and titanium plates have been utilized to “keep the door

This is an open access article distributed under the terms of the Creative Commons Attribution-NonCommercial-ShareAlike 3.0 License, which allows others to remix, tweak, and build upon the work non-commercially, as long as the author is credited and the new creations are licensed under the identical terms.

**For reprints contact:** [reprints@medknow.com](mailto:reprints@medknow.com)

**How to cite this article:** Matsuoka H, Ohara Y, Tomita Y, Kikuchi N, Hirano Y, Uchikado H, et al. Initial radiological findings utilizing titanium basket for cervical open door laminoplasty. *Surg Neurol Int* 2017;8:217.  
<http://surgicalneurologyint.com/Initial-radiological-findings-utilizing-titanium-basket-for-cervical-open-door-laminoplasty/>

open.”<sup>[1-4,7,9,11]</sup> Although reports described fusion on the gutter side after cervical laminoplasty performed with titanium plate, few studies have focused on fusion on the “open side.”<sup>[5,6,8]</sup> Here, we evaluated the 12-month (or longer) fusion rates (X-rays/CT) on both sides of a laminoplasty utilizing a new titanium, L-Basket spacer.<sup>[10]</sup>

## MATERIALS AND METHODS

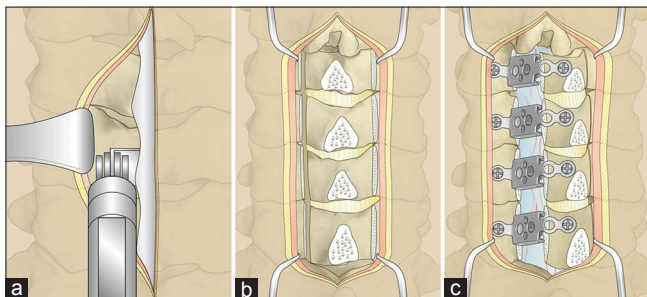
We retrospectively reviewed the medical records and clinical outcomes of 27 consecutive patients who underwent open door laminoplasty utilizing the L-Basket for cervical degenerative disease and OPLL. Postoperative X-ray and computed tomography (CT) studies were analyzed a minimum of 12-months postoperatively (follow-up period, 12–19 months). Preoperative deficits included myelopathy (94.1%) and radiculopathy (5.8%). Of the 27 cases (18 men and 9 women), the average preoperative JOA score was 10.3. All patients underwent preoperative X-ray, magnetic resonance (MR), and CT evaluations; 22 (81.5%) had cervical spondylosis and 5 (18.5%) had OPLL.

### Surgical technique of open-door laminoplasty

A standard surgical procedure of open-door laminoplasty was performed as follows [Figure 1a-c]. After the bilateral lamina was exposed, the open side of the lamina was divided at its lateral margin using a 3-mm diamond burr and Sonopet. Elevation of the lamina at the open side was stabilized with laminoplasty baskets and mini-screw (Ammtec Co., Tokyo, Japan). One 5-mm mini-screw was placed into the lateral mass through the plate and one 4-mm mini-screw was placed through the plate into the cut lamina in all cases. All patients wore a cervical soft collar for 1 week after surgery.

### Computed tomography scan analysis

CT scans obtained after surgery were independently evaluated for healing by four different reviewers (all Neurosurgical Spinal Surgeons). Bone union at the open side and closed sides were both evaluated by axial



**Figure 1:** Schematic drawings of open door laminoplasty using the titanium spacer. (a) Unilateral exposure of lamina, horizontal amputation of the spinous process. (b) After unilateral laminotomy and contralateral gutter formation with diamond drill. (c) Fixation of the spacer.

CT images at 12 months after surgery to determine the state of the bone union at the medial and lateral sides of the titanium basket based on our classification [Figure 2]. Four union categories were utilized – stage 1, nonunion, stage 2, shaggy (tends to unite), stage 3, half (partial union), and stage 4, bridge (complete union) [Table 1]. The bone union status of each lamina was determined by consensus of two of four reviewers.

## RESULTS

### Clinical outcome

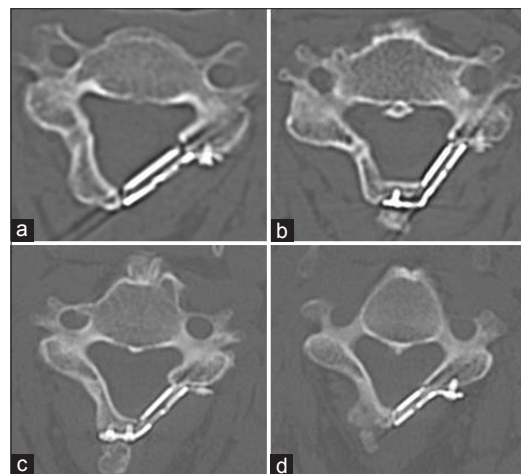
Open door laminoplasty was safely performed in 27 patients, 92 laminae were elevated. Percentage JOA improvement was  $70.5 \pm 14.8$  (standard deviation); the mean preoperative JOA score was  $10.3 \pm 2.9$ , and the mean postoperative score was  $14.8 \pm 2.1$  [Table 2]. One patient experienced a transient C5 palsy for 2 weeks as postoperative complication, however, there were no other major complications.

### Radiological measurements

Utilizing X-ray and CT studies 12 months postoperatively, bone union occurred on the hinged side 90.2% of the time. Fusion was confirmed on the open side 62.0% of

**Table 1: Definitions of Bone Union**

	Lateral mass			
	None	Shaggy	Half	Bridge
Medial lamina				
None	Non-union	Non-union	Non-union	Non-union
Shaggy	Non-union	Tends to unite	Union	Union
Half	Non-union	Union	Union	Union
Bridge	Non-union	Union	Union	Union



**Figure 2:** CT classification of bone fusion at the open side (our classification). (a) none. No visible density between the basket and lamina, and lateral mass. (b) shaggy. Bone density is slightly visible between the basket and lamina, and lateral mass. (c) Half. Bone density is visible in the basket. (d) Bridge. Bone density is continuous from the lateral mass to lamina

**Table 2: Summary of 27 patients treated by open door laminoplasty with L-Basket**

Characteristic	Value
Age (years)	
Range	37-83
Mean±SD	64.8±10.2
Sex	
Men	18
Women	9
Disease	
CSM	22
OPLL	5
Factor	Value
No. of enlarged laminae	
2	4
3	8
4	15
Operation time (minutes)	
Range	85-217
Mean±SD	147.6±32.4
Preoperative JOA score	
Range	1.5-13.5
Mean±SD	10.3±2.9
Postoperative JOA score	
Range	6.5-16.5
Mean±SD	14.8±2.1
JOA % improvement	
Range	31.6-90.9
Mean±SD	70.5±14.8

the time; stage 1, 42 baskets; 22.8%, stage 2, 71 baskets: 38.6%, stage 3, 49 baskets: 26.6%, and stage 4, 22 baskets: 12.0%. Circumferential fusion was confirmed 59.8% of the time, whereas the nonunion rate on both sides was 6.5%.

## DISCUSSION

The main purpose of the present study was to investigate the radiological union rate at the open side after laminoplasty. The L-Basket titanium plate with a titanium box associated with satisfactory short-term clinical results. In the present study, bone union at the hinge side was

observed in 83/92 (90.2%) of 27 patients at 12 months; these data are similar to results published in other studies.<sup>[6,8]</sup> Our bone union rate on the open side reached 62.0%, whereas circumferential bone fusion was noted in 55/92 (59.8%) cases. Postoperatively, we observed no basket migration or complications other than one C5 transient root palsy. We would conclude the titanium basket implant provided immediate stabilization and continuous fixation following open door laminoplasty and provided a high rate of fusion on both the hinged and open sides.

## Financial support and sponsorship

Nil.

## Conflicts of interest

There are no conflicts of interest.

## REFERENCES

1. Deutsch H, Mummaneni PV, Rodts GE, Haid RW. Posterior cervical laminoplasty using a new plating system. *J Spinal Disord Tech* 2004;17:317-20.
2. Iguchi T, Kanemura A, Kurihara A, Kasahara K, Yoshida S, Doita M, et al. Cervical laminoplasty: Evaluation of bone bonding of a high porosity hydroxyapatite spacer. *J Neurosurg* 2003;98 (2 Suppl):137-142.
3. Jin SW, Kim SH, Kim BJ, Choi JI, Ha SK, Kim SD, et al. Modified open-door laminoplasty using hydroxyapatite spacers and miniplates. *Korean J Spine* 2014;11:188-94.
4. Kihara S, Umebayashi T, Hoshimaru M. Technical improvements and results of open-door expansive laminoplasty with hydroxyapatite implants for cervical myelopathy. *Neurosurgery* 2005;57 (4 Suppl):348-56.
5. Lee S, Chung CK, Kim CH. Risk factor analysis of hinge fusion failure after plate-only open-door laminoplasty. *Global Spine J* 2015;5:9-16.
6. Rhee JM, Register B, Hamasaki T, Franklin B. Plate-only open door laminoplasty maintains stable spinal canal expansion with high rate of hinge union and no plate failures. *Spine (Phila Pa 1976)* 2011;36:9-14.
7. Takayasu M, Takagi T, Nishizawa T, Osuka K, Nakajima T, Yoshida J. Bilateral open-door cervical expansive laminoplasty with hydroxyapatite spacers and titanium screws. *J Neurosurg (Spine 1)* 2002;96:22-8.
8. Tanaka N, Nakanishi K, Fujimoto Y, Sasaki H, Kamei N, Hamasaki T, et al. Expansive laminoplasty for cervical myelopathy with interconnected porous calcium hydroxyapatite ceramic spacers: Comparison with autogenous bone spacers. *J Spinal Disord Tech* 2008;21:547-52.
9. Tanaka S, Tashiro T, Gomi A, Ujiiie H. Cervical unilateral open-door laminoplasty with titanium miniplates through newly designed hydroxyapatite spacers. *Neurol Med Chir (Tokyo)* 2011;51:673-7.
10. Tani S, Suetsuna F, Mizuno J, Uchikado H, Nagashima H, Akiyama M, et al. New titanium spacer for cervical laminoplasty: Initial clinical experience. *Neurol Med Chir (Tokyo)* 2010;50:1132-36.
11. Tung KL, Cheung P, Kwok TK, Wong KK, Mak KH, Wong WC. Single-door cervical laminoplasty using titanium miniplates alone. *J Orthop Surg* 2015;23:174-9.