

Case Report

Fourth ventricle neurocysticercosis: Rigid endoscopic management. Description of direct transcerebellar approach

A. Ceja-Espinosa, J. A. Franco-Jiménez, A. Sosa-Nájera, G. A. Gutiérrez-Aceves, M. I. Ruiz-Flores

Neurosurgery Department, Centro Médico "Lic. Adolfo López Mateos", Instituto de Salud del Estado de México, Av. Nicolas San Juan s/n Ex Hacienda La Magdalena, Estado de México, México

E-mail: *A. Ceja-Espinosa - alexcjae@hotmail.com; J. A. Franco-Jiménez - franco-doc@hotmail.com; A. Sosa-Nájera - antonio01986@hotmail.com; G. A. Gutiérrez-Aceves - neuroaxa@gmail.com; M. I. Ruiz-Flores - mdruizmilton79@yahoo.com.mx

*Corresponding author

Received: 08 July 17 Accepted: 18 July 17 Published: 26 September 17

Abstract

Background: Endoscopy has gained a crucial role in high specialty neurosurgery during the last decades. At present, there are well-defined flexible neuroendoscopic procedures to treat ventricular and subarachnoid space pathologies. Neurocysticercosis is recognized as a common cause of neurologic disease in developing countries and the United States. Surgical intervention, especially cerebrospinal fluid diversion, is the key for management of hydrocephalus. In 2002, a consensus suggested that ventricular forms should be treated with endoscopy as the first option.

Case Description: Here, we present the case of a 51-year-old right-handed male, from Estado de México. Two days before admission he experienced holocraneal headache 7/10 on the visual analogue scale which was intermittent, with no response to any medication, sudden worsening of pain to 10/10, nausea, and vomit. On physical examination, he presented with 14 points in the Glasgow coma scale (M6, O4, V4), pupils were 3 mm, there was adequate light-reflex response, and bilateral papilledema. The cranial nerves did not have other pathological responses, extremities had adequate strength of 5/5, and normal reflexes (++++) were noted. Neuroimaging studies showed dilatation of the four ventricles as well as a cystic lesion in the fourth ventricle. Surgical position was Concorde, and the approach through a suboccipital burr hole was planned preoperatively with craneometric points. A rigid Karl Storz Hopkins II® endoscope was inserted directly through the cerebellum and the cystic lesion was extracted entirely.

Conclusion: This article presents a useful technique with low morbidity and mortality. Further investigation is needed, especially in our Mexico, where neuroendoscopical techniques are still in the development phase.

Key Words: 4th ventricle neurocysticercosis, neuroendoscopy, transcerebellar approach

Access this article online

Website:www.surgicalneurologyint.com**DOI:**

10.4103/sni.sni_251_17

Quick Response Code:

This is an open access article distributed under the terms of the Creative Commons Attribution-NonCommercial-ShareAlike 3.0 License, which allows others to remix, tweak, and build upon the work non-commercially, as long as the author is credited and the new creations are licensed under the identical terms.

For reprints contact: reprints@medknow.com

How to cite this article: Ceja-Espinosa A, Franco-Jiménez JA, Sosa-Nájera A, Gutiérrez-Aceves GA, Ruiz-Flores MI. Fourth ventricle neurocysticercosis: Rigid endoscopic management. Description of direct transcerebellar approach. *Surg Neurol Int* 2017;8:232.

<http://surgicalneurologyint.com/Fourth-ventricle-neurocysticercosis-Rigid-endoscopic-management-Description-of-direct-transcerebellar-approach/>

BACKGROUND

Endoscopy has gained a crucial role in high specialty neurosurgery during the last decades. It started being used in neurosurgery 30 years ago and is the approach of choice for multiple pathologies such as spontaneous intracranial hemorrhage, hydrocephalus, pituitary adenoma, and intraventricular tumors.^[8]

The fourth ventricle was originally studied by Galen^[1] and Da Vinci and was described as part of the ventricular system by Vesalius, but it remained a poorly understood structure until the nineteenth century. Magendie^[15] named the central foramen and Luschka^[16] the lateral foramina. A surgical approach to it was not possible until the early twentieth century when it was developed by Cushing and Dandy.^[10] The development of the flexible neuroendoscopy started a new era for intraventricular endoscopy.^[7] At present, there are well-defined flexible neuroendoscopic procedures to treat ventricular and subarachnoid space pathologies. These procedures have been classified into basic and advanced.^[11-13] The exploration of the fourth ventricle is considered an advanced endoscopic procedure. In general, pathologies within the fourth ventricle are associated with hydrocephalus; therefore, an endoscopic approach serves two goals – diagnosis and therapeutic.

The fourth ventricle exploration has been reported by Torres-Corzo *et al.* in tri or tetraventricular hydrocephalus;^[14] they mainly described their technique through a frontal approach using a flexible endoscope.

Neurocysticercosis is recognized as a common cause of neurologic disease in developing countries as well as the United States. The pathogenesis and clinical manifestations vary with the site of infestation and the accompanying host response. Ventricular neurocysticercosis often causes obstructive hydrocephalus. Surgical intervention, especially cerebrospinal fluid diversion, is the key to the management of hydrocephalus. Shunt failure may be less frequent when patients are treated with prednisone and/or antiparasitic drugs. Subarachnoid cysticercosis is associated with arachnoiditis. Arachnoiditis may result in meningitis, vasculitis with stroke, or hydrocephalus. Patients should be treated with corticosteroids, antiparasitic drugs, and shunting if hydrocephalus is present.^[17]

In 2002, a consensus suggested that ventricular forms should be treated with endoscopy as the first option.^[5] Husain *et al.* in 2007 described the removal of fourth ventricle neurocysti with an endoscopic procedure through a transaqueductal approach and angiographic catheter.^[6] Other surgical techniques have been described to approach the fourth ventricle endoscopically most of which involve a suboccipital craniotomy or a transforaminal transaqueductal

approach.^[9] We describe a case with rigid endoscopic transcerebellar approach.

CASE DESCRIPTION

A 51-year-old right-handed male, from Estado de México, presented with deficient hygiene and dietary habits. He was hypertense since 5 months prior to presentation which was controlled with losartan (40 mg once daily). Two days before admission, he experienced holocraneal headache 7/10 in the visual analogue scale, intermittent, with no response to any medication, sudden worsening of pain to 10/10, nausea, and vomit. On physical examination, he presented with 14 points in the Glasgow coma scale (M6, O4, V4), pupils were 3 mm, adequate light-reflex response, and bilateral papilledema. The cranial nerves did not have other pathological responses, extremities had adequate strength 5/5, and normal reflexes (++) were noted. He presented with gait disturbance with lateralization to the right side [Figure 1].

We describe our surgical decision and rationale for this management. The patient had classical clinical symptoms of intracranial hypertension such as headache, nausea and vomiting. The computed tomography (CT) scans showed tetraventricular hydrocephalus and important dilatation of the fourth ventricle, due to this finding and because of the high prevalence of neurocysticercosis in our country,

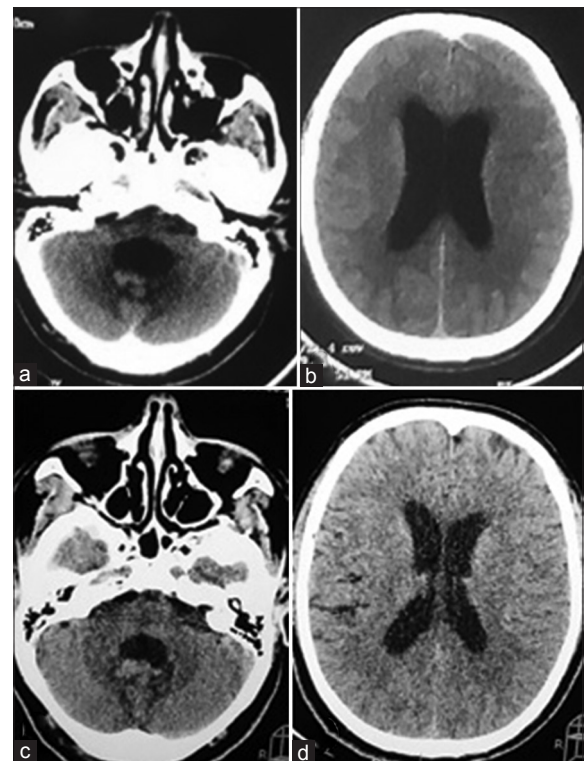


Figure 1: (a and b) Preoperative CT scan with tetraventricular dilatation. (c and d) Postoperative CT scan hydrocephalus resolved

we decided to perform a fourth ventricle exploration with the Hopkins II rigid endoscope (Karl Storz, Germany)[®]. In this case, we considered that the described approach for the exploration of the fourth ventricle through a prefrontal burr-hole with flexible endoscopy could be riskier than approaching just the fourth ventricle with one suboccipital burr hole because the third ventricle and cerebral aqueduct were not dilated enough to allow our endoscope to go through. The patient was placed in a Concorde position, with a soft head paddle, taking care of the pressure points to avoid any complication, and then adequate antisepsis of the region was performed with iodine solution. A single burr hole approach was made, which was planned 3 cm from the midline to the right side and 2 cm down from theinion. The burr hole was planned with craneometric points in the preoperative images, as shown, we did not use any image-guided system. The skin was approached in the standard manner until the suboccipital bone was reached. Then we performed the burr hole with a midas rex system and adequate hemostasis was made. The dura was opened in a cruciate form and then we performed a 1 cm cortisectomy with bipolar forceps. The rigid endoscope was inserted directly through the cerebellar cortical surface in the right hemisphere with a freehand approach. Just as soon as the endoscope passed through to the fourth ventricle, a cystic lesion was found, which was compatible with a neurocysti; as shown in the image it was not adherent to any of the fourth ventricle structures. We were able to remove the entire cystic lesion, and then we performed a fourth ventricle exploration, showing that the aqueduct and both Luschka foramina were permeable, as well as the obex. Surgical time was 40 minutes with no complications. The fourth ventricle ependymal showed no macroscopical findings of ependymitis, and due to the surgical procedure the cerebrospinal fluid flow was restored. Postoperatively, the patient did well and

was discharged home 48 hours later, with oral standard neurocysticercosis treatment with albendazole 15 mg/kg and corticosteroids [Figures 2 and 3].

CONCLUSION

As described by Bergsneider *et al.*,^[2] it is feasible to remove cystic lesions from the fourth ventricle, aided by the endoscope with low incidence of transoperative complications, however, this technique differs from ours because we did not perform a suboccipital craniotomy, just a keyhole approach with one burr hole.

In selected patients such as this one, that presents with a single neurocysti in the fourth ventricle and tetraventricular hydrocephalus, we consider that cerebrospinal fluid diversion with a shunt device has risks such as malfunction or infection, and also the CSF diversion would not remove the neurocysti that would keep the inflammatory response of the host going on, and this could lead to complications such as neurological deterioration and death.

In addition, medical treatment has shown partial results in the intraventricular forms of neurocysticercosis.^[4] With complete removal of the cystic lesion, we avoided shunting of cerebrospinal fluid and the complications described for this procedure such as infection, dysfunction, misplacement, intestinal perforation, as well as the dependence to the shunt devices.^[3]

Because there is no consensus regarding the management of the fourth ventricular cysticercosis, we consider that this paper shows a useful technique that can be introduced to the neuroendoscopic field to treat this pathology. Further investigation is needed, especially in Mexico where neuroendoscopic techniques are still in the developmental phase.

Financial support and sponsorship

Nil.

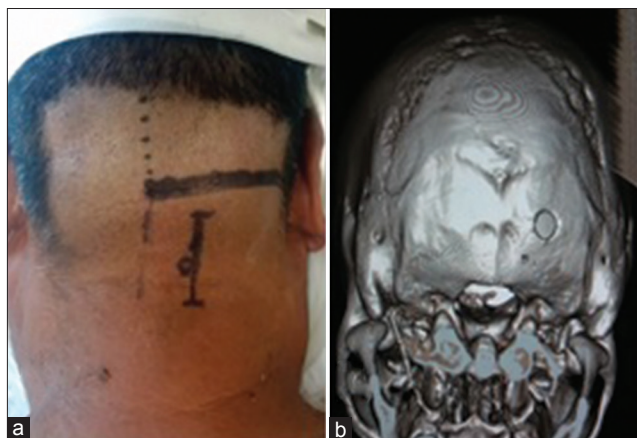

Figure 2: (a) The surgical planning with the vascular anatomic structures in the posterior fossa. **(b)** 3D reconstruction of CT scan with burr hole at the occipital bone

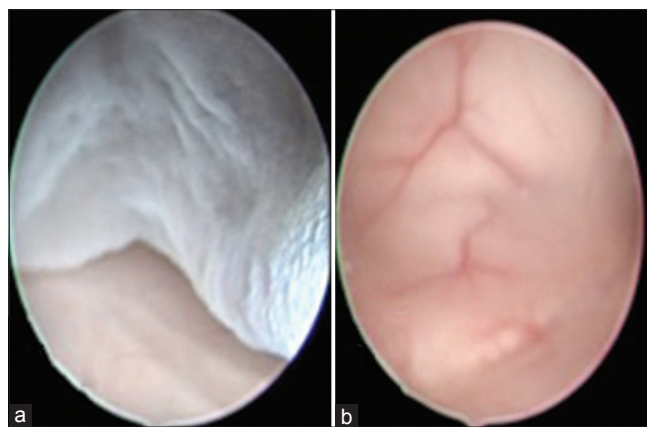


Figure 3: (a) Neurocysti in the 4th ventricle. **(b)** After the extraction of the cystic lesion. Ependyma of the 4th ventricle

Conflicts of interest

There are no conflicts of interest.

REFERENCES

1. Baig MN, Chishty F, Immesoete P, Karas CS. The Eastern Heart and Galen's ventricle: A historical review of the purpose of the brain. *Neurosurg Focus* 2007;23:E3.
2. Bergsneider M. Endoscopic removal of cysticercal cysts within the fourth ventricle: Technical note. *J Neurosurg* 1999;91:340-5.
3. Blount JP, Campbell JA, Haines SJ. Complications in ventricular cerebrospinal fluid shunting. *Neurosurg Clin N Am* 1993;4:633.
4. Carpio A, Santillán F, León P, Flores C, Hauser WA. Is the course of neurocysticercosis modified by treatment with antihelmintic agents? *Arch Intern Med* 1995;155:1982-8.
5. García HH, Evans CA, Nash TE, Takayanagui OM, White Jr AC, Botero D, et al. Current consensus guidelines for treatment of neurocysticercosis. *Clin Microbiol Rev* 2002;15:747-56.
6. Husain M, Rastogi M, Jha DK, Husain N, Gupta RK. Endoscopic transaqueductal removal of fourth ventricular neurocysticercosis with an angiographic catheter. *Neurosurgery* 2007;60(Suppl 2):249-54.
7. Matula C, Reinprecht A, Roessler K, Tschabitscher M, Koos WT. Endoscopic exploration of the IVth ventricle. *Minim Invasive Neurosurg* 1996;39:86-92.
8. Méndez PJA, Bargés CJ, Méndez RD. Neurocirugía endoscópica, la nueva era. *Residente* 2009;4(2).
9. Ranjan M, Konar SK, Somanna S, Bhagavatula ID, Ashwathnarayana CB. Endoscopic intervention for the fourth ventricular neurocysticercal cyst: What should be the optimum therapeutic approach? *Br J Neurosurg* 2014;28:626-30.
10. Rodríguez-Della Vecchia R, Torres-Corzo J, Chalita Williams JC, Rangel-Castilla L. "Historia de la endoscopia". In: Ramos Zuñiga R. *Tractos Históricos de la Neurocirugía en México*. Guadalajara, México: Ediciones de la Noche; 2012.
11. Torres-Corzo J, Rangel-Castilla L. Flexible Neuroendoscopy: Part II—Clinical and diagnostic indications. *Contempor Neurosurg* 2013;35:1-5.
12. Torres-Corzo J, Rangel-Castilla L. Flexible Neuroendoscopy: Part III-Basic endoscopic procedures and advantages of flexible neuroendoscopy. *Contempor Neurosurg* 2013;35:1-6.
13. Torres-Corzo J, Rangel-Castilla L. Flexible Neuroendoscopy: Part IV – Advanced endoscopic procedures and complications of flexible neuroendoscopy. *Contempor Neurosurg* 2013;35:6.
14. Torres-Corzo J, Rangel Castilla L, Nakaji P. *Neuroendoscopic Surgery*. 1st ed. Thieme; 2016.
15. Tubbs RS, Loukas M, Shoja MM, Shokouhi G, Oakes WJ. Francois Magendie and his contributions to the foundations of neuroscience and neurosurgery. *J Neurosurg* 2008;108:1038-42.
16. Tubbs RS, Vahedi P, Loukas M, Shoja MM, Cohen-Gadol AA. Hubert von Luschka: His life, discoveries, and contributions to our understanding of the nervous system. *J Neurosurg* 2011;114:268-72.
17. White Jr AC. Neurocysticercosis: Updates on epidemiology, pathogenesis, diagnosis and management. *Ann Rev Med* 2000;51:187-206.