

Case Report

Epidural cerebrospinal fluid collection following lumbar puncture in an adult patient: A case report and literature review

Jonathon Cavaleri, Jennifer L. Perez, Alp Ozpinar¹, Nima Alan¹, Edward Monaco III¹Department of Neurological Surgery, University of Pittsburgh Medical Center, ¹University of Pittsburgh School of Medicine, Pittsburgh, Pennsylvania, USAE-mail: Jonathon Cavaleri - cavaleri.johnathon@medstudent.pitt.edu; Jennifer L. Perez - perez.jennifer@medstudent.pitt.edu; Alp Ozpinar - ozpinara@upmc.edu; Nima Alan - alann@upmc.edu; *Edward Monaco III - monaco2@upmc.edu

*Corresponding author

Received: 26 December 17 Accepted: 05 April 18 Published: 22 August 18

Abstract

Background: Cerebrospinal fluid (CSF) leakage into the epidural space following lumbar puncture (LP) has been documented in pediatric patients, but there have been no reported cases in adults.

Case Description: We report an epidural CSF leak in an adult who presented with back pain, positional headache, urinary retention, and constipation following an LP performed as a part of a research study. The patient's magnetic resonance (MR) scan showed an extensive epidural CSF collection. Following placement in a recumbent position for 72 h, the collection fully resolved along with his neurological complaints.

Conclusion: Symptomatic epidural CSF collections rarely occur in adults following LPs. Nevertheless, the management remains the same as for pediatric patients; bed rest for 72 h results typically in full resolution of symptoms/signs and regression of the collection on MR studies.

Key Words: Adults, cerebrospinal fluid leak, epidural, lumbar puncture, magnetic resonance, pediatrics, review, resolution of symptoms and signs

Access this article online

Website:www.surgicalneurologyint.com**DOI:**

10.4103/sni.sni_476_17

Quick Response Code:

INTRODUCTION

There are multiple complications associated with performing lumbar punctures (LPs) in children, but few are typically reported in adult patients. Most commonly, headache and backache occur together approximately 20%–30% of the time. More serious and rare complications of LPs in adults include meningitis, hematoma, radicular pain, cranial nerve palsy, and cerebral herniation. Here we present a 26-year-old male who developed a significant epidural cerebrospinal fluid (CSF) collection following an uneventful LP performed as part of a research study. He was successfully treated with bed rest alone for 72 h, resulting in full resolution of his symptoms, signs, and epidural magnetic resonance (MR) collection.

CASE DESCRIPTION

A 26-year-old male presented to the emergency department (ED) with lower back pain 1 day after having had an LP performed as part of a research study.

This is an open access journal, and articles are distributed under the terms of the Creative Commons Attribution-NonCommercial-ShareAlike 4.0 License, which allows others to remix, tweak, and build upon the work non-commercially, as long as appropriate credit is given and the new creations are licensed under the identical terms.

For reprints contact: reprints@medknow.com

How to cite this article: Cavaleri J, Perez JL, Ozpinar A, Alan N, Monaco III E. Epidural cerebrospinal fluid collection following lumbar puncture in an adult patient: A case report and literature review. *Surg Neurol Int* 2018;9:169.

<http://surgicalneurologyint.com/Epidural-cerebrospinal-fluid-collection-following-lumbar-puncture-in-an-adult-patient--A-case-report-and-literature-review/>

The pain started 2 h after the LP and spread to his lower back. A lumbar computed tomography (CT) scan performed in the ED was negative, and the patient was discharged home with oxycodone. The next day, the patient returned with diffuse frontal postural headaches, bilateral lower extremity numbness, tingling, weakness, difficulty voiding, and constipation. On examination, he exhibited bilateral myelopathy, radiculopathy, and saddle hypoesthesia, but intact rectal tone. The lumbar, thoracic, and cervical (L/T/C) MR scans revealed an extensive epidural CSF collection extending from C7-T1 to L5 resulting in moderate dorsal/lateral cord/thecal sac compression without any increased signal in the cord at any level [Figure 1a-g]. The MR scan also documented that his bladder was distended indicative of urinary retention.

Management of epidural dorsolateral cord/thecal sac compression C7-T1 to L5

The patient was treated with strict bed rest for 72 h. He required a Foley catheter for 48 h. Subsequently, he was discharged neurologically intact; all symptoms/signs resolved. The 3-day follow-up L/T/CMR showed full resolution of epidural collection. Six weeks later, he had no residual neurologic deficit, and the MR studies continued to show full resolution of the original dorsolateral C7/T1 to L5 epidural CSF collection [Figure 1d].

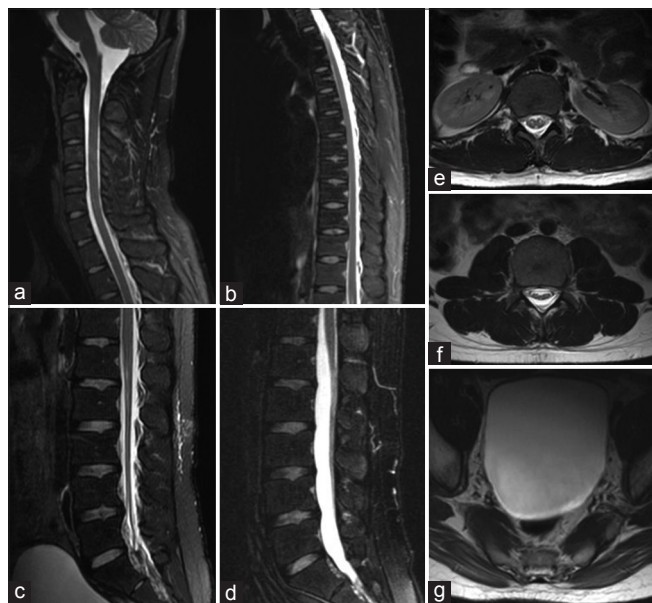


Figure 1: MRI visualization of epidural CSF collection extending from lumbar spine to C7-T1 in an adult patient following LP. (a) Sagittal T2 fast relaxation fast spin echo (FRFSE) MRI image of the cervical and upper thoracic spine C7-T1. (b) Sagittal T2 FRFSE image of the entire thoracic spine. (c) Sagittal T2 FRFSE image of the lumbar spine. (d) Sagittal T2 FRFSE image of the lumbar spine at 6-week follow-up. (e and f) Axial T2 FRFSE image at the levels of L1 and L3, respectively. (g) Axial T2 FRFSE image visualizing the bladder, showing considerable urinary retention

DISCUSSION

There are rare reports of symptomatic epidural CSF collections after LPs were performed in neonates, but these are rarely found in adults. In neonates, Kiechl-Kohlendorfer *et al.*^[2] found on ultrasound that 21 of 33 patients (64%) undergoing LP had evidence of epidural CSF leakage (eight thoracic, four cervical); these spontaneously resorbed within 2–10 days. Koch *et al.*^[3] found that MR studies in 25 pediatric patients (average age 5 years, 1 month old) undergoing LPs had epidural CSF collections on MR scans; symptoms also fully resolved with conservative treatment. When Amini *et al.*^[1] described a 4-year-old who developed a cauda equina syndrome after an LP, the symptoms, signs, and MR findings of an epidural CSF collection (cervicothoracic-sacrum) also resolved with bed rest alone over 48 h.

CONCLUSION

Here we presented an adult and reviewed the literature regarding the rare risks of epidural dorsolateral MR-documented collections in adults having LPs. In this instance, a 26-year-old male, following an LP performed in a research study, developed an epidural C7-T1 to L5 dorsolateral epidural CSF collection that resolved, along with his symptoms/and signs with 72 h of bed alone.

Declaration of patient consent

The authors certify that they have obtained all appropriate patient consent forms. In the form the patient(s) has/have given his/her/their consent for his/her/their images and other clinical information to be reported in the journal. The patients understand that their names and initials will not be published and due efforts will be made to conceal their identity, but anonymity cannot be guaranteed.

Financial support and sponsorship

Nil.

Conflicts of interest

There are no conflicts of interest.

REFERENCES

1. Amini A, Liu JK, Kan P, Brockmeyer DL. Cerebrospinal fluid dissecting into spinal epidural space after lumbar puncture causing cauda equine syndrome: Review of the literature and illustrative case. *Childs Nerv Syst* 2006;22:1639-41.
2. Kiechl-Kohlendorfer U, Unsinn KM, Schlenck B, Trawöger R, Gassner I. Cerebrospinal fluid leakage after lumbar puncture in neonates: Incidence and sonographic appearance. *AJR Am J Roentgenol* 2003;181:231-4.
3. Koch BL, Moosbrugger EA, Egelhoff JC. Symptomatic spinal epidural collections after lumbar puncture in children. *Am J Neuroradiol* 2007;28:1811-6.