

Case Report

Progressive edematous lesions in subacute phase after neuroendovascular therapy

Tomoyoshi Kuribara, Koichi Haraguchi, Shunya Ohtaki, Tadakazu Shimizu, Nobuki Matsuura, Kazumi Ogane, Yasunori Maruo¹, Noriyuki Yokoyama¹, Takeshi Mikami², Takeo Itou, Nobuhiro Mikuni²

Department of Neurosurgery, Hakodate Shintoshi Hospital, ¹Department of Neurology, Hakodate Municipal Hospital, Hakodate, ²Department of Neurosurgery, Sapporo Medical University, Sapporo, Hokkaido, Japan

E-mail: Tomoyoshi Kuribara - kuribara@yushinkai.jp; *Koichi Haraguchi - haraguchi@yushinkai.jp; Shunya Ohtaki - sotaki@sapmed.ac.jp; Tadakazu Shimizu - t-shimizu@yushinkai.jp; Nobuki Matsuura - matsuura@kuhp.kyoto-u.ac.jp; Kazumi Ogane - kansanrumoi3812@yahoo.co.jp; Yasunori Maruo - maruo@hospital.hakodate.hokkaido.jp; Noriyuki Yokoyama - n-yokoyama@hakodate-ishikai-hp.jp; Takeshi Mikami - tmikami@sapmed.ac.jp; Takeo Itou - itou@yushinkai.jp; Nobuhiro Mikuni - mikunin@sapmed.ac.jp
*Corresponding author

Received: 21 May 18 Accepted: 20 July 18 Published: 28 August 2018

Abstract

Background: The appearance of edematous lesions in the subacute phase is a rare complication following neuroendovascular therapy. Effective management of these lesions remains unclear. In this report, a case with progressive edematous lesions in the subacute phase after neuroendovascular therapy was described, and the clinical features and therapeutic strategies were discussed.

Case Description: A 54-year-old female with a large, right cavernous internal carotid artery aneurysm was treated with a flow diverter. Left hemiparesis developed 15 days after the procedure, and multiple edematous lesions in areas of prior catheter procedures were revealed on radiological findings. Steroid pulse therapy was employed, and the lesions were gradually reduced without any additional neurological deficits. No recurrence was recognized in the follow-up study.

Conclusion: In some reports, pathological findings indicate that these lesions result from the presence of foreign bodies, and emboli could be caused by cotton fibers or hydrophilic polymers used as surface coatings on endovascular catheters. In this case, the edematous lesions were most likely caused by hydrophilic polymer emboli. Steroid pulse therapy had a beneficial effect on the lesions. It is important to effectively manage prescribed periods after the procedure to avoid such a rare complication.

Key Words: Flow diverter, foreign body emboli, hydrophilic polymer, neuroendovascular therapy

Access this article online

Website:

www.surgicalneurologyint.com

DOI:

10.4103/sni.sni_152_18

Quick Response Code:

INTRODUCTION

Neuroendovascular therapy is commonly used for intracranial aneurysms. Recently, the complication rate of this procedure is relatively low and mostly includes thromboembolic events and intraprocedure aneurysm rupture. Foreign body emboli in the distal cerebral arteries during neuroendovascular therapy are

This is an open access journal, and articles are distributed under the terms of the Creative Commons Attribution-NonCommercial-ShareAlike 4.0 License, which allows others to remix, tweak, and build upon the work non-commercially, as long as appropriate credit is given and the new creations are licensed under the identical terms.

For reprints contact: reprints@medknow.com

How to cite this article: Kuribara T, Haraguchi K, Ohtaki S, Shimizu T, Matsuura N, Ogane K, et al. Progressive edematous lesions in subacute phase after neuroendovascular therapy. *Surg Neurol Int* 2018;9:173.

<http://surgicalneurologyint.com/Progressive-edematous-lesions-in-subacute-phase-after-neuroendovascular-therapy/>

occasionally encountered, and are a potential cause of ischemic stroke and parenchymal hemorrhage. Of these cases, there have been only a few reports concerning focal edematous lesions.^[1-9] Although the pathological basis of these lesions is postulated from the surgical specimens,^[2] effective therapeutic strategies remain unclear. In this report, we present a case of multiple edematous lesions in the subacute phase following neuroendovascular therapy, and we review their clinical features and therapeutic management.

CASE REPORT

A 54-year-old female with a history of nephrotic syndrome and hypertension presented with a persistent headache at her local clinic. A right thrombosed cavernous internal carotid artery aneurysm measuring 22.5 × 19.7 × 19.2 mm was detected on computed tomography angiography (CTA). She was introduced to our hospital and underwent flow diverter deployment for the aneurysm with a pipeline embolization device (PED) (Covidien, Irvine, California, USA). Under general anesthesia, a 5 Fr Navien 058 Intracranial Support Catheter (Covidien, Irvine, California, USA) and a Marksman Catheter (Covidien, Irvine, California, USA) were advanced over the neck of the aneurysm using a 0.014 inch Asahi Chikai microguidewire (Asahi Intecc, Aichi, Japan) through the shuttle sheath. A 4.75/20 mm PED was deployed to cover the neck of the aneurysm through the triaxial system, and the stent was re-sheathed twice. The procedure was performed in 61 min without any complications [Figure 1a and b], though diffusion-weighted imaging (DWI) after the procedure revealed a few scattered hyperintensities in the right hemisphere [Figure 2a and b]. Fifteen days after the procedure, left hemiparesis developed and multiple edematous lesions were revealed in the right hemisphere on magnetic resonance imaging (MRI) 28 days after the procedure [Figure 2c and d]. The hemiparesis gradually progressed, and the edematous lesions were enlarged on MRI [Figure 2e and f]. At this time, white blood cell

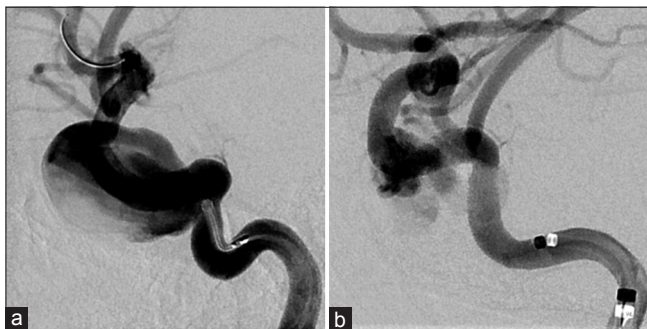


Figure 1: Preprocedural angiography showed a right large cavernous internal carotid artery aneurysm (a). Postprocedural angiography showed a remarkable reduction of the blood flow to the aneurysm (b)

count was 149×10^2 cells/mm³, C-reactive protein was 2.37 mg/dl, and creatinine was 1.28 mg/dl. Three courses of steroid pulse therapy (intravenous administration of methylprednisolone 1000 mg daily × 3 days and oral prednisolone 50 mg daily × 4 days) were then performed.

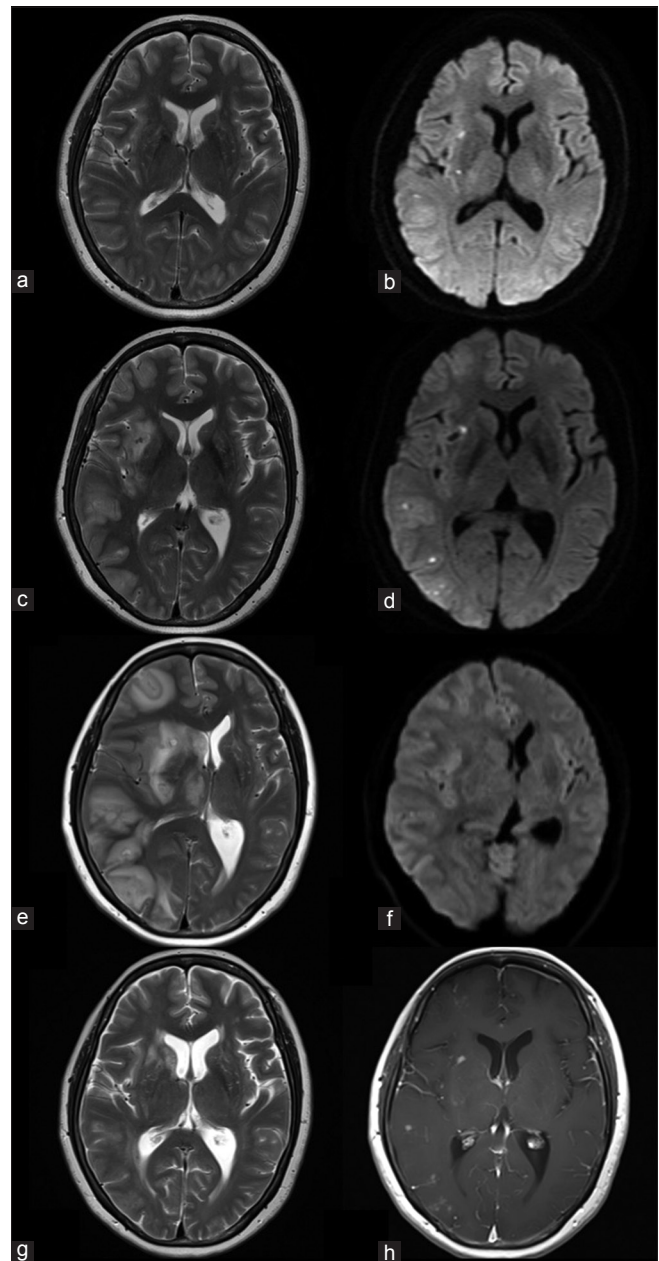


Figure 2: T2-weighted magnetic resonance imaging after the procedure showed no edema (a) and diffusion-weighted imaging showed a few hyperintensities in the right hemisphere (b). Magnetic resonance imaging 28 days after the procedure showed multiple edematous lesions in the right hemisphere (c), although there were no remarkable changes in diffusion-weighted imaging (d). Magnetic resonance imaging 42 days after the procedure showed a progression of edemas (e), though there were no remarkable changes on diffusion-weighted imaging (f). Magnetic resonance imaging after three courses of steroid pulse therapy (81 days after the procedure) showed a regression of edemas (g), and Gd-enhanced T1-weighted magnetic resonance imaging showed residual multiple enhancing lesions (h)

Subsequently, hemiparesis was improved in association with the improvement of edemas [Figure 2g]. Eighty-one days after the procedure, the edemas were diminished, though nodular enhancing lesions were persistent on contrast-enhanced MRI [Figure 2h]. During the 6-month follow-up periods, there has been no recurrence and no neurological deficits.

DISCUSSION

Clinical features of edematous lesions following neuroendovascular therapy are summarized in Table 1. The time from the procedure to the appearance of the clinical presentation varied from 1 day to 9 months,^[2-8,10-13] indicating that the complications might possibly occur over relatively long periods. Delayed allergic reactions might be associated to the complications, although there is no finding to support this. In terms of embolic sources, cotton fibers have been reported in previous studies,^[10] though hydrophilic polymers applied as a surface coating on endovascular catheters are the most common cause in recent years.^[1,9] From DWI findings, the scattered hyperintensities after the procedure are thought to be

foreign body emboli and inflammatory cells surrounding them rather than acute cerebral infarctions, because their locations seem to be atypical for ischemic lesions and are at center of each edematous lesion. Moreover, the edematous lesions surrounding them are considered to be vasogenic edemas, and steroid therapy should be theoretically appropriate for such lesions. Steroid therapy is reported to result in relatively good prognoses.^[4,7,11] Cruz *et al.* reported seven cases of foreign body emboli, and one of the patients treated with steroids improved and showed no neurological deficit at their last follow up.^[2] Shapiro *et al.* reported five cases of similar lesions treated by steroids, and their MRI findings at the last follow up showed resolution of the edemas.^[11] Lorentzen *et al.* reported similar lesions after neuroendovascular therapy with a flow diverter. The patient was also treated with steroids and immunosuppressants, and showed substantial regression of the edemas.^[7] Overall, there are few cases of recurrences and progression, and the symptoms are relatively mild in comparison with their initial imaging findings. From a pathological point of view, cerebral inflammation caused by foreign body emboli could be related to these edematous lesions.

Table 1: Summary of 20 patients with multiple edematous lesions after neuroendovascular therapy

| n [reference] | Age/sex | Procedure | Device | Onset* | Presenting neurological sign(s)* | Treatment | Outcome |
|---------------|-----------|-----------|---------------------|-------------------|--|-----------------------------------|---------|
| 1 [7] | 58/female | SAC | BPC, BAC | 9 months | Hemiparesis, hemianesthesia, tonic-clonic seizure | Biopsy | DP |
| 2 [8] | 53/female | BLAC | BPC, BAC, HyperForm | 3 days | Hemiparesis, hemianesthesia, facial paresis, aphasia, dysarthria | Steroids, antibiotics, antivirals | CR |
| 3 [9] | 46/female | BLAC | BPC, BAC | 4 weeks, 10 weeks | Scintillating scotomas, dysmetria | Observation | CR |
| 4 [9] | 56/female | SAC, STAC | BAC, Enterprise | 9 months | Hemiparesthesia, difficulty ambulating | Observation | CR |
| 5 [10] | 71/female | SAC | BPC | N/A | N/A | N/A | N/A |
| 6 [10] | 51/male | SAC | BPC | N/A | N/A | N/A | N/A |
| 7 [10] | 62/female | BLAC | BAC, enterprise | N/A | N/A | N/A | N/A |
| 8 [10] | 32/female | BLAC | BPC | N/A | N/A | N/A | N/A |
| 9 [10] | 63/female | STAC | BPC, enterprise, TS | N/A | N/A | N/A | N/A |
| 10 [10] | 51/female | FDD | Silk | N/A | N/A | N/A | N/A |
| 11 [10] | 54/female | FDD | PED | N/A | N/A | N/A | N/A |
| 12 [11] | 33/female | BLAC | BPC, HyperForm | N/A | N/A | Observation | PR |
| 13 [12] | 65/female | SAC | BAC, Enterprise | 4 days | Hemiparesis | Steroids, IS | RD |
| 14 [5] | N/A | FDDC | PED, TS | 8 weeks | Hemiparesis, homonymous quadrantanopsia | Steroids, antibiotics | CR |
| 15 [5] | N/A | FDDC | PED, TS | 8 weeks | Homonymous quadrantanopsia | Steroids | PR |
| 16 [5] | N/A | FDDC | PED, TS | 2 weeks | Headache | Biopsy, steroids | PR |
| 17 [5] | N/A | FDDC | PED, TS | 1 day, 3 months | Hemiparesis, involuntary movement | Biopsy, steroids | RD |
| 18 [5] | N/A | STAC | TS | 2 weeks | Hemianesthesia, spasm | Steroids | PR |
| 19 [13] | 52/female | FDD | PED, TS | 3 months | Hemiparesis, ataxia, aphasia | Biopsy, steroids, IS | SD |
| Our case | 54/female | FDD | PED, TS | 15 days | Hemiparesis | Steroids, IS | |

*Postprocedural sign or symptom suspected from cerebral foreign body reaction. N/A: Not available, SAC: Simple aneurysm coiling, BLAC: Balloon-assisted coiling, STAC: Stent-assisted coiling, FDD: Flow diverter deployment, FDDC: Flow diverter deployment with coiling, BPC: Bare platinum coil, BC: Bioactive coil, HyperForm: Hyperform balloon (eV3 Neurovascular, Irvine, California, USA), Enterprise: Enterprise VRD (Johnson and Johnson Codman, Miami, Florida, USA), TS: Triaxial system, Silk: Silk flow diverter (Balt Extrusion, Montmorency, France), PED: Pipeline embolization device (Covidien, Irvine, California, USA), IS: Immunosuppressants, CR: Complete resolution, PR: Partial resolution, SD: Stable disease, PD: Progressive disease, RD: Recurrent disease

Mehta *et al.* reviewed several biopsy-proved cases of foreign body emboli with parenchymal inflammation. In all of these cases, foreign polymer materials and the surrounding inflammatory responses were identified pathologically.^[8] If necessary, immunosuppressants might also be considered for such lesions to suppress the reactions due to their anti-inflammatory effects.

Cerebral foreign body emboli could be related to intercatheter friction, made increasingly common by the adoption of the triaxial catheter technique for deployment of a flow diverter. For that reason, the incidence of this complication is expected to increase in the near future. Treatment with a flow diverter is currently on the rise for both large and giant unruptured aneurysms. Advanced catheter stability is necessary to obtain a precise and secure delivery of the device. To achieve this stability, it is customary to use the triaxial catheter technique, which can lead to increased friction between catheters and may create a predisposition for small emboli from the coating of the catheters. Our case might also be associated with the use of tight-fitting catheter combinations to deploy the device. The accumulation of similar cases is necessary to more fully understand the technical factors involved.

CONCLUSION

A case with progressive edematous lesions in the subacute phase after neuroendovascular therapy was described. In this case, the edematous lesions were most likely caused by hydrophilic polymer emboli. Steroid pulse therapy had beneficial effect on the lesions. It is important to effectively manage prescribed periods after the procedure to avoid such a rare complication.

Declaration of patient consent

The authors certify that they have obtained all appropriate patient consent forms. In the form the patient(s) has/have given his/her/their consent for his/her/their images and other clinical information to be reported in the journal. The patients understand that their names and initials will not be published and due efforts will be

made to conceal their identity, but anonymity cannot be guaranteed.

Financial support and sponsorship

Nil.

Conflicts of interest

There are no conflicts of interest.

REFERENCES

1. Barnwell SL, D'Agostino AN, Shapiro SL, Nesbit GM, Kellogg JX. Foreign bodies in small arteries after use of an infusion microcatheter. *AJNR Am J Neuroradiol* 1997;18:1886-9.
2. Cruz JP, Marotta T, O'Kelly C, Holtmannspötter M, Saliou G, Willinsky R, *et al.* Enhancing brain lesions after endovascular treatment of aneurysms. *AJNR Am J Neuroradiol* 2014;35:1954-8.
3. Deguchi K, Kawahara Y, Deguchi S, Morimoto N, Kurata T, Ikeda Y, *et al.* A patient develops transient unique cerebral and cerebellar lesions after unruptured aneurysm coiling. *BMC Neurol* 2015;15:49.
4. Deus-Silva L, Lum C, De Meulemeester C, dos Santos MP. Severe aggressive acute disseminated encephalomyelitis-like reaction after aneurysm coiling. *Neurosurgery* 2010;66:E222-3.
5. Fealey ME, Edwards WD, Giannini C, Piepgras DG, Cloft H, Rihal CS. Complications of endovascular polymers associated with vascular introducer sheaths and metallic coils in 3 patients, with literature review. *Am J Surg Pathol* 2008;32:1310-6.
6. Grewal SS, López Del Valle EM, Gupta V, Ramon N, Freeman WVD, Tawk RG. Neurological changes with abnormal brain reactivity following coiling of cerebral aneurysm. Possible reactivity to endovascular devices and material? *J Vasc Interv Neurol* 2015;8:28-36.
7. Lorentzen AO, Nome T, Bakke SJ, Scheie D, Stenset VA, Aamodt AH. Cerebral foreign body reaction after carotid aneurysm stenting. *Interv Neuroradiol* 2016;22:53-7.
8. Mehta RI, Mehta RI. Polymer-induced central nervous system complications following vascular procedures: Spectrum of iatrogenic injuries and review of outcomes. *Hum Pathol* 2016;53:178-90.
9. Mehta RI, Mehta RI, Solis OE, Jahan R, Salamon N, Tobis JM, *et al.* Hydrophilic polymer emboli: An under-recognized iatrogenic cause of ischemia and infarct. *Mod Pathol* 2010;23:921-30.
10. Shannon P, Bilbao JM, Marotta T, Terbrugge K. Inadvertent foreign body embolization in diagnostic and therapeutic cerebral angiography. *AJNR Am J Neuroradiol* 2006;27:278-82.
11. Shapiro M, Ollenschlegler MD, Baccin C, Becske T, Spiegel GR, Wang Y, *et al.* Foreign body emboli following cerebrovascular interventions: Clinical, radiographic, and histopathologic features. *AJNR Am J Neuroradiol* 2015;36:2121-6.
12. Silberman J, Cravioto H, Feigin I. Foreign body emboli following cerebral angiography. *Trans Am Neurol Assoc* 1960;85:123-5.
13. Skolarus LE, Gemmete JJ, Braley T, Morgenstern LB, Pandey A. Abnormal white matter changes after cerebral aneurysm treatment with polyglycolic-poly-lactic acid coils. *World Neurosurg* 2010;74:640-4.