

## Case Report

# Migrating spinal intradural schwannoma with adjacent disc herniation: A case report and brief literature review

Hossein Ghalaenovi, Arash Fattahi

Department of Neurosurgery, Iran University of Medical Sciences, Tehran, Iran

E-mail: Hossein Ghalaenovi - [hghalaenovi@yahoo.com](mailto:hghalaenovi@yahoo.com); \*Arash Fattahi - [arashmedicine@gmail.com](mailto:arashmedicine@gmail.com)

\*Corresponding author

Received: 13 August 18 Accepted: 24 September 18 Published: 05 November 18

## Abstract

**Background:** Schwannoma is the most common migrating tumor in the intradural space.

**Case Description:** We present a patient with migrating schwannoma of the cauda which admitted with buttock and thigh pain since 2 years ago. On two preoperative lumbosacral magnetic resonance imaging (MRI), he had a L2/3 disc herniation concomitant with the intradural extra-axial mass at level of the L1/2 disc on the first MRI and then on the second one, his mass was just posterior to the L3 vertebral body, 22 months later. During the surgical resection of the mass, we found it just posterior to the L2 body. In the literature, we found no accompaniment of migrating intradural spinal mass with adjacent intervertebral disc herniation caused by a double-level cerebro-spinal fluid (CSF) blockade, as it was with our case. On serial imaging, we have seen the mass above and then below the level of CSF blockade, resulting from an extra-dural disc herniation.

**Conclusion:** We think this rare case could promote a better understanding of the dynamic nature of the central nervous system and the peripheral nervous system within intradural space.

**Key Words:** CSF blockade, CSF dynamic, disc herniation, migrating schwannoma

### Access this article online

**Website:**[www.surgicalneurologyint.com](http://www.surgicalneurologyint.com)**DOI:**

10.4103/sni.sni\_284\_18

**Quick Response Code:**

## BACKGROUND

Migrating schwannomas of the cauda equina are reported in the literature.<sup>[3]</sup> Here, we present a patient whose lumbar intradural schwannoma migrated from L1/2 to the L3 level over a 22-month period and was accompanied by an L2/3 disc herniation.

## CASE DESCRIPTION

A 60-year-old male presented with 2 years of left buttock and posterior thigh pain that was exacerbated at night. On examination, he had muscle spasm, but no focal neurological deficits. The first lumbosacral magnetic resonance imaging (MRI) scan revealed an intradural

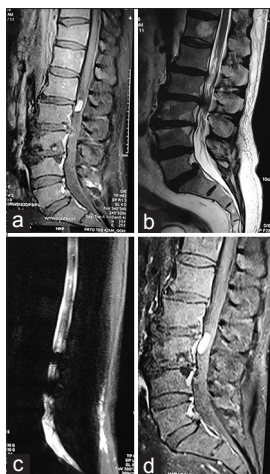
extramedullary mass with homogeneous enhancement at the L1/2 level accompanied by an L2/3 disc herniation [Figure 1a-c]. The second MRI, 22 months later, showed the tumor had migrated inferiorly and was now behind the L3 body [Figure 1d].

This is an open access journal, and articles are distributed under the terms of the Creative Commons Attribution-NonCommercial-ShareAlike 4.0 License, which allows others to remix, tweak, and build upon the work non-commercially, as long as appropriate credit is given and the new creations are licensed under the identical terms.

**For reprints contact:** [reprints@medknow.com](mailto:reprints@medknow.com)

**How to cite this article:** Ghalaenovi H, Fattahi A. Migrating spinal intradural schwannoma with adjacent disc herniation: A case report and brief literature review. *Surg Neurol Int* 2018;9:228.

<http://surgicalneurologyint.com/Migrating-spinal-intradural-schwannoma-with-adjacent-disc-herniation:-A-case-report-and-brief-literature-review/>



**Figure 1:** Twenty-two months ago, the first lumbosacral magnetic resonance imaging (MRI) with and without gadolinium revealed a well-defined intradural extra-axial mass that homogeneously enhanced posterior to the L1/2 disc space (a). There was also an L2/3 disc herniation (b and c). Twenty-two months later, the second MRI showed the mass migrated posterior to the L3 vertebral body, while the L2/3 disc herniation remained the same (d)

The patient underwent a laminectomy involving the L1, L2, and L3 levels. At surgery, the mass was behind the left L3 body, and its capsule was connected to one nerve root of the cauda. As the rootlet was intrinsically involved within the lesion, it was sacrificed in an en bloc fashion. Additionally, the L2/3 disc was removed. Three months later, the patient was asymptomatic. The histopathological exam was consistent with a schwannoma.

## DISCUSSION

The literature showed 28 cases of migrating spinal intradural masses that were predominantly schwannomas, followed by ependymomas and neurenteric cysts.<sup>[2,3,4,6]</sup> In 1991, Murai *et al.* reported a thoracolumbar neurenteric cyst that had migrated eight levels.<sup>[5]</sup> Other studies described a total of 10 migrating spinal cord schwannomas involving different levels.<sup>[3,6]</sup> Notably, however, no cases of migrating intradural spinal masses/schwannomas were associated with adjacent level intervertebral disc herniations.

The etiology of the migration of schwannomas within the spinal neuraxis is difficult to explain, although likely attributable to the: “dynamic nature of the central nervous system and peripheral nervous system in the CSF space”.<sup>[1]</sup>

## CONCLUSION

Here, we report a lumbar intradural schwannoma that migrated from the L1/2 to the L3 level over a 22-month period, accompanied by an L2/3 disc herniation.

## Declaration of patient consent

The authors certify that they have obtained all appropriate patient consent forms. In the form the patient(s) has/have given his/her/their consent for his/her/their images and other clinical information to be reported in the journal. The patients understand that their names and initials will not be published and due efforts will be made to conceal their identity, but anonymity cannot be guaranteed.

## Financial support and sponsorship

Nil.

## Conflicts of interest

There are no conflicts of interest.

## REFERENCES

1. Friedman JA, Atkinson JL, Lane JL. Migration of an intraspinal schwannoma documented by intraoperative ultrasound: Case report. *Surg Neuro* 2000;54:455-7.
2. Khan RA, Rahman A, Bhandari PB, Khan SK. Double migration of a schwannoma of thoracic spine. *BMJ Case Rep* 2013;2013. doi: 10.1136/bcr-2012-008182.
3. Lee DY, Chung HJ. Mobile schwannoma of the cauda equina diagnosed by magnetic resonance imaging and magnetic resonance myelography: A case report and review of the literatures. *Nerve* 2017;3:71-4.
4. Marin-Sanabria EA, Sih IM, Tan KK, Tan JS. Mobile cauda equina schwannomas. *Singapore Med J* 2007;48:e53-6.
5. Murai H, Arai M, Satoh K, Kataoka Y, Senma S. (Mobile spinal neurenteric cyst) A case report. *Seikei Geka* 1991;42:1746-9.
6. Naik S, Agarwal V, Kumar S. Migrating extramedullary intradural schwannoma of cervico-thoracic junction. *J Spine* 2016;5:323.