

Case Report

Primary tuberculous psoas abscess as a postpartum complication: Case report and literature review

Ali Akhaddar, Walter Hall¹, Mohammed Ramraoui², Mehdi Nabil, Ahmed Elkhader²Departments of Neurosurgery and ²Surgery, Avicenne Military Hospital of Marrakech, Mohammed V University in Rabat, Morocco, ¹Department of Neurosurgery, State University of New York (SUNY), Upstate Medical University, Syracuse, New York, USA

E-mail: *Ali Akhaddar - akhaddar@hotmail.fr; Walter Hall - hallw@upstate.edu; Mohammed Ramraoui - mramraoui@gmail.com; Mehdi Nabil - mehdi.nabil.benabdellah@gmail.com; Ahmed Elkhader - elkhader@gmail.com

*Corresponding author

Received: 22 September 18 Accepted: 25 October 18 Published: 28 November 18

Abstract

Background: Primary psoas abscess is an unusual clinical entity rarely encountered in the postpartum period. Only seven cases have been reported to date. Here, we present a woman with a primary psoas abscess caused by *Mycobacterium tuberculosis* and occurred 2 months following a normal vaginal birth. We highlight the difficulties in the management of this uncommon condition in light of the relevant literature.

Case Description: A 34-year-old woman who was previously healthy was presented at 2 months' postpartum with important right sciatica and low back pain without fever. Examination of the abdomen revealed tenderness in the right iliac fossa but obstetric/gynecologic and neurologic examinations were normal. The patient had an elevated C-reactive protein level and computed tomography (CT)-scan demonstrated a large psoas abscess on the right side without sacroiliac or spine abnormalities. Initial posterior lumbar percutaneous drainage was useful, but no pathogens were identified. The patient was discharged home with oral antibiotics therapy (amoxicillin/clavulanate and metronidazole). Four weeks later, the follow-up CT-scan showed a re-accumulation of the abscess cavity. Subsequently, the patient underwent a right anterolateral laparotomy with a retroperitoneal approach for abscess drainage. Again, no microorganisms were found. However, diagnosis of tuberculosis was established on histopathologic study. She was successfully treated with antituberculous drugs with a good outcome.

Conclusions: Most primary psoas abscesses present with a delay in diagnosis because of the rarity of this infectious disease, the lack of specific symptoms and signs, and its similarity to many differential diagnoses. When suspected, CT-scan and/or magnetic resonance imaging help in making an accurate diagnosis and facilitate percutaneous or open surgical drainage of the abscess. Correct and

Access this article online

Website:www.surgicalneurologyint.com**DOI:**

10.4103/sni.sni_329_18

Quick Response Code:

This is an open access journal, and articles are distributed under the terms of the Creative Commons Attribution-NonCommercial-ShareAlike 4.0 License, which allows others to remix, tweak, and build upon the work non-commercially, as long as appropriate credit is given and the new creations are licensed under the identical terms.

For reprints contact: reprints@medknow.com

How to cite this article: Akhaddar A, Hall W, Ramraoui M, Nabil M, Elkhader A. Primary tuberculous psoas abscess as a postpartum complication: Case report and literature review. *Surg Neurol Int* 2018;9:239.

<http://surgicalneurologyint.com/Primary-tuberculous-psoas-abscess-as-a-postpartum-complication:-Case-report-and-literature-review/>

fast identification of the microorganisms in addition to appropriate usage of antibiotic regimen improves the outcome.

Key Words: Complication, infection, postpartum, psoas abscess, recurrence, tuberculosis, vaginal delivery

INTRODUCTION

Since the first description of psoas (or iliopsoas) muscle abscess by Herman Mynter in 1881,^[18] this infection has been recognized as infrequent, insidious, misdiagnosed, and a potentially life-threatening condition.^[8,20] Psoas abscess can be either primary or secondary, depending on the presence or absence of an underlying infectious disease. *Staphylococcus aureus* is the most frequently isolated pathogen.^[9,20] Primary (isolated) tuberculous psoas abscess is currently uncommon and often associated with a concomitant spondylodiscitis (Pott's disease).^[11,6] Primary psoas abscess (PPA) is a rare complication in general obstetrics and gynecology. In addition, the diagnosis may be a particular challenge because pain in the lower back and buttocks is common and often nonspecific during pregnancy and the postpartum period. To the best of our knowledge, only six cases of PPAs were reported during ongoing pregnancy,^[26] two cases in the postabortal period,^[12,22] and seven cases in the postpartum period.^[4,5,13,19,21,24,29]

We present a woman who was found to have a primary tuberculous psoas abscess in the postpartum requiring two surgical drainages. We highlight the difficulties in the management of this uncommon condition in light of the relevant literature.

CASE REPORT

After a normal pregnancy and an uneventful vaginal birth of a healthy female infant, a 34-year-old biparous woman presented 2 months' postpartum with significant right sciatic-like back pain. She had no significant past medical history. The symptoms were initially misdiagnosed as a sciatic neuropathy and she was treated symptomatically at another medical center with a good outcome. On examination, she was afebrile and her vital signs were within normal limits. The examination of the abdomen revealed mild tenderness in the right iliac fossa but her obstetric/gynecologic examination was normal. In addition, the examination of the respiratory, cardiovascular, and central nervous systems revealed no abnormalities.

Initial blood tests showed a leukocytosis of 7.3, a hemoglobin of 10.9 g/dL, a raised C-reactive protein (CRP) level of 102 mg/L, and a normal procalcitonin level at 0.316 ng/mL. Serology tests were negative for human immunodeficiency virus (HIV-1 and HIV-2). Spinal lumbar and abdominal computed tomography scans (CT-scan) surprisingly showed a large right psoas abscess measuring

18 × 10 × 8 cm (a volume of about 720 mL) [Figure 1]. However, the right sacroiliac joint, the lumbar spine, and intervertebral disks appeared normal.

Posterior lumbar percutaneous drainage of the abscess was performed. Approximately, 570 mL of purulent fluid was obtained and a drain was left in place [Figure 2a]. Both polymerase chain reaction to detect *Mycobacterium tuberculosis* and acid fast staining were negative. Culture failed to grow any microorganisms (including mycobacterium and mycoses). She was treated with gentamicin, amoxicillin/clavulanate, and metronidazole parenterally. Her symptomatology improved daily. The follow-up CT-scan on day 2 postoperatively showed near complete resolution of the abscess [Figure 2b]. The drain was removed on postoperative day 4. The patient was discharged to home on postoperative day 15 with combined oral antibiotic therapy (amoxicillin/clavulanate and metronidazole) for 1 month.

Four weeks later, there was no recurrence of neurological symptoms except for mild low back pain. However, a repeat CT-scan of the abdomen and the pelvis showed a re-accumulation of the right psoas collection measuring approximately 400 mL. Subsequently, she underwent a right anterolateral minilaparotomy with a retroperitoneal approach for open abscess drainage. Again, no microorganisms were identified on culture. However, a diagnosis of tuberculosis was established after identification of epithelioid giant cells and caseous necrosis on the fibrotic abscess wall biopsy. The patient made an uneventful recovery and was discharged home on postoperative day 5. A follow-up CT-scan showed no re-accumulation of the abscess. She was successfully treated with antituberculous chemotherapy for 6 months with good clinical and radiological outcomes [Figure 2c].

DISCUSSION

In obstetrical practice, postpartum infection usually involves the uterus and adjacent pelvic structures presenting with typical and predictable symptoms and signs. However, musculoskeletal and focal neurological infections can rarely be seen in the postpartum period.^[2,3,16] Among them, PPA is uncommon. Few cases have been previously reported in postpartum patients, typically following normal vaginal delivery or cesarean section [Table 1]. PPA is generally seen in young males without an identifiable cause in most cases. In contrast, secondary psoas abscesses are generally seen in older individuals with chronic diseases.^[20]

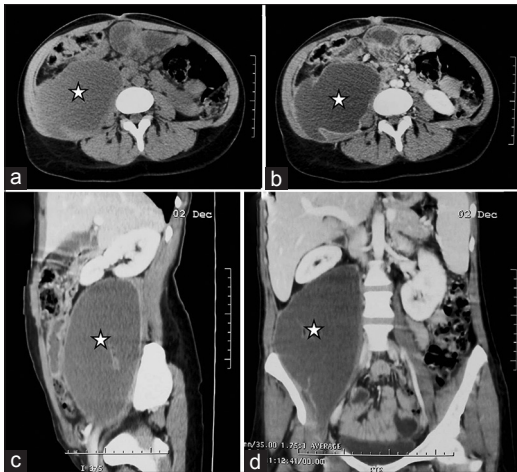


Figure 1: Axial abdominal and pelvic CT-scan before (a) and after (b) contrast injection. Sagittal (c) and coronal (d) abdominal reconstructions following contrast administration. There was a large right psoas muscle abscess (stars) displacing the right kidney upward. Note the presence of ring enhancement

The psoas muscle is in near proximity to anatomical structures such as the thoraco-lumbo-sacral spine, iliac lymph nodes, abdominal aorta, kidneys, ureters, pancreas, jejunum, sigmoid colon, and appendix. For this reason, infections of intra-abdominal organs can spread to the iliopsoas muscle. The important blood supply of this muscle is supposed to predispose it to hematogenous spread from occult sites of infection.^[17]

The clinical presentation of a psoas abscess is often variable and nonspecific.^[27] The classical clinical triad (fever, back pain, and lower extremity weakness) is present in less than a third of the patients with psoas abscess.^[20] As the psoas muscle is innervated by L2–L4, pain can radiate to hip and the lower extremity, mimicking the sciatic nerve symptom of pain. Indeed, there is a direct anatomical link between the psoas muscle and surrounding neural structures (lumbosacral structures) that can produce radicular pain. The diagnosis may be more evident with “psoitis” which is a nonspecific but well-defined sign in patients with psoas abscess. In the supine position, the knee is moderately flexed and the hip mildly externally rotated.^[28] Hyperextension of the involved side results in increased leg pain. However, collection of pus in the psoas muscle compartment may present with a gradual onset of symptoms, moderate pain, and low-grade or absent fever, as was seen in our case.

Psoas muscle abscess is often initially misdiagnosed as muscle strain, acute myositis, contusion, hematoma, septic pelvic thrombophlebitis, perinephric abscess, pyelonephritis, acute appendicitis, pelvic or spinal osteomyelitis, trochanteric bursitis, sacroiliitis, cellulitis, or necrotizing fasciitis. In addition, tumors arising from the structures within the pelvis or lumbar area may mimic a psoas abscess.^[16,17,23] In the postpartum period,

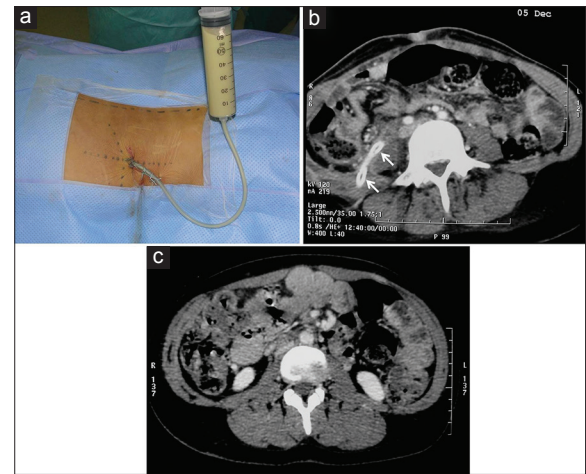


Figure 2: Operative view demonstrating posterior percutaneous drainage of the purulent collection above the right iliac crest (a). Follow-up abdominal CT scan 2 days after drainage of the abscess. Note the placement of the percutaneous drain (arrows) and the near complete resolution of the retroperitoneal collection (b). A follow-up axial abdominal CT scan with contrast injection 6 months postoperatively showing the absence of recurrent abscess (c)

special attention should be given to sepsis arising from endometritis, retained products of conception, or urinary tract infections.^[29] In neurosurgical practice, psoas abscess must be considered in the differential diagnosis of low back and leg pain even without the presence of fever.

Laboratory tests reveal nonspecific signs of inflammation: marked elevation of the erythrocyte sedimentation rate and CRP levels, an increased peripheral white blood cell count, and occasionally anemia. Blood cultures may be positive for a particular organism causing the abscess. HIV test is recommended, as this is a cause for immunosuppression predisposing to the development of PPA. In endemic areas, every effort should be made to ensure that the mycobacterium is excluded by acid-fast staining and culture techniques.^[6,25]

CT-scan and magnetic resonance imaging (MRI) are the best radiological modalities for diagnosis because of the low sensitivity and specificity of ultrasound.^[4,13] An obvious systemic source of sepsis should always be considered, with screening for an infectious focus of secondary psoas abscess.^[1]

S. aureus is the most frequently identified pathogen in patients with PPA (about 90% of cases). Secondary psoas abscess is usually caused by enteric bacteria such as *Streptococcus* species (4.9%) and *Escherichia coli* (2.8%).^[20] *M. tuberculosis* is currently an uncommon cause of PPA and often associated with a concomitant spondylodiscitis (Pott’s disease).^[1,7,25] Our patient was diagnosed as a primary tubercular psoas abscess since no other source of tuberculosis was identified. If tuberculosis is suspected, etiological confirmation is made either by demonstration of *M. tuberculosis* on a pathological

Table 1: Summary of cases with primary psoas abscess diagnosed during the postpartum period reported in world literature to date

First author, year	Ref.	Country	Age (years)	Antecedents	Mode of delivery/gestation	Clinical interval	Clinical presentation	Coinfection	Imaging diagnosis	Abscess side, measurements	Type of surgery	Bacteria isolated	Antibiotics used, duration	Outcome, follow-up
Saylam, 2002	[11]	Belgium	28	Unremarkable	Cesarean/NA	2 weeks	Wound infection, fever, edematous Rt thigh	Wound infection + thigh abscess + sacroiliitis + bacteremia	CT-scan MRI	Lt, multifocal abscess 80 mL	Thigh abscess puncture	<i>Staphylococcus aureus</i> + <i>Klebsiella pneumoniae</i>	Oxacillin + rifampicin + temocillin 4 months	Good 18 months
Shahabi, 2002	[12]	USA	NA	Gestational diabetes, vulvar and perirectal condyloma	Vaginal/42 weeks	2 days	Fever, left back pain, left lower abdominal pain, and hip pain	No	CT-scan	Lt, 14 × 4 cm	Anterior percutaneous CT-guided drainage	<i>Streptococcus viridans</i>	Gentamicin + clindamycin + cephalosporin 4 weeks	Good NA
Patil, 2006	[13]	UK	33	Unremarkable	Vaginal/37 weeks	3 weeks	Fever, pain in the right iliac fossa, and Rt leg	Upper respiratory tract infection	MRI	Rt, NA	Posterior open drainage	No microorganisms	NA	NA
Bhattacharya, 2008	[14]	UK	39	Mild hypertension	Vaginal/37 weeks	3 weeks	Fever, lower abdominal pain and Lt sciatic-like pain	No	CT-scan	Lt, multiseptated abscess NA	Anterior retroperitoneal drainage	Group B <i>Streptococcus</i> species	Clindamycin + tazocin NA	Good NA
Kwan, 2009	[15]	UK	31	Unremarkable	Vaginal/NA	4 weeks	Fever, Lt lower abdominal pain radiating to the thigh, dysuria	No	CT-scan	Lt, NA	Percutaneous ultrasound-guided drainage	Gram-positive cocci	Ceftriaxone + metronidazole 2 weeks	Good 6 weeks
Young, 2010	[16]	USA	17	Lt hip replacement 8 years before	Vaginal/NA	3 weeks	Fever, Rt leg pain	Urinary tract infection, endometritis	CT-scan	Rt, 4 × 4 cm	Percutaneous CT-guided drainage	Coagulase-negative <i>Staphylococcus</i>	Amoxicillin/Clavulanic acid 2 weeks	Good NA
Aydogmus, 2014	[17]	Turkey	27	Unremarkable	Cesarean/NA	10 months	Fever, Rt leg pain, abdominal tenderness	No	Ultrasound CT-scan	Rt, 6 × 6 × 5 cm	Percutaneous ultrasound-guided drainage	No microorganisms	Ceftriaxone + metronidazole	Good 6 months
Present case, 2018	NA	Morocco	34	Unremarkable	Vaginal/38 weeks	2 months	Low back pain, Rt sciatic pain, tenderness in the Rt iliac fossa	No	CT-scan	Rt, 18 × 10 × 8 cm 720 mL	Posterior percutaneous drainage then anterior retroperitoneal drainage	<i>Mycobacterium tuberculosis</i>	Amoxicillin/Clavulanate + gentamycin + metronidazole then antituberculous/6 months	Completely recovered 8 months

Rt=Right, Lt=Left, cm=Centimeters, mL=Milliliters, MRI=Magnetic resonance imaging, CT-scan=Computed tomography, NA=Not available, Ref = Reference, USA=United States of America, UK=United Kingdom

specimen or histological evidence of epithelioid-giant cell granulomas with caseating necrosis on the biopsy material. DNA amplification techniques and the QuantiFERON®-TB Gold In-Tube assay are also helpful for early and rapid diagnosis.^[1]

The pathogenesis of PPA in the postpartum period remains unclear. It has been suggested that trauma during delivery may cause an asymptomatic hematoma within the psoas muscle which can become infected.^[8,10,23] Another possibility is the disruption of the sacroiliac joint during delivery that may result in a retroperitoneal abscess.^[23] Shahabi *et al.* found that vaginal or cervical lacerations could potentially spread retroperitoneally causing an abscess.^[24] In addition, transient bacteremia following pharyngitis or urinary tract infection may predispose patients to this condition.^[15,19] On the other hand, alterations to the immune status during pregnancy can lead to impaired cell-mediated immunity with an increased susceptibility to certain infections such as tuberculosis.^[3] Our patient had no known history suggesting a malignancy or dysfunctional immunity. In addition, it is unclear as to how a woman who was healthy previously could develop such a potentially serious complication after an apparently uncomplicated vaginal delivery. Furthermore, our patient has no potential risk factors or source of infection for developing a psoas abscess.

Treatment should be started as soon as a clinical diagnosis of psoas abscess is confirmed. The administration of appropriate antibiotics and prompt surgical drainage are necessary when a large suppurative collection is found. Antibiotic coverage should include staphylococcal species and enteric organisms. Antimicrobial adjustments should be based on the report of the abscess fluid culture and sensitivity testing.^[12] Antibiotics given for 3–4 weeks are usually sufficient for patients without complications. Tubercular lesions must be treated with the appropriate antituberculous regimens.^[1,3] Drainage of the suppurative abscess collection may be either surgically or under radiological guidance. Percutaneous drainage is much less invasive than open surgical drainage and is appropriate for draining uniloculated and multiloculated abscesses with few septations as was the case in our patient.^[9] The indications for open surgical drainage are (1) failure of percutaneous drainage, (2) absence of pathogen identification, and (3) the presence of another intra-abdominal or retroperitoneal pathology requiring surgery. As seen in our patient, it was clear that open surgery was necessary due to the need to identify a causative organism to guide medical treatment. In addition, there are only a very small number of cases treated successfully by antibiotics.^[21,26,27]

If treated early and adequately, most patients with PPA will be cured without further complications or recurrent infection.^[27] The possibility of another systemic source of infection (multifocal infection) should be considered

when the patient does not respond to antibiotic treatment. Fortunately, patients with postpartum PPA usually have a good outcome. However, we must consider that the mortality rate of treated psoas abscess ranges from 6.7% to 8.1%.^[14,20]

CONCLUSION

PPA is an uncommon but serious clinical entity rarely encountered in neurosurgery, obstetrics, and gynecology. This clinical problem may occur as a postpartum complication but a delay in diagnosis is common because of its insidious development and lack of specific (localizing) symptoms and signs. When PPA is suspected, the CT-scan and MRI help in making an accurate diagnosis and will facilitate the percutaneous or open drainage of the purulent collection. Correct identification of the causative microorganisms and prompt and appropriate usage of antimicrobial therapy can result in improved clinical outcome and reduce neurological morbidity. Therefore, psoas abscess must be considered in the differential diagnosis for patients with low back and leg pain even in the absence of fever.

Declaration of patient consent

The authors certify that they have obtained all appropriate patient consent forms. In the form the patient(s) has/have given his/her/their consent for his/her/their images and other clinical information to be reported in the journal. The patients understand that their names and initials will not be published and due efforts will be made to conceal their identity, but anonymity cannot be guaranteed.

Financial support and sponsorship

Nil.

Conflicts of interest

There are no conflicts of interest.

REFERENCES

1. Akhaddar A, editor. Spinal tuberculosis. In: Atlas of Infections in Neurosurgery and Spinal surgery. 1st ed. Switzerland: Springer International Publishing; 2017; p. 249-275. doi: 10.1007/978-3-319-60086-4_24.
2. Akhaddar A, Elmostarchid B, Boucetta M. Primary subdural empyema after spontaneous vaginal delivery. *Surg Infect (Larchmt)* 2009;10:363-4.
3. Akhaddar A, Mahi M, Harket A, Elmostarchid B, Belhachemi A, Elasri A, *et al.* Brainstem tuberculoma in a postpartum patient. *J Neuroradiol* 2007;34:345-6.
4. Aydogmus S, Sen Selim H, Eris S, Kelekci S. A rare complication of caesarean delivery: Iliopsoas abscess. *Acta Obstet Gynecol Scand* 2014;93:1071-2.
5. Bhattacharya R, Gobrial H, Barrington JW, Isaacs J. Psoas abscess after uncomplicated vaginal delivery: An unusual case. *J Obstet Gynaecol* 2008;28:544-6.
6. Biswas R, Baghel V, Shanker S. A gibbus in puerperium. *BMJ Case Rep* 2008;2008:bcr0620080154.
7. Chawla K, D'Souza A, N SB, Mukhopadhyay C. Primary tubercular psoas abscess: A rare presentation. *J Infect Dev Ctries* 2012;6:86-8.
8. Desandre AR, Cottone FJ, Evers ML. Iliopsoas abscess: Etiology, diagnosis, and treatment. *Am Surg* 1995;61:1087-91.

9. Dinc H, Onder C, Turhan AU, Sari A, Aydin A, Yuluğ G, *et al.* Percutaneous drainage of tuberculous and nontuberculous psoas abscesses. *Eur J Radiol* 1996;23:130-4.
10. Garagiola DM, Tarver RD, Gibson L, Rogers RE, Wass JL. Anatomic changes in the pelvis after uncomplicated vaginal delivery: A CT study on 14 women. *Am J Roentgenol* 1989;153:1239-41.
11. Garner JP, Meiring PD, Ravi K, Gupta R. Psoas abscess-not as rare as we think? *Colorectal Dis* 2007;9:269-74.
12. Kumar S, Malhotra N, Chanana C, Lal S. Psoas abscess in obstetrics. *Arch Gynecol Obstet* 2009;279:247-9.
13. Kwan A, Bhanshaly A, Wright C. Iliopsoas abscess: An unusual cause of postpartum sepsis. *Obstet Med* 2009;2:30-1.
14. Lai YC, Lin PC, Wang WS, Lai JI. An update on Psoas Muscle Abscess: An 8-Year experience and review of literature. *Int J Gerontol* 2011;5:75-9.
15. Lau SK, Woo PC, Yim TC, To AP, Yuen KY. Molecular characterization of a strain of group a streptococcus isolated from a patient with a psoas abscess. *J Clin Microbiol* 2003;41:4888-91.
16. Liu XQ, Li FC, Wang JW, Wang S. Postpartum septic sacroiliitis misdiagnosed as sciatic neuropathy. *Am J Med Sci* 2010;339:292-5.
17. Mallick IH, Thoufeeq MH, Rajendran TP. Iliopsoas abscesses. *Postgrad Med J* 2004;80:459-62.
18. Mynter H. Acute psoitis. *Buffalo Med Surg J* 1881;21:202-10.
19. Patil A, Gatongi DK, Haque L, Mires G. Primary psoas abscess following spontaneous vaginal delivery. *J Obstet Gynaecol* 2006;26:565-9.
20. Ricci MA, Rose FB, Meyer KK. Pyogenic psoas abscess: Worldwide variations in etiology. *World J Surg* 1986;10:834-43.
21. Saylam K, Anaf V, Kirkpatrick C. Successful medical management of multifocal psoas abscess following cesarean section: Report of a case and review of the literature. *Eur J Obstet Gynecol Reprod Biol* 2002;102:211-4.
22. Scheepers NJ, van Bommel PF, Bleker OP. Psoas abscess related to spontaneous abortion, intra-uterine contraceptive device and curettage. *Acta Obstet Gynecol Scand* 1993;72:223-4.
23. Shah PN, Rane VA, Moolgaoker AS. Retroperitoneal abscess complicating a normal delivery. *Br J Obstet Gynaecol* 1992;99:160-1.
24. Shahabi S, Klein JP, Rinaudo PF. Primary psoas abscess complicating a normal vaginal delivery. *Obstet Gynecol* 2002;99:906-9.
25. Shinohara T, Kagawa K, Okano Y, Sawada T, Kobayashi T, Takikawa M, *et al.* Disseminated tuberculosis after pregnancy progressed to paradoxical response to the treatment: Report of two cases. *BMC Infect Dis* 2016;16:284.
26. Suzaki A, Takazoe M. Successful medical management of multilocular psoas abscess in a pregnant woman with Crohn's disease: A case report. *J Nihon Univ Med Ass* 2011;70:50-3.
27. Thomas A, Albert AS, Bhat S, Sunil KR. Primary psoas abscess--diagnostic and therapeutic considerations. *Br J Urol* 1996;78:358-60.
28. Wong JG. The psoas signs. Well-described but often forgotten physical examination findings of iliopsoas inflammation. *N C Med J* 1993;54:598-600.
29. Young OM, Werner E, Sfakianaki AK. Primary psoas muscle abscess after an uncomplicated spontaneous vaginal delivery. *Obstet Gynecol* 2010;116S2:477-9.