

Case Report

Cerebral abscesses after endovascular coiling of a paraophthalmic aneurysm: Case report and review of the literature

Charles Fish, David Wilson¹, Biyi Chen², Charlotte Yin³

Department of Neurosurgery, Royal Prince Alfred Hospital, 50 Missenden Road, Camperdown, New South Wales 2050, ¹Department of Neurosurgery, St Vincent's Hospital, 390 Victoria Street, Darlinghurst, New South Wales 2010, ²Faculty of Medicine, University of Sydney, Camperdown, New South Wales 2050, ³Department of Nuclear Medicine and Theranostics, St Vincent's Hospital, 390 Victoria Street, Darlinghurst, New South Wales 2010, Australia

*Charles Fish - charlestfish@gmail.com; David Wilson - davidnwilson14@gmail.com; Biyi Chen - chen.m.biyi@gmail.com; Charlotte Yin - charlotte.yin@gmail.com
*Corresponding author

Received: 14 June 18 Accepted: 21 September 18 Published: 13 December 18

Abstract

Background: Intracranial infections are a rare complication of therapeutic neuroendovascular procedures.

Case Description: We present a case of a 72-year-old female with multiple unilateral cerebral hemisphere abscesses after endovascular embolization of a right paraophthalmic aneurysm and also provide a comprehensive review of the literature on cerebral abscesses following neurovascular embolization.

Conclusion: Infection following coil embolization of cerebral aneurysm is rare. However, it is likely to increase in the setting of increased use of neuroendovascular techniques in the future. Therefore, we suggest that extreme care is taken to ensure proper asepsis during embolization, and a high index of suspicion is maintained in patients with predisposing characteristics (large hemorrhage, ischemia, recurrent endovascular procedures, right-to-left shunt, and concomitant infection). Given the fact that the majority of abscesses occurred in patients who have had ruptured aneurysms, we suggest consideration is given to prophylactic intraprocedural intravenous antibiotics use as seen with open aneurysm treatment.

Key Words: Abscesses, aneurysm, complication, neuroendovascular

Access this article online

Website:www.surgicalneurologyint.com**DOI:**

10.4103/sni.sni_189_18

Quick Response Code:

INTRODUCTION

Endovascular embolization is an important therapeutic option for cerebral aneurysms and cerebral arteriovenous malformations (AVMs), and provide an alternative to surgical clipping; especially, for patients who are poor surgical candidates.^[19] Although complications such as aneurysm rupture^[21] and cerebral infarction^[14] are well documented, central nervous system (CNS) infection is a rare complication of intracranial endovascular procedures. Only six cases of cerebral abscesses post endovascular embolization have been reported, and ours is the first case of multiple and distal cerebral abscesses.

CASE REPORT

A 72-year-old female presented with a Fisher Grade 3 and World Federation of Neurological Societies Grade V

This is an open access journal, and articles are distributed under the terms of the Creative Commons Attribution-NonCommercial-ShareAlike 4.0 License, which allows others to remix, tweak, and build upon the work non-commercially, as long as appropriate credit is given and the new creations are licensed under the identical terms.

For reprints contact: reprints@medknow.com

How to cite this article: Fish C, Wilson D, Chen B, Yin C. Cerebral abscesses after endovascular coiling of a paraophthalmic aneurysm: Case report and review of the literature. *Surg Neurol Int* 2018;9:252.

<http://surgicalneurologyint.com/Cerebral-abscesses-after-endovascular-coiling-of-a-paraophthalmic-aneurysm-Case-report-and-review-of-the-literature/>

aneurysmal subarachnoid hemorrhage (SAH) and an acute left traumatic subdural hematoma (SDH) post fall [Figure 1a and b]. Cerebral angiography showed a superiorly projecting $5.5 \times 3.4 \times 3.7$ mm³ aneurysm arising from the supraclinoid internal carotid artery (ICA) [Figure 2a]. The aneurysm incorporates the origin of the right ophthalmic artery and has a 2.5 mm neck. A left ophthalmic artery aneurysm and bilateral cavernous ICA aneurysms were also found.

She underwent balloon assisted coiling of the right paraophthalmic aneurysm using microvention coils one day after the SAH [Figure 2b]. The right ophthalmic artery remained patent with partial contrast opacification of a loosely packed anteroinferior aneurysm adjacent to the ophthalmic artery origin.

Angiography one week post coiling showed severe vasospasm of the bilateral AIs and its distal branches [Figure 3a and b]. The patient was treated with intra-arterial verapamil and nimodipine. Repeat angiography one day later showed ongoing severe stenosis in bilateral AIs and the patient was again treated with intra-arterial vasodilators with improvement in the anterior cerebral artery (ACA) vessel caliber and perfusion to the ACA territory. She remained

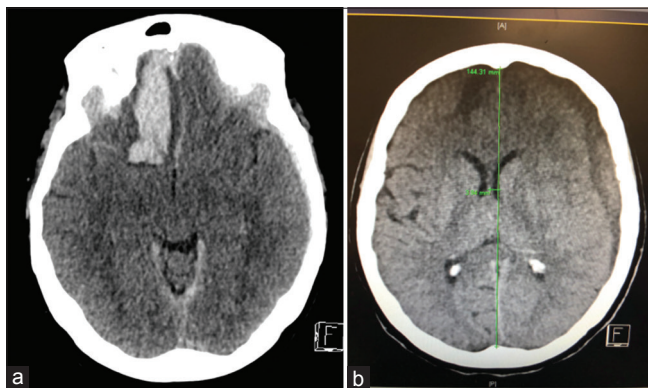


Figure 1: (a) Axial CT scan showing the Fisher Grade 3 aneurysmal subarachnoid hemorrhage. (b) Axial CT showing a left subdural hematoma with 3.94 mm of midline shift

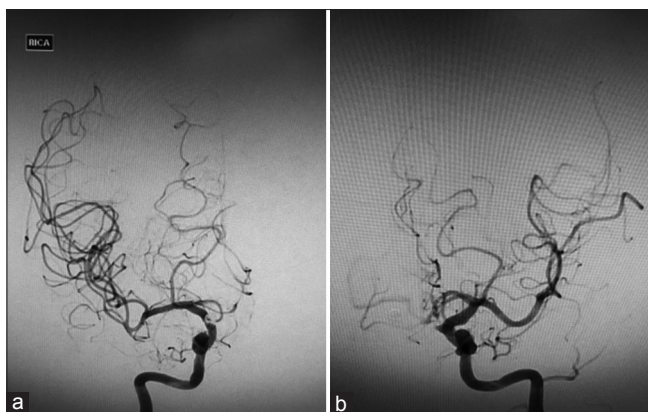


Figure 3: (a and b) Angiography showing severe vasospasm of the right (3a), left AIs and its distal branches

clinically stable with ongoing mild left hemiparesis post-procedure.

Three weeks after the intra-arterial treatment, the patient became hemodynamically unstable and developed a right sided hemiparesis. CT scan showed evolution of the left acute SDH into a chronic SDH with mass effect. She underwent an uneventful burr hole evacuation of the left SDH with resolution of her right-sided hemiparesis.

Her post-treatment course was complicated by vasospasm requiring two take backs for endovascular intra-arterial treatment and evacuation of the left SDH. CT one month after admission showed a new 27×25 mm² low density area in the right posterior

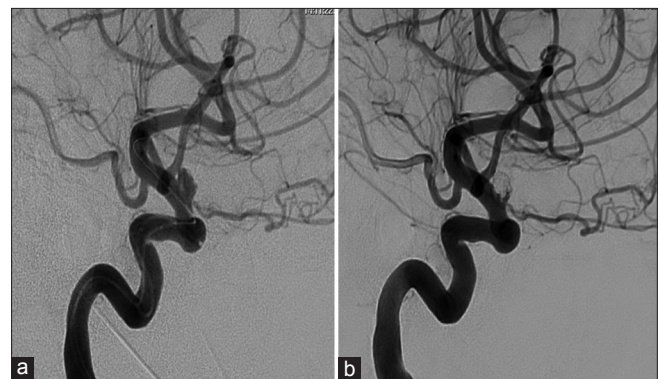


Figure 2: (a) Angiography (anteroposterior view) confirms the presence of a $5.5 \times 3.4 \times 3.7$ mm superiorly projecting aneurysm arising from the supraclinoid internal carotid artery (ICA) with a 2.5 mm neck. (b) Angiography showing good occlusion of the fundus but some residual neck filling of the right ICA

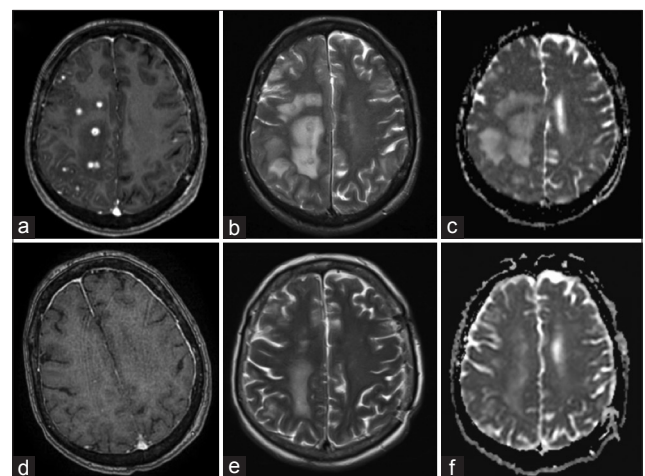


Figure 4: (a) T1-weighted (T1W) axial MRI with gad shows multiple ring-enhancing abscesses in the right frontal, parietal, and occipital lobes with surrounding edema. (b) Corresponding T2-weighted (T2W) axial image showed multiple hyperintense centers and hypointense irregular rims. (c) The abscesses appear isointense with areas of hypointensity on apparent diffusion coefficient (ADC) map suggestive of restricted diffusion. One month after the commencement of antimicrobial therapy, MRI demonstrated resolution in many of the enhancing foci with significant decrease in the size of the surrounding vasogenic edema (e-f)

frontal lobe suggestive of ischemia. She remained a febrile with no signs of meningism, however, developed worsening left-sided hemiparesis and confusion. Magnetic resonance imaging (MRI) showed significant enhancement around the coil mass and multiple ring-enhancing lesions in the right frontal, parietal, and occipital lobes with surrounding edema [Figure 4a-c]. Magnetic resonance angiography (MRA) showed a small anterior protrusion into the supraophthalmic portion of the right ICA.

Intra-arterial blood distal to the coils was obtained for culture. Attempted biopsy of the emboli was abandoned after post sampling angiography showed a filling defect at the right middle cerebral artery (MCA) bifurcation. Repeat right ICA angiography showed clearance at the MCA bifurcation with migration of the thrombus to a single M2/M3 branch. Thrombectomy was not attempted because of the risks of hemorrhage in the setting of possible infective arteritis. Peripheral and intra-arterial blood cultures were negative. White cell count WCC, C-reactive protein (CRP), and chest X-Ray (CXR) were unremarkable. Transesophageal echocardiogram was negative for valvular vegetations. She was commenced

on dexamethasone and intravenous vancomycin 1g BD, ceftriaxone 2g BD, and fluconazole 400 mg. Tissue biopsy was not taken in light of antibiotic commencement and the likelihood of obtaining a sterile sample.

One month after the commencement of antimicrobial therapy, MRI brain demonstrated resolution of many of the enhancing foci with significant decrease in the size of the surrounding vasogenic edema [Figure 4d-f] despite corticosteroids being ceased two weeks prior. Patient remained clinically stable with significant improvement in her left-sided hemiparesis and was discharged to rehabilitation for further therapy.

DISCUSSION

A search was conducted using MEDLINE and PubMed of all English language case reports published between January 1945 and January 2018, which describe intracranial abscesses post embolization. The following search terms were used in combination: “cerebral,” “abscess,” “endovascular,” and “embolization.” Review of literature found 12 patients (13 including our case) satisfying these criteria.^[1,3,4,6,7,11,13,15,17,18,20] The patients who developed

Table 1: Cases of CNS infection post endovascular embolization of aneurysm (including our case)

Authors	Sex/ Age	Hunt	Imaging	Vascular malformation	Treatment	Complication	Timing	Abscess treatment	Pathogen	Outcome
Al-Okaili 2002	70F	1	No SAH	R PComA	51 × GDC coils Residual filling	Abscess adjacent to aneurysm with surrounding edema	1 month	IV abx for	NS	Near total radiological resolution after 2/12
Kirollos 2002	55F	NS	SAH	R paraophthalmic with wide neck	GDC coils Residual filling	Abscess surrounding the coils with ventriculitis	3.5 years	IV ceftriaxone then cephalexin	Salmonella group D	Complete resolution of abscess after 5/12
Jenkinson 2003	70F	1	SAH	R terminal ICA	GDC coils Residual filling	Abscess adjacent to the coil-packed fundus of the aneurysm	5 weeks	IV ceftriaxone Intrathecal vancomycin	S. aureus	Regression of abscess 18/12
Diaz-Romero 2009	57F	2	No SAH	R giant intracavernous aneurysm	GDC coils + stent. Complete embolization	Perianeurysmal abscess with thrombophlebitis of cavernous sinus	2 weeks	PO rifampicin	Coagulase negative S. aureus	Radiological improvement after 2/12
Chen 2014	54M	4	SAH	Left MCA aneurysm	6 × GDC coils. Residual filling	Abscess adjacent to aneurysm	11 weeks	Abscess drained	NS	Death 6 hours post drainage due to re-rupture of aneurysm
Cossu 2017	40F	1	SAH	Basilar tip aneurysm	Target coils	Left cerebellar abscess with mass effect on 4 th ventricle and basal cisterns.	2 months	IV imipenem then ceftriaxone and rifampicin for 6/52. Surgical excision and EVD.	NS	Complete radiology regression after 5/12
Ours	72F	5	SAH	R paraophthalmic aneurysm	Microvention coils	Multiple abscesses in the R frontal, parietal, and occipital lobes	1 month	IV ceftriaxone, metronidazole and fluconazole	NS	Ongoing

Table 2: Cases of CNS infection post endovascular embolization of AVM

Authors	Sex/ Age	Spetzler Martin	Imaging	Vascular malformation	Treatment	Complication	Timing	Abscess treatment	Pathogen	Outcome
Mourier 1993	24F	2	R frontal hemorrhage	R frontal AVM fed by MCA and 2 lenticulo-striatal branches. Drained by cortical vein and SSS.	2 × NBCA glue embolizations. Residual filling	R frontal abscess	4 months	IV vancomycin, rifampicin, and excision of AVM and surrounding abscesses	MRSA	Clinical and radiological improvement after 3/12
Pendakar 2006	30M	2	R centrum semiovale hemorrhage with IVE	R frontoparietal AVM fed by R ACA, MCA, MMA, and bilateral superficial temporal artery. Drained by cortical veins to SSS.	4 × NBCA glue embolizations. Residual filling	Sinus with pus discharge over vertex. R frontoparietal abscesses.	8 months	IV amikacin and cefotaxime	Pseudomonas aeruginosa	NS
Chagla 2008	24M	NS	No hemorrhage	L parietal AVM	NBCA glue embolization. Not specified.	Left parietal lobe abscesses	4 years	Craniotomy and excision of residual AVM and abscesses	No growth	Complete clinical resolution.
Sharma 2011	38M	3	Subacute R occipital lobe hemorrhage	R parieto-occipital AVM fed by R PCA and MCA. Drains into R transverse sinus and vein of Galen.	NBCA glue embolization. Complete	Multiple abscesses and hydrocephalus.	10 months	IV ceftriaxone and amikacin. Declined surgery	No growth	Death
	25F	NS	No hemorrhage	L frontal AVM fed by L MCA. Drain into SSS.	NBCA glue embolization. Complete	Multiple L frontal lobe abscesses	5 months	Left frontal craniotomy and excision of abscesses	Burkholderia caecia	Clinically improved
Khoshnevisan 2014	21F	NS	No hemorrhage	L parietal AVM fed by L ACA and MCA.	NBCA glue embolization. Complete.	Multiple L frontoparietal abscesses	5 months	IV abx and drained by cannula through burr hole.	E. coli	Clinical and radiological improvement after 4/12

intracranial abscess had endovascular procedures to treat their aneurysm^[1,4,6,7,11,15] or AVM.^[3,13,17,18,20]

A review of literature found that cerebral abscess in the context of endovascular procedures occurs irrespective of the age, gender, location of aneurysm or AVM, and the clinical and radiological grade of the SAH [Tables 1 and 2].

There were 9 females and 4 males. Their mean age at diagnosis was 40 ± 18 years (range 21–72 years). In seven patients,^[1,4,6,7,11,15] this was to treat a cerebral aneurysm, and in six cases, this was to treat an AVM.^[3,13,17,18,20]

Six females^[1,6,7,11,15] and 1 male^[4] had cerebral aneurysms (female: male ratio of 6) with a mean age of 59.7 years (range 40–72 years). On admission, most patients had SAH secondary to aneurysmal rupture (71.4%).^[4,6,11,15] Four patients had Fisher grades ≤ 3 (57%). Five patients had anterior circulation aneurysms and two patients had posterior circulation aneurysms. Complete embolization

was achieved in two cases (28.6%).^[6,7] The average duration of time for a patient to become symptomatic from a brain abscess was 7.9 weeks (range 2 weeks to 3.5 years). The presenting complaint of patient with abscess varied with fever and the classic triad of cerebral abscesses (headache, fever, and focal neurological deficit) present in only 2 patients (28.6%).^[6,15]

Three males^[3,18,20] and 3 females^[13,17,20] had therapeutic endovascular treatment of AVM (female: male ratio 1). Mean age of 27 years (range 21–38 years). On admission, 50% of patients had lobar hemorrhage secondary to cerebral AVMs.^[17,18,20] Complete embolization with N-butyl cyanoacrylate glue was performed in three cases, while in two cases residual filling persisted. The result of embolization was not specified in one case. The average duration of time for patient to become symptomatic from brain abscess post coiling was 6.5 months (range 4 months to 4 years). In total, 50% of patients had

focal neurological deficits and 66.6% had signs associated with raised ICP. Two patients were pyrexia.

All 13 patients had CT or MRI scans that showed a single abscess in 6 patients (46.2%) and multiple cerebral abscesses in 7 patients (53.8%). Singular abscesses were common in aneurysm patients post endovascular treatment, whereas multiple abscesses were more common in AVM patients. Abscesses are more likely to develop adjacent to aneurysms than AVMs and may be explained by the majority of aneurysm patients in the literature having ruptured aneurysms on initial presentation. All abscesses were located in the same hemisphere as the aneurysm or AVM.

Pathogens were identified in 7 out of 13 patients. In 3 out of 13 patients (2 aneurysms, 1 AVM), *Staphylococcus aureus* was present in blood culture.^[7,11,17] *Staphylococcus* is a skin saprophyte and frequently penetrates the bloodstream through the femoral puncture site leading to bacteremia and maybe a source of the contamination for intravascular devices.^[9] *Salmonella group D species* was identified in the report by Kirolos *et al.* in both blood culture and cerebrospinal fluid (CSF) following a cerebral angiogram. Kirolos *et al.* postulated that the Guglielmi detachable coils (GDCs) acted as a colonized foreign body leading to surrounding abscess formation after infection with salmonella bacteremia or the inflammatory response in the surrounding tissue to the GDC was a predisposing factor and acted as a nidus for abscess formation. Single cases of *Pseudomonas aeruginosa*^[18] and *Burkholderia cepacia*^[20] were identified and postulated to have been introduced using irrigation fluids used during the procedure.

Kelkar *et al.*'s retrospective review of 2918 cerebral angiograms and neurointerventional procedures performed without prophylactic antibiotics found that the risk of infection attributable to angiography was 0.1% with all infections that were found localized to the femoral artery puncture site with no systemic and no CNS complications.^[12]

The majority of patients (92.3%) were treated with antimicrobial therapy for at least 4 weeks. A total of 8 patients (3 aneurysm and 5 AVM, 53.8%) also underwent surgical treatment: 6 surgical drainages (1 aneurysm, 5 AVM), 1 surgical drainage plus insertion of external ventricular drain (EVD), 1 insertion of EVD that was then changed to a ventriculoperitoneal shunt for hydrocephalus, and 3 surgical excisions of AVMs. The only patient who did not receive 4 weeks of antimicrobial therapy passed away shortly after drainage of his abscess due to aneurysm re-rupture.^[4] All patients with cerebral abscesses post endovascular treatment of AVMs had surgical drainage of the abscesses except for one patient who declined surgery and died shortly afterwards.^[20]

A total of 10 out of 13 patients had a favorable outcome (including ours to date) with clinical and radiological regression or resolution of the abscess/s. A total of 2 patients had an unfavorable outcome: one died shortly after surgical drainage of the abscess due to aneurysm re-rupture and another with AVM died after declining surgery.

Cerebral abscess results from predisposing factors such as disruption of the blood-brain barrier, underlying disease, or a systemic source of infection (e.g., endocarditis or bacteremia).^[2] The infectious agent can enter the brain through either percutaneous colonization or hematogenous dissemination from an infective focus.

Disruption of the blood-brain barrier allows the infectious agent to penetrate the intimal wall and cause an intraparenchymal infection. Three key causes include hemorrhage, edema, and ischemia. The cerebral inflammatory response is initiated at the time of aneurysmal rupture with erythrocytes that accumulate in the subarachnoid space lysing and releasing inflammatory cytokines.^[10,16] Hanafy *et al.* in 2010 postulated that the level of inflammatory response post hemorrhage can be correlated to the Hunt and Hess grading for aneurysms. This is in line with our literature review with 5 out of 7 aneurysmal cases presenting with SAH and all patients having vasogenic edema on imaging. Similarly, patients with large lobar hemorrhages secondary to AVMs are postulated to provoke a greater cerebral inflammatory response.

In the normal brain, the blood-brain barrier provides resistance to infection but its disruption during ischemia and hemorrhage opens the way to abscess growth. With a high incidence of bacteremia during therapeutic angiography, the risk of infection is heightened if the procedure causes any ischemia.^[5,8]

Cerebral abscesses following therapeutic endovascular procedures are a rare but an important complication associated with significant morbidity and mortality. The incidence of CNS infections is only expected to become more prevalent with the increased use of endovascular procedures.

In our patient, a polyvinylpyrrolidone (PVP) infection is likely to have been introduced during the endovascular procedure or during intra-arterial vasospasm treatments using the sheath, catheters, or balloon. This is supported by the 4-week interval between the procedure and the formation of the abscesses on the same hemisphere as the coils. In addition, our patient had no other systemic infection or congenital abnormality such as a right-to-left shunt that could have led to hematogenous dissemination. The infectious agents could have penetrated the aneurysm wall and caused intraparenchymal infection when the integrity of the blood-brain barrier is disrupted

by hemorrhage and ischemia as is likely to have occurred in our patient.

Our patient also had poor prognostic factors (Grade V hemorrhage and older age) that likely triggered a strong cerebral inflammatory response that was responsible for the surrounding edema and periods of ischemia from the lack of blood supply around the inert coils after an efficient embolization and then prolonged periods of vasospasms during multiple intra-arterial treatments.

CONCLUSION

PVP encephalitis following coil embolization of cerebral aneurysm is rare and more likely to occur in the presence of hemorrhage, edema, and ischemia. Therefore, we suggest that extreme care is taken to ensure proper asepsis during embolization, and a high index of suspicion is maintained in patients with predisposing characteristics (large hemorrhage, ischemia, recurrent endovascular procedures, right-to-left shunt, and concomitant infection). Given 5 out of 7 SAH patients reported were ruptured, we suggest consideration is given to prophylactic intraprocedural IV antibiotics use as seen with open aneurysm treatment.

Declaration of patient consent

The authors certify that they have obtained all appropriate patient consent forms. In the form the patient(s) has/have given his/her/their consent for his/her/their images and other clinical information to be reported in the journal. The patients understand that their names and initials will not be published and due efforts will be made to conceal their identity, but anonymity cannot be guaranteed.

Financial support and sponsorship

Nil.

Conflicts of interest

There are no conflicts of interest.

REFERENCES

1. AL-Okaili R, Patel SJ. Brain abscess after endovascular coiling of a saccular aneurysm: Case Report. *Am J Neuroradiol* 2002;23:697-9.
2. Brouwer MC, Tunkel AR, McKhann GM, van de Beek D. Brain abscess. *N Engl J Med* 2014;371:447-56.
3. Chagla AS, Balasubramaniam S. Cerebral N-butyl cyanoacrylate glue-induced

- abscess complicating embolization. *J Neurosurg* 2008;109:347.
4. Chen G, Zhan S, Chen W, Li Z, Zhou D, Zeng S, et al. Brain abscess after endosaccular embolisation of a cerebral aneurysm. *J Clin Neurosci* 2014;21:163-5.
5. Chen S-T, Tang L-M, Ro L-S. Brain abscess as a complication of stroke. *Stroke* 1995;26:696-8.
6. Cossu G, Daniel RT, Messerer M. Cerebral abscess after neuro-vascular embolization: Own experience and review of the literature. *Acta Neurochir (Wien)* 2017;159:583-91.
7. Diaz-Romero R, Zenteno M, Santos-Franco JA, Soto-Hernandez JL, Lee A. Perianeurysmal abscess and meningitis after endovascular coil placement for an intracranial aneurysm. *Surg Infect (Larchmt)* 2009;10:359-62.
8. Emmez H, Borcek AO, Dogulu F, Ceviker N. Ischemic stroke complicated by a brain abscess: A case report and review of the literature. *Turk Neurosurg* 2007;17:48-54.
9. Falagas ME, Nikou SA, Siempos II. Infections related to coils used for embolization of arteries: Review of the published evidence. *J Vasc Interv Radiol* 2007;18:697-701.
10. Hanafy KA, Morgan Stuart R, Fernandez L, Schmidt JM, Claassen J, Lee K, et al. Cerebral inflammatory response and predictors of admission clinical grade after aneurysmal subarachnoid hemorrhage. *J Clin Neurosci* 2010;17:22-5.
11. Jenkinson MD, Javadpour M, Nixon T, Warnke P. Intracerebral abscess formation following embolisation of an internal carotid artery aneurysm using Guglielmi detachable coils. *Acta Neurochir (Wien)* 2003;145:703-6.
12. Kelkar PS, Fleming JB, Walters BC, Harrigan MR. Infection risk in neurointervention and cerebral angiography. *Neurosurgery* 2013;72:327-31.
13. Khoshnevisan A, Ghorbani A, Sistani Allahabadi N, Farzaneh F, Abdollahzadeh S, Soleymani S, et al. Cerebral abscess complicating embolization of an arteriovenous malformation: Case report and review of litera. *Iran J Neurol* 2014;13:181-4.
14. Kim H-K, Hwang S-K, Kim S-H. Types of thromboembolic complications in coil embolization for intracerebral aneurysms and management. *J Korean Neurosurg Soc* 2009;46:226-31.
15. Kirolos RW, Bosma JJ, Radhakrishnan J, Pigott TD. Endovascularly treated cerebral aneurysm using Guglielmi detachable coils acting as a nidus for brain abscess formation secondary to Salmonella bacteremia: Case report. *Neurosurgery* 2002;51:234-7; discussion 237-238.
16. Lucke-Wold BP, Logsdon AF, Manoranjan B, Turner RC, McConnell E, Vates GE, et al. Aneurysmal subarachnoid hemorrhage and neuroinflammation: A comprehensive review. *Int J Mol Sci* 2016;17:497.
17. Mourier KL, Bellec C, Lot G, Reizine D, Gelbert F, Dematons C, et al. Pyogenic parenchymatous and nidus infection after embolization of an arteriovenous malformation. An unusual complication. Case report. *Acta Neurochir* 1993;122:130-3.
18. Pendarkar H, Krishnamoorthy T, Purkayastha S, Gupta AK. Pyogenic cerebral abscess with discharging sinus complicating an embolized arteriovenous malformation. *J Neuroradiol* 2006;33:133-8.
19. Seibert B, Tummala RP, Chow R, Faridar A, Mousavi SA, Divani AA. Intracranial aneurysms: Review of current treatment options and outcomes. *Front Neurol* 2011;2:45.
20. Sharma A, Jagetia A, Loomba P, Singh D, Tandon M. Delayed brain abscess after embolization of arterio-venous malformation: Report of two cases and review of literature. *Neurol India* 2011;59:620-23.
21. Tummala RP, Chu RM, Madison MT, Myers M, Tubman D, Nussbaum ES. Outcomes after aneurysm rupture during endovascular coil embolization. *Neurosurgery* 2001;49:1059-66; discussion 1066-1057.