



Case Report

# Intermittent penile erection in lumbar spinal stenosis: Report of four new cases and review

Abolfazl Rahimizadeh, Housain Soufiani, Walter L. Williamson, Shaghayegh Rahimizadeh, Mahan Amirzadeh, Mona Karimi  
Pars Advanced and Minimally Invasive Medical Manners Research Center, Pars Hospital, Iran University of Medical Sciences, Tehran, Iran.

E-mail: \*Abolfazl Rahimizadeh - a\_rahimizadeh@hotmail.com; Housain Soufiani - soufianihosein@gmail.com; Walter L. Williamson - wlwilliamson@gmail.com; Shaghayegh Rahimizadeh - sherryrahimi@hotmail.com; Mahan Amirzadeh - mahan.amirzade@gmail.com; Mona Karimi - kmmonik20@gmail.com



**\*Corresponding author:**

Abolfazl Rahimizadeh,  
Pars Advanced and Minimally  
Invasive Medical Manners  
Research Center,  
Num. 10, Rastak St., Keshawarz  
Blvd., Tehran, Iran.

[a\\_rahimizadeh@hotmail.com](mailto:a_rahimizadeh@hotmail.com)

Received : 31 July 19  
Accepted : 03 August 19  
Published : 25 October 19

DOI  
10.25259/SNI\_368\_2019

Quick Response Code:



## ABSTRACT

**Background:** Lumbar spinal stenosis (LSS) classically presents with intermittent neurogenic claudication. Rarely, however, it may cause unanticipated, unpleasant, involuntary, and transient penile erections without sexual stimulation along with urinary urgency and claudication.

**Case Description:** The authors present four males with LSS whose principal symptoms were intermittent neurogenic claudication and unanticipated erections while walking, accompanied by urinary urgency.

**Conclusion:** There is scant literature on the topic of LSS presenting with unanticipated penile erections, urinary urgency, and neurogenic claudication.

**Keywords:** Involuntary penile erection, Lumbar, Lumbar spinal stenosis, Neurogenic claudication, Priapism

## INTRODUCTION

Lumbar spinal stenosis (LSS) is typically characterized by intermittent neurogenic claudication on ambulation. However, in males, it may also rarely be accompanied by unanticipated, intermittent penile erections (e.g., that lasts as long as the patient ambulates, in the absence of sexual stimulation) with urinary urgency. Here, we describe our experience with four such patients, along with a review of 17 similar cases published in literature.<sup>[1,3-14]</sup>

## CASE DESCRIPTION

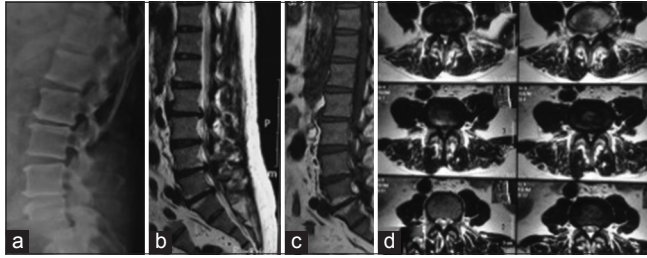
From 2012 to 2018, four patients with lumbar stenosis presented with intermittent neurogenic claudication associated with intermittent involuntary penile erections after walking between 50 and 200 m accompanied by urinary urgency. The age of the patients ranged from 53 to 63. Patients had these symptoms for between 18 months and 4 years. All four patients had multilevel LSS. Two patients were successfully managed with decompressive laminectomies [Figures 1 and 2]. The remaining two cases involved two biological brothers who both declined surgical interventions [Table 1].

## DISCUSSION

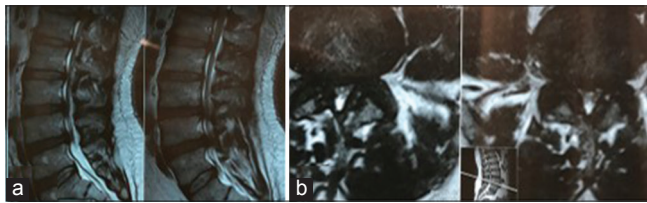
Rarely, male patients with LSS and intermittent neurogenic claudication additionally develop intermittent priapism and urinary urgency, relieved on sitting down or by bending forward.<sup>[1,3-11,13,14]</sup>

This is an open-access article distributed under the terms of the Creative Commons Attribution-Non Commercial-Share Alike 4.0 License, which allows others to remix, tweak, and build upon the work non-commercially, as long as the author is credited and the new creations are licensed under the identical terms.

©2019 Published by Scientific Scholar on behalf of Surgical Neurology International



**Figure 1:** (a) Lateral lumbar spine radiograph, (b and c) T2- and T1-weighted sagittal magnetic resonance imaging of the lumbar region showing lumbar canal stenosis. (d) T2-weighted axial images showing marked stenosis.



**Figure 2:** (a) T2-weighted sagittal lumbar spine magnetic resonance imaging (MRI) and (b) T2-weighted axial MRI both showing multilevel lumbar canal stenosis.

**Table 1:** Patients' information about age, sex, and type of management.

Case	Sex	Age	Duration	Surgery	Outcome
1	Male	63	18 months	Laminectomy	Good
2	Male	54	3 years	Laminectomy	Good
3	Male	53	2 years	Not yet	The same
4	Male	57	4 years	Not yet	The same

### Pathogenesis of intermittent penile erection

LSS can cause erections by altering the balance of sympathetic and parasympathetic discharges from the spinal cord or cauda equina.<sup>[11-14]</sup> In 2005, Tubbs *et al.* described an achondroplastic patient who had intermittent penile erections secondary to LSS.<sup>[12]</sup> Valsalva maneuver-induced priapism was also reported by Chen *et al.*, in a patient with a lumbar extradural arachnoid cyst.<sup>[2]</sup> Appropriate decompressive surgery was recommended to treat this constellation of symptoms.<sup>[1,3-11,13,14]</sup>

### CONCLUSION

For males with LSS, the additional development of transient, painful, involuntary penile erections, without sexual

stimulation, accompanied by urinary urgency may be effectively relieved with decompressive spinal surgery.

### Financial support and sponsorship

Nil.

### Conflicts of interest

There are no conflicts of interest.

### REFERENCES

- Baba H, Maezawa Y, Furusawa N, Kawahara N, Tomita K. Lumbar spinal stenosis causing intermittent priapism. *Paraplegia* 1995;33:338-45.
- Chen WL, Tsai WC, Tsao YT. Valsalva maneuver-induced priapism: A hidden culprit. *J Sex Med* 2009;6:1181-4.
- Duerinck J, Van Rompaey K, Van Der Veken J, Du Four S, Ampe B, Moens M, *et al.* Erections upon walking. A less known symptom of lumbar canal stenosis. *World Neurosurg* 2013;5:666.
- Hopkins A, Clarke C, Brindley G. Erections on walking as a symptom of spinal canal stenosis. *J Neurol Neurosurg Psychiatry* 1987;50:1371-4.
- Kanala DL. Intermittent priapism in degenerative lumbar spinal stenosis: Case report. *Turk Neurosurg* 2007;17:260-3.
- Laha RK, Dujovny M, Huang PS. Intermittent erection in spinal canal stenosis. *J Urol* 1979;121:123-4.
- Maurice-Williams RS, Marsh HT. Priapism as a feature of claudication of the cauda equina. *Surg Neurol* 1985;23:626-8.
- Ram Z, Findler G, Spiegelman R, Shacked I, Tadmor R, Sahar A, *et al.* Intermittent priapism in spinal canal stenosis. *Spine (Phila Pa 1976)* 1987;12:377-8.
- Rampin O, Bernabé J, Giuliano F. Spinal control of penile erection. *World J Urol* 1997;15:2-13.
- Ravindran M. Cauda equina compression presenting as spontaneous priapism. *J Neurol Neurosurg Psychiatry* 1979;42:280-2.
- Shintani S, Shiozawa Z, Tsunoda S. Intermittent penile erection in lumbar canal stenosis. *J Neurol* 1988;235:188-9.
- Tubbs RS, Oakes WJ. An unusual presentation of achondroplasia. Case report. *J Neurosurg* 2005;103:170-1.
- Willén JG, Griffiths ER, Mastaglia FL, Beaver R. Intermittent parasympathetic symptoms in lumbar spinal stenosis. *J Spinal Disord* 1989;2:109-13.
- Yamanishi T, Yasuda K, Sakakibara R, Murayama N, Hattori T, Ito H, *et al.* Detrusor overactivity and penile erection in patients with lower lumbar spine lesions. *Eur Urol* 1998;34:360-4.

**How to cite this article:** Rahimizadeh A, Soufiani H, Williamson WL, Rahimizadeh S, Amirzadeh M, Karimi M. Intermittent penile erection in lumbar spinal stenosis: Report of four new cases and review. *Surg Neurol Int* 2019;10:209.