




Case Report

Clinical and surgical management of holocervical spinal cord ependymomas

Kevin Mckay¹, Mark Attiah¹, Tianyi Niu¹, Daniel Nagasawa¹, Kunal Patel¹, Bilwaj Gaonkar¹, Barbara Van de Wiele², Natalie Moreland², Alexander Tucker¹, Pedro Churchman², Ulrich Batzdorf¹, Luke Macyszyn¹

Departments of ¹Neurosurgery and ²Anesthesiology, University of California, Los Angeles.

E-mail: Kevin Mckay - kmckay@mednet.ucla.edu; Mark Attiah - mattiah@mednet.ucla.edu; Tianyi Niu - tniu85420@gmail.com; Daniel Nagasawa - dnagasawa@mednet.ucla.edu; Kunal Patel - kpatel@mednet.ucla.edu; Bilwaj Gaonkar - bgaonkar@mednet.ucla.edu; Barbara Van de wiele - bvan@mednet.ucla.edu; Natalie Moreland - nmoreland@mednet.ucla.edu; Alex Tucker - atucker@mednet.ucla.edu; Pedro Churchman - pchurchman@mednet.ucla.edu; Ulrich Batzdorf - ubatzdorf@mednet.ucla.edu; *Luke Macyszyn - lmacyszyn@mednet.ucla.edu



***Corresponding author:**

Luke Macyszyn, M.D., M.A.,
200 UCLA Medical Plaza B265,
Los Angeles, CA 90095.

lmacyszyn@mednet.ucla.edu

Received : 23 September 19

Accepted : 10 October 19

Published : 22 November 19

DOI

10.25259/SNI_374_2019

Quick Response Code:



ABSTRACT

Background: Spinal ependymomas are rare tumors of the central nervous system, and those spanning the entire cervical spine are atypical. Here, we present two unusual cases of holocervical (C1-C7) spinal ependymomas.

Case Description: Two patients, a 32-year-old female and a 24-year-old male presented with neck pain, motor, and sensory deficits. Sagittal MRI confirmed hypointense lesions on T1 and hyperintense regions on T2 spanning the entire cervical spine. These were accompanied by cystic cavities extending caudally into the thoracic spine and rostrally to the cervicomedullary junction. Both patients underwent gross total resection of these lesions and sustained excellent recoveries.

Conclusion: Two holocervical cord intramedullary ependymomas were safely and effectively surgically resected without incurring significant perioperative morbidity.

Keywords: Ependymoma, Spinal cord tumor, Tumor cyst

INTRODUCTION

Ependymomas are exceptionally rare primary intramedullary gliomas of the central nervous system.^[3,5] Complete surgical resection of holocervical intramedullary lesions (spanning C1-C7) is optimal.^[2] Here, we present two cases of gross total *en-bloc* resection of holocervical cord intramedullary ependymomas, extending from the cervicomedullary junction to the thoracic spine.

CASE DESCRIPTION

Patient 1

A 32-year-old female presented with severe progressive spastic quadriparesis attributed to a cervical cord intramedullary tumor (e.g., large cystic-enhancing expansile mass) extending from C1 to C7-T1 on MRI [Figure 1]. She underwent a C1-T1 laminectomy for *en-bloc* tumor removal

with a C2-C7 laminoplasty. Pathology deemed it a WHO grade II spinal ependymoma. Intraoperative motor-evoked potentials (MEPs) and somatosensory-evoked potentials (SSEPs) did not change. Postoperatively, her neurological examination did not deteriorate. Sixteen months later, the patient's gait ataxia and motor deficits resolved; the only residual deficit was proprioceptive loss in the right upper extremity. The 15-month postoperative MRI confirmed no evidence of residual or recurrent tumor [Figure 2].

Patient 2

A 24-year-old male also presented with a spastic quadriparesis and cervical MR-documented cystic, enhancing, expansile intramedullary mass extending from C1-C7 [Figure 3].

A C1-C7 laminectomy with midline myelotomy (*en bloc* tumor removal) and C2-C7 posterior fusion was performed. MEP's remained unchanged during the surgery. Postoperatively, the patient showed no neurological worsening. Pathologically, this was deemed a WHO grade II ependymoma. One year later, the patient had 4+/5 motor strength in the upper

extremities, intact motor strength in his lower extremities, and mild residual decreased sensation in the right C6-C7 dermatome. The 1-year postoperative cervical MRI showed no evidence of residual or recurrent tumor [Figure 4].

DISCUSSION

Demographics

Ependymomas tend to present more often in middle-aged adults and in the spinal cord.^[1,4]

Clinical presentation

Patients commonly experience symptoms for over a year before their initial diagnosis.^[1] Common symptoms can include pain, sensory and motor deficits, gait ataxia, bladder, and bowel dysfunction.^[5]

MR findings

MR imaging of spinal ependymomas demonstrates hypo- to isointensity on T1, hyperintense on T2 studies, often with

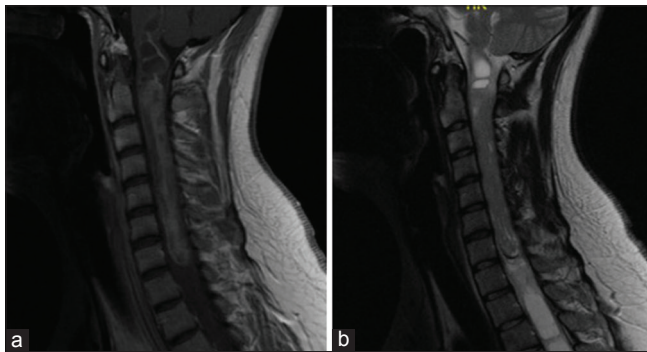


Figure 1: Case 1. Preoperative MRI cervical spine T1-weighted with contrast (left) and T2 weighted (right). There is a large-enhancing expansile mass of the cervical spinal cord extending from the level C1-C7 measuring 9.8 × 1.2 cm. A large tumor cyst extends from end of mass at C7 inferiorly into the thoracic spine.

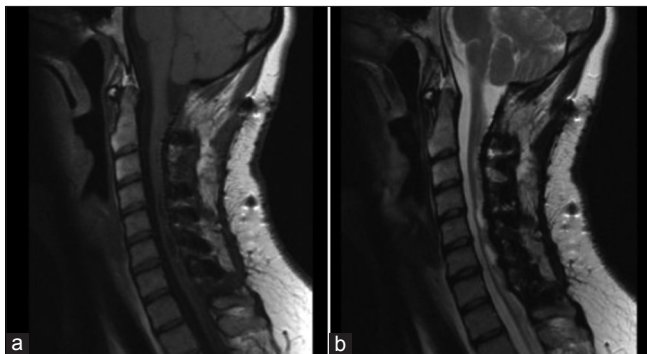


Figure 2: Case 1. Postoperative sagittal T1-weighted with contrast (left) and T2-weighted (right) MR images of the cervical spine after laminectomy and posterior fusion. Gross total resection was achieved with no residual tumor.

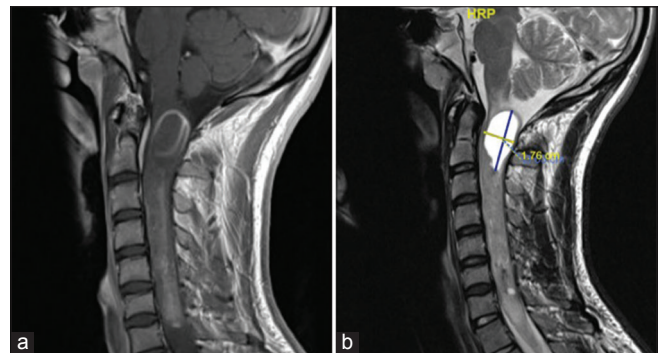


Figure 3: Case 2. Preoperative sagittal T1-weighted with contrast (left) and T2-weighted (right) MR images demonstrating a heterogeneous mass within the cervical cord from C1-C7. The superior portion of the mass demonstrates 1.7 × 3.6 cm cystic component.

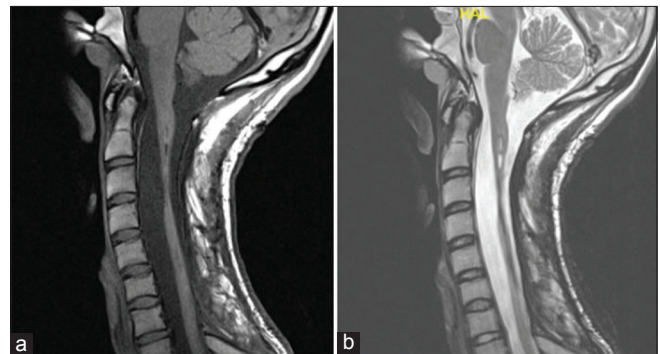


Figure 4: Case 2. Postoperative sagittal T1-weighted with contrast (left) and T2-weighted (right) MR images after laminectomy and posterior fusion. Gross total resection was achieved, albeit with marked spinal cord myelomalacia from C2-C3 through C6.

a cystic component, and heterogenous enhancement with gadolinium.^[1]

Surgical considerations and intraoperative monitoring

Both cases were performed with patient in the prone position. MEP and SSEP were used throughout. Both patients had wide laminectomies performed for adequate visualization. Following central durotomies, the spinal cords of both patients were significantly expanded. Midline myelotomies were performed in the both cases under microscopic visualization and were carried superiorly and inferiorly to the poles of the tumor. Both tumors were resected *en bloc*. We have found that if a favorable plane is delineated between tumor and normal tissue, internal debulking may add unnecessary time and undue cord manipulation potentially. Frequently in our practice, there is an associated cyst at the superior and inferior poles of the tumor. Care must be taken when resecting the poles of the tumors when next to a cystic cavity, as this may cause the surgeon to lose orientation, leading to inadvertent cord manipulation. At the end of the dissection/tumor removal, the arachnoid was approximated in both patients with 6-0 prolene sutures, a maneuver performed to reduce pathologic traction, prevent adhesions, and reconstitute a more anatomic central canal. The extent of bony removal increases the potential for postoperative kyphosis. The risk of deformity can be mitigated by concurrently providing rigid or semirigid internal fixation, e.g., augmenting the decompression with laminoplasty or posterior lateral mass fusion.

CONCLUSION

Two patients underwent *en bloc* surgical resection of holocervical cord C1-C7 intramedullary WHO grade II ependymomas. Our patients had excellent recovery of neurological function up to and including their respective most recent follow-up visits at 28 and 12 months postoperatively.

Declaration of patient consent

The authors certify that they have obtained all appropriate patient consent forms.

Financial support and sponsorship

Nil.

Conflicts of interest

There are no conflicts of interest.

REFERENCES

1. Kobayashi K, Ando K, Kato F, Kanemura T, Sato K, Kamiya M, *et al.* Surgical outcomes of spinal cord and cauda equina ependymoma: Postoperative motor status and recurrence for each WHO grade in a multicenter study. *J Orthop Sci* 2018;23:614-21.
2. Kobayashi K, Ando K, Kato F, Kanemura T, Sato K, Kamiya M, *et al.* MRI characteristics of spinal ependymoma in WHO grade II: A review of 59 cases. *Spine (Phila Pa 1976)* 2018;43:E525-30.
3. Kucia EJ, Bambakidis NC, Chang SW, Spetzler RF. Surgical technique and outcomes in the treatment of spinal cord ependymomas, part 1: Intramedullary ependymomas. *Neurosurgery* 2011;68:57-63.
4. Wild F, Hartmann C, Heissler HE, Hong B, Krauss JK, Nakamura M, *et al.* Surgical treatment of spinal ependymomas: Experience in 49 patients. *World Neurosurg* 2018;111:e703-9.
5. Wostrack M, Ringel F, Eicker SO, Jägersberg M, Schaller K, Kerschbaumer J, *et al.* Spinal ependymoma in adults: A multicenter investigation of surgical outcome and progression-free survival. *J Neurosurg Spine* 2018;28:654-62.

How to cite this article: Mckay K, Attiah M, Niu T, Nagasawa D, Patel K, Gaonkar B, *et al.* Clinical and surgical management of holocervical spinal cord ependymomas. *Surg Neurol Int* 2019;10:223.