



Case Report

Engorged venous plexus mimicking adjacent segment disease: Case report and review of the literature

Omron Hassan¹, Courtney S. Lewis², Likitha Aradhyula², Brian R. Hirshman², Martin H. Pham²

¹Department of Basic Sciences, School of Osteopathic Medicine, Touro University Nevada, Henderson, Nevada, ²Department of Neurosurgery, University of California San Diego School of Medicine, San Diego, California, United States.

E-mail: *Omron Hassan - do22.omron.hassan@nv.touro.edu; Courtney S. Lewis - ctyslewis@gmail.com; Likitha Aradhyula - laradhyu@ucsd.edu; Brian R. Hirshman - bhirshma@health.ucsd.edu; Martin H. Pham - mhpham@ucsd.edu



*Corresponding author:

Omron Hassan,
School of Osteopathic
Medicine, Touro University
Nevada, 874 American Pacific
Drive, Henderson 89014,
Nevada, United States.

do22.omron.hassan@nv.touro.
edu

Received : 08 April 2020

Accepted : 16 April 2020

Published : 09 May 2020

DOI

10.25259/SNI_166_2020

Quick Response Code:



ABSTRACT

Background: An engorged venous plexus may mimic nerve compression from a herniated disk on the magnetic resonance (MR) studies as they both have similar signal intensities. During a laminectomy, if an engorged venous plexus is encountered instead of a disk herniation, there may be marked unanticipated bleeding.

Case Description: A 58-year-old female who had a prior anterior lumbar interbody fusion later returned with recurrent radiculopathy. Adjacent segment disease from a spinal disk herniation was suspected based on the surgical history, physical examination, and imaging (MRI) findings. Rather than a disk, an engorged venous plexuses (EVP) was encountered intraoperatively.

Conclusion: Here, we discussed our findings regarding a lumbar EVP rather than a herniated disk and reviewed the current literature. Although rare, a higher index of suspicion for these vascular malformations based on combined historical information and MRI studies should allow one to better detect and/or anticipate an EVP rather than a routine disk.

Keywords: Adjacent segment disease, Epidural venous plexus, Lumbar radiculopathy

INTRODUCTION

Patients, who previously had spinal fusions, may develop recurrent lumbar radiculopathy due to adjacent-level disk herniations. However, new adjacent level disease may occasionally be attributed to engorged venous plexuses (EVP) rather than new disk herniations.^[2,13,27] Furthermore, EVPs may mimic the symptoms of a new herniated disk and exhibit comparable magnetic resonance imaging (MRI) findings as they both have similar signal intensities.^[2,13,17,26] Implementing EVPs among differential diagnostic considerations should enable spine surgeons to better anticipate surgical options and deal with attendant rapid intraoperative blood loss.

Here, we present a 58-year-old female patient who had previously undergone an anterior lumbar interbody fusion (ALIF) but later returned with lumbar radiculopathy. Although adjacent segment disease from a new spinal disk herniation was suspected, particularly based on relatively routine MRI findings, an EVP was discovered intraoperatively and was appropriately excised.

This is an open-access article distributed under the terms of the Creative Commons Attribution-Non Commercial-Share Alike 4.0 License, which allows others to remix, tweak, and build upon the work non-commercially, as long as the author is credited and the new creations are licensed under the identical terms.

©2020 Published by Scientific Scholar on behalf of Surgical Neurology International

CASE REPORT

Clinical presentation

A 58-year-old female presented with the left lower radiculopathy. Seven years ago, she had a prior L5-S1 ALIF. On examination she had decreased the left lower-extremity 1/5 motor function in the tibialis anterior and extensor hallucis longus distributions, plus a 3/5 in the gastrocnemius. The MRI showed what appeared to be an L4-L5 left-sided disk herniation above the level of her prior fusion (i.e., adjacent L4-L5 segment disk disease) [Figure 1].

Operative course

She subsequently underwent an L4-L5 left-sided minimally invasive microdiscectomy. After the laminotomy was completed and nerve root identified, there was a large venous plexus in the nerve root axilla extending ventrally and laterally. This was successfully coagulated with bipolar cautery. Due to the fragility of the plexus and recurrent venous bleeding, multiple hemostatic agents were repeatedly employed to control the bleeding [Figure 2]. After successful cauterization, a thorough examination of the nerve root and disk showed no free fragments or accompanying disk herniations.

Outcome and follow-up

Postoperatively, she reported immediate improvement of her foot strength and resolution of her left lower extremity and buttock pain. She was discharged on postoperative day 1 after a follow-up MRI confirmed an EVP as the ultimate etiology of her radiculopathy [Figure 3]. Six months later, an examination showed improvement to 4–/5 motor strength in the left tibialis anterior and extensor hallucis longus distributions, plus 4+/5 in the gastrocnemius.

DISCUSSION

A review of the English-language literature demonstrated 25 reports ranging in publication year between 1916 and

2019 that described patients with EVPs who presented similarly to those with lumbar disk herniations [Table 1]. There were a total of 55 patients (range 15–71 years old, 25 males and 24 females) in reports where this information was available. Patients most commonly presented with

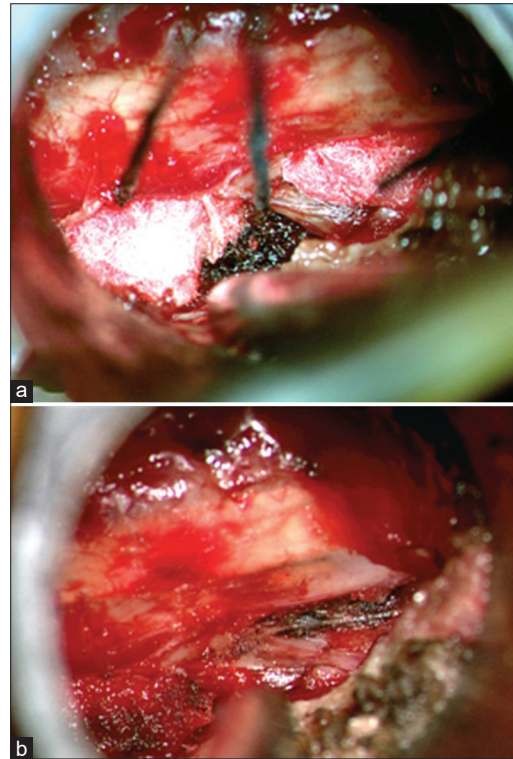


Figure 2: Intraoperative view down the minimally invasive tubular retractor showing (a) the lateral edge of the dural and nerve root with cottonoids and Surgicel® hemostatic material at both the nerve root shoulder and axilla after encountering copious venous bleeding. (b) View of the nerve root after exploration which demonstrated no herniated disk bulge or fragment.

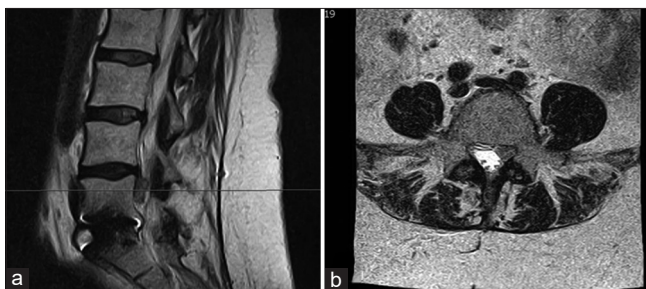


Figure 1: Preoperative T2-weighted magnetic resonance imaging in (a) sagittal and (b) axial views demonstrating the left-sided lateral recess epidural venous plexus at the adjacent level above a fusion mimicking a herniated disk associated with adjacent segment disease.

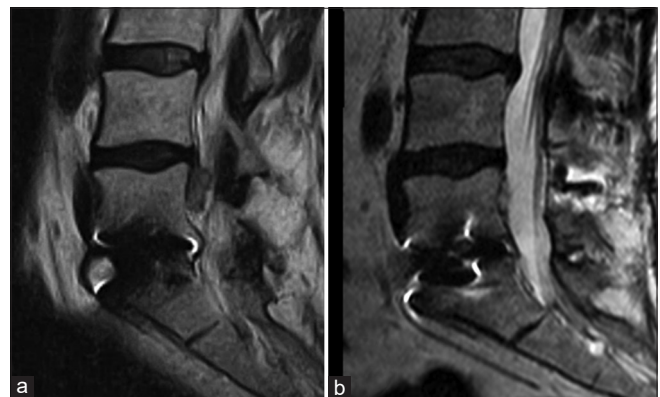


Figure 3: (a) Preoperative and (b) postoperative T2-weighted magnetic resonance imaging showing resolution of the epidural venous plexus after surgical intervention, confirming its etiology as the source of radiculopathy.

Table 1: Case reports and series with similar case presentations to lumbar disk herniation.

Publications	Age	Sex	Presenting symptom	MRI findings	Init. diag.	Suspected cause of EVP	Spinal levels	Outcome
Diaz <i>et al.</i> (2019) ^[7]	40	F/1	Radiculopathy	EVP compressing dural sac and CES	EVP	Common iliac vein stenosis caused EVP	L4-L5	Stent deployed into the left iliac vein improved radicular symptoms, positive Leiden Factor V thrombophilia, residual right leg discomfort
Jeong <i>et al.</i> (2019) ^[18]	15	M/1	Radiculopathy	DP and EVP	HD	Obesity-related abdominal pressure compression of venous drainage	L1-L2	Reduction of pain after morphine sulfate, gabapentin, and oxycodone, remained on medication
Im <i>et al.</i> (2018) ^[17]	36	F/1	Radiculopathy	Cystic lesion hyperintense on T2WI, hypointense on T1WI	EVP	-	L3-L4	Pain unresponsive to conservative treatment, laminectomy performed and an epidural varix found compressing dural sac and nerve root, EVP was coagulated with bipolar and removed, free of symptoms and MRI showed the lesion absence
Fredrickson <i>et al.</i> (2017) ^[13]	29	F/1	Radiculopathy	Diffuse spondylolysis with DP	DB	Lumboperitoneal shunt intracranial hypotension	L2-L5	Planned decompression and fusion operation aborted, intraoperatively found EVP, hemostasis of EVP and a posterior spinal fusion was completed, complete resolution of radiculopathy
Maki <i>et al.</i> (2017) ^[20]	71	M/1	Cauda equina	HD, dural sac shift, and EVP	CES	Previous microsdisectomy surgery	L5-S1	Medical therapy was not sufficient, laminoplasty was performed, EVP was coagulated, CES was resolved
Sniderman (2017) ^[24]	59	M/1	Radiculopathy	DP, effacement of thecal sac from EVP	VAS	May-Thurner Syndrome reduced the venous return	L3-S1	Decided to forego spine interventions, planned to attempt recanalization of the IVC but not yet performed upon publication
Bursali <i>et al.</i> (2016) ^[2]	26	M/1	Radiculopathy	Hypointense epidural lesion on T1WI and hyperintense on T2WI	HD	-	L4-L5	EVP discovered on surgery compressing nerve root, EVP dissected and found thrombosed, EVP no longer visible on MRI postoperatively, symptoms resolved
Tuan <i>et al.</i> (2016) ^[25]	37	M/1	Radiculopathy	EVP with cauda equina crowding, distended bladder	EVP	Distended bladder compression	L5-S1	Urinary catheter was placed to drain and decompress the bladder, EVP, and symptoms resolved
Donmez (2015) ^[8]	24	F/1	Radiculopathy	EVP	HD	Leiden Factor V mutation	-	Prophylactic antithrombotic treatment was given, resolution of symptoms was not reported
Raghavendra <i>et al.</i> (2014) ^[23]	43 45	M/1 F/1	Radiculopathy nerve roots	DP compressing	DP	-	L5-S1	Coagulative ablation of the dilated epidural veins was performed in both patients

(Contd...)

Table 1: (Continued)

Publications	Age	Sex	Presenting symptom	MRI findings	Init. diag.	Suspected cause of EVP	Spinal levels	Outcome
Dabasia et al. (2012) ^[4]	55	M/1	Myelopathy	EVP	SS	Follicular lymphoma occluding IVC	L2-L4	Chemotherapy reduced the para-aortic lymphadenopathy, follow-up MRI showed resolution of EVP, resolution myelopathy chemotherapy
Lee et al. (2011) ^[9]	72	F/1	Radiculopathy	Hypointense lesion at epidural space	-	Epidural venous thrombolith	T12-L1	Hemilaminectomy performed, left epidural vein was found dilated intraoperatively and was removed, radiculopathy symptom improved
Endres (2011) ^[10]	48	F/1	Radiculopathy	DP compressing a nerve root	DB	IVC hypoplasia collateral dilations	L4-L5	Determined surgery could not correct IVC hypoplasia, peripheral analgesics and low dose pregabalin reduced patient's symptoms, marcumar and compression therapy helpful, reduction in radiculopathy and pain
Floman et al. (2007) ^[12]	17	M/1	Radiculopathy	-	IVCT	IVC obstruction, Leiden Factor V mutation	L5-S1	IV heparin given followed by oral warfarin; patient had full resolution of symptoms with no further symptoms
Oterdoom et al. (2007) ^[21]	17	F/1	Cauda equina	Cauda equina compression from EVP	EVP	Iliac vein thrombosis increased venous inflow	-	Warfarin given, later replaced by coumarine, recovery and no new complaints
Pakoy and Gormus (2004) ^[22]	20-53	M/4 F/9	Radiculopathy Myelopathy	Tortuosity of epidural venous plexuses	HD	IVC obstruction prevented venous drainage	L3-S1 L4-S1 L5-S1	Inoperable intra-abdominal malignancy had low molecular weight heparin administered, venous thrombectomy for IVC thrombosis, LMWH given to eight patients, 12 patients without intra-abdominal malignancy had complete symptom resolution
Hammer et al. (2003) ^[15]	20-50	M/2 F/4	Radiculopathy	DP and DB	DP	-	L4-L5 L5-S1	Decompression and foraminotomy performed, EVP coagulated using a bipolar, no disk pathology in 5/6 patients, all patients had reduction in back pain and radiculopathy
Wong et al. (2003) ^[26]	40 50	M/2	Radiculopathy	DP and prominent veins in epidural space	HD	Phlebotrombosis and postdiscectomy EVP	L3-L4 L4-L5	Laminectomy with discectomy and excision of epidural vein, discectomy and coagulative ablation of epidural vein, EVP discovered intraoperatively, both patients decreased radicular symptoms and back pain
Genevay et al. (2002) ^[14]	67 70	M/1 F/1	Radiculopathy Myelopathy	DP	HD	Thrombosis venous dilation	T12-L1 L2-L3	Laminectomy where nonthrombotic varicose bundle compressing thecal sac was decompressed, both patients had reduced pain and resolved radiculopathy

(Contd...)

Table 1: (Continued)

Publications	Age	Sex	Presenting symptom	MRI findings	Init. diag.	Suspected cause of EVP	Spinal levels	Outcome
Demaerel et al. (1999) ^[6]	41	F/1	Radiculopathy	Hyperintense canal lesion on T1WI and hypointense T2WI	DF	-	L4-L5	Dilated vein found intraoperatively in epidural space compressing nerve root, vein coagulated and excised, free of symptoms
De Kruijk et al. (1999) ^[5]	58	M/1 Cauda equina	Radiculopathy	Dilated anterior epidural veins	CES	Dilated anterior IVC thrombosis	L4-S1	Treatment with IV heparin and acenocoumarol reduced neurological symptoms
Zimmerman et al. (1994) ^[27]	22-57	M/4	Radiculopathy	Hyperintense T2WI mass compressing thecal sac	HD	Obesity-related venous abnormalities	L4-L5	EVP discovered intraoperatively compressing nerve root and was aspirated and excised, pathology report showed injured vessel wall and thrombosis, all patients reported resolution of radiculopathy
Epstein (1947) ^[11]	33-57	M/3	Radiculopathy	-	HD	-	L4-L5 L5-S1	EVP discovered intraoperatively with subsequent bleeding and no evidence of HD, all patients reported resolution of radiculopathy
Cohen (1941) ^[3]	54	F/1	Radiculopathy	-	HD	-	L2-L4	Laminectomy discovered EVP along a nerve root and brisk bleeding occurred, patient's radiculopathy resolved after surgery
Elsberg (1916) ^[9]	-	-	Radiculopathy	-	T	-	-	Six patients, laminectomy revealed enlarged vessels running under nerve roots which were ligated and excised, pain, and symptoms resolved in some patients

M: Male, F: Female, R: Radiculopathy, M: Myelopathy, CES: Cauda equina syndrome, HD: Herniated disk, DB: Disk bulge, DP: Disk prolapse, SS: Spinal stenosis, IVC: IVC thrombosis, DF: Disk fragment, VAS: Vascular origin, T: Spinal tumor, MRI (T1WI): Magnetic resonance imaging T1-weighted, MRI (T2WI): Magnetic resonance imaging (T2-weighted), LMWH: Low molecular weight heparin

radiculopathy, followed respectively by myelopathy and cauda equina syndrome. In most cases, the surgeons initially had a preoperative diagnosis other than EVP of herniated disks or lumbar stenosis; other diagnoses were: cauda equina syndrome, tumor, disk bulge, disk fragment, disk prolapse, inferior vena cava (IVC) thrombosis, and vascular origin. MRI findings consisted of herniated disk, dural sac compression, cystic lesion, spondylosis, nerve root compression, hypo-/hyperintense canal lesion, and tortuous/dilated epidural vein. EVPs were found between T12-S1 and most often occurred between L4-S1 levels. Some of the reports did not opt for surgery, but all cases reported a final or postoperative diagnosis of EVP. Determined causes of the EVPs included: iliac vein stenosis, obesity, lumboperitoneal shunt intracranial hypotension, May-Thurner syndrome, Factor V Leiden mutation, follicular lymphoma, epidural venous thrombolith, IVC thrombosis/hypoplasia, previous microdiscectomy, oral contraceptives, and pregnancy. Complications included intraoperative hemorrhage, abortion of the surgical procedure, and residual radiculopathy.

Location and pathology of EVPs

EVPs are variously attributed to IVC thrombosis/hypoplasia and iliac vein stenosis. EVPs in the lumbar region represent dilations of the vertebral venous plexus system resulting from either increased blood flow or disrupted venous drainage. Notably, EVP at the cervical and thoracic levels have different regional etiologies.^[1,13] EVPs are variously attributed to: vascular anomalies such as IVC thrombosis/hypoplasia, iliac vein stenosis, obesity related IVC obstruction, bladder distention, intracranial hypotension, previous microdiscectomy, coagulopathy, Factor V Leiden mutation, protein C deficiency, Behcet's, and Budd-Chiari syndrome.^[18,22] These conditions block normal venous drainage into or through the IVC, and divert blood flow into collaterals through the vertebral venous plexus; this results in venous engorgement and compression of the thecal sac, nerve roots, or cauda equine.^[22]

Encountering unanticipated EVPs during lumbar surgery

Although rare, clinicians should consider EVPs in their differential diagnosis when encountering patients with radiculopathy who also have a history of obesity, vascular conditions, current pregnancy, or are taking oral contraceptives.^[18,21,22] Where EVPs are discovered intraoperatively, surgical decompression utilizing electrocautery or hemostatic techniques should be performed to relieve neural compression and radiculopathy.^[2,14,15,26] However, avoiding rupture of these vessels is critical as this can contribute to marked increase difficulty in obtaining hemostasis.^[2] An immediate postoperative MRI should be used to confirm adequate obliteration of the

EVP. Alternatively, there are instances in which medical management with anticoagulation of those with iliac vein or IVC thrombosis will sufficiently resolve signs/symptoms.^[5,10,12,21,22]

Differentiating between EVP and disk on MRI

Differentiating between EVPs and herniated disks can be difficult, as both have similar MRI appearances. However, lumbar disk herniations typically appear hypo/hyperintense on MRI reflecting their water content.^[2] EVPs on T1-weighted MRI contain low signal intensity flow voids which mimic solid mass lesions, similar to disk herniations.^[19,26] However, thrombosed varices can be hyperintense on both T1- and T2-weighted MRIs (T2WI).^[23] EVPs without thrombosis vary in signal intensity depending on the rate of blood flow (e.g., hypointense at normal and hyperintense at slow blood flow rates).^[16,17] In this case, the sagittal T2WI showed the EVP at the posterior body of L5 seemingly in continuity with the disk, exhibiting a similar signal intensity as an extruded disk. In retrospect, the homogeneity of signal intensity in our patient's MRI and the relatively preserved disk height should have raised the possibility that we were dealing with an EVP. Although we were able to control the venous bleeding, cases of extensive intraoperative hemorrhages have been reported.^[13]

CONCLUSION

We report a 58-year-old female with a lumbar EVP above the level of a prior L5-S1 ALIF. Although rare, EVP should be anticipated if additional EVP-related MRI findings are present.

Acknowledgments

There were no conflicts of interest or sources of funding for this work.

Declaration of patient consent

Patient's consent not required as patients identity is not disclosed or compromised.

Financial support and sponsorship

Nil.

Conflicts of interest

There are no conflicts of interest.

REFERENCES

1. Amano E, Ozaki K, Egawa S, Suzuki M, Hirai T, Ishibashi S, *et al.* Dynamic spinal compression revealed by computed

- tomography myelography in overshunting-associated myelopathy: A case report. *Medicine (Baltimore)* 2018;97:e0082.
2. Bursalı A, Akyoldas G, Guvenal AB, Yaman O. Lumbar epidural varix mimicking disc herniation. *J Korean Neurosurg Soc* 2016;59:410-3.
 3. Cohen I. Extradural varix simulating herniated nucleus pulposus. *J Mt Sinai Hosp N Y* 1941;8:136-8.
 4. Dabasia H, Rahim N, Marshall R. Neurogenic claudication without spinal stenosis arising as a result of lumbar epidural varices. *J Bone Joint Surg Br* 2012;94:1292-4.
 5. de Kruijk J, Korten A, Boiten J, Wilmink J. Acute cauda equina syndrome caused by thrombosis of the inferior vena cava. *J Neurol Neurosurg Psychiatry* 1999;67:827-8.
 6. Demaerel P, Petré C, Wilms G, Plets C. Sciatica caused by a dilated epidural vein: MR findings. *Eur Radiol* 1999;9:113-4.
 7. Díaz CT, Allegue NA, Sala DG, Martins GG, Torremorell MB, Montoya SB. Cauda equina syndrome caused by epidural venous plexus engorgement in a patient with may-thurner syndrome. *Ann Vasc Surg* 2019;60:480.e7-480.e11.
 8. Donmez FY. Epidural venous plexus engorgement: What lies beneath? *Case Rep Radiol* 2015;2015:965106.
 9. Elsberg CA. The surgical significance and operative treatment of enlarged and varicose veins of the spinal cord. *Am J Med Sci* 1916;151:78-86.
 10. Endres S. Epidural varicosity as a possible cause of radicular pain: A case report. *J Med Case Rep* 2011;5:537.
 11. Epstein BS. Low back pain associated with varices of the epidural veins simulating herniation of the nucleus pulposus. *Am J Roentgenol Radium Ther* 1947;57:736-40.
 12. Floman Y, Smorgick Y, Rand N, Bar-Ziv J. Inferior vena cava thrombosis presenting as lumbar radiculopathy. *Am J Phys Med Rehabil* 2007;86:952-5.
 13. Fredrickson VL, Patel A, Pham MH, Strickland BA, Ohiorhenuan I, Chen T. Spine surgery complicated by an engorged lumbar epidural venous plexus from cerebrospinal fluid overshunting: A case report and review of the literature. *World Neurosurg* 2018;111:68-72.
 14. Genevay S, Palazzo E, Hutten D, Fossati P, Meyer O. Lumboradiculopathy due to epidural varices: Two case reports and a review of the literature. *Joint Bone Spine* 2002;69:214-7.
 15. Hammer A, Knight I, Agarwal A. Localized venous plexi in the spine simulating prolapse of an intervertebral disc: A report of six cases. *Spine (Phila Pa 1976)* 2003;28:E5-12.
 16. Hanley EN, Howard BH, Brigham CD, Chapman TM, Guilford WB, Coumas JM. Lumbar epidural varix as a cause of radiculopathy. *Spine (Phila Pa 1976)* 1994;19:2122-6.
 17. Im IK, Son ES, Kim DH. Lumbar epidural varix causing radicular pain: A case report and differential diagnosis of lumbar cystic lesions. *PM R* 2018;10:1283-7.
 18. Jeong HJ, Sim WS, Park HJ, Lee SH, Oh MS, Cho MK, *et al.* Severe lumbar radiculopathy with epidural venous plexus engorgement in a morbidly obese pediatric patient: A case report. *Medicine (Baltimore)* 2019;98:e16842.
 19. Lee YS, Choi ES, Kim JO, Ji JH. A rare calcified thrombosis of the dilated epidural venous plexus presenting with lumbar radiculopathy: A case report. *Spine J* 2011;11:e28-31.
 20. Maki Y, Takayama M, Hayashi H, Yokoyama Y, Agawa Y. Cauda equina syndrome due to dural sac shift with engorgement of the epidural venous plexus: Rare complication after lumbar microdiscectomy. *World Neurosurg* 2017;104:e15-1048.
 21. Oterdoom DL, de Jong BM, Hoogland PV, Groen RJ. Transient cauda equina compression syndrome and headache caused by internal vertebral venous plexus engorgement in a teenage female with vena cava inferior agenesis and iliac vein thrombosis. *J Neurol Neurosurg Psychiatry* 2007;78:1283-4.
 22. Paksoy Y, Gormus N. Epidural venous plexus enlargements presenting with radiculopathy and back pain in patients with inferior vena cava obstruction or occlusion. *Spine (Phila Pa 1976)* 2004;29:2419-24.
 23. Raghavendra V, Haridas P, Kumar A, Ajith k. Spinal epidural varices, a great mimic of intervertebral disc prolapse-a case series. *J Orthop Case Rep* 2014;4:3-5.
 24. Sniderman M. Epidural injections contraindicated for lumbar radiculopathy in may-thurner syndrome: A case report. *A Case Rep* 2018;9:294-6.
 25. Tuan AS, Nabavizadeh SA, Pukenas B, Mohan S, Learned KO. Reversible dilatation of lumbar epidural venous plexus secondary to pelvic venous compression: Mimicker of pathology. *BJR Case Rep* 2017;3:20150287.
 26. Wong CH, Thng PL, Thoo FL, Low CO. Symptomatic spinal epidural varices presenting with nerve impingement: Report of two cases and review of the literature. *Spine (Phila Pa 1976)* 2003;28:E347-50.
 27. Zimmerman GA, Weingarten K, Lavyne AM. Transient cauda equina compression syndrome and headache caused by internal vertebral venous plexus engorgement in a teenage female with vena cava inferior agenesis and iliac vein thrombosis. *J Neurosurg* 1994;80:914-8.

How to cite this article: Hassan O, Lewis CS, Aradhya L, Hirshman BR, Pham MH. Engorged venous plexus mimicking adjacent segment disease: Case report and review of the literature. *Surg Neurol Int* 2020;11:104.