




Case Report

Fungal mycotic aneurysm in a patient with *Aspergillus terreus* chronic meningoencephalitis

Marcos Vinicius Sangrador-Deitos¹, Jimena Alejandra González Olvera², Heidy Adames Espinal³, Graciela Cárdenas Hernández³, Verónica Angeles Morales³, José Luis Soto Hernandez³

Departments of ¹Neurosurgery and ³Neuroinfectology, National Institute of Neurology and Neurosurgery, Mexico, ²Department of Internal Medicine, Instituto Mexicano del Seguro Social, León, Mexico.

E-mail: *Marcos Vinicius Sangrador-Deitos - marcos_5949@hotmail.com; Jimena Alejandra González Olvera - gonzalezjimena@gmail.com; Heidy Adames Espinal - adames_espinal@hotmail.com; Graciela Cárdenas Hernández - gracielaardenas@yahoo.com.mx; Verónica Angeles Morales - vero_angeles_morales@yahoo.com.mx; José Luis Soto Hernandez - joseluis_sotohernandez@yahoo.com



*Corresponding author:

Marcos Vinicius Sangrador-Deitos,
Department of Neurosurgery,
National Institute of Neurology
and Neurosurgery, Insurgentes
Sur 3877, La Fama, Mexico City
- 14269, Mexico.

marcos_5949@hotmail.com

Received : 05 October 2019

Accepted : 13 May 2020

Published : 06 June 2020

DOI

10.25259/SNI_506_2019

Quick Response Code:



ABSTRACT

Background: Central nervous system involvement due to aspergillosis is an extremely serious entity, particularly in patients with severe neutropenia, hematological diseases, or post-transplant cases. Immunocompetent patients can be infected by intense exposure, particularly iatrogenic after invasive procedures.

Case Description: We present the case of a 26-year-old male with a 1 year appendectomy background, which required epidural anesthesia. After that surgery, insidious headache presented, requiring mild analgesics for adequate control. In the following weeks, headaches increased and tomographic imaging revealed hydrocephalus. A ventriculoperitoneal shunt was placed, and empirical treatment for neurocysticercosis was established, but diagnosis was never confirmed. Sequentially, shunt dysfunction occurred twice, for which shunt replacement was performed. Cerebrospinal fluid and shunt's catheter were cultured. Some days later, a filamentous fungus was isolated and finally identified as *Aspergillus* sp. Intravenous amphotericin B and fluconazole at therapeutic dosage were administered; however, a torpid clinical evolution was observed. After a 2-week antifungal scheme, the fungus was identified as *Aspergillus terreus*. The patient developed sudden rostrocaudal deterioration. Computed tomography imaging was done, revealing a 70 cc hematoma in the right operculoinsular region, midline shift, and a 9 mm saccular aneurysm at the bifurcation of the middle cerebral artery.

Conclusion: Cerebral aspergillosis is a serious disease with high mortality in patients, particularly those without identifiable risk factors. The iatrogenic forms are serious, due to the delay of clinical diagnosis. It is important to have a high index of suspicion in patients with a history of invasive procedures such as epidural anesthesia or surgery, and who develop a persistent chronic headache or chronic meningitis.

Keywords: Aneurysm, *Aspergillus terreus*, Mycotic

INTRODUCTION

In 1885, William Osler was the first to describe an aortic aneurysm secondary to infectious endocarditis.^[21] Since then, infectious, or so-called "mycotic," cerebral aneurysms are uncommon and represent around 1% of all intracranial aneurysms.^[2,12] Although the term mycotic refers to fungal infections, most of these aneurysms are caused by bacterial agents, being viridans

This is an open-access article distributed under the terms of the Creative Commons Attribution-Non Commercial-Share Alike 4.0 License, which allows others to remix, tweak, and build upon the work non-commercially, as long as the author is credited and the new creations are licensed under the identical terms.

©2020 Published by Scientific Scholar on behalf of Surgical Neurology International

group streptococci and *Staphylococcus aureus*, the two most common pathogens, secondary to infectious endocarditis that causes septic embolism. Fungal agents that can cause mycotic aneurysms (MA) include *Candida* species and *Aspergillus* species, and even specific organisms such as *Mycobacterium tuberculosis* can become a causal agent.^[22] *Aspergillus* species excels as the most common fungal agents in MA, and it was Oppe,^[20] in 1897, who reported the first case of cerebral aspergillosis in humans. Multiple cases of cerebral aspergillosis with aneurysm formation have been reported since, in which, a lethal outcome occurred in most of them [Table 1]^[1,5,7,8,9,18,19,26,27].

CASE DESCRIPTION

We present the case of a 26-year-old non-HIV male with a 1-year background appendectomy, which required epidural anesthesia. After surgery, he presented an insidious headache, requiring mild analgesics for adequate control. In the following weeks, headaches increased and tomographic imaging revealed hydrocephalus. A ventriculoperitoneal shunt was installed for suspicion of neurocysticercosis. Even though treatment was initiated, there was no clinical improvement. Sequentially, during hospital stay, shunt dysfunction occurred twice, for which shunt replacement was performed. Cerebrospinal fluid (CSF) and shunt's catheter were cultured, identifying a filamentous fungus. CSF and serum galactomannan tests

were positive for *Aspergillus* spp.: 9.4 ng/dl and 5.8 ng/dL, respectively. Intravenous amphotericin B and fluconazole were administered; however, a torpid clinical evolution was observed. The filamentous fungus was finally sequenced as *Aspergillus terreus*. After a 2-week antifungal scheme, sudden rostrocaudal deterioration appeared. Computed tomography imaging was done, revealing a 70 cc hematoma in the right operculoinsular region, midline shift [Figure 1a-c], and maximum intensity projections revealed a 9 mm saccular aneurysm at the bifurcation of the middle cerebral artery [Figure 2a and b]. Due to bad prognosis, hematoma evacuation surgery was not performed, and the patient died from intracranial hypertension 5 days after diagnosis. No evidence of immunocompromise was evidenced during hospital stay.

DISCUSSION

Fungal cerebral MAs are most commonly seen in patients with immunocompromised states, such as AIDS or complicated diabetes mellitus.^[3] Historically, infectious endocarditis has been considered as the main origin of septic emboli.^[25] However, there are multiple other origin sites that should be considered when facing these cases such as cavernous sinus thrombophlebitis,^[24] paranasal sinus infections,^[4] and, as in our case, following spinal anesthesia.^[6,23] Diagnosis still remains a challenge for most physicians, as the distinctive pathological process can only be evidenced through autopsy

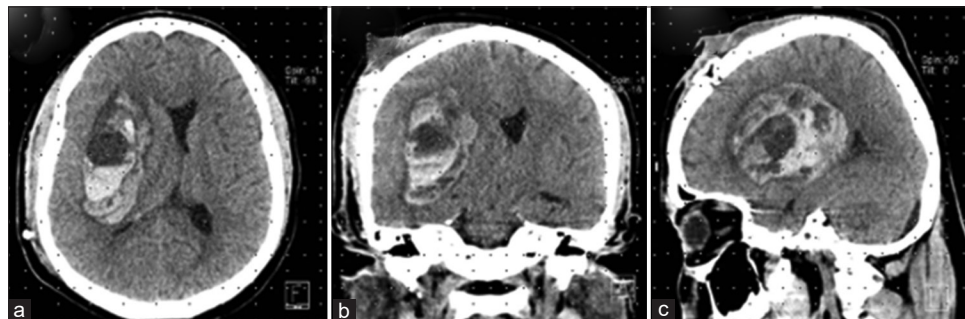


Figure 1: Simple computed tomography scan: (a) axial, (b) coronal, and (c) sagittal reconstructions, in which a right operculoinsular hematoma is observed. Due to the location of the hematoma, it can be suspected that the origin is from the middle cerebral artery.

Table 1: Reported cases of *Aspergillus* species mycotic aneurysms.

Study	Age (years)	Type of fungus	Outcome
Present case	26	<i>Aspergillus terreus</i>	Death 4 weeks after a presentation from aneurysm rupture
Ahuja et al. ^[11]	18	<i>Aspergillus</i> spp.	Death 25 days from status epilepticus secondary to subarachnoid hemorrhage
Horten et al. ^[7]	3 weeks	<i>Aspergillus fumigatus</i>	Death 9 days after a presentation from aneurysm rupture
Davidson et al. ^[15]	75	<i>Aspergillus</i> spp.	Death 2 months after presentation from aneurysm rupture
Iihara et al. ^[8]	78	<i>Aspergillus fumigatus</i>	Death 1 year after presentation due to ICA rupture complications
Wilson et al. ^[27]	77	<i>Aspergillus fumigatus</i>	Death on admission from aneurysm rupture
Lee et al. ^[18]	65	<i>Aspergillus</i> spp.	Death 10 days after presentation from aneurysm rupture
Nenoff et al. ^[19]	74	<i>Aspergillus fumigatus</i>	Death 16 months after presentation due to ICA rupture complications
Jao et al. ^[9]	76	<i>Aspergillus</i> spp.	Resolution after coiling (death from urosepsis and cardiac failure 7 months later)
Wang et al. ^[26]	41	<i>Aspergillus</i> spp.	Resolution after coiling (death from AIDS complications after 2 years)

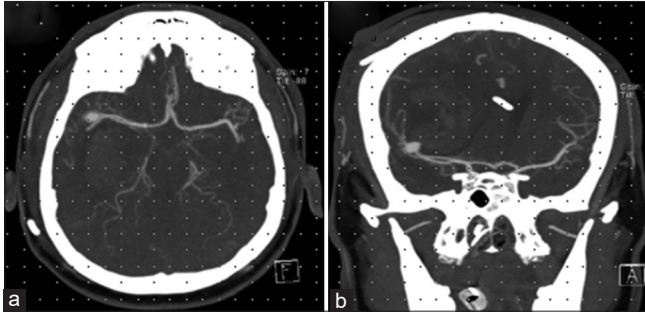


Figure 2: Contrast-enhanced computed angiography scan: (a) axial and (b) coronal reconstructions of maximum intensity projection images showing a saccular 9 mm aneurysm located in the right middle cerebral artery bifurcation.

material study. The causal organism can only be identified in 30–50% of cases when cultures from blood or CSF are taken.^[17] In 2008, Kanno *et al.*^[14] proposed diagnostic criteria for the diagnosis of MAs, which showed a sensitivity of 96% and a specificity of 100% when all the criteria are met [Table 2]. According to these criteria, our patient could be included in the “probable diagnosis” group, reaching a sensitivity of 100% and specificity of 87.4%.

Iatrogenic fungal infections of the central nervous system must be suspected in patients with meningitis and a background of epidural invasive procedures such as anesthesia or any drug administration.^[15] Kainer *et al.*^[11] reported a series of 66 patients, in which central nervous system fungal infections were evidenced following contaminated methylprednisolone epidural administration. All the patients presented with one of these syndromes: meningitis, cauda equina syndrome, focal infection, or stroke. CSF analysis is a useful, but not definite, diagnostic study, as the only constant variable observed in multiple studies is a white cell count above normal (>5 cells/mm³), as glucose and protein values tend to vary greatly, and it is suggested that antifungal treatment must be initiated as soon as pleocytosis is detected.^[13] Galactomannan detection in CSF is highly useful in *Aspergillus* detection with a sensitivity of 80% and specificity of 100%.^[16] Specific antifungal treatment must be always initiated as soon as diagnosis is suspected. Combined antifungal therapy is recommended for central nervous system infections, being caspofungin plus voriconazole the first option.^[10]

CONCLUSION

We present the first case report of a fungal MA of the middle cerebral artery bifurcation caused by *A. terreus*, a fungus found worldwide in soil. It has been reported to cause pathologic states in immunocompromised patients; however, our patient showed no evidence of immunocompromise whatsoever. Intrathecal inoculation following epidural anesthesia

Table 2: Diagnostic criteria for mycotic aneurysms.

Mandatory criterion

Aneurysm demonstrated by imaging

Supporting criteria

Predisposing infection:	Angiographic features:	Other features:
Infectious endocarditis	Multiplicity	Younger age <45 years
Meningitis	Distal location	History of recent lumbar puncture
Cavernous sinus thrombophlebitis	Fusiform shape	Fever at presentation
	Change in size of aneurysm/appearance of new aneurysm on follow-up	Intraparenchymal hemorrhage in CT/MRI

Definite: if mandatory criteria and any three of the supportive criteria are met

Probable: if mandatory criteria and any two of the supportive criteria are met

Possible: if mandatory criteria and any one of the supportive criteria are met

represents the form of transmission, which should be always taken into account with patients presenting this background history. The lethal outcome observed, depicts the intrinsic resistance this pathogen presents for amphotericin, which has been administered to the patient. Even though the wide range of diagnostic studies and treatment strategies, fungal central nervous system infections remain a diagnosis challenge which requires high suspicion and continues to be have one of the highest mortality rates among neurological diseases.

Declaration of patient consent

Patient’s consent is not required as identity is not disclosed or compromised.

Financial support and sponsorship

Nil.

Conflicts of interest

There are no conflicts of interest.

REFERENCES

- Ahuja G, Jain N, Vijayaraghavan M, Roy S. Cerebral mycotic aneurysm of fungal origin. Case report. *J Neurosurg* 1978;49:107-10.
- Akhaddar A, Diabira S. Intracranial fungal aneurysms. In: Turgut M, Challa S, Akhaddar A, editors. *Fungal Infections of the Central Nervous System*. Cham, Switzerland: Springer International Publishing; 2019. p. 327-34.
- Allen LM, Fowler AM, Walker C, Derdeyn CP, Nguyen BV, Hasso AN, *et al.* Retrospective review of cerebral mycotic aneurysms in 26 patients: Focus on treatment in strongly immunocompromised patients with a brief literature review.

- AJNR Am J Neuroradiol 2013;34:823-7.
4. Azar MM, Assi R, Patel N, Malinis MF. Fungal mycotic aneurysm of the internal carotid artery associated with sphenoid sinusitis in an immunocompromised patient: A case report and review of the literature. *Mycopathologia* 2016;181:425-33.
 5. Davidson P, Robertson D. A true mycotic (*Aspergillus*) aneurysm leading to fatal subarachnoid hemorrhage in a patient with hereditary hemorrhagic telangiectasia. Case report. *J Neurosurg* 1971;35:71-6.
 6. Gunaratne PS, Wijeyaratne CN, Chandrasiri P, Sivakumaran S, Sellahewa K, Perera P, et al. An outbreak of *Aspergillus meningitis* following spinal anaesthesia for caesarean section in Sri Lanka: A post-tsunami effect? *Ceylon Med J* 2006;51:137-42.
 7. Horten B, Abbott G, Porro R. Fungal aneurysms of intracranial vessels. *Arch Neurol* 1976;33:577-9.
 8. Iihara K, Makita Y, Nabeshima S, Tei T, Keyaki A, Nioka H. Aspergillosis of the central nervous system causing subarachnoid hemorrhage from mycotic aneurysm of the basilar artery--case report. *Neurol Med Chir (Tokyo)* 1990;30:618-23.
 9. Jao SY, Weng HH, Wong HF, Wang WH, Tsai YH. Successful endovascular treatment of intractable epistaxis due to ruptured internal carotid artery pseudoaneurysm secondary to invasive fungal sinusitis. *Head Neck* 2011;33:437-40.
 10. Johnson M, Perfect J. Use of antifungal combination therapy: Agents, order, and timing. *Curr Fungal Infect Rep* 2010;4:87-95.
 11. Kainer MA, Reagan DR, Nguyen DB, Wiese AD, Wise ME, Ward J, et al. Fungal infections associated with contaminated methylprednisolone in Tennessee. *N Engl J Med* 2012;367:2194-203.
 12. Kannoth S, Iyer R, Thomas SV, Furtado SV, Rajesh BJ, Kesavadas C, et al. Intracranial infectious aneurysm: Presentation, management and outcome. *J Neurol Sci* 2007;256:3-9.
 13. Kannoth S, Thomas S. Intracranial microbial aneurysm (infectious aneurysm): Current options for diagnosis and management. *Neurocrit Care* 2009;11:120-9.
 14. Kannoth S, Thomas SV, Nair S, Sarma PS. Proposed diagnostic criteria for intracranial infectious aneurysms. *J Neurol Neurosurg Psychiatry* 2008;79:943-6.
 15. Kauffman C, Pappas P, Patterson T. Fungal infections associated with contaminated methylprednisolone injections. *N Engl J Med* 2013;368:2495-500.
 16. Klont R, Mennink-Kersten M, Verweij P. Utility of *Aspergillus* antigen detection in specimens other than serum specimens. *Clin Infect Dis* 2004;39:1467-74.
 17. Lahoti S, Berger J. Iatrogenic fungal infections of the central nervous system. *Curr Neurol Neurosci Rep* 2013;13:399.
 18. Lee DH, Yoon TM, Lee JK, Joo JE, Park KH, Lim SC. Invasive fungal sinusitis of the sphenoid sinus. *Clin Exp Otorhinolaryngol* 2014;7:181-7.
 19. Nenoff P, Kellermann S, Horn LC, Keiner S, Bootz F, Schneider S, et al. Case report. Mycotic arteritis due to *Aspergillus fumigatus* in a diabetic with retrobulbar aspergillosis and mycotic meningitis. *Mycoses* 2001;44:407-14.
 20. Oppe W. Zur kenntniss der schimmelmymykosen beim menschen. *Z Allg Path* 1897;8:301-6.
 21. Osler W. The Gulstonian lectures, on malignant endocarditis. *Br Med J* 1885;1:467-70.
 22. Roach M, Drake C. Ruptured cerebral aneurysms caused by micro-organisms. *N Engl J Med* 1965;273:240-4.
 23. Rodrigo N, Perera KN, Ranwala R, Jayasinghe S, Warnakulasuriya A, Hapuarachchi S. *Aspergillus meningitis* following spinal anaesthesia for caesarean section in Colombo, Sri Lanka. *Int J Osbtet Anesth* 2007;16:256-60.
 24. Suwanwela C, Suwanwela N, Charuchinda S, Hongsaprabhas C. Intracranial mycotic aneurysms of extravascular origin. *J Neurosurg* 1972;36:552-9.
 25. Venkatesh SK, Phadke RV, Kalode RR, Kumar S, Jain VK. Intracranial infective aneurysms presenting with haemorrhage: An analysis of angiographic findings, management and outcome. *Clin Radiol* 2000;55:946-53.
 26. Wang H, Rammos S, Fraser K, Elwood P. Successful endovascular treatment of a ruptured mycotic intracavernous carotid artery aneurysm in an AIDS patient. *Neurocrit Care* 2007;7:156-9.
 27. Wilson WR, Hawrych A, Olan W. Rapid development of bilateral internal carotid artery aneurysm from sphenoid sinus aspergillosis. *Skull Base Surg* 1998;8:211-4.

How to cite this article: Deitos MV, Olvera JA, Espinal HA, Hernández GC, Morales VA, Hernandez JS. Fungal mycotic aneurysm in a patient with *Aspergillus terreus* chronic meningoencephalitis. *Surg Neurol Int* 2020;11:139.