

Image Report

Hypertrophic cranial pachymeningitis coinfection with tuberculosis and actinomycosis

Ali Akhaddar¹, Issam Rharrassi²

¹Department of Neurosurgery, Avicenne Military Hospital, Mohammed V University, Rabat, ²Department of Pathology, Avicenne Military Hospital of Marrakech, Marrakech, Morocco.

E-mail: *Ali Akhaddar - akhaddar@hotmail.fr; Issam Rharrassi - rharrassi@yahoo.fr

*Corresponding author:

Ali Akhaddar,
Department of Neurosurgery,
Avicenne Military Hospital,
Mohammed V University,
Rabat, Morocco.

akhaddar@hotmail.fr

Received : 25 June 2020

Accepted : 01 July 2020

Published : 18 July 2020

DOI

10.25259/SNI_383_2020

Quick Response Code:



ABSTRACT

This is a rare case report about hypertrophic cranial pachymeningitis coinfection with tuberculosis and actinomycosis in a 35-year-old male. The patient presented with progressive headache, paraesthesia, and blurred vision. Dural biopsy, histology, and cultures are imperative in pachymeningitis for establishing the diagnosis and guiding treatment.

Keywords: Actinomycosis, Hypertrophic cranial pachymeningitis, Intracranial infection, Pachymeningitis, Tuberculosis

IMAGE REPORT

A 35-year-old male presented with progressive headache, paraesthesia, and blurred vision. The MRI showed diffuse meningeal enhancement with thickening, along with areas of brain edema [Figure 1a-c]. Despite this mild meningeal inflammatory syndrome, cultures were negative. Although there was an initial perceived response to steroids, the patient had a relapse. A dural biopsy revealed

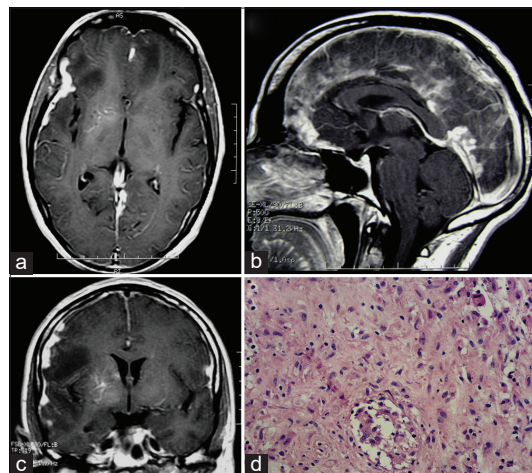


Figure 1: Axial (a), sagittal (b), and coronal (c) cranial magnetic resonance imaging following gadolinium injection showing diffuse meningeal enhancement and thickening, along with areas of brain edema. Dural biopsy revealing epithelioid-giant cell granulomas with caseous necrosis (hematoxylin-eosin staining) (d).

This is an open-access article distributed under the terms of the Creative Commons Attribution-Non Commercial-Share Alike 4.0 License, which allows others to remix, tweak, and build upon the work non-commercially, as long as the author is credited and the new creations are licensed under the identical terms.

©2020 Published by Scientific Scholar on behalf of Surgical Neurology International

epithelioid-giant cell granulomas with caseous necrosis, and TB-PCR of tissue was positive [Figure 1d]. In addition, the anaerobic culture (requiring about 4 weeks) eventually grew *Actinomyces* species. The patient had a good response to oral ciprofloxacin and antituberculous medication. The conclusion was that dural biopsy, histology, and cultures are imperative in pachymeningitis for establishing the diagnosis and guiding treatment.

Declaration of patient consent

The authors certify that they have obtained all appropriate patient consent.

Financial support and sponsorship

Nil.

Conflicts of interest

There are no conflicts of interest.

How to cite this article: Akhaddar A, Rharrassi I. Hypertrophic cranial pachymeningitis coinfection with tuberculosis and actinomycosis. *Surg Neurol Int* 2020;11:201.