



Case Report

Brainstem abscess treated conservatively

Camila Furtado Leao¹, Maira Piani Couto², Jose Antonio Santos de Lima², Eric Homero Albuquerque Paschoal³, Jose Reginaldo Nascimento Brito²

¹Department of Medicine, State University of Para, ²Department of Neurosurgery, Ophir Loyola Hospital, ³Federal University of Para, Belem, Para, Brazil.

E-mail: *Camila Furtado Leao - camilaleao95@gmail.com; Maira Piani Couto - mairapiani@hotmail.com; Jose Antonio Santos de Lima - josedelima.87@gmail.com; Eric Homero Albuquerque Paschoal - ericpaschoal@yahoo.com.br; Jose Reginaldo Nascimento Brito - jrnbrito@gmail.com



*Corresponding author:

Camila Furtado Leao,
Department of Medicine,
State University of Para, 2623
Perebeui Street,
Belem - 66087-662, Para, Brazil.
camilaleao95@gmail.com

Received : 21 November 2019

Accepted : 25 June 2020

Published : 25 July 2020

DOI

10.25259/SNI_569_2019

Quick Response Code:



ABSTRACT

Background: Brainstem abscess is a rare condition with a variety of treatment approaches. In this paper, we report an unusual case of a brainstem abscess with a positive outcome in an immunocompetent patient who was treated with antibiotic therapy.

Case Description: A 22-year-old female presented with bilateral tetraparesis that was worse on the left hemibody, appendicular tremor, and left upper eyelid ptosis. Brain magnetic resonance imaging showed an abscess in the pons and midbrain due to possible nocardiosis. She was treated with dexamethasone, phenytoin, vancomycin, and meropenem for 8 weeks and trimethoprim-sulfamethoxazole for 6 weeks. The brain injury decreased, and the patient's neurological status significantly improved.

Conclusion: Brainstem abscess may be treated conservatively, leading to improvement of the clinical condition and decreased lesion size on imaging.

Keywords: Antibiotic therapy, Brain abscess, Brainstem, Nocardia infections

INTRODUCTION

Brainstem abscess is an uncommon and severe condition.^[2,7,15] The pons and midbrain are more commonly affected than other brain regions.^[4,13] This condition is frequently associated with HIV and diabetes.^[12] The most common causative microorganisms identified are *Streptococcus* spp., *Staphylococcus* spp., *Listeria* spp., *Mycobacterium tuberculosis*, Cytomegalovirus, *Nocardia* spp., *Toxoplasma gondii*, and *Haemophilus influenzae* type b (*Hib*).^[12,16,25]

The clinical manifestations depend on the size and stage of the infection. Symptoms include fever, headache, vomiting (due to an increase in intracranial pressure), tetraparesis, and diplopia, with or without sepsis.^[9,12,15,16] Treatment depends on the clinical presentation, the affected area, and the etiology of infection.^[7]

CASE REPORT

A 22-year-old immunocompetent female was referred to Ophir Loyola Hospital presenting a 6-day history of tetraparesis, which was worst in the left hemibody, appendicular tremor, and left upper eyelid ptosis. On admission, the Glasgow coma scale (GCS) was 13, and she presented tetraparesis,

This is an open-access article distributed under the terms of the Creative Commons Attribution-Non Commercial-Share Alike 4.0 License, which allows others to remix, tweak, and build upon the work non-commercially, as long as the author is credited and the new creations are licensed under the identical terms.

©2020 Published by Scientific Scholar on behalf of Surgical Neurology International

which was worst in left hemibody, ataxia, hypoesthesia of the left side of the face and the left hemibody, left upper eyelid ptosis, right 6th cranial nerve paresis, right peripheral facial paralysis, vertigo, and nausea. She could not walk and was using a nasogastric tube. No other alterations were observed. Magnetic resonance imaging (MRI) of the brain showed an encapsulated lesion with peripheral contrast in the brainstem (pons and midbrain), suggestive of abscess; after spectrometric study, the lesion measured 18.7 mm axially and 23.2 mm sagittally [Figure 1]. In addition, chest computed tomography (CT) showed a right pulmonary intraparenchymal lesion suggestive of fungus, and biopsy of the collected pulmonary fragment demonstrated pulmonary tissue and bronchial mucosa without significant histological changes and with no granulomas or atypia. All bacterial cultures and serological tests were negative. The liquor was cloudy and purulent, with 15872 cells, 85 erythrocytes, 100% polymorphonuclear leukocytes, and total protein: 149 mg/dL. Therapy with vancomycin (2 g/day), meropenem (3 g/day), and dexamethasone was introduced. On the 4th day of hospitalization, phenytoin was added to the therapeutic regimen. Every 15 days, MRI of the brain was performed to monitor evolution, and the images indicated a gradual decrease in the size of the abscess.

On the 42nd day of hospitalization, the patient underwent a new chest CT that showed improvement in lung injury, and a presumptive diagnosis of nocardiosis was established by a pneumologist. Thus, trimethoprim-sulfamethoxazole (160 mg + 800 mg) was added to the antibiotic regimen.

On the 49th day of hospitalization, after 8 weeks of vancomycin and meropenem and 2 weeks of trimethoprim-sulfamethoxazole, the patient was discharged. On physical

examination, she was conscious and oriented, with GCS 15 and normal reflexes, presenting retardation of movement of the arm, strength graduated on 4/5 of the left arm, and hypoesthesia of the left hemibody. In addition, the patient presented with right 6th cranial nerve paresis and right peripheral facial paralysis and did not walk. The image examination showed a lesion measuring 4.9 mm (axially) × 11 mm (sagittally) [Figure 2]. The patient was prescribed outpatient treatment with ciprofloxacin (500 mg/day) for 2 weeks and prednisone (40 mg/day) for 2 months, and trimethoprim-sulfamethoxazole (160 mg + 800 mg) was maintained for more 30 days.

After 2 weeks, she returned to the neurosurgery ambulatory service; she was walking with support and had right 6th cranial nerve paresis, right peripheral facial paralysis, diplopia, and GCS 15.

DISCUSSION

Here, we described the evolution of a case of a female patient who was treated at the neurosurgery service of a hospital for brainstem abscess after pulmonary nocardiosis. She was treated with antibiotic therapy, which resulted in improvement of neurological condition and neuroimaging, with a decrease in lesion size of 13.8 mm axially and 12.2 mm sagittally.

Drug therapy must be considered the first choice for brainstem abscesses, principally due to the difficulty of surgical access.^[19,26]

We found 14 case reports describing antibiotic therapy for the treatment of brainstem abscess.^[6,8-11,14,17-20,22-24,26] A summary is shown in [Table 1]. The outcomes of those case reports support our outcome.

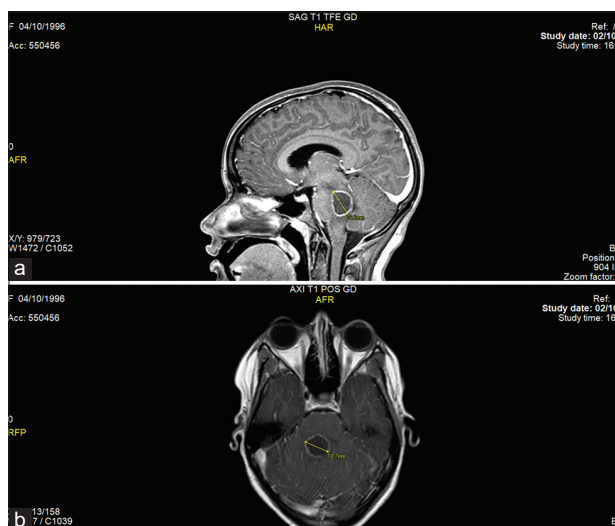


Figure 1: (a) Magnetic resonance imaging showing contrast (gadolinium) lesions in the pons and midbrain in the sagittal orientation before antibiotic treatment. (b) Magnetic resonance imaging showing contrast (gadolinium) lesions in the pons and midbrain in the axial orientations before antibiotic treatment.

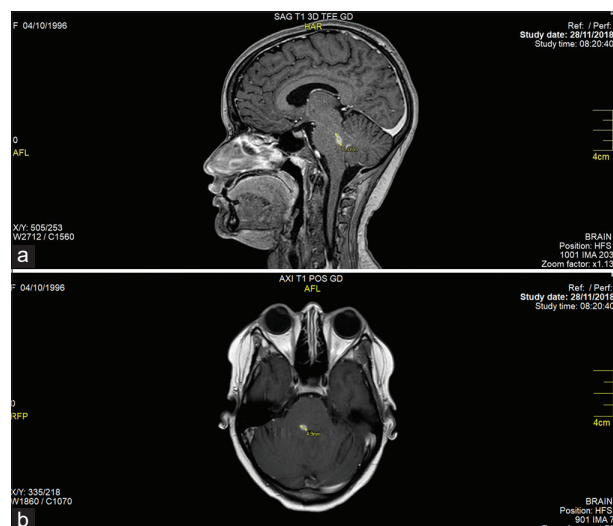


Figure 2: (a) Magnetic resonance imaging showing contrast (gadolinium) lesions in the pons and midbrain in the sagittal orientation after antibiotic treatment. (b) Magnetic resonance imaging showing contrast (gadolinium) lesions in the pons and midbrain in the axial orientation after antibiotic treatment.

Table 1: Clinical summary of patients with brainstem abscess treated with antibiotics only.

References	Year	Sex/age (year)	Presenting symptoms	Location	Organism	Empiric treatment	Etiologic treatment	Outcome	Size of abscess after treatment
Kumar et al.	2017	Female/0.8	Left eye medial rectus palsy and plantar reflexes were flexor	Midbrain, pontine, right basal ganglia, thalamus, and corona radiata	<i>Burkholderia pseudomallei</i>	Ceftriaxone and vancomycin for 5 days	Meropenem for 6 weeks and cotrimoxazole for 6 months	No residual neurological deficits	n.m.
Chen et al.	2013	Male/59	Right 6 th cranial nerve palsy, mild ptosis, dysmetria, and left-sided facial, and body paresthesia	Pons	n.m.	Ampicillin/sulbactam (4.5 g/day), ceftriaxone (4 g/day), clindamycin (600 mg) and betamethasone (12 mg/day)	n.m.	Left-sided facial dysesthesia	Decreased
Chow et al.	2013	Male/60	Diplopia, gait instability and right facial droop	Right posterior pons	<i>Nocardia farcinica</i>	Voriconazole, linezolid, ceftriaxone, and metronidazole	Ceftriaxone and TMP-SMX	Without neurological deficits	Decreased
Faisant et al.	2012	Female/28	Babinski's sign on the left and anisocoria	Right frontal lobe, right peduncle, left internal capsule	<i>Neisseria meningitidis group B</i>	n.m.	Amoxicillin (10 g/day) for 6 weeks	Without neurological deficits	Punctiform lesion of the right cerebral peduncle
Tanaka et al.	2011	Male/67	Diplopia, dizziness, and dysesthesia of the left upper and lower extremities	Right pons	n.m.	Meropenem (6 g/day) for 2 months	n.m.	Neurological deficits improved	Without abscess
Ramalho et al.	2008	Female/68	Hypoesthesia on the right, right cerebellar alteration, alteration of the 3 th , 4 th , 5 th , 6 th , and 7 th cranial nerves	Pons, left middle cerebellar peduncle, and midbrain	<i>Streptococcus viridians</i>	TMP-SMX, metronidazole, vancomycin, and fluconazole	Meropenem	Patient's neurological status significantly improved	n.m.
Ricard et al.	2008	Male/63	Meningeal signs, right hemiparesis and Parinaud syndrome	Left peduncle	<i>Listeria monocytogenes</i>	TMP-SMX (3200 mg-640 mg/day) and cefotaxime 8 g/d for one day	Amoxicillin (8 g/day) for 1 month and Gentamicin	Right hemiparesis and left 3 rd cranial nerve palsy	n.m.
Soares-Fernandes et al.	2008	Female/46	Comatose, with conjugate eye deviation to the right, left hemiparesis and neck stiffness	Right thalamus, basal ganglia and frontal white matter and midbrain	<i>Listeria monocytogenes</i>	n.m.	Ampicillin (8 g/day) for 8 weeks and gentamicin (300 mg/day) for 4 weeks	Slight bilateral restriction of ocular abduction and moderate left-sided hemiparesis (grade 4/5)	Residual enhancement in the right basal ganglia

(Contd...)

Table 1: (Continued).

References	Year	Sex/age (year)	Presenting symptoms	Location	Organism	Empiric treatment	Etiologic treatment	Outcome	Size of abscess after treatment
Smiatecz et al.	2006	Male/24	Vertigo, dysarthria, dysphagia with pharyngeal and palatal areflexia, nystagmus, paresis with paresthesia of the right leg, positive Romberg and neck stiffness	Dorsal region of the brainstem and deep structures of the left hemisphere	<i>Listeria monocytogenes</i>	Ceftriaxone, doxycycline and acyclovir	Ampicillin for 6 weeks, Gentamycin for 10 days and dexamethasone	Palatal and pharyngeal are flexia and slight dysmetria	Without abscess
Bekar et al.	2004	Male/33	V1-V2 hypoesthesia and diminished corneal reflex	Right pons	n.m.	Metronidazole (1500 mg/day) and ceftriaxone (4 g/day) for 6 weeks	n.m.	Without neurological deficits	Without abscess
Pandian et al.	2000	Male/11	Partial ptosis, a dilated sluggishly reacting pupil, and restricted elevation and abduction involving the left eye, right facial weakness, incoordination of right upper and lower limbs	Midbrain and pons	n.m.	Crystalline penicillin, chloramphenicol, metronidazole, and dexamethasone	n.m.	Without neurological deficits	Without abscess
Fulgham et al.	1996	Male/62	Bilateral ptosis, markedly impaired upgaze, paresis of the left abducens nerve, left intranuclear ophthalmoplegia, bilateral nystagmus, ataxic with tandem gait	Midbrain and upper pons associated with ventricular enhancement	n.m.	Ceftazidime (6 g/day), nafcillin (9 g/day), metronidazole (2 g/day)	n.m.	Mild ataxia and difficulty with double vision	Without abscess
Carpenter	1994	Female/31	Bilateral torsion nystagmus, weakness and areflexia in the lower limbs, weakness in the left upper extremity	Brain stem to medulla	n.m.	Penicillin, nafcillin, Gentamicin, ceftazidime (9 g/day), nafcillin (12 g/day), tobramycin, ampicillin (12 g/day), rifampin, vancomycin, trimethoprim-sulfamethoxazole and amoxicillin/clavulanate	n.m.	Nystagmus	Normal brain stem, but the cervical spine was not well visualized
Outin et al.	1989	Male/26	Right pontomedullary deficit and meningitis	From the superior cerebellar peduncle to the lateral portion of the medulla	<i>Listeria</i>	n.m.	Ampicillin for 5 months	Soft palate right paresis	Without abscess

*n.m.: Not mentioned. TMP-SMX: trimethoprim-sulfamethoxazole

Empirical treatment with broad-spectrum antibiotics must be started immediately and maintained for 6 to 8 weeks or more, with sequential brain MRI to monitor the effectiveness of the treatment every 2 weeks.^[2,9,12,13,15] The antibiotic used may be vancomycin or meropenem at high doses.^[26] After diagnosis or presumed diagnosis of microorganisms that might cause symptoms, the drug must be reviewed.

Infections caused by nocardia may affect the skin, lung, and lymph nodes and may disseminate to the central nervous system (CNS).^[5,21] Chest images may demonstrate a single or multiple nodules or a cavity.^[3] The treatment recommended by experts is trimethoprim-sulfamethoxazole for 12 months in cases of brainstem abscess.^[1,3]

In this case report and literature review, we showed that conservative treatment of brainstem abscess may lead to a positive outcome.

Declaration of patient consent

The authors certify that they have obtained all appropriate patient consent.

Financial support and sponsorship

Nil.

Conflicts of interest

There are no conflicts of interest.

REFERENCES

1. Aliaga L, Fatoul G, Guirao E, Peña A, Rodríguez-Granger J, Cobo F. *Nocardia paucivorans* brain abscess. Clinical and microbiological characteristics. IDCases 2018;13:e00422.
2. Arias M, Dapena D, Arias-Rivas S, Vázquez F. Widespread brainstem abscess resolved with medical therapy. Neurologia 2007;22:118-21.
3. Arrache D, Zait H, Rodriguez-Nava V, Bergeron E, Durand T, Yahiaoui M, et al. Cerebral and pulmonary nocardiosis to *Nocardia abscessus* in an immunocompetent Algerian patient. J Mycol Med 2018;28:531-7.
4. Arzoglou V, D'Angelo L, Koutzoglou M, Di Rocco C. Abscess of the medulla oblongata in a toddler: Case report and technical considerations based on magnetic resonance imaging tractography. Neurosurgery 2011;69:E483-7.
5. Baburao A, Prasad S, Prakash S, Narayanswamy H. Pulmonary nocardiosis: Report of two cases from a tertiary care hospital. Indian J Pathol Microbiol 2019;62:153-5.
6. Bekar A, Kocaeli H, Yilmaz E, Doğan S. Trigeminal neuralgia caused by a pontine abscess: Case report. Neurosurgery 2004;55:E1450-2.
7. Bulthuis VJ, Gubler FS, Teernstra OP, Temel Y. A case of a brain stem abscess with a favorable outcome. Surg Neurol Int 2015;6:161.
8. Carpenter JL. Brain stem abscesses: Cure with medical therapy, case report, and review. Clin Infect Dis 1994;18:219-26.
9. Chen MH, Kao HW, Cheng CA. Complete resolution of a solitary pontine abscess in a patient with dental caries. Am J Emerg Med 2013;31:892.e3-4.
10. Chow FC, Marson A, Liu C. Successful medical management of a *Nocardia farcinica* multiloculated pontine abscess. BMJ Case Rep 2013;2013:bcr2013201308.
11. Faisant C, Cochin JP, Rapoport N, Evreux F, Vaschalde Y. Cerebral trunk abscess due to *Neisseria meningitidis* in a 28-year-old immunocompetent patient. Rev Neurol (Paris) 2012;168:287-90.
12. Filho PT, Zanini MA. Brainstem abscess of undetermined origin: Microsurgical drainage and brief antibiotic therapy. Sao Paulo Med J 2014;132:121-4.
13. Fuentes S, Bouillot P, Regis J, Lena G, Choux M. Management of brain stem abscess. Br J Neurosurg 2001;15:57-62.
14. Fulgham JR, Wijdicks EF, Wright AJ. Cure of a solitary abscess with antibiotic therapy: Case report. Neurology 1996;46:1451-4.
15. Ghannane H, Laghmari M, Aniba K, Lmejjati M, Benali SA. Diagnostic and management of pediatric brain stem abscess, a case-based update. Childs Nerv Syst 2011;27:1053-62.
16. Kirchhoff DC, Kirchhoff DE, Muoio V. Abscessos do tronco cerebral: Apresentação de seis casos. Arq Bras Neurocir 2008;27:30-4.
17. Kumar MP, Krishnamurthy S, Venkateswaran VS, Mahadevan S, Lalitha M, Sistla S, et al. Brainstem micro-abscesses caused by *Burkholderia pseudomallei* in a 10-month-old infant: A case report. Paediatr Int Child Health 2017;37:230-2.
18. Outin HD, Merrer J, Molho H, Rabault N, Simon N, Nouailhat F. Solitary listerial abscess of the brain stem. Cure with antibiotic treatment. Rev Neurol (Paris) 1989;145:153-6.
19. Pandian JD, Moosa NV, Cherian PJ, Radhakrishnan K. Brainstem abscess complicating tetralogy of fallot successfully treated with antibiotics alone. Neurol India 2000;48:272-5.
20. Ramalho J, Castillo M. Case of the season: Brainstem abscess. Semin Roentgenol 2008;43:168-70.
21. Rawat D, Rajasurya V, Chakraborty RK, Sharma S, et al. Nocardiosis. Treasure Island (FL): Stat Pearls; 2020.
22. Ricard D, Sallansonnet-Froment M, Defuentes G, de Greslan T, Bounolleau P, Taillia H, et al. *Listeria monocytogenes* abscess of the brain. Rev Neurol (Paris) 2008;164:388-93.
23. Smiatcz T, Kowalik MM, Hlebowicz M. Prolonged dysphagia due to *Listeria*-rhombencephalitis with brainstem abscess and acute polyradiculoneuritis. J Infect 2006;52:e165-7.
24. Soares-Fernandes JP, Beleza P, Cerqueira JJ, Ribeiro M, Maré R, Lourenço E, et al. Simultaneous supratentorial and brainstem abscesses due to *Listeria monocytogenes*. J Neuroradiol 2008;35:173-6.
25. Stein M, Schirotzek I, Preuss M, Scharbrodt W, Oertel M. Brainstem abscess caused by *Haemophilus influenzae* and *Peptostreptococcus* species. J Clin Neurosci 2011;18:425-8.
26. Tanaka T, Sakamoto H, Kato N, Arai T, Hasegawa Y. Successful treatment of brain stem and thalamic abscesses with high-dose meropenem. Brain Nerve 2011;63:891-6.

How to cite this article: Leao CF, Couto MP, de Lima JA, Paschoal EH, Brito JR. Brainstem abscess treated conservatively. Surg Neurol Int 2020;11:205.