



## Case Report

# Spinal extradural arachnoid cyst: Rare cases from Indian Institutes

Jitender Chaturvedi<sup>1</sup>, Punit Singh<sup>1</sup>, Sunil Malagi<sup>2</sup>, Nishant Goyal<sup>1</sup>, Anil Kumar Sharma<sup>3</sup>

<sup>1</sup>Department of Neurosurgery, All India Institute of Medical Sciences, Rishikesh, Uttarakhand, <sup>2</sup>Department of Neurosurgery, SDM College of Medical Sciences and Hospital, Dharwad, Karnataka, <sup>3</sup>Department of Neurosurgery, All India Institute of Medical Science, Raipur, Chhattisgarh, India.

E-mail: \*Jitender Chaturvedi - drjittu28@gmail.com; Punit Singh - docpunit21@gmail.com; Sunil Malagi - sunil\_kims@yahoo.co.in; Nishant Goyal - drnishantgoyal@gmail.com; Anil Kumar Sharma - dr.anilsharma02@gmail.com



### \*Corresponding author:

Jitender Chaturvedi,  
Department of Neurosurgery,  
All India Institute of  
Medical Sciences, Rishikesh,  
Uttarakhand, India.

drjittu28@gmail.com

Received : 17 August 2020  
Accepted : 02 September 2020  
Published : 25 September 2020

DOI  
10.25259/SNI\_545\_2020

Quick Response Code:



## ABSTRACT

**Background:** Spinal extradural arachnoid cyst (SEDAC), accounting for approximately 1% of all spinal lesions, rarely causes compressive myelopathy. It is usually found at lower thoracic or upper lumbar levels in males in their forties to sixties. The standard surgical procedures include direct dural repair.

**Case Description:** A 37-year-old male presented with myelopathy attributed to a type I meningeal cyst (SEDAC) that was successfully managed with a laminectomy, cyst excision, and direct dural sleeve repair. Similar cases reported in the literature were also reviewed.

**Conclusion:** SEDACs, although rare, must be considered among the differential diagnoses for compressive myelopathy/neurogenic bladder.

**Keywords:** Arachnoid cyst, Compressive myelopathy, Extradural, India, Meningeal cyst, Spine

## INTRODUCTION

Spinal extradural arachnoid cyst (SEDAC) is a rare cause of compressive myelopathy, accounting for approximately 1% of all spinal lesions.<sup>[1]</sup> Pathologically, they are comprised of herniation of arachnoid through an obvious or occult dural defect. These SEDACs can be congenital or an acquired due to trauma, infection, inflammation/arachnoiditis, or iatrogenic (e.g., postsurgical: (1) decompressive laminectomy for cervical compressive myelopathy or (2) after a simple lumbar puncture).<sup>[2]</sup> These lesions tend to enlarge secondary to progressive/recurrent trapping of cerebrospinal fluid within the “cystic” cavity.<sup>[1,2]</sup> They are found most typically in the lower thoracic or upper lumbar spinal levels and are more commonly seen among males in their twenties to fifties.<sup>[7]</sup>

Here, along with a literature review, we present a 37-year-old male with a SEDAC successfully managed with a laminectomy, excision of cyst, and defective dural sleeve repair.

## CASE REPORT

A 37-year-old male presented with progressive lower extremity paraparesis of 3 years duration (motor power of 3/5 in both legs with a 0/5 left foot drop for 1 year). There were no history

This is an open-access article distributed under the terms of the Creative Commons Attribution-Non Commercial-Share Alike 4.0 License, which allows others to remix, tweak, and build upon the work non-commercially, as long as the author is credited and the new creations are licensed under the identical terms.

©2020 Published by Scientific Scholar on behalf of Surgical Neurology International

of back pain, significant trauma, spinal surgery/lumbar puncture, or tuberculosis.

The thoracic MR showed, on axial cuts, an arachnoid cyst with lateral extension into both neural foramina between the T12-L1 levels; no further lesions were noted on the cervical or lumbar MR studies.

### Surgery

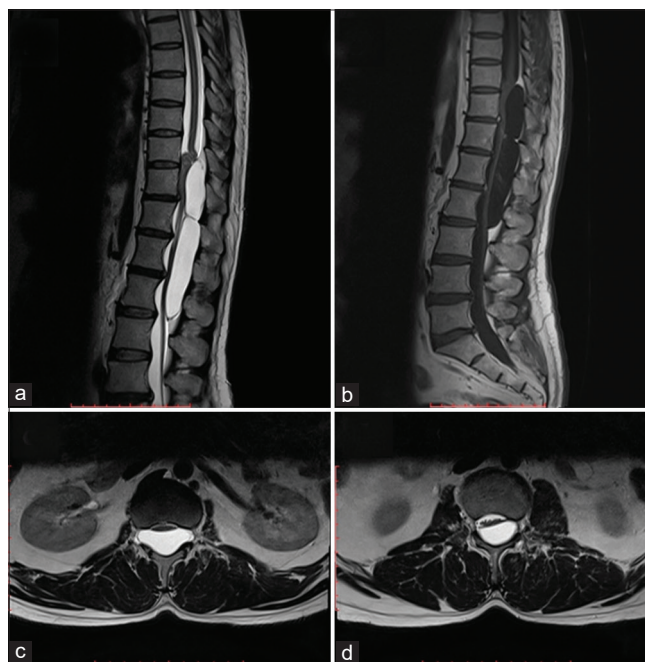
The patient underwent L1 preserving laminectomies from T11 to L2 [Figures 1-3], revealing a distended cyst. Thinning of the dura with arachnoid herniation was observed involving both T12-L1 neural foramina (e.g., especially on the right). The dural defect was directly repaired using a nonabsorbable monofilament suture made of expanded polytetrafluoroethylene (GORE-TEX) plus application of a small muscle patch graft. The wound was then routinely repaired in layers, with a drain placed in the epidural space.

### Pathology

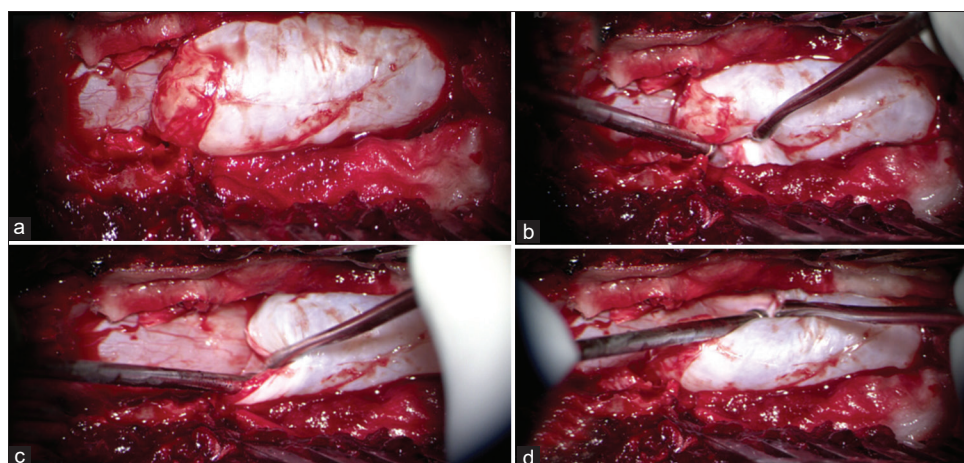
The histopathological examination revealed collagenous tissue within the wall of the cyst with occasional cuboidal and flattened cells, suggestive of a meningothelial reaction.

### Postoperative course

Immediately after surgery, the patient had dramatic relief in his symptoms. The follow-up MRI 3 months later confirmed complete excision of cyst and thecal sac decompression. By 9 postoperative months, the patient was completely asymptomatic.



**Figure 1:** (a) T2-W MRI sagittal images disclose a well-defined uniformly hyperintense (identical to CSF) cystic multiseptate lesion extending from the lower end of the T10 vertebral body to the lower end of L2 vertebral body. The bulk of the lesion is seen to create a mass effect and compression over the cauda equina. (b) T1-W MRI sagittal images after contrast injection reveal a well-defined uniform hypointense multiseptate lesion with no evidence of enhancement within the substance or peripheral wall of the lesion. (c and d) T2-W MRI axial images, at the level of T12 and L2, disclose well-defined uniform hyperintense lesion with compression and displacement of conus as well as caudal roots at respective levels. The lesion is seen to be extended into intervertebral foramen at the level of T12.



**Figure 2:** (a) Intraoperative picture (under microscope) after T11-L2 laminectomy. Upper pole of large cystic lesion noted hanging over the underlying intact dura, while the inferior end is extending under L1 lamina which was preserved in tailored exposure. (b) Distended cyst wall is seen extending into the left neural foramina between T12 and L1 vertebral level. (c) Distinguished plane between cyst wall and native dura is clearly seen under the cranial pole of the cyst. (d) Distended cyst wall is seen extending into right neural foramina between T12 and L1 vertebral level.

Table 1: Summary of spinal extradural arachnoid cyst cases reported from India.

Author	Centre	Year	Number (n) of cases	Age and gender	Vertebral level	Special notes
Present case Singh <i>et al.</i>	AIIMS, Rishikesh SGPGIMS, Lucknow	2020	1	45 M	D10-L2	No recurrence at 9-month follow-up after surgery
		2019	13	Eight males and five females with 15-60 years of age range	All thoracic or lumbar or thoracolumbar but none was cervical or sacral	No recurrence in any case
Daflani <i>et al.</i>	Sri Sathya Sai Institute of Higher Medical Sciences, Bengaluru	2018	1	42 M	D3-D5	Recurrence noted on the 3 <sup>rd</sup> postoperative day with recollection of extradural fluid which necessitated reexploration
Satyarthee	AIIMS, New Delhi	2018	1	5 M	S1-S4	Presentation as neurogenic bladder No recurrence after surgical excision
Mishra <i>et al.</i>	NIMHANS, Bengaluru	2017	1	25 F	D10-S1	Emphasized role of dynamic MRI in preoperative evaluation, helps reestablishing communication theory/passive fluid dynamic theory for development of SEDAC No recurrence after intervention
Nayak <i>et al.</i>	Bangur Institute of Neurosciences, Kolkata	2017	1	7 F	D1-D7	No recurrence
Garg <i>et al.</i>	AIIMS, New Delhi	2017	11	Median age 32.9±20.8 years (M:F=8:3)	Thoracolumbar	No recurrences in any case Operative complications were noted in two of their patients. One patient was noted to have worsening of lower limb power immediately after surgery, which recovered over a period of next 3 days. He was discharged with power same as preoperative level Another patient, in whom fat graft was used to augment dural closure, did not improve following surgery. MRI revealed compression of the cord by the fat graft and required removal of the graft, following which he improved No recurrence
Phadke <i>et al.</i>	SGPGIMS, Lucknow	2016	1	45 F	L4-sacrum	No recurrence
Nath <i>et al.</i>	SCB Medical College, Cuttack, Odisha	2016	1	45 M	C6-D1 intradural extramedullary anterior arachnoid cyst	A history of C6-T1 laminectomy 28 years back at age of 17 years. Primary pathology was C6-7/C7-T1 Disc prolapse leading to compressive myelopathy No recurrence after reexploration through posterior midline and excision of cyst at age of 45 years No recurrence
Panigrahi <i>et al.</i>	S.C.B. Medical College and Hospital, Cuttack	2012	1	15 M	D8-L1	No recurrence

(Contd...)

Table 1: (Continued).

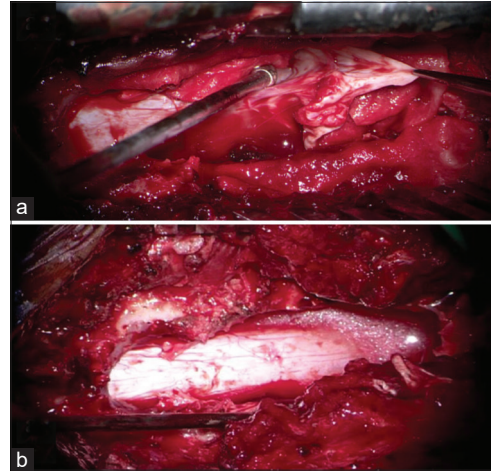
Author	Centre	Year	Number (n) of cases	Age and gender	Vertebral level	Special notes
Muthukumar et al.	Madurai Medical College, Madurai	2012	1	New born girl	Cervicothoracic, communication at C7 root sleeve	Presentation masquerading as obstetric brachial plexus palsy No recurrence following excision at 7 months of age after an initial expectant management
Thakar et al.	Sri Sathya Sai Institute of Higher Medical Sciences, Bengaluru	2011	1	15 M	S2-S4 with holocord nonenhancing syrinx	1 <sup>st</sup> report of a sacral SEDAC leading to holocord syrinx formation No recurrence, complete resolution of clinical symptoms as well as holocord syrinx after surgery
Kumar et al.	Institute of Medical Sciences, Banaras Hindu University, Varanasi	2011	31	16 females and 15 males 0-15 years=2 15-30 years=11 30-45 years=13 45-60 years=3 >60 years=2	2 sacral, 4 cervical, 10 thoracic, 3 lumbar, rest all were mixed cervicodorsal or thoracolumbar	2 patients develop pseudomeningoceles in postoperative period that necessitated reexploration One different patient had no improvement compared to preoperative power, while 2 other patients suffered surgical site infections No recurrences at 4-year long follow-up
Srinivas et al.	Christian Medical College, Vellore	2010	1	9-month-old boy	Thoracolumbar multiple spinal extradural cysts. Largest one was at right L2 root with significant extraspinal extension resulting in a visible large swelling in the right paraspinous region and radiological evidence of compression of the right kidney with hydronephrosis	No recurrence after excision The patient had phenotypic features of Noonan syndrome and authors claimed this case as the youngest patient reported in literature (at time of this publication) to have a spinal extradural cyst and also the first patient in whom the cyst had presented as a paraspinous mass
Rashid et al.	Jawaharlal Nehru Medical College Hospital, AMU, Aligarh	2008	1	Not available	Thoracolumbar	No recurrence
Dev et al.	King George Medical University, Lucknow	2008	1	9 M	T7-L1	No recurrence after cystothesostomy through L1 Laminectomy under LA, minimally invasive procedure (according to authors) to save the child from long segment laminectomy or laminoplasty
Jena et al.	Institute of Nuclear Medicine and Allied Sciences, Delhi	1990	2	11 M 17 M	T4-L1 (extradural) C7-T1 (intradural)	Novel imaging features of SEDAC in MRI were discussed Surgical details or follow-up not available
Mathew et al.	Not available	1970	Not available	Not available	Not available	Not available

(Contd...)



Table 1: (Continued).

Author	Centre	Year	Number (n) of cases	Age and gender	Vertebral level	Special notes
Dastur	K.E.M. Hospital, Parel, Bombay	1963	3	15 M 40 M 32 M	D7 and D10 D11-D12 D6-D10	No recurrence No recurrence First reported case from independent India. In 1948, at age of 19 years, this patient was first operated (laminectomy and excision of multiple extradural arachnoid cysts) under Dr. R N Cooper; after which he achieved full recovery in postoperative period. Although reexplorations were needed twice in coming years. First one in 1950 (at age 21 years) and second in 1953 (at age 24 years). Author had to finally reexplore for recurring symptoms in 1961 for the 4 <sup>th</sup> time (at age of 32 years). Myelograms were used for preoperative diagnosis. After many months of surgery and following prolonged physiotherapy, he was discharged with ability to use harness and crutches



**Figure 3:** (a) Intraoperative picture after fenestration and decompression of the cyst, the collapsed wall is seen extending into neural foramina between T12 and L1 vertebral level, where the dural defect was identified and repaired using 4-0 Prolene with muscle patch and fibrin glue. (b) After complete excision of cyst, dura is noted to be adequately decompressed (no evidence of CSF leak on Valsalva maneuver subsequently).

## DISCUSSION

### Nabors three part classification of spinal arachnoid cysts

According to Nabors classification,<sup>[3]</sup> spinal arachnoid cysts are of three types. Extradural cysts (SEDAC); without and with involvement of nerve root are Type I and Type II cysts, respectively. All intradural cysts are Type III cysts.

Clinical manifestations of SEDAC are usually myelopathy, radiculopathy, or neurogenic bladder. SEDAC can either be congenital in etiology or sporadic. The former is caused by mutations in the FOXC2 gene and is inherited as a part of lymphedema–distichiasis syndrome.

Various surgical strategies have been described ranging from complete microsurgical resection to simple fenestration followed by closure of dural defect.<sup>[1,2,5]</sup> Lee *et al.* demonstrated that recurrence of the cyst was dependent on the extent/adequacy of dural closure and not on the completeness of surgical excision.<sup>[5]</sup> Dural defects are usually found around nerve root sleeves, possibly due to tension across the movable dural sac and relatively fixed nerve roots. As laminectomy increases the risk of future kyphotic deformity, some surgeons advocate a tailored laminectomy with cyst fenestration allowing for dural defect repair rather than attempting complete cyst resection and increasing the risk of instability.<sup>[4]</sup>

### Review of seventy prior SEDAC cases

A total of seventy SEDAC cases have been reported, including 42 males and 28 females.<sup>[1-7]</sup> The predominant postoperative complication remains cyst recurrence [Table 1].

## CONCLUSION

Type 1 meningeal cysts can cause compressive myelopathy in the thoracolumbar region. Here, it was successfully managed with laminectomy, cyst excision, and direct repair of the dural defect.

## Declaration of patient consent

Patient's consent not required as patients identity is not disclosed or compromised.

## Financial support and sponsorship

Nil.

## Conflicts of interest

There are no conflicts of interest.

## REFERENCES

1. Funao H, Nakamura M, Hosogane N, Watanabe K, Tsuji T, Ishii K, *et al.* Surgical treatment of spinal extradural arachnoid cysts in the thoracolumbar spine. *Neurosurgery* 2012;71:278-84.
2. Furtado SV, Thakar S, Murthy GK, Dadlani R, Hegde AS. Management of complex giant spinal arachnoid cysts presenting with myelopathy. *J Neurosurg Spine* 2011;15:107-12.
3. Garg K, Borkar SA, Kale SS, Sharma BS. Spinal arachnoid cysts-our experience and review of literature. *Br J Neurosurg* 2017;31:172-8.
4. Kumar A, Sakia R, Singh K, Sharma V. Spinal arachnoid cyst. *J Clin Neurosci* 2011;18:1189-92.
5. Lee CH, Hyun SJ, Kim KJ, Jahng TA, Kim HJ. What is a reasonable surgical procedure for spinal extradural arachnoid cysts: Is cyst removal mandatory? Eight consecutive cases and a review of the literature. *Acta Neurochir (Wien)* 2012;154:1219-27.
6. Nayak R, Chaudhuri A, Sadique S, Attry S. Multiple spinal extradural arachnoid cysts: An uncommon cause of thoracic cord compression. *Asian J Neurosurg* 2017;12:321-3.
7. Netra R, Min L, Hui MS, Wang JC, Bin Y, Ming Z. Spinal extradural meningeal cysts: An MRI evaluation of a case series and literature review. *J Spinal Disord Tech* 2011;24:132-6.

**How to cite this article:** Chaturvedi J, Singh P, Malagi S, Goyal N, Sharma AK. Spinal extradural arachnoid cyst: Rare cases from Indian Institutes. *Surg Neurol Int* 2020;11:306.