



## Case Report

# Acute handlebar syndrome: Two extremes of a challenging diagnosis

Fabio Veiga de Castro Sparapani<sup>1</sup>, Marcela Fernandes<sup>2</sup>, Leonardo Favi Bocca<sup>1</sup>, Luis Renato Nakachima<sup>2</sup>, Sergio Cavalheiro<sup>1</sup>

<sup>1</sup>Department of Neurology and Neurosurgery, Universidade Federal de São Paulo, Rua Napoleão de Barros, 720, 6<sup>th</sup> floor, Sao Paulo, Brazil, <sup>2</sup>Department of Orthopedics and Traumatology, Universidade Federal de São Paulo, Rua Napoleão de Barros, 720, 1<sup>st</sup> floor, Sao Paulo, Brazil.

E-mail: Fabio Veiga de Castro Sparapani - fspara@yahoo.com.br; Marcela Fernandes - marcelafernandes@me.com; Leonardo Favi Bocca - leobocca5@gmail.com; \*Luis Renato Nakachima - lrnaka@uol.com.br; Sergio Cavalheiro - sergiocavalheironeuro@gmail.com



### \*Corresponding author:

Leonardo Favi Bocca,  
Department of Neurology and  
Neurosurgery, Universidade  
Federal de São Paulo, Rua  
Napoleão de Barros, 720,  
6<sup>th</sup> floor, Sao Paulo, Brazil.

leobocca5@gmail.com

Received : 04 September 2020

Accepted : 30 September 2020

Published : 29 October 2020

### DOI

10.25259/SNI\_606\_2020

### Quick Response Code:



## ABSTRACT

**Background:** Ulnar nerve mononeuropathy diagnosis can be challenging depending on where neural lesion is present. Repetitive trauma during cycling is a rare cause of ulnar neuropathy.

**Case Description:** We describe two patients who developed the handlebar syndrome, an ulnar nerve palsy at Guyon's canal after cycling. The first patient had the syndrome after a short-distance ride and she was treated surgically, while the second patient developed the classical syndrome after a long ride and received conservative treatment. Surgical treatment of the first patient led to functional recovery.

**Conclusion:** Handlebar syndrome is a neuropathy caused by extrinsic repetitive compression of ulnar nerve at wrist. Increasing incidence of this disease can be expected after increasing popularity of cycling sports. Avoid of repetitive trauma is the main management goal, with surgical treatment reserved for failure of conservative treatment.

**Keywords:** Cycling, Guyon's canal, Nerve compression syndrome, Ulnar neuropathy

## INTRODUCTION

The diagnosis of the ulnar nerve lesion at Guyon's canal could be challenging. The characteristic sensory loss at the ulnar portion of the hand and weakness of all ulnar intrinsic hand muscles occurs when both the superficial and deep branches are affected.<sup>[7,10]</sup>

When only the terminal superficial or deep branches are affected, both due to intrinsic or extrinsic causes, uncommon clinical features could be seen. These unusual clinical presentations can be difficult to be interpreted by nonspecialists. Misdiagnosis can lead to equivocal treatment, delaying or preclude nerve recovery.

## CASE DESCRIPTION

### Case 1

A 55-year-old female presented to our outpatient facility complaining about 4 weeks history of weakness and clumsiness of the left hand without pain or sensory loss. She spontaneously denied

This is an open-access article distributed under the terms of the Creative Commons Attribution-Non Commercial-Share Alike 4.0 License, which allows others to remix, tweak, and build upon the work non-commercially, as long as the author is credited and the new creations are licensed under the identical terms.

©2020 Published by Scientific Scholar on behalf of Surgical Neurology International

any unusual situation but, after a thorough anamnesis, she remembered some light exercises, including a short bike ride on a weekend trip. Her medical records are unremarkable. Physical examination showed marked weakness and atrophy of all ulnar supplied intrinsic left hand muscles, except for the hypothenar muscles [Figure 1]. No cutaneous sensory deficit and nerve tenderness (Tinel's sign) over Guyon's canal were present.

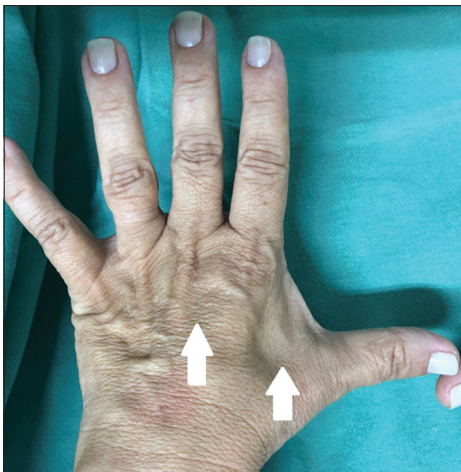Before our evaluation, magnetic resonance imaging (MRI) of the cervical spine was performed showing no cervical myelopathy or compression of cervical roots and an electroneurography (ENMG), done just after initial symptoms, showed an unspecific axonal multineuropathy without motor conduction block. With these examinations, a suspected diagnosis of amyotrophic lateral sclerosis was performed by general physician and patient was sent to our institution. After our evaluation, a forelimb MRI was performed and no nerve compression was observed. The patient was submitted to another ENMG that confirmed ulnar neuropathy.

A surgical exploration was indicated after clinical complementary evaluation confirmed ulnar neuropathy. The procedure revealed a mild compression of the deep ulnar branch under the origin of the flexor digiti quinti brevis and opponens digiti quinti muscles [Figure 2].

During the outpatient follow-up, the patient had an uneventful recovery with motor and sensory improvement.

## Case 2

A 45-year-old female complained about weakness of the left hand with local pain and sensory loss in the IV, V fingers and hypothenar volar region in the 4<sup>th</sup> day of a 500 km road cycling amateur competition. After the end



**Figure 1:** Dorsal view of left hand. Note interosseous muscles atrophy, specially seen between I and II metacarpal bones (white arrow).

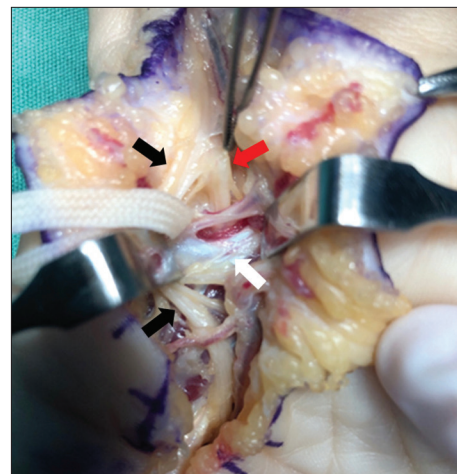
of the competition, the pain has gone but the rest of the symptoms remained. The patient presented to our outpatient facility 3 weeks after the end of cycling event. Her medical records were unremarkable.

Physical examination revealed mild weakness (Grade IV) and atrophy of all ulnar supplied intrinsic left hand muscles, including the hypothenar muscles, and hypoesthesia in the V finger [Figure 3]. The nerve tenderness (Tinel's sign) over Guyon's canal was not present.

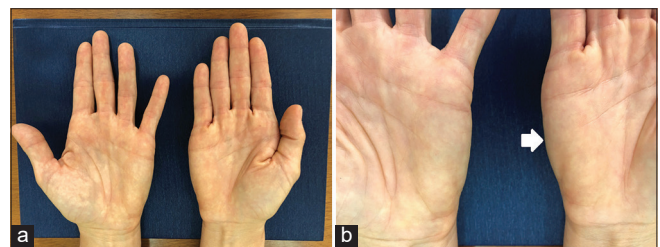
A forearm and wrist MRI were requested and she denied being submitted an electroneurography. The MRI did not reveal any anomalies except the amyotrophy related. A conservative treatment was done with a good recovery.

## DISCUSSION

The handlebar is one of the three contact areas that support the cyclist, beyond pedals, and the seat. Continuous and hyperextended position of the hand could compress and stretch both ulnar and median nerves at the wrist.<sup>[4]</sup>



**Figure 2:** Surgical view showing the pisohamate hiatus. The fibrous arch (white arrow) must be divided to release the deep branch of ulnar nerve (red arrow) passing posterior to the fibrous arch and the superficial branch of ulnar nerve (black arrow) passing anterior to the arch.



**Figure 3:** Physical examination of hands. (a) Ventral view of hands, atrophy of ulnar innervated intrinsic hand muscles. (b) Close aspect of hypothenar region. Note left hypothenar region atrophy (white arrow).

The Guyon's canal lesions are usually divided into four places with distinct clinical aspects. Cavallo *et al.* proposed a clinical classification to distal ulnar neuropathy that can be easily applied to clinical practice.<sup>[3]</sup> The most common is the lesion proximal to the Guyon's canal (Type 1) characterized by sensory loss at the ulnar portion of the hand and weakness of all ulnar intrinsic hand muscles, last alteration being the most seen clinical aspect of it. More distal lesions inside the Guyon's canal (Type 2) cause an isolated palsy of the deep terminal motor branch without sensory loss. This lesion could be differentiated from Type 3 because the latter spares the hypothenar muscles. Type 4 affects the superficial branch only leading to sensory loss.<sup>[3]</sup>

The most reported etiologies of these lesions are the compressive in nature: lipoma, cysts, anomalies of ligaments or muscles, hook of the hamate fracture, and ulnar artery aneurysms. Extrinsic causes, such as chronic repetitive trauma or chronic pressure together with vibration, are not commonly reported, except if applied for months or years.<sup>[8]</sup> The most common sports associated with injuries of the ulnar nerve at the wrist is cycling.<sup>[9]</sup> Weightlift, rowing, gymnastics, and table tennis are more related to lesions of ulnar nerve at the elbow.<sup>[9]</sup> Wheelchair sports could affect both sites.<sup>[9]</sup>

The prevalence of ulnar and median nerve compression in long-distance cyclists ranges from 10% to 70%<sup>[5]</sup> with its characteristics motor or sensory disturbances. When no sensory involvement or pain is triggered by the sport, the cyclist can prolongate the activity without any change in the hand's position, leading to lesion progression.

When history is unclear and the clinical findings are not specific, further diagnostic workups are needed. ENMG and an MRI of the hand should be performed for the exclusion of pathological structures at Guyon's canal. Important differential diagnosis should be discarded, including radiculopathy of C8 and/or T1 roots. In pure motor syndromes, amyotrophic lateral sclerosis, multifocal motor neuropathy, and hereditary neuropathy with liability to pressure palsy (HNPP) should be ruled out.<sup>[2]</sup>

In our first case, the initial diagnosis caused intense stress and great suffering to the patient and her family. Her short history of cycling was an unusual cause of distal ulnar neuropathy, usually related to long-distance and repetitive cycling. Since the first report by Simpson<sup>[7]</sup> in 1895, literature reports describe cases of long-distance or prolonged cycling as possible extrinsic etiology for ulnar neuropathy. Few reports of ulnar neuropathy following short-distance cycling can be found, as Capitani and Beer<sup>[1]</sup> described in 2002, three cases of handlebar syndrome, one case of them was an unexperienced mountain biker that developed ulnar neuropathy after only one downhill mountain bike trip. Authors theorized the rider posture, leaning too forward and an inadequate frame or handlebar

grip as facilitating factors to rapid developing symptoms presented in that patient.

Although handlebar syndrome tends to recover with conservative management, it has to be early diagnosed to avoid a worsening of the case, as presented by the second patient. There is a lack of evidence-based recommendations on literature regarding handlebar syndrome treatment.<sup>[1]</sup> Most authors use Delphi consensus strategy recommendations derived from European HANDGUIDE study to guide their treatment. For mild-to-moderate symptoms, recommendations start with avoidance of local pressure and/or limit mechanical overload including repetitive or static movements of the wrist and splinting the wrist in a neutral position in a fingers free splint for 1–12 weeks at night.<sup>[6]</sup> Surgery is reserved to patients with chronic symptoms or a severe presentation and consists of ulnar nerve exploration in the canal.<sup>[6]</sup>

## CONCLUSION

Handlebar syndrome is a distal ulnar neuropathy cause by extrinsic repetitive compression of ulnar nerve at wrist. Its differential diagnosis can be challenging and must be ruled out before definitive diagnosis.

The incidence of handlebar syndrome should increase more and more with the increasing popularity of cycling sports, including mountain bike or long-distance cycling, so clinicians must be aware of this diagnosis. Surgical treatment is reserved to conservative management failure or anatomical anomaly found after imaging evaluation.

## Declaration of patient consent

The authors certify that they have obtained all appropriate patient consent.

## Financial support and sponsorship

Nil.

## Conflicts of interest

There are no conflicts of interest.

## REFERENCES

1. Brown CK, Stainsby B, Sovak G. Guyon canal syndrome: Lack of management in a case of unresolved handlebar palsy. *J Can Chiropr Assoc* 2014;58:413-20.
2. Capitani D, Beer S. Handlebar palsy-a compression syndrome of the deep terminal (motor) branch of the ulnar nerve in biking. *J Neurol* 2002;249:1441-5.
3. Cavallo M, Poppi M, Martinelli P, Gaist G. Distal ulnar neuropathy from carpal ganglia: A clinical and

- electrophysiological study. *Neurosurgery* 1988;22:902-5.
4. Cohen GC. Cycling injuries. *Can Fam Physician* 1993;39:628-32.
  5. Dettori NJ, Norvell DC. Non-traumatic bicycle injuries: A review of the literature. *Sports Med* 2006;36:7-18.
  6. Hoogvliet P, Coert JH, Fridén J, Huisstede BM. How to treat guyon's canal syndrome? Results from the European handguide study: A multidisciplinary treatment guideline. *Br J Sports Med* 2013;47:1063-70.
  7. Neal S. Peripheral nerve injury of the upper extremity. In: Shane-Tubbs R, editor. *Nerves and Nerve Injuries*. London: Elsevier Ltd.; 2015. p. 510-2.
  8. Shea JD, McClain EJ. Ulnar-nerve compression syndromes at and below the wrist. *J Bone Joint Surg Am* 1969;51:1095-103.
  9. Sparapani F, Spinner R. Peripheral nerve injuries in athletes. In: Petraglia AL, Bailes JE, Day AL, editors. *Handbook of Neurological Sports Medicine: Concussion and Other Nervous System Injuries in the Athlete*. Champaign, United States: Human Kinetics; 2015. p. 341-5.
  10. Streib EW, Sun SF, Cochran RM, Leibrock LG. Distal ulnar neuropathy. Clinical and electrophysiologic aspects. *Surg Neurol* 1985;23:281-6.

**How to cite this article:** de Castro Sparapani FV, Fernandes M, Bocca LF, Nakachima LR, Cavalheiro S. Acute handlebar syndrome: Two extremes of a challenging diagnosis. *Surg Neurol Int* 2020;11:366.