



Review Article

## Nonmissile penetrating spinal injuries: Mechanisms, expectations, and management

Brian Fiani<sup>1</sup>, Ryan Arthur Figueras<sup>2</sup>, Frank De Stefano<sup>3</sup>, Neha Gautam<sup>4</sup>, Asif Khan<sup>5</sup>, Marisol Soula<sup>6</sup>

<sup>1</sup>Department of Neurosurgery, Desert Regional Medical Center, Palm Springs, California, <sup>2</sup>School of Medicine, University of California Riverside, Riverside, California, <sup>3</sup>College of Osteopathic Medicine, Kansas City University of Medicine and Biosciences, Kansas City, Missouri, <sup>4</sup>Department of Medical Research, University of California Davis, Davis, California, <sup>5</sup>Department of Podiatry, Beaumont Hospital, Farmington Hills, Michigan, <sup>6</sup>Grossman School of Medicine, New York University, New York, United States.

E-mail: \*Brian Fiani - bfiani@outlook.com; Ryan Arthur Figueras - ryanarthur.figueras@medsch.ucr.edu; Frank De Stefano - destefanofranka@gmail.com; Neha Gautam - ngautam@ucdavis.edu; Asif Khan - asif.khan@beaumont.org; Marisol Soula - marisol.soula@nyulangone.org



**\*Corresponding author:**

Brian Fiani, D.O.

Department of Neurosurgery,  
Desert Regional Medical  
Center, Palm Springs,  
California, United States.

bfiani@outlook.com

Received : 31 August 2020

Accepted : 02 November 2020

Published : 25 November 2020

**DOI**

10.25259/SNI\_596\_2020

**Quick Response Code:**



### ABSTRACT

**Background:** Nonmissile penetrating spinal injury (NMPSI) is an uncommon form of traumatic injury to the spine. Here, we present a comprehensive and contemporary literature review that provides insight into NMPSI-type injuries, their mechanisms, clinical practice, management, and expectations.

**Methods:** An extensive review of the published literature was conducted in PubMed, OVID Medline, and EMBASE journals for studies of nonmissile penetrating spine injuries. Terms for search included NMPSI and nonmissile penetrating spinal cord injury. No date restrictions were used.

**Results:** The search yielded only 17 related articles. Cross-checking of articles was conducted to exclude duplicate articles. The 17 articles were screened for their full text and English language availability. We finalized those articles pertaining to the topic.

**Conclusion:** The mechanism of injury in NMPSI occurs in two different stages. Immediate injury is caused by direct damage to the neurological structures. The delayed injury response is caused by damage to the spinal vasculature and activated immune response pathways. Computed tomography (CT) angiograms or formal diagnostic angiograms are indicated to identify vascular injury or development of pseudoaneurysm and can be performed both preoperatively and postoperatively. Surgically, decompressive procedures include laminectomies and hemilaminectomies. Dural exploration may be indicated if a cerebrospinal fluid leak with fistula develops from dural puncture. Further research and technologies are being developed to provide patients who have suffered NMPSI with more resources for a better quality of life.

**Keywords:** Neurotrauma, Nonmissile penetrating spinal injury, Nonmissile, Penetrating spinal injury

### INTRODUCTION

Nonmissile penetrating spinal injury (NMPSI) is an uncommon form of traumatic injury to the spine, particularly rare in North America.<sup>[15]</sup> Large trauma centers only see a few cases each year.<sup>[20]</sup> Foreign institutions report that out of all spinal injuries that presented in the past 10 years, only 7% were classified as NMPSIs.<sup>[25]</sup> In Western populations, this type of injury accounts for only 0.3%–2.1% of spinal injuries.<sup>[32]</sup> Although there are several case studies published, the low

This is an open-access article distributed under the terms of the Creative Commons Attribution-Non Commercial-Share Alike 4.0 License, which allows others to remix, tweak, and build upon the work non-commercially, as long as the author is credited and the new creations are licensed under the identical terms.

©2020 Published by Scientific Scholar on behalf of Surgical Neurology International

incidence has led to uncertainty in the approach used to best manage NMPSIs and doubt as to whether further studies are necessary.

The vast majority of spinal injuries in North America are due to either motor vehicle accidents or falls.<sup>[15]</sup> A large portion of spinal injuries is also due to missile forces, such as gunshot wounds.<sup>[15]</sup> When NMPSIs occur, they rarely affect the structural stability of the spine.<sup>[20]</sup> The stability of the spine is maintained by the bony spinal column, intervertebral discs, and attaching ligaments which are rarely disrupted in these types of injuries. The victims of these injuries are usually males in their 2<sup>nd</sup> and 3<sup>rd</sup> decade of life and the penetrating object typically enters the dorsal cervical and upper thoracic spine.<sup>[15,25]</sup> Management can be complicated when there is a retained foreign body, such as a knife secondary to a stab wound, as this may lead to neurological compromise. A small case series reports that surgical intervention for decompression or removal of foreign body has led to improved neurological function in 7 out of 9 cases.<sup>[20]</sup> Although conservative treatment has been reported to be linked to a high mortality rate and complications such as cerebrospinal fluid (CSF) fistulas and septicemia, surgical versus conservative treatment has been a contentious debate in the literature.<sup>[20,32]</sup> Our objective is to perform an extensive contemporary review of literature regarding NMPSI including the mechanisms, clinical practices, as well as the management and expectations associated with these injuries.

## MECHANISM OF INJURY

Penetrating wounds occur when an object pierces the body in a traumatic fashion that can destroy, disrupt, or contuse the tissue it penetrates and adjacent areas.<sup>[11]</sup> Penetrating injuries have a myriad of etiologies, the most common cause being gunshot wounds (GSWs), which is a form of missile penetrating injury, followed by sharp instruments such as knives (nonmissile).<sup>[11]</sup> The type of material comprising the penetrating object, the movement or trajectory of the object, and the anatomy of the patient are all factors which heavily influence the specific way in which tissue damage occurs.<sup>[11]</sup> The degree of injury is partly determined by the biomechanics of the penetrating object which includes the energy transfer efficiency from the object to the body tissues on contact.<sup>[9]</sup> The physics of the object entry such as velocity, area of impact, ability for object's material to deform on contact, as well as the density of the particular damaged tissues play a significant role in the severity of injury.<sup>[9]</sup> Regarding velocity, mechanisms of penetrating injuries can be broadly divided into low-, medium-, and high-grade velocity.

Injuries involving knives usually produce limited injury because knives are classified as low-velocity projectiles. Such low-velocity projectiles will typically cause damage confined

to tissues solely within the path of the penetrating object. In contrast, bullet wounds caused by air-powered pellet guns and handguns are classified as medium velocity. These medium-velocity wounds are distinct from low-velocity types in that they cause cavitation of the tissues and extend the area of tissue damage beyond the path of the penetrating object through shock waves.<sup>[9]</sup> In addition, medium-velocity projectile wounds are distinct from high-velocity projectile wounds in that they have far less primary tissue destruction. Finally, high-velocity injuries are caused by bullet wounds from rifle discharge and military weapons.<sup>[9]</sup>

Concerning penetrating trauma wounds, the physics of the energy exchange impacts the degree of tissue damage.<sup>[2]</sup> The kinetic energy (KE) equation  $KE = (1/2) (\text{Mass [M]}) (\text{Velocity [V]}^2)$  describes the transfer of energy due to the motion of the object. As evident from this equation, if two penetrating objects with identical mass are in motion, an object going twice the speed will have  $\times 4$  the KE. Because KE increases with the square of velocity, a smaller bullet traveling at faster speeds can cause greater damage than a larger but slower bullet to a certain extent. Basic knowledge of weapon size, shape, anatomical entry site, and velocity can aid clinicians in estimating the potential for injury.<sup>[2]</sup>

The most commonly occurring NMPSIs are stab wounds of the back directed toward the thoracic spine (up to 63% of cases), the cervical spine (up to 30% of cases), or the lumbar region (6.7% of cases).<sup>[4,14]</sup> Within the thoracic and cervical spine regions, the neurological injury which ensues occurs through one of two mechanisms. The first is an immediate mechanism as a result of direct damage to neurological structures, and the second is a delayed mechanism which is caused by inflammatory pathways causing tissue damage internally or externally from injury to vasculature supply to the spinal cord. The artery of Adamkiewicz and the aorta are the most commonly injured vascular structures from NMPSI.<sup>[8]</sup> The first mechanism most typically causes incomplete spinal cord injury (SCI), typically Brown-Sequard syndrome. On the other hand, the delayed mechanism will typically cause complete SCI.<sup>[8]</sup> In some cases, the penetrating object may also cause anatomical hemisection of the spinal cord. Another possible outcome is if the object's trajectory collides with the bony elements of the spine, in which case the object is deflected away from midline, greatly reducing the chances of complete SCI. Mechanistically, from a bony injury standpoint, laminar fractures have also been observed when the penetrating object was of ample size and mass.<sup>[13,25]</sup>

## NEUROLOGICAL SEQUELAE

Because NMPSI represents such a small subset of overall spinal injury, guidelines for the management of these patients and the resulting neurological sequelae are elusive. The possible outcomes and neurological deficits observed in

patients are vast, ranging from asymptomatic dural tear to injuries of the nerve root, and patients have been observed to experience symptoms from neurapraxia to neurotmesis, with complete SCI being the most detrimental outcome from NMPSI.

Historically, the neurological sequelae for patients with sustained NMPSI are optimistic. According to a 1991 institutional study, a good prognosis has been reported in 50–60% of NMPSI cases, with surgical intervention demonstrating improved neurological function in 7 out of 9 cases.<sup>[26]</sup> In most cases of NMPSI, decompressive procedures such as laminectomies, hemilaminectomies, and dural exploration are the procedures of choice to improve patient outcomes in injuries sustained to the back.<sup>[8,26]</sup> However, it is generally advised that patients be evaluated on a case-by-case basis due to lack of clinical guidelines on treatment.

The previous studies have shown that 40% of patients with partial spinal cord injuries were able to recover to functional capacity and able to return to previous places of employment, and an additional 57% demonstrated significant recovery, which is defined by the recovery of their physical capacity which allowed them to be gainfully employed.<sup>[13]</sup> When considering the physical capabilities of patients who have sustained NMPSI, Peacock *et al.* reported that 66% of patients recovered to the extent of walking unassisted or with minimal assistance.<sup>[17]</sup> Finally, a Texas SCI study found that chances for significant neurologic recovery among several classes of trauma patients found NMPSI patients to demonstrate the highest chances for significant recovery at 61%, which was greater than motor vehicle accident patients at 44% and GSW patients at 32%,<sup>[21]</sup> indicating that the neurological sequelae of NMPSI fare better overall when compared to other comparable spinal injury.

## INDICATIONS FOR ANGIOGRAM

For patients that present with NMPSI, an initial and immediate concern should be the integrity of the vasculature in the spinal region, especially the vertebral arteries. CT angiography has been proven to be a fast, safe, and reliable noninvasive method to assess patients with penetrating neck traumas. It has a specificity of about 100% and sensitivity of 90% for identifying lesions of vascular structures in the neck region.<sup>[16,24]</sup> CT is also a highly useful tool for providing details on the location, extent, and the trajectory of vascular injury and for potential aerodigestive injury. Such details are invaluable for planning the management of the patient's condition.<sup>[23]</sup> A CT scan is critical to delineate the bony structures of the vertebrae that are sometimes fractured and so it is typically performed before any surgical intervention. If the patient's routine preoperative CT shows that the patient sustained damage or bone fractures adjacent to the vertebral arteries or the aorta, CT angiography or conventional

angiography is indicated.<sup>[29]</sup> Most clinician protocols will dictate that a CT angiography be performed to rule out vascular injury in penetrating spinal injuries because CT angiography has been proven to effectively identify injury to the carotid arteries and vertebral arteries.<sup>[5]</sup> Therefore, in cases where there is damage in proximity to the vertebral arteries and the aorta, CT angiography or conventional angiography is indicated, with CT angiography being preferred initially in the trauma setting due to it being a faster diagnostic test.<sup>[5]</sup> Formal diagnostic angiograms can be performed afterward for therapeutic purposes or for a better image quality if there are questionable findings from the CT angiogram.

Because vascular injuries related to NMPSI are most common in the cervical spine as opposed to thoracic or lumbar spine (comprising up to 40% of penetrating neck traumas), clinicians should observe the patient for signs that are suggestive of vascular injury.<sup>[1]</sup> Concerning signs include rapidly expanding or pulsatile hematoma, severe hemorrhage or difficulty controlling bleeding, shock refractory to fluid resuscitation, decreased or absent pulses, vascular bruits or thrills, or any neurological deficits on physical examination.<sup>[1]</sup> These signs are indications to perform CT angiography or formal diagnostic angiogram to check for the integrity of vascular structures in the spinal region.<sup>[1]</sup> The CT angiography assessment of the vascular structures should inform the physician on the location and type of injury, as well as, the effectiveness of collateral circulation pathways.<sup>[5]</sup> Abnormal findings that can be identified through CT angiography include dissection, vascular occlusion, pseudoaneurysm formation, and free contrast extravasation from an uncontained rupture.<sup>[5]</sup>

In some cases of penetrating traumas, such as CSF leaks, a mandatory exploratory surgery is carefully performed to determine the precise injuries of the patient and to surgically correct any concerns such as performing primary dural closure of a CSF leak.<sup>[10]</sup> Open surgery or endovascular treatment can be necessary for some patients with significant sustained damage to the vertebral artery. Intraoperative surgical management options include hemostatic tamponade, a microvascular repair of the injured artery, and a ligation of the vertebral artery.<sup>[18]</sup> Intraoperative angiography should be performed when ligation of the VA is intended and direct repair shown to be impossible.<sup>[18]</sup> Ligation of the VA has been shown to cause significant morbidities of cerebellar infarction, isolated cranial nerve paresis, and hemiplegia, with a reported mortality of 12%.<sup>[18]</sup> For this reason, microvascular primary repair is preferred as it allows normal flow of the circulation and minimizes the risk of both delayed and immediate ischemic complications. However, this method is more technically demanding in terms of skill.<sup>[18]</sup> For some less severe cases, in which it is unnecessary to operate, antiplatelets may be administered with magnetic resonance imaging monitoring for posterior fossa strokes.

After open neurovascular surgery or endovascular treatment, there are concerns such as incomplete treatment of vascular injury, delayed cerebral infarcts, or cerebral hemorrhage.<sup>[18]</sup> Conventional angiography is indicated postoperatively if the surgeon elected to manage the vertebral artery injury with tamponade only or direct repair.<sup>[18]</sup> This allows the clinician to detect vascular complications postoperatively, verify that collateral circulation pathways are providing sufficient blood supply, and determine the proper function of surgically repaired vessels.<sup>[18]</sup> In addition, a 2020 case report by Yoneoka *et al.* found that in the case of a patient brought in for a stab wound by a glass shard which shattered on impact, a postoperative CT angiography was found to be useful in validating the integrity of the vertebral arteries and ruling out pseudoaneurysm.<sup>[31]</sup> Therefore, in cases where there are small retained fragments from the object of injury, or fractures of the vertebrae which would cause a similar type of injury, a postoperative CT angiography is indicated to assess the integrity of the vasculature after the patient has undergone complete removal of small fragments, and complete repair of the vasculature, as the CT will inform the surgeon whether all small fragments which compromise the vasculature have been successfully removed.<sup>[31]</sup> In summary, CT angiogram is a useful imaging modality that can be used both preoperatively and postoperatively to evaluate the vascular structures and ensure that the patient has optimal chances of recovering from NMPSIs.

## GENERAL SURGICAL GUIDELINES

The benefit of surgical exploration versus nonsurgical management of NMPSI is a debated topic. Surgical consideration is warranted for progressive neurologic deficits, evidence of RFB, or prolonged CSF leakage.<sup>[6]</sup> When indicated, laminectomy to remove foreign fragments is the standard surgical approach among numerous cases.<sup>[15]</sup> Prompt recognition of the necessity for surgical exploration improves patient outcomes. However, studies suggest patients with delays in surgical care still benefit in regard to functional outcomes.<sup>[7]</sup> Many cases in the literature have demonstrated the urgent need for surgery immediately after removal of the foreign body.<sup>[22,27,30]</sup> In light of this, extraction of the foreign body in a surgical operating room with full surgical support is warranted in comparison to bedside management.<sup>[17]</sup> This recommendation is accepted regardless of neurologic sequelae or deteriorating clinical condition. Full surgical exploration is necessary in scenarios with developing CSF leaks, hemorrhage, and difficulty when removing the foreign body [Figure 1].

Advances in minimally invasive retrieval approaches of a RFB with the use of fluoroscopy have shown promise.<sup>[15]</sup> One case report utilizing the minimal dissection technique focused on reducing damage to musculature, soft tissue,

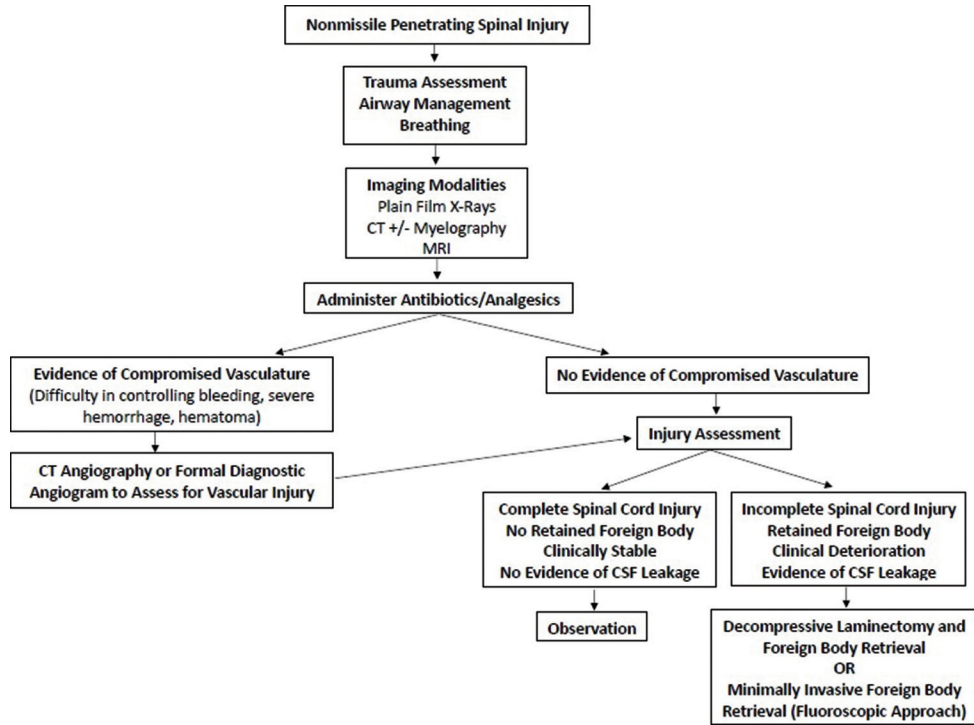
and bone. This approach may lead to a faster recovery and shorter hospital length of stay in comparison to traditional laminectomy approaches in the literature.<sup>[15,29]</sup> Because infection is also a concern in NMPSI, a minimally invasive technique that minimizes access through the RFB tract is beneficial to decrease the risk of infections and meningitis.<sup>[15]</sup> New operative techniques, such as the minimally invasive approach utilizing fluoroscopy by Moldovan *et al.*, provide an alternative treatment opportunity to traditional open laminectomy by employing the principles and techniques of minimally invasive spine surgery.<sup>[15]</sup>

Standard antibiotic prophylaxis recommendations specifically for NMPSI have not been reported. One report utilized an empiric antibiotic regimen recommended for open fracture protocols. Antibiotics should be given within 4 h of presentation and no later than 48–72 h. Evidence of spinal canal penetration warrants administration of third-generation cephalosporins for central nervous system coverage given concern for meningitis.<sup>[8]</sup> Benefit with corticosteroid therapy remains inconclusive and is not recommended. National acute spinal cord injury studies (NASCI) have investigated steroid usage in patients with traumatic spinal cord injuries in three separate trials. NASCI-3 trial demonstrated improved motor recovery in patients treated with methylprednisolone for 48 h versus 24 h at 6 weeks and 6 months, but must be weighed with the risk of systemic effects of the medication.<sup>[3]</sup> However, a larger study suggests no significant difference in long-term functional outcomes while also increasing susceptibility to infection.<sup>[12]</sup>

## NEW TECHNOLOGY AND RESEARCH FOR RECOVERY

NMPSI has the potential to cause permanent neurological deficits from SCI. In the event of SCI, the communication within the nervous system is disrupted, leading to the loss of essential neurological functions. With technological advancements and growth in innovation, much research focus is being placed on the recovery, or at least improving the functionality, of SCI patients. University of California Los Angeles researchers have created an innovative technique to increase the effective impulse potential through translational perspectives both in the treatment and in the diagnostics of spinal injuries.<sup>[19]</sup>

The utilization of electric stimulation is an innovative technique allowing patients with spinal injury to restore limb functionality.<sup>[19]</sup> Former stimulation approaches involved a device positioned on the injured cord that stimulated the spinal cord making the injured spinal cord more responsive even to weak incoming messages from the brain. An amplified transmission signal continues beyond the site of damage to reach the extremities. The new design utilizes multiple electrodes to stimulate the cord at different locations.<sup>[19]</sup>



**Figure 1:** Systematic flowchart of patient assessment and care plan.

The amplitude and frequency variations that were provided with the multielectrode positioning also played a crucial role in effectiveness.<sup>[19]</sup> The positioning of where the device was placed was carefully studied and assessed to join the portion of the spinal cord above the injury with that below.<sup>[19]</sup> The electrodes of this interface can also effectively record the activity of spinal neurons, which is extremely useful in diagnostics when assessing the residual activity of the cord after injury.<sup>[19]</sup>

Targeted spinal cord stimulation has shown progress with utilization of neurotechnology to facilitate voluntary control of walking in individuals who sustained a SCI status post-NMPSI.<sup>[28]</sup> Three participants with chronic cervical SCI and severe lower limb deficits or complete paralysis were implanted with 16-electrode paddle. This pulse generator targeted proprioceptive circuits by delivering trains of spatially selective stimulation to the posterior roots of the lumbosacral spinal cord. Through a novel closed-loop wireless design, the participants had real-time control over independently adjusted stimulation trains. Hence, the device created epidural electrical stimulation with timing that coincided with the intended movement thereby, restoring ambulation in individuals with severe or complete paralysis, even those with chronic symptoms. Within just 1 week, this spatiotemporal stimulation had reestablished adaptive control of paralyzed muscles during overground walking.<sup>[28]</sup> In addition, motor strength and gait performance improved during treatment, and after a few months, participants

regained walking capability during spatiotemporal stimulation.<sup>[28]</sup>

## CONCLUSION

NMPSI is a devastating traumatic injury that occurs rarely but can have lasting implications. It is important for neurologists and neurosurgeons to have proper understanding of the mechanism of injury, the potential neurological sequelae, and the most recent management guidelines. Workup includes CT angiography or formal diagnostic angiogram either preoperatively or both preoperative and postoperatively. Multielectrode pulse generators that potentiate impulse signals to the spinal cord have shown dramatic advances in NMPSI patients. However, there is a significant lack of data regarding outcomes and expectations. Likewise, literature on surgical intervention techniques is lacking uniformity and therefore treatment is individualized to each patient. Physician researchers are working on advanced techniques to perfect a standardization of care for NMPSI.

## Declaration of patient consent

Patient's consent not required as patients identity is not disclosed or compromised.

## Financial support and sponsorship

Nil.

## Conflicts of interest

There are no conflicts of interest.

## REFERENCES

- Alao T, Waseem M. Neck Trauma. Treasure Island, FL: Stat Pearls; 2020.
- Bledsoe BE, Casey M, Hodnick R. Breaking the surface: Arm yourself with knowledge about penetrating trauma. *JEMS* 2012;37:58-64.
- Bracken MB, Shepard MJ, Holford TR, Leo-Summers L, Aldrich EF, Fazl M, *et al.* Administration of methylprednisolone for 24 or 48 hours or tirilazad mesylate for 48 hours in the treatment of acute spinal cord injury. Results of the third national acute spinal cord injury randomized controlled trial. National acute spinal cord injury study. *JAMA* 1997;277:1597-604.
- Enicker B, Gonya S, Hardcastle TC. Spinal stab injury with retained knife blades: 51 Consecutive patients managed at a regional referral unit. *Injury* 2015;46:1726-33.
- Goldberg AL, Kershah SM. Advances in imaging of vertebral and spinal cord injury. *J Spinal Cord Med* 2010;33:105-16.
- Goyal RS, Goyal NK, Salunke P. Non-missile penetrating spinal injuries. *Indian J Neurotrauma* 2009;6:81-4.
- Groen RJ, Kafiluiddin EA, Hamburger HL, Veldhuizen EJ. Spinal cord injury with a stingray spine. *Acta Neurochir (Wien)* 2002;144:507-8.
- Kramer MM, Acker A, Ohana N. Penetrating spinal cord injury. In: *Essentials of Spinal Cord Injury Medicine*. London: Intech Open; 2018.
- Kuhajda I, Zarogoulidis K, Kougioumtzi I, Huang H, Li Q, Dryllis G, *et al.* Penetrating trauma. *J Thorac Dis* 2014;6 Suppl 4:S461-5.
- Kumar A, Pandey PN, Ghani A, Jaiswal G. Penetrating spinal injuries and their management. *J Craniovertebr Junction Spine* 2011;2:57-61.
- Lefebvre CW, Babich JP, Grendell JH, Grendell JH, Heffner JE, Thibault R, *et al.* Penetrating wounds. In: *Encyclopedia of Intensive Care Medicine*. Berlin, New York: Springer; 2012. p. 1699-703.
- Levy ML, Gans W, Wijesinghe HS, SooHoo WE, Adkins RH, Stillerman CB. Use of methylprednisolone as an adjunct in the management of patients with penetrating spinal cord injury: Outcome analysis. *Neurosurgery* 1996;39:1141-9.
- Lipschitz R, Block J. Stab wounds of the spinal cord. *Lancet* 1962;280:169-72.
- Martin MD, Wolfla CE. Penetrating Spine Trauma, Neupsy Key; 2016. Available from: <https://www.neupsykey.com/penetrating-spine-trauma>. [Last accessed on 2020 Jul 29].
- Moldovan K, Telfeian AE, Fridley JS, Gokaslan ZL, Aghion D, Oyelese AA. Minimally invasive approach to non-missile penetrating spinal injury with resultant retained foreign body: A case report and review of the literature. *Clin Neurol Neurosurg* 2019;184:105405.
- Nasr A, de Oliveira JT, Mazepa MM, de Albuquerque CL, Martini GS, Nazario M, *et al.* Evaluation of the use of tomography in penetrating neck trauma. *Rev Col Bras Cir* 2015;42:215-9.
- Peacock WJ, Shrosbree RD, Key AG. A review of 450 stabwounds of the spinal cord. *S Afr Med J* 1977;51:961-4.
- Peng CW, Chou BT, Bendo JA, Spivak JM. Vertebral artery injury in cervical spine surgery: Anatomical considerations, management, and preventive measures. *Spine J* 2009;9:70-6.
- Ramani D. Spinal Injuries: A New Technology of Electrostimulation for a More Effective Approach. United States: American Association for the Advancement of Science; 2019. Available from: [https://www.eurekalert.org/pub\\_releases/2019-11/sisd-sia111319.php](https://www.eurekalert.org/pub_releases/2019-11/sisd-sia111319.php). [Last accessed on 2020 Jul 29].
- Shahlaie K, Chang DJ, Anderson JT. Nonmissile penetrating spinal injury. Case report and review of the literature. *J Neurosurg Spine* 2006;4:400-8.
- Simpson RK Jr., Venger BH, Narayan RK. Treatment of acute penetrating injuries of the spine: A retrospective analysis. *J Trauma* 1989;29:42-6.
- Smith C, White JB. Penetrating knife injuries to the spine: Management considerations and literature review. *Interdiscip Neurosurg* 2014;1:3-4.
- Sperry JL, Moore EE, Coimbra R, Croce M, Davis JW, Karmy-Jones R, *et al.* Western trauma association critical decisions in trauma. *J Trauma Acute Care Surg* 2013;75:936-40.
- Steenburg SD, Sliker CW, Shanmuganathan K, Siegel EL. Imaging evaluation of penetrating neck injuries. *Radiographics* 2010;30:869-86.
- Takhtani D, Melhem ER. MR imaging in cervical spine trauma. *Clin Sports Med* 2002;21:49-75, 6.
- Thakur RC, Khosla VK, Kak VK. Non-missile penetrating injuries of the spine. *Acta Neurochir (Wien)* 1991;113:144-8.
- Villarreal-García FI, Reyes-Fernández PM, Martínez-Gutiérrez OA, Peña-Martínez VM, Morales-Ávalos R. Direct withdrawal of a knife in the lumbar spinal canal in a patient without neurological deficit: Case report and review of the literature. *Spinal Cord Ser Cases* 2018;4:48.
- Wagner FB, Mignardot JB, Le Goff-Mignardot CG, Demesmaeker R, Komi S, Capogrosso M, *et al.* Targeted neurotechnology restores walking in humans with spinal cord injury. *Nature* 2018;563:65-71.
- Wallace DJ, Sy C, Peitz G, Grandhi R. Management of non-missile penetrating spinal injury. *Neurosurg Rev* 2019;42:791-8.
- Xia X, Zhang F, Lu F, Jiang J, Wang L, Ma X. Stab wound with lodged knife tip causing spinal cord and vertebral artery injuries: Case report and literature review. *Spine (Phila Pa 1976)* 2012;37:E931-4.
- Yoneoka Y, Akiyama K, Seki Y. Glass fragment injury to the craniocervical junction with interatlantooccipital penetration to the subarachnoid space: Not-to-be-missed important aspects of craniocervical trauma even in the middle of the COVID-19 pandemic: Case report and review of literature. *World Neurosurg* 2020;141:402-5.
- Yoon J, Efendy J, Szkandera B, Redmond M. Non missile penetrating spinal injury. *J Clin Neurosci* 2019;67:239-43.

**How to cite this article:** Fiani B, Figueras RA, De Stefano F, Gautam N, Khan A, Soula M. Nonmissile penetrating spinal injuries: Mechanisms, expectations, and management. *Surg Neurol Int* 2020;11:406.