ScientificScholar®
Knowledge is power
Publisher of Scientific Journals

www.surgicalneurologyint.com

Surgical Neurology International

Editor-in-Chief: Nancy E. Epstein, MD, Clinical Professor of Neurological Surgery, School of Medicine, State U. of NY at Stony Brook.

SNI: Spine

Editor
Nancy E. Epstein, MD
Clinical Professor of Neurological Surgery, School of Medicine, State U. of NY at Stony Brook

SNI
Open Access

Case Report

Broken surgical blade retrieval following lumbar discectomy through paravertebral/lateral transpsoas approach: A case report

Pablo Barbero-Aznarez, Carlos Bucheli-Peñafiel, Eduardo Olmos-Francisco, Asís Lorente-Muñoz, Severiano Cortés-Franco

Department of Neurosurgery, Hospital Quironsalud Zaragoza, Zaragoza, Aragon, Spain.

E-mail: *Pablo Barbero-Aznarez - pbancx@icloud.com; Carlos Bucheli-Peñafiel - carlos.bucheli@quironsalud.es; Eduardo Olmos-Francisco - olmos.f@gmail.com; Asís Lorente-Muñoz - asislm@hotmail.com; Severiano Cortés-Franco - sevezgz@hotmail.com



***Corresponding author:**
Pablo Barbero-Aznarez,
Department of Neurosurgery,
Hospital Quironsalud Zaragoza,
Zaragoza, Aragon, Spain.

pbancx@icloud.com

Received : 06 December 2020
Accepted : 24 December 2020
Published : 20 January 2021

DOI
10.25259/SNI_880_2020

Quick Response Code:

ABSTRACT

Background: There are rare reports of broken surgical blades occurring during lumbar discectomy, and even fewer that discuss their retrieval.

Case Description: While a 54-year-old male was undergoing a lumbar discectomy, the knife blade was broken. As it was difficult to retrieve the fragment through the original incision, the patient was closed, and a postoperative angio-computerized tomography (CT) was obtained. When the CT angiogram (CTA) documented the retained fragment had become lodged near the iliac vein within the psoas muscle, a second operation for blade retrieval, consisting of a paravertebral, lateral transpsoas approach, was successfully performed.

Conclusion: In some cases, it is difficult to retrieve a broken scalpel blade during the index surgery. When this occurs, we would recommend closing the patient, and obtaining a CTA to better document the location of the retained foreign body. Based upon these findings, a safer second stage procedure may be performed (e.g., as in this case using a paravertebral lateral transpsoas approach) to avoid undue sequelae/morbidity.

Keywords: Broken surgical blade, Complication, Lateral transpsoas approach, Lumbar discectomy

INTRODUCTION

There are few guidelines as to how retrieve potentially dangerous fractured surgical blades during index spinal surgical procedures (e.g., endoscopically, transforaminally, robot-assisted laparoscopy, paravertebral lateral transpsoas approach, and other).

Zheng emphasized that in such circumstances, a knife may migrate to a potentially dangerous location,[4] while others like Amirjamshidi recommend retrieving these blades at second operations.[1]

Here, following a lumbar discectomy, we utilized a postoperative computerized tomography angiogram (CTA) to identify a retained/migrated knife blade and removed it secondarily through a paravertebral, lateral transpsoas approach.

CASE DESCRIPTION

A 54-year-old male underwent a standard L4-L5 discectomy during which the knife blade suddenly broke off. After numerous failed attempts to retrieve the blade under fluoroscopy, the patient was closed, and a CTA was ordered [Figure 1]. When the CTA showed that the knife had migrated in close vicinity to the iliac vein [Figure 2], the fragment was safely retrieved utilizing a second paravertebral, lateral transpsoas approach performed with a vascular surgeon in attendance [Figure 3].

DISCUSSION

Here, we report a case in which a surgical blade broke off during a L4-L5 discectomy. After obtaining a postoperative CTA, the retained foreign body was safely approached utilizing a secondary paravertebral, lateral transpsoas approach. There

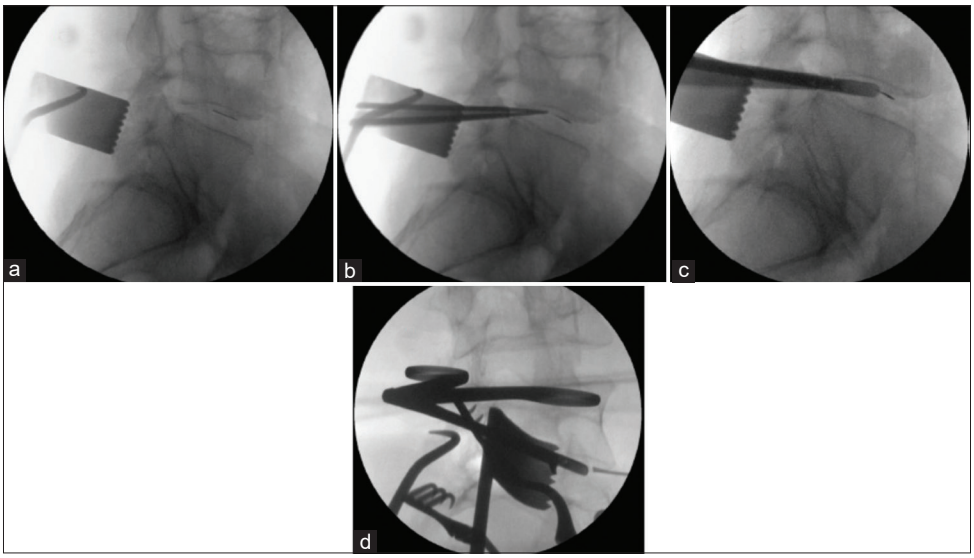

Figure 1: (a) Surgical blade in the intervertebral disc. (b) Use of forceps to try to retrieve the blade. (c) Use of a dissector to feel where the blade is. (d) AP view showing the blade is halfway outside the spine.

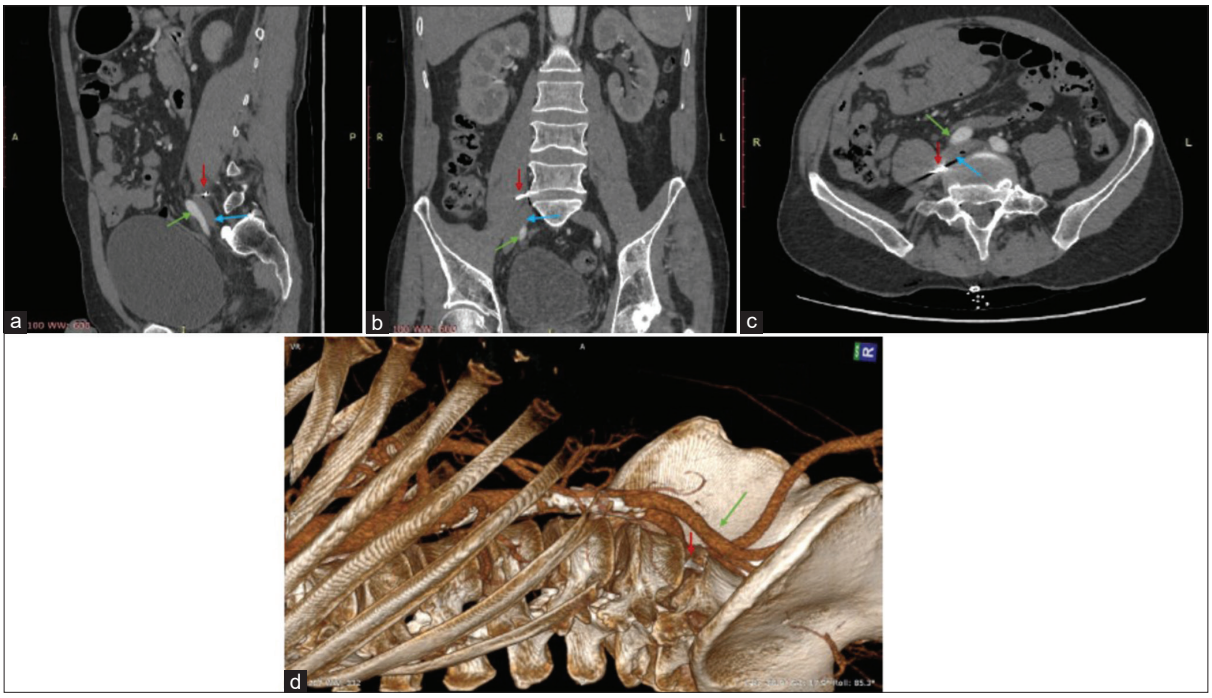

Figure 2: (a) Sagittal (b) coronal (c) axial (d) 3D reconstruction showing the approximate field of view of lateral transpsoas approach. Red arrow: Surgical blade. Green arrow: Iliac artery. Blue arrow: Iliac vein.

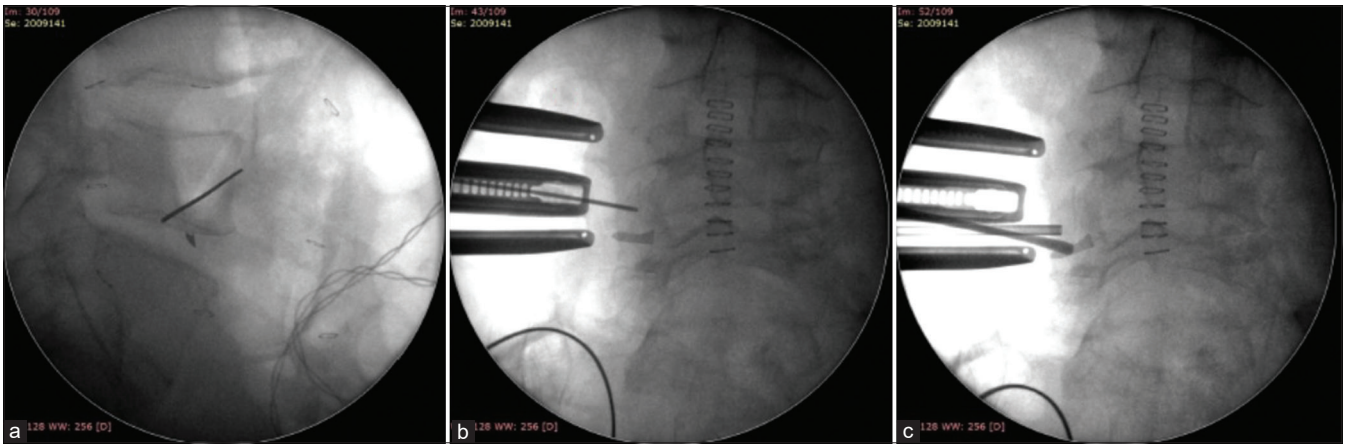

Figure 3: (a) Placement of Kirschner wire. (b) Placement of automatic retractor. (c) Use of dissector and suction to help dissect muscle fibers and retrieve the blade.

are other approaches for retrieving a broken blade in the spine like the transforaminal approach, described by Rahimizadeh *et al*., not applicable to our particular case [3] and the use of robot-assisted laparoscopy to remove a broken blade which had migrated toward the aorta and iliac artery during a lumbar discectomy, described by Koutserimpas *et al*.[2]

CONCLUSION

A surgical scalpel broke and significantly migrated during a lumbar discectomy making it impossible to remove at the index procedure. Utilizing a postoperative CTA to document the fragment location (i.e., close to the iliac vein), the patient underwent a secondary paravertebral lateral transpsoas approach for safe scalpel blade excision.

Declaration of patient consent

The authors certify that they have obtained all appropriate patient consent.

Financial support and sponsorship

Nil.

Conflicts of interest

There are no conflicts of interest.

REFERENCES

1. Amirjamshidi A, Mehrazin M, Abbassioun K, Ketabtchi E. Retained broken knife blades within the disc space. Spine (Phila Pa 1976) 1994;19:981-4.
2. Koutserimpas C, Ioannidis A, Konstantinidis M, Athanasopoulos P, Antonakopoulos F, Konstantinidis K. Robot-assisted removal of a broken scalpel blade following discectomy. Case Rep Surg 2019;2019:8609246.
3. Rahimizadeh A, Ghorbani E, Rahimizadeh S. Transforaminal retrieval of intradiscal retained broken surgical knife blade. Spine (Phila Pa 1976) 2013;38:E1278-81.
4. Zheng GB, Wang Z. Removal of the deeply located intradiskal broken knife blade with arthroscopic assistance: Case report and literature review. World Neurosurg 2020;137:272-5.

How to cite this article: Barbero-Aznarez P, Bucheli-Peñafiel C, Olmos-Francisco E, Lorente-Muñoz A, Cortés-Franco S. Broken surgical blade retrieval following lumbar discectomy through paravertebral/lateral transpsoas approach: A case report. Surg Neurol Int 2021;12:25.