



Case Report

Distant large acute epidural hematoma after closed cerebrospinal fluid tapping through the anterior fontanelle: A case report and its pathogenesis

Ahmed A. M. Ezzat, Mohamed A. R. Soliman, Mohammad Baraka, Mohamed El Shimy, Adham Ezz, Ehab El Refaee

Department of Neurosurgery, Cairo University, Cairo, Egypt.

E-mail: Ahmed A. M. Ezzat - doommika@yahoo.com; *Mohamed A. R. Soliman - moh.ar.sol@kasralainy.edu.eg; Mohammad Baraka - barakaegypt@gmail.com; Mohamed El Shimy - mohamed.m.elshimy@gmail.com; Adham Ezz - adham_ezz_08@yahoo.com; Ehab El Refaee - e.elrefaee@googlemail.com

***Corresponding author:**

Mohamed A. R. Soliman,
Department of Neurosurgery,
Cairo University, Cairo, Egypt.
moh.ar.sol@kasralainy.edu.eg

Received : 16 December 2020

Accepted : 20 January 2021

Published : 17 February 2021

DOI

10.25259/SNI_921_2020

Quick Response Code:



ABSTRACT

Background: Cerebrospinal fluid (CSF) infection is one of the most common and serious complications of shunt placement. The CSF shunt infections are preferably treated with intravenous antibiotics, infected shunt removal, repeated tapping (infants) or placement of an external ventricular drainage (EVD) device, and placement of a new shunt once the CSF is sterile. The tapping through the anterior fontanelle is commonly used instead of the EVD in developing countries to manage CSF infection in open anterior fontanelle patients. To the best of our knowledge, this would be considered the first reported case of distant epidural hematoma after closed ventricular tapping.

Case Description: We report a case of 6-months child with Chiari malformation (Type II) presenting to us with a shunt infection with possible obstruction. CSF was aspirated for examination through a tap through the anterior fontanelle followed by the development of extradural hemorrhage far from the tapping site.

Conclusion: EDH after a transfontanellar ventricular tap can rapidly evolve and lead to patient death. This report raises the awareness of the neurosurgeons to this possible complication that can happen and leads to major complications. Monitoring the conscious level would be needed after ventricular tapping to detect this possible complication.

Keywords: Acute epidural hematoma, Anterior fontanelle, Cerebrospinal fluid tapping, Distant, Transfontanellar

INTRODUCTION

Ventriculoperitoneal shunt (VPS) is the most common procedure used for the management of hydrocephalus. Epidural hematoma (EDH) is a common disease and represents serious risks if not quickly diagnosed and managed. The preferred treatment of cerebrospinal fluid (CSF) shunt infections involves intravenous antibiotics, infected shunt removal, repeated ventricular tapping in infants, or preferably placement of an external ventricular drainage (EVD) device followed by placement of a new shunt once the CSF is sterile.^[11] Percutaneous transfontanellar tapping is commonly used in low resource countries due to the high costs of the EVD, however, there is no information in the literature on the proper technique, volume of tapping, speed of tapping, precautions, and contraindications.

The occurrence of EDH following ventricular drainage procedures is rare (0.4%)^[8] and has rarely been reported, however, it can lead to death justify excessive suspicion of this entity.^[12] In this

This is an open-access article distributed under the terms of the Creative Commons Attribution-Non Commercial-Share Alike 4.0 License, which allows others to remix, tweak, and build upon the work non-commercially, as long as the author is credited and the new creations are licensed under the identical terms.

©2020 Published by Scientific Scholar on behalf of Surgical Neurology International

report, we present the first report of EDH after a closed CSF tap through the anterior fontanelle in a child with shunt infection and suspected obstruction. The main aim of this report is to draw the attention of those who manage hydrocephalus patients, such as neurosurgeons and pediatric neurologists to this potentially fatal complication which if diagnosed early can be successfully treated.

CASE REPORT

A 6-months child with Chiari II malformation who is otherwise medically free presented to us at the age of 4 months with lumbar meningomyelocele (MMC) and hydrocephalic changes operated on initially by right posterior parietal Chhabra medium pressure contoured VP shunt (G. Surgiwear Ltd., India) at the time of presentation. The MMC was repaired in the same session by direct repair and closure in layers. Two months after surgery, he developed fever, malaise, bulging, and tense anterior fontanelle and was diagnosed with a shunt infection after the VP shunt valve tap showed a CSF TLC of 150 cells/mm³ mainly polymorphs, as well as the culture and sensitivity, showed *Staphylococcus aureus*. This was managed by intravenous vancomycin 200 mg 3 times a day for 1 week with closed ventricular tapping (about 40 ml passively tapped using gravity [pressure gradient] over 20 min using a 20 F cannula after good sterilization) with leaving the shunt in place. The tapping was done 2 times (3 days apart). The 2nd day after the last tap, the child was sleepy with poor oral feeding. Urgent CT brain showed a 36.3 cc right parietal EDH [Figure 1] managed by surgical evacuation through an inverted U-shaped incision with simultaneous shunt replacement at the previous trajectory as the new CSF analysis was normal TLC with negative cultures. We did not recognize any source of bleeding intraoperatively and all the preoperative patient's laboratories were normal. Following the evacuation and the shunt replacement, the child was fully conscious with good oral feeding and discharged home after 2 days with the CT showed full evacuation of the EDH [Figure 2]. The patient was clinically normal at 3- and 6-month follow-up.

DISCUSSION

VP shunt is the most common surgical procedure in the treatment of hydrocephalus worldwide.^[2,4] Complications such as infection and obstruction are more common than bleeding.^[5,15] The first EDH reported after CSF drainage by a VP shunt was in 1941 since that time there were several cases reported in the literature.^[3,6,15] However, there are no reported cases in the literature about EDH occurrence after ventricular tapping, which is commonly used instead of the EVD to manage CSF infection in open anterior fontanelle patients.^[13,14] The tapping was done through the right or left angles of the anterior fontanelle in a direction away from the superior sagittal sinus using a small-bore cannula at a

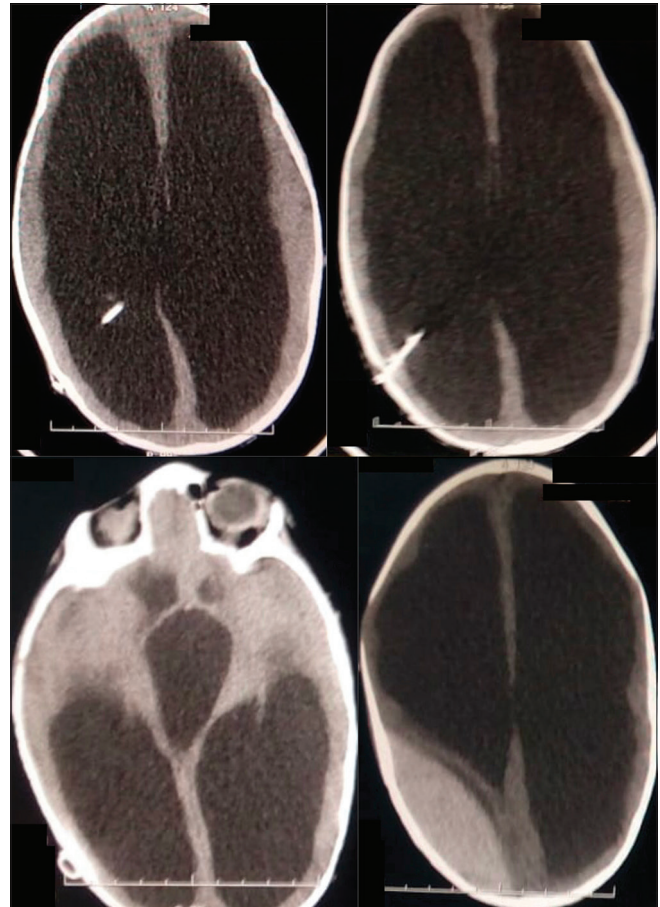


Figure 1: Computed tomography head showing a right parietal large epidural hematoma away from the shunt track and hydrocephalus.

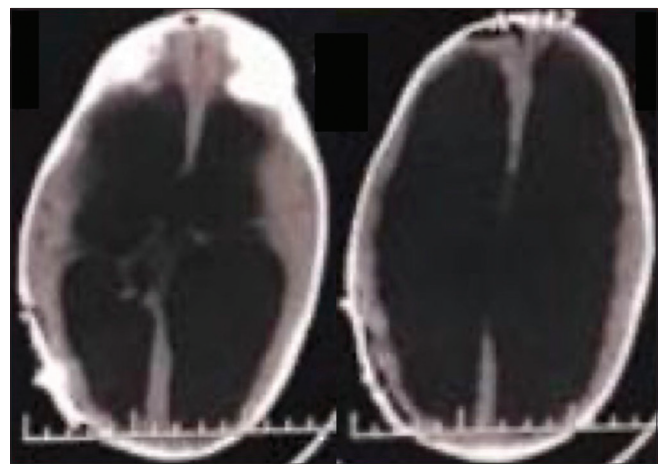


Figure 2: Computed tomography head showing evacuation of the previously seen epidural hematoma.

rate of 2 ml/min. In the authors' hospital, due to the low socioeconomic standards, the open anterior fontanelle infants are managed by IV antibiotics and anterior fontanelle tapping every 3 days for CSF drainage and analysis until the CSF is

clear from infection. The authors find a high rate of infection and a longer hospital stay with shunt externalization leading to increased occupancy of the department by these patients.

Pathophysiology of EDH formation

EDH can occur after several cranial procedures, as the epidural space is violated. Decreased intracranial pressure (ICP) after craniotomies or CSF diversion procedures would allow the collection of a hematoma in the subdural or the epidural space.^[15] Two essential factors are necessary for the development of EDH; the first is the presence of a bleeding source and the second is the dura mater separation from the cranial vault.^[5] Schorstein *et al.* mentioned that the decreased ICP led to the traction of the dura leading to separation in some areas. The traction exerted by the brain's venous attachment on the dura would also be a factor leading to venous hematoma. There is controversy on finding a recognizable source of bleeding, Sengupta and Hankinson review, they failed to find a recognizable source of bleeding either at necropsy or during reexploration which is consistent with our case,^[15] while, Niimura *et al.* review reported that a source of bleeding was identified in 67% of the reported cases.^[10]

The frontoparietal lobes are the most common locations of EDH. This may be attributed to the loose attachment of the dura in this region to the cranial vault.^[5] EDH tends to occur within hours after lowering the increased ICP. Odake and Matsumoto reported the largest case series of EDH after ventricular procedures, including VP and ventriculoatrial shunts, ventriculography, ventricular puncture, and others.^[12]

EVD was first described by Dandy.^[17] The most common complications related to EVD are hemorrhage and infection; however, there is sparse reporting of hemorrhagic complications of EVD in the literature.^[9] EDH is rare after EVD placement. It can occur either at the site of EVD placement or at a distant site.^[11] In our case, hematoma occurred remotely at the parietal lobe on the opposite side.

Release of CSF after lumbar punctures has been previously reported to cause the development of hemorrhage. In most cases, it would cause a spinal epidural hematoma, however, it was previously reported to cause intracranial hemorrhage.^[7]

The cortex collapse as the etiology of hematomas should be taken into consideration as it can lead to traction forces on the middle meningeal artery or its branches which are slightly adherent to the skull.^[14] Seyithanoglu *et al.* hypothesized that the arachnoid-dura adhesions are tighter than the dura-skull adhesions and thus overdrainage would lead to hematoma formation in the epidural space rather than the subdural space.^[16]

It seems that the 40 ml over 20 min lead to EDH may be attributed to rapid dilated ventricles decompression with

dura mater stripping from the bone leading to an acute EDH. In addition, the longstanding hydrocephalus associated with the decreased brain parenchyma thickness has led to the event. Till now, it is unavoidable to use the ventricular tapping technique in the CSF infection management in open fontanelle infants in lower income countries settings. Furthermore, there are no guidelines on the indications, precautions, contraindications, tapping volume, and speed of the tap in the literature. We are calling neurosurgeons from lower income countries that are using this technique to report their techniques and outcomes to set guidelines for this technique to avoid future complications.

CONCLUSION

To the best of our knowledge, we present the first reported EDH after a ventricular tap through the anterior fontanelle, which can rapidly evolve and lead to patient death. Neurosurgeons must be aware of such complications that can happen despite the slow CSF tapping. Clinical monitoring of the conscious level is essential to detect this hazard and manage it properly. Furthermore, we are calling for further studies, especially from low resource countries to present their experience on the clinical outcomes and techniques of the transfontanellar tapping to prevent this unfortunate incident in the future.

Declaration of patient consent

Patient's consent not required as patients identity is not disclosed or compromised.

Financial support and sponsorship

Nil.

Conflicts of interest

There are no conflicts of interest.

REFERENCES

1. Chung HJ, Park JS, Park JH, Jeun SS. Remote postoperative epidural hematoma after brain tumor surgery. *Brain Tumor Res Treat* 2015;3:132-7.
2. Ezzat AA, Soliman MA, Hasanain AA, Thabit MA, Elshityan H, Kandel H, *et al.* Migration of the distal catheter of ventriculoperitoneal shunts in pediatric age group: Case series. *World Neurosurg* 2018;119:e131-7.
3. Fujimoto Y, Aguiar PH, Carneiro JD, Martins RS, Ciquini O, de Andrade AF, *et al.* Spontaneous epidural hematoma following a shunt in an infant with congenital factor X deficiency. Case report and literature review. *Neurosurg Rev* 1999;22:226-9.
4. Hasanain AA, Abdullah A, Alsawy MF, Soliman MA, Ghaleb AA, Elwy R, *et al.* Incidence of and causes for ventriculoperitoneal shunt failure in children younger

- than 2 years: A systematic review. *J Neurol Surg A Cent Eur Neurosurg* 2018;80:26-33.
5. Higazi I. Epidural hematoma as complication of ventricular drainage: Report of a case and review of literature. *J Neurosurg* 1963;20:527-8.
 6. Kalia KK, Swift DM, Pang D. Multiple epidural hematomas following ventriculoperitoneal shunt. *Pediatr Neurosurg* 1993;19:78-80.
 7. Lee SJ, Lin YY, Hsu CW, Chu SJ, Tsai SH. Intraventricular hematoma, subarachnoid hematoma and spinal epidural hematoma caused by lumbar puncture: An unusual complication. *Am J Med Sci* 2009;337:143-5.
 8. Louzada PR, Requejo PR, Barroso MV, Vaitsman RP, Machado AL, Paiva MS, *et al.* Bilateral extradural haematoma after acute ventricular over-drainage. *Brain Inj* 2012;26:95-100.
 9. Maniker AH, Vaynman AY, Karimi RJ, Sabit AO, Holland B. Hemorrhagic complications of external ventricular drainage. *Neurosurgery* 2006;59:ONS419-24; discussion ONS424-5.
 10. Niimura M, Takai K, Taniguchi M. Postoperative epidural haematomas associated with hydrocephalus caused by intraoperative overdrainage of cerebrospinal fluid: Two case reports with a literature review of 19 cases. *BMJ Case Rep* 2015;2015:bcr2014206654.
 11. Noleto G, Neville IS, Tavares WM, Saad F, Pinto FC, Teixeira MJ, *et al.* Giant acute epidural hematoma after ventriculoperitoneal shunt: A case report and literature review. *Int J Clin Exp Med* 2014;7:2355-9.
 12. Otake G, Matsumoto S. Supratentorial epidural hematoma as a complication of internal decompression. *Neurol Med Chir (Tokyo)* 1981;21:897-905.
 13. Ojo OA, Asha MA, Bankole OB, Kanu OO. Improvised external ventricular drain in neurosurgery: A Nigerian tertiary hospital experience. *J Neurosci Rural Pract* 2015;6:304-8.
 14. Schreffler RT, Schreffler AJ, Wittler RR. Treatment of cerebrospinal fluid shunt infections: A decision analysis. *Pediatr Infect Dis J* 2002;21:632-6.
 15. Sengupta RP, Hankinson J. Extradural haemorrhage-a hazard of ventricular drainage. *J Neurol Neurosurg Psychiatry* 1972;35:297-303.
 16. Seyithanoglu H, Guzey FK, Emel E, Ozkan N, Aycan A. Chronic ossified epidural hematoma after ventriculoperitoneal shunt insertion: A case report. *Turk Neurosurg* 2009;20:519-23.
 17. Srinivasan VM, O'Neill BR, Jho D, Whiting DM, Oh MY. The history of external ventricular drainage: Historical vignette. *J Neurosurg* 2014;120:228-36.

How to cite this article: Ezzat AA, Soliman MA, Baraka M, El Shimy M, Ezz A, El Refaee E. Distant large acute epidural hematoma after closed cerebrospinal fluid tapping through the anterior fontanelle: A case report and its pathogenesis. *Surg Neurol Int* 2021;12:59.