




Review Article

# Venous sinus stenting for intractable pulsatile tinnitus: A review of indications and outcomes

Brian Fiani<sup>1</sup>, Athanasios Kondilis<sup>2</sup>, Thao Doan<sup>3</sup>, Juliana Runnels<sup>4</sup>, Nicholas J. Fiani<sup>5</sup>, Erika Sarno<sup>6</sup>

<sup>1</sup>Department of Neurosurgery, Desert Regional Medical Center, Palm Springs, California, CA, <sup>2</sup>College of Osteopathic Medicine, Michigan State University, East Lansing, Michigan, <sup>3</sup>University of Texas Medical Branch, Galveston, Texas, <sup>4</sup>School of Medicine, University of New Mexico, Albuquerque, New Mexico, <sup>5</sup>University of Medicine and Health Sciences Medical School, New York, NY, <sup>6</sup>College of Osteopathic Medicine, Michigan State University, East Lansing, Michigan, United States.

E-mail: \*Brian Fiani - bfiani@outlook.com; Athanasios Kondilis - kondilis@msu.edu; Thao Doan - tmdoan@utmb.edu; Juliana Runnels - jmrannels@salud.unm.edu; Nicholas J. Fiani - nfiani@live.com; Erika Sarno - sarnoeri@msu.edu



**\*Corresponding author:**

Brian Fiani, D.O.  
Department of Neurosurgery,  
Desert Regional Medical  
Center, Palm Springs,  
California, United States.

bfiani@outlook.com

Received : 01 January 2021  
Accepted : 09 February 2021  
Published : 02 March 2021

DOI  
10.25259/SNI\_1\_2021

Quick Response Code:



## ABSTRACT

**Background:** Pulsatile tinnitus presents as a unique variation of tinnitus in which a conscious perception of the heartbeat is localized to the ears in either unilateral or bilateral fashion. The sensation is typically caused by an increase in turbulent blood flow in the affected ear, in most cases, due to a structural abnormality of the venous sinuses – the most common of which being stenosis. Herein, we discuss the etiology of pulsatile tinnitus followed by indications for treatment of various pathologies which have been successfully treated with venous sinus stenting and have led to resolution of auditory symptoms.

**Methods:** The authors queried PubMed database using combinations of the keywords “venous sinus stenting,” “endovascular treatment,” and “pulsatile tinnitus” to identify relevant studies published in English after 2001 and before December 1, 2020 and verified selected.

**Results:** Our results corroborate those published in prior reviews reporting a high rate of pulsatile tinnitus resolution with venous sinus stenting.

**Conclusion:** The success of venous sinus stenting is clinically relevant as an effective treatment option for patients suffering from pulsatile tinnitus. Future applications and studies are needed and are currently being developed to further demonstrate the effectiveness of stents in the treatment of pulsatile tinnitus.

**Keywords:** Angioplasty, Neuro-otology, Pulsatile tinnitus, Venous sinus stenosis, Venous sinus stenting

## INTRODUCTION

Tinnitus, often described as “ringing in the ears,” is the persistent, unwanted perception of sound, usually in the absence of a genuine physical source. There are two general subtypes of tinnitus: pulsatile and nonpulsatile. In nonpulsatile tinnitus, the sound is caused by a hearing malfunction. However, in pulsatile tinnitus, hearing is intact and the tinnitus is usually due to perception of turbulent, accelerated, or normal blood or cerebrospinal fluid (CSF) flow within vessels proximal to ear.<sup>[27,50]</sup> Diagnosis of pulsatile tinnitus includes examination of comprehensive clinical data as well as magnetic resonance imaging (MRI) and even digital subtractive angiography (DSA) in some patients.<sup>[4,22]</sup> Current treatments include lifestyle modifications and medications aimed

This is an open-access article distributed under the terms of the Creative Commons Attribution-Non Commercial-Share Alike 4.0 License, which allows others to remix, tweak, and build upon the work non-commercially, as long as the author is credited and the new creations are licensed under the identical terms.

©2020 Published by Scientific Scholar on behalf of Surgical Neurology International

at the reduction of high blood pressure which may be an underlying cause in some patients.<sup>[22,27]</sup>

Venous stenting procedures have been established as an effective in patients with pulsatile tinnitus resulting from vascular abnormalities.<sup>[4,6,50]</sup> However, in the remaining cases of pulsatile tinnitus of nonvascular origin, resulting from abnormal flow of CSF, stenting of venous sinuses is emerging as an effective treatment.<sup>[9,32,50]</sup> In a prospective cohort study, most patients experienced complete or near complete resolution of their symptoms after stenting of the lateral venous sinus demonstrating the safety and efficacy of this technique.<sup>[38]</sup> In this review, we will provide a contemporary and comprehensive assessment of venous sinus stenting as a treatment of pulsatile tinnitus stemming from various etiologies and provide necessary information for patient selection and approach in treatment.

## PATIENT SELECTION

### Symptoms

Patients with intractable pulsatile tinnitus present with an array of symptoms, the most common of which being a conscious perception of the heartbeat within the ears of the affected individual (typically unilateral, but in rare cases can present bilaterally).<sup>[6]</sup> Patients tend to describe pulsatile tinnitus as a “whooshing” sensation in the affected ear, due to an increase in turbulent blood flow.<sup>[5]</sup> The loudness of the tinnitus is found to be reduced by head rotation or ipsilateral neck compression; however, this relief is temporary in duration.<sup>[5]</sup> Decibel range for loudness in cases of pulsatile tinnitus can extend from 30 to 85 dB and frequencies between 125 and 1000 Hz.<sup>[5]</sup> As a result, patients tend to report decreases in sleep duration, as well as decreased quality of life, with severe cases also presenting with concomitant depression.<sup>[25]</sup>

### Indications

In the event of pulsatile tinnitus, patients will typically present with some form of cerebrovascular disease to warrant treatment through venous sinus stenting. This commonly includes idiopathic intracranial hypertension, of which pulsatile tinnitus tends to present secondarily to primary reports of headaches, papilledema, and visual disturbances.<sup>[6,40,54]</sup> Updated Dandy criteria for diagnosis of idiopathic intracranial hypertension include the aforementioned signs of increased intracranial pressure (ICP) along with no other localizing neurologic signs (barring unilateral or bilateral VI nerve paresis), increased pressure in the CSF without any cytologic or chemical abnormalities, and normal to small ventricles as demonstrated by CT.<sup>[18]</sup> Studies have shown upward of 90% of patients with idiopathic intracranial hypertension also present with venous sinus stenosis (VSS), hence, the indication for stenting.<sup>[6]</sup>

Although there is no current standard for stenting in VSS as a result of idiopathic intracranial hypertension, prior studies describe cases of significant intracranial hypertension (with a pressure gradient >10 mmHg across the area of stenosis and VSS >50%) as key indications for stenting following failed conservative treatment.<sup>[7,13,16,49]</sup>

VSS can also cause pulsatile tinnitus without a noticeable increase in ICP, which also poses one of the controversies of stenting as to whether or not the surgical intervention is warranted.<sup>[43,54]</sup> Routine CT or MRI rarely shows an abnormality due to difficulty localizing stenosis which can be hidden at the transverse-sigmoid junction, but can be confirmed with DSA.<sup>[5,54]</sup> Further, it has been determined that hemodynamic shifts – particularly, vortex formation in the distal expansion of the transverse sinus – are found to produce the tinnitus without any additional symptoms.<sup>[43]</sup> In a study by Russell *et al.*, clinical presentations of tinnitus without increased ICP were discussed but no treatment was implemented.<sup>[43]</sup> However, a study by Baomin *et al.* found that 43 out of 46 patients enrolled displayed signs of PT without an increase in ICP, and subsequent venous stenting was found to eliminate pulsatile tinnitus in all 46 patients with no recurrence noted, indicating a high degree of efficacy in cases of VSS whether or not ICP is present.<sup>[5]</sup>

Pulsatile tinnitus can also be caused by a sigmoid sinus diverticulum or dehiscence (SSDD) or venous sinus aneurysm when the lesion occurs proximal to mastoid air cells.<sup>[45]</sup> Schoeff *et al.* determined a 23% prevalence of pulsatile tinnitus in SSDD patients with MRI as the diagnostic modality of choice in these cases.<sup>[45]</sup> Another study by Grewal *et al.* determined a 34% prevalence of pulsatile tinnitus using CT as the diagnostic criteria in cases of SSDD, true diverticula, or dehiscence.<sup>[21]</sup> In these cases, temporal bone CT was specifically recommended for evaluation of patients with pulsatile tinnitus.<sup>[21]</sup> In addition, in cases of venous sinus aneurysm, stenting followed by coil embolization was found to eliminate pulsatile tinnitus symptoms, though larger studies are warranted to support these findings.<sup>[33,44]</sup>

First-line intervention for venous sinus thrombosis involves anti-coagulation therapy. However, in cases where patients are unresponsive to treatment or symptoms worsen over time, surgical intervention through stenting may be warranted, especially if pulsatile tinnitus is also present.<sup>[23,52]</sup> Indications for stenting typically occur as a result of thrombus reformation following thrombectomy and unsuccessful balloon venoplasty (wherein a patient still exhibits stenosis) [Figure 1].<sup>[39,42]</sup> Venous stenting may present as an effective treatment in the management and restoration of venous circulation following thrombosis, which may ultimately correct the PT symptoms as well.<sup>[17]</sup> However, there is currently a void in the literature examining the resolution of PT following treatment of venous sinus thrombosis.

Pulsatile tinnitus is also found in cases of dural arteriovenous fistulas (AVF) or arteriovenous malformations (AVM), where stenting may present as an effective therapy, where concomitant VSS has manifested.<sup>[28,46]</sup> In the case of VSS with AVF, if first-line treatment through transvenous or transarterial embolization cannot be performed, stenting can be utilized to decrease pressure in the draining veins, reduce bleeding, and ultimately prolong the course of management so that future treatment can potentially be performed.<sup>[26,31]</sup> Cases of AVM have shown to be more difficult in management, as a case study by Tsumoto *et al.* found that sigmoid sinus stenting was followed by restenosis, rupture, and bleeding indicating the importance of consistent follow-up in patients with AVM, especially in cases of restenosis.<sup>[51]</sup> The biggest issue, however, is that there are few studies explicitly describing changes in PT following stenting in cases of AVF or AVM.

Another known source of intractable pulsatile tinnitus is arterial supply aneurysms or atherosclerosis. Regarding aneurysms, the aneurysm can be intracranial or extracranial internal carotid artery, but most typically in the petrous portion of the internal carotid artery. Sound is transmitted to the inner ear creating the tinnitus sensation. Direct treatment with endovascular coiling or surgical clipping is the treatment of choice for resolution of symptoms.

### Contraindications

Contraindications for the treatment of pulsatile tinnitus itself vary, however, in the case of venous sinus stenting; contraindications are more related to surgical intervention or the diagnostic modality rather than the specific procedure. Hypoplasia of the contralateral sigmoid sinus or small petrous hemangiomas has been reported by Couloigner *et al.* as a contraindication to surgical intervention due to risk of increased ICP following intervention.<sup>[10]</sup> From the diagnostic perspective, contraindications are present for patients allergic to contrast material in contrast-enhanced CT, in which case MRI becomes the preferred imaging modality to diagnose pulsatile tinnitus.<sup>[53]</sup>

### TECHNIQUE

Before venous sinus stenting, patients are premedicated with antiplatelet therapy such as aspirin and clopidogrel, and the stenotic area is localized in the dural venous sinus using magnetic resonance venography. Stenosis may be unilateral or bilateral with involvement of the dominant lateral sinus or both lateral sinuses, respectively.<sup>[6]</sup> To confirm stenosis presence and severity, a microcatheter is inserted through the common femoral vein into the dural venous sinus with patients under local anesthesia. Venous manometry is used to measure the pressure at different areas, such as the transverse sinus, sigmoid sinus, superior sagittal sinus, and jugular bulb.<sup>[6]</sup> A pressure gradient of 6–8 mmHg is generally used to assess candidacy

for stenting.<sup>[15]</sup> Under general anesthesia, a guidance catheter is directed into the venous sinus, and a dilation balloon is used to enlarge the area of stenosis. A self-expanding stent is inserted through the catheter and positioned across the stenotic region. Venography and manometry are repeated to measure pressure and assess venous drainage after stenting. Patients are observed for any signs of hemorrhage, hematoma, or compression before being discharged and instructed to continue taking aspirin and clopidogrel for 3–6 months followed by aspirin monotherapy.<sup>[5,8,16]</sup>

### OUTCOMES

It has been hypothesized in patients with pulsatile tinnitus with idiopathic intracranial hypertension and sinus stenosis, venous sinus stenting across the stenosis can alter venous flow dynamics and minimize turbulence to resolve pulsatile tinnitus.<sup>[6]</sup> Thus, improvement or complete resolution of tinnitus is the desired outcome of venous sinus stenting for these patients.

To identify studies reporting outcomes from venous sinus stenting in patients with intractable pulsatile tinnitus, the authors queried PubMed using combinations of the keywords: venous sinus stenting, endovascular treatment, and pulsatile tinnitus to identify relevant studies published in English after 2001 and before December 1, 2021. The authors verified selected publications by conducting a supplemental reverse bibliography search from previously published case reports, systematic reviews, and/or meta-analyses. Sixteen observational studies were identified and are listed in Table 1 showing a resolution range from 53% to 100%.<sup>[20,48,3,14,19,37,29]</sup>

**Table 1:** Studies evaluating pulsatile tinnitus following venous sinus stenting.

Study	Year	n	Resolution of pulsatile tinnitus (%)
Donnet <i>et al.</i> <sup>[12]</sup>	2008	5	5/5 (100)
Ahmed <i>et al.</i> <sup>[2]</sup>	2011	17	17/17 (100)
Fields <i>et al.</i> <sup>[16]</sup>	2013	14	11/14 (79)
Radvany <i>et al.</i> <sup>[41]</sup>	2013	12	12/12 (100)
Baomin <i>et al.</i> <sup>[5]</sup>	2014	46	46/46 (100)
Goodwin <i>et al.</i> <sup>[20]</sup>	2014	15	15/15 (100)
Teleb <i>et al.</i> <sup>[48]</sup>	2015	5	4/5 (80)
Boddu <i>et al.</i> <sup>[6]</sup>	2016	29	28/29 (97)
Aguilar-Pérez <i>et al.</i> <sup>[11]</sup>	2017	9	9/9 (100)
Asif <i>et al.</i> <sup>[3]</sup>	2017	19	10/19 (53)
Dinkin <i>et al.</i> <sup>[111]</sup>	2017	13	13/13 (100)
Lenck <i>et al.</i> <sup>[30]</sup>	2017	21	21/21 (100)
El Mekabaty <i>et al.</i> <sup>[14]</sup>	2018	19	18/19 (95)
Funnell <i>et al.</i> <sup>[19]</sup>	2018	7	7/7 (100)
Oh <i>et al.</i> <sup>[37]</sup>	2019	5	5/5 (100)
Kulhari <i>et al.</i> <sup>[29]</sup>	2020	4	4/4 (100)
Total		240	225/240 (94)

Across studies, investigators assessed postoperative clinical outcomes by evaluating for persistence or resolution of pulsatile tinnitus in the immediate postoperative period or at the patient's first postoperative clinic visit. Among included studies, follow-up time ranged from 3 months to 3 years. Following venous sinus stenting, pulsatile tinnitus resolved in 94% of all cases included in [Table 1] (range, 53–100%).

In a recent prospective study by Boddy *et al.*, immediate and complete resolution of pulsatile tinnitus following venous sinus stenting in patients with idiopathic intracranial hypertension and distal transverse sinus stenosis was reported. This study was the only to use the tinnitus handicap inventory (THI), a common patient-reported outcome measure used in clinical trials to assess tinnitus.<sup>[24,34,35]</sup> The authors categorized tinnitus severity based on THI at present, 0 days, and 1, 3, 6, 12, 18, and 24-month follow-up. Notably, subjects reported resolution of tinnitus on the same day of the procedure (day-0).<sup>[6]</sup> There was significant improvement of THI with a mean change THI of 2.7 (95% CI: 2.3–3.1 THI,  $P < 0.001$ ).<sup>[6]</sup>

Our results corroborate those published in prior reviews reporting a high rate of pulsatile tinnitus resolution with venous sinus stenting [summarized in Table 2]. Puffer *et al.* noted that pulsatile tinnitus resolved in 38 of 41 patients (93%) after stent placement. A systematic review by Starke *et al.* reported that resolution of tinnitus at a mean clinical follow-up of 22 months was achieved in 52 of 56 patients, or 92.9% (95% CI 88.7–97.1%).<sup>[47]</sup> In a recent meta-analysis

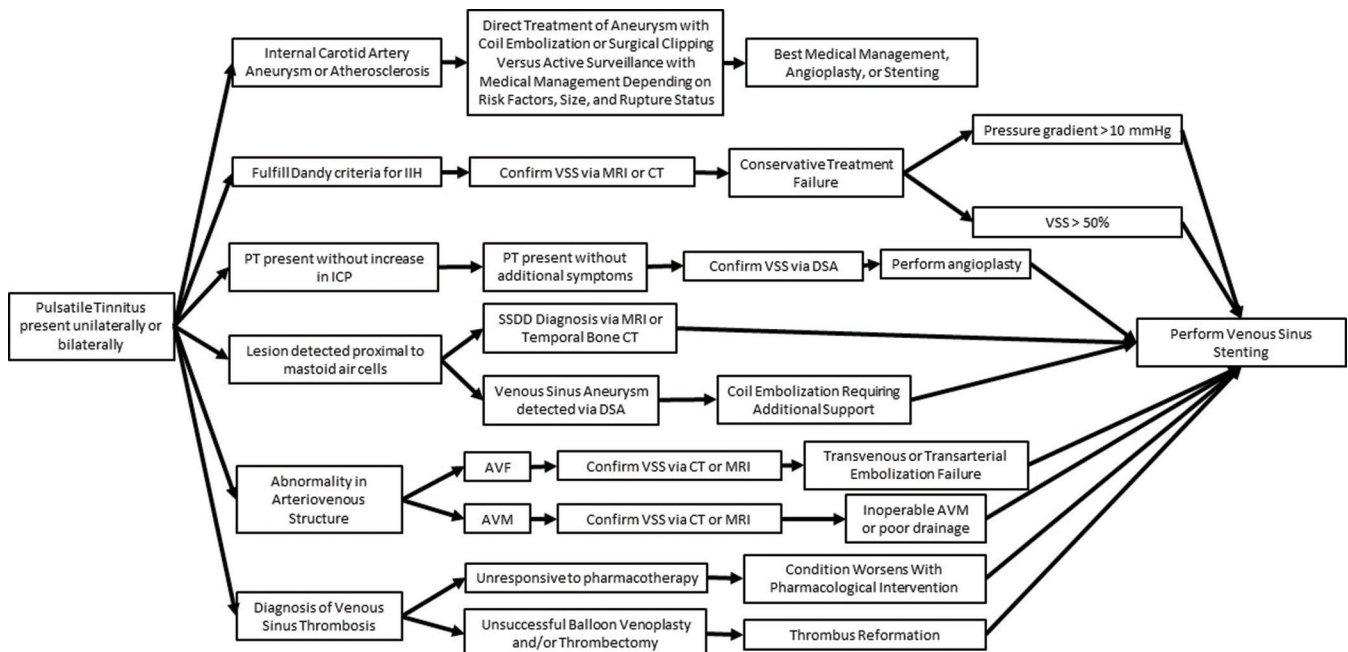
by Nicholson *et al.*, overall improvement in pulsatile tinnitus was seen in 134 of 154 patients, or 90.3% (95% CI 83.8–96.70%), but significant study heterogeneity was reported.<sup>[36]</sup>

Minor complications were uncommon, but those reported include transient focal headache, femoral pseudoaneurysm, and self-limited retroperitoneal hemorrhage.<sup>[11,12,16,30]</sup> Similarly, further operative management was rarely indicated. Fields *et al.* and Radvany *et al.* similarly reported a combined total of three cases which required further management with VP shunt.<sup>[16,41]</sup> Ahmed *et al.* reported that re-stenting was necessary in 6/52 (12%) of cases where 5/6 patients required additional stent placement and the remaining patient required 4 sequential stents.<sup>[2]</sup>

Although there is no randomized data supporting venous sinus stenting for treatment of pulsatile tinnitus at present, a prospective and randomized trial is ongoing at the Weill Medical College of Cornell University (NCT02734576).

**Table 2:** Clinical outcomes reported by systematic reviews and meta-analyses.

Study	Year	No studies	No patients	Pulsatile tinnitus resolution (%)
Puffer <i>et al.</i> <sup>[40]</sup>	2013	15	143	93
Teleb <i>et al.</i> <sup>[49]</sup>	2013	19	207	95
Starke <i>et al.</i> <sup>[47]</sup>	2015	15	185	92.9
Nicholson <i>et al.</i> <sup>[36]</sup>	2019	11	154	90.3



**Figure 1:** Indications for venous sinus stenting in cases of pulsatile tinnitus.

## CONCLUSION

Venous sinus stenting presents as an effective treatment option for patients suffering from pulsatile tinnitus and a concomitant cerebrovascular disease. As solo therapy, venous stenting has successfully reduced, if not outright eliminated pulsatile tinnitus in cases of IIH following conservative treatment failure, VSS where pulsatile tinnitus is present without additional symptoms and venous sinus thrombosis in cases where anticoagulant treatment is unsuccessful in reducing pulsatile tinnitus. Further, in combination therapy with coil embolization, venous stenting was shown to effectively reduce pulsatile tinnitus in patients presenting with venous sinus aneurysm. In cases of inoperable AVM or AVM with poor drainage or if failed embolization in AVF, stenting presents as a potential option to reduce severity of the physiologic issue at hand as well as the pulsatile tinnitus itself.

Although the data regarding resolution of pulsatile tinnitus through stenting is incredibly promising, there are limitations in the interpretation of said data due to smaller study cohorts. This is particularly true in studies describing AVM which are typically single case studies presenting with various complications making it difficult to ascertain the effectiveness of stenting when a patient is high-risk for rupture and restenosis. Although the Dandy criteria are currently utilized for diagnosis of IIH, criteria for determining whether venous stenting is warranted are not entirely clear and a consensus on such criteria has yet to be established. Additional studies are also needed to determine long-term resolution of pulsatile tinnitus in patients with venous sinus thrombosis as the current literature available did not present with sufficient data specifically investigating the connection between stenting in venous sinus thrombosis and pulsatile tinnitus severity (and ultimately resolution). The current data available describe venous sinus stenting as an effective tool for treatment of pulsatile tinnitus from a variety of etiologies, either as first-line therapy or as an adjunct. As such, further studies are indicated to assess the effectiveness in larger cohorts of patients of which pulsatile tinnitus presents as a chief complaint.

### Declaration of patient consent

Patient's consent not required as patients identity is not disclosed or compromised.

### Financial support and sponsorship

Nil.

### Conflicts of interest

There are no conflicts of interest.

## REFERENCES

1. Aguilar-Pérez M, Martínez-Moreno R, Kurre W, Wendl C, Bätzner H, Ganslandt O, *et al.* Endovascular treatment of idiopathic intracranial hypertension: Retrospective analysis of immediate and long-term results in 51 patients. *Neuroradiology* 2017;59:277-87.
2. Ahmed RM, Wilkinson M, Parker GD, Thurtell MJ, Macdonald J, McCluskey PJ, *et al.* Transverse sinus stenting for idiopathic intracranial hypertension: A review of 52 patients and of model predictions. *AJNR Am J Neuroradiol* 2011;32:1408-14.
3. Asif H, Craven CL, Siddiqui AH, Shah SN, Matloob SA, Thorne L, *et al.* Idiopathic intracranial hypertension: 120-day clinical, radiological, and manometric outcomes after stent insertion into the dural venous sinus. *J Neurosurg* 2018;129:723-31.
4. Baomin L, Xiangyu C, Xinfeng L, Sheng L, Jun W, Yongping L, *et al.* Interventional diagnosis and treatment of vasculogenic pulsatile tinnitus. *J Otol* 2014;9:7-15.
5. Baomin L, Yongbing S, Xiangyu C. Angioplasty and stenting for intractable pulsatile tinnitus caused by dural venous sinus stenosis: A case series report. *Otol Neurotol* 2014;35:366-70.
6. Boddu S, Dinkin M, Suurna M, Hannsgen K, Bui X, Patsalides A. Resolution of pulsatile tinnitus after venous sinus stenting in patients with idiopathic intracranial hypertension. *PLoS One* 2016;11:e0164466.
7. Bussiere M, Falero R, Nicolle D, Proulx A, Patel V, Pelz D. Unilateral transverse sinus stenting of patients with idiopathic intracranial hypertension. *AJNR Am J Neuroradiol* 2010;31:645-50.
8. Cappuzzo JM, Hess RM, Morrison JE, Davies JM, Snyder KV, Levy EI, *et al.* Transverse venous stenting for the treatment of idiopathic intracranial hypertension, or pseudotumor cerebri. *Neurosurg Focus* 2018;45:E11.
9. Comay Y, Zvenigorodsky V, Borodetsky V, Star M, Ben-Zion J, Shelef I, *et al.* Cerebral venous stenting for pulsatile tinnitus after unsuccessful jugular ligation: Case report and literature review. *Ear Nose Throat J* 2020.
10. Couloigner V, Grayeli AB, Bouccara D, Julien N, Sterkers O. Surgical treatment of the high jugular bulb in patients with Meniere's disease and pulsatile tinnitus. *Eur Arch Otorhinolaryngol* 1999;256:224-9.
11. Dinkin MJ, Patsalides A. Venous sinus stenting in idiopathic intracranial hypertension: Results of a prospective trial. *J Neuroophthalmol* 2017;37:113-21.
12. Donnet A, Metellus P, Levrier O, Mekkaoui C, Fuentes S, Dufour H, *et al.* Endovascular treatment of idiopathic intracranial hypertension: Clinical and radiologic outcome of 10 consecutive patients. *Neurology* 2008;70:641-7.
13. Ducruet AF, Crowley RW, McDougall CG, Albuquerque FC. Long-term patency of venous sinus stents for idiopathic intracranial hypertension. *J Neurointerv Surg* 2014;6:238-42.
14. El Mekabaty A, Obuchowski NA, Luciano MG, John S, Chung CY, Moghekar A, *et al.* Predictors for venous sinus stent retreatment in patients with idiopathic intracranial hypertension. *J Neurointerv Surg* 2017;9:1228-32.
15. Fargen KM, Liu K, Garner RM, Greenway GP, Wolfe SQ,

- Crowley RW. Recommendations for the selection and treatment of patients with idiopathic intracranial hypertension for venous sinus stenting. *J Neurointerv Surg* 2018;10:1203-8.
16. Fields JD, Javedani PP, Falardeau J, Nesbit GM, Dogan A, Helseth EK, et al. Dural venous sinus angioplasty and stenting for the treatment of idiopathic intracranial hypertension. *J Neurointerv Surg* 2013;5:62-8.
  17. Formaglio M, Catenoiu H, Tahon F, Manguiere F, Vighetto A, Turjman F. Stenting of a cerebral venous thrombosis. *J Neuroradiol* 2010;37:182-4.
  18. Friedman DI, Jacobson DM. Diagnostic criteria for idiopathic intracranial hypertension. *Neurology* 2002;59:1492-5.
  19. Funnell JP, Craven CL, Thompson SD, D'Antona L, Chari A, Thorne L, et al. Pulsatile versus non-pulsatile tinnitus in idiopathic intracranial hypertension. *Acta Neurochir (Wien)* 2018;160:2025-9.
  20. Goodwin CR, Elder BD, Ward A, Orkoulas-Razis D, Kosztowski TA, Hoffberger J, et al. Risk factors for failed transverse sinus stenting in pseudotumor cerebri patients. *Clin Neurol Neurosurg* 2014;127:75-8.
  21. Grewal AK, Kim HY, Comstock RH 3<sup>rd</sup>, Berkowitz F, Kim HJ, Jay AK. Clinical presentation and imaging findings in patients with pulsatile tinnitus and sigmoid sinus diverticulum/dehiscence. *Otol Neurotol* 2014;35:16-21.
  22. Grierson KE, Bou-Haidar P, Dumper J, Fagan PA. The assessment of pulsatile tinnitus-a systematic review of underlying pathologies and modern diagnostic approaches. *Aust J Otolaryngol* 2018;1:1-16.
  23. Haghighi AB, Mahmoodi M, Edgell RC, Cruz-Flores S, Ghanaati H, Jamshidi M, et al. Mechanical thrombectomy for cerebral venous sinus thrombosis: A comprehensive literature review. *Clin Appl Thromb Hemost* 2014;20:507-15.
  24. Hall DA, Haider H, Szczepek AJ, Lau P, Rabau S, Jones-Diette J, et al. Systematic review of outcome domains and instruments used in clinical trials of tinnitus treatments in adults. *Trials* 2016;17:270.
  25. Henry JA, Dennis KC, Schechter MA. General review of tinnitus: Prevalence, mechanisms, effects, and management. *J Speech Lang Hear Res* 2005;48:1204-35.
  26. Hirata E, Higashi T, Iwamuro Y, Watanabe Y, Ando M, Arakawa Y, et al. Angioplasty and stent deployment in acute sinus thrombosis following endovascular treatment of dural arteriovenous fistulae. *J Clin Neurosci* 2009;16:725-7.
  27. Hofmann E, Behr R, Neumann-Haefelin T, Schwager K. Pulsatile tinnitus: Imaging and differential diagnosis. *Dtsch Arztebl Int* 2013;110:451-8.
  28. Kircher ML, Leonetti JP, Marzo SJ, Standing B. S205-neuroradiologic assessment of pulsatile tinnitus. *Otolaryngol Head Neck Surg* 2017;139 Suppl 2:P144.
  29. Kulhari A, He M, Fourcand F, Singh A, Zacharatos H, Mehta S, et al. Safety and clinical outcomes after transverse venous sinus stenting for treatment of refractory idiopathic intracranial hypertension: Single center experience. *J Vasc Interv Neurol* 2020;11:6-12.
  30. Lenck S, Vallée F, Labeyrie MA, Touitou V, Saint-Maurice JP, Guillonnet A, et al. Stenting of the lateral sinus in idiopathic intracranial hypertension according to the type of stenosis. *Neurosurgery* 2017;80:393-400.
  31. Liebig T, Henkes H, Brew S, Miloslavski E, Kirsch M, Kuhne D. Reconstructive treatment of dural arteriovenous fistulas of the transverse and sigmoid sinus: Transvenous angioplasty and stent deployment. *Neuroradiology* 2005;47:543-51.
  32. Mathis JM, Mattox D, Malloy P, Zoarski G. Endovascular treatment of pulsatile tinnitus caused by dural sinus stenosis. *Skull Base Surg* 1997;7:145-50.
  33. Mehanna R, Shaltoni H, Morsi H, Mawad M. Endovascular treatment of sigmoid sinus aneurysm presenting as devastating pulsatile tinnitus. A case report and review of literature. *Interv Neuroradiol* 2010;16:451-4.
  34. Newman CW, Jacobson GP, Spitzer JB. Development of the tinnitus handicap inventory. *Arch Otolaryngol Head Neck Surg* 1996;122:143-8.
  35. Newman CW, Sandridge SA, Bolek L. Development and psychometric adequacy of the screening version of the tinnitus handicap inventory. *Otol Neurotol* 2008;29:276-81.
  36. Nicholson P, Brinjikji W, Radovanovic I, Hilditch CA, Tsang AC, Krings T, et al. Venous sinus stenting for idiopathic intracranial hypertension: A systematic review and meta-analysis. *J Neurointerv Surg* 2019;11:380-5.
  37. Oh SJ, Kim D, Lee JI, Ko JK, Choi SW, Kong SK, et al. Transvenous stent-assisted coil embolization for management of dehiscent high jugular bulb with tinnitus and contralateral hypoplastic venous sinuses. *Otol Neurotol* 2019;40:1253-9.
  38. Patsalides A, Santillan A, Sundararajan SH, Michael M, Suurna M, Alexiades G. Venous sinus stenting for the treatment of isolated pulsatile tinnitus: Results of a prospective trial. *Interv Neuroradiol* 2020.
  39. Prasad RS, Michaels LA, Roychowdhury S, Craig V, Sorrell A, Schonfeld S. Combined venous sinus angioplasty and low-dose thrombolytic therapy for treatment of hemorrhagic transverse sinus thrombosis in a pediatric patient. *J Pediatr Hematol Oncol* 2006;28:196-9.
  40. Puffer RC, Mustafa W, Lanzino G. Venous sinus stenting for idiopathic intracranial hypertension: A review of the literature. *J Neurointerv Surg* 2013;5:483-6.
  41. Radvany MG, Solomon D, Nijjar S, Subramanian PS, Miller NR, Rigamonti D, et al. Visual and neurological outcomes following endovascular stenting for pseudotumor cerebri associated with transverse sinus stenosis. *J Neuroophthalmol* 2013;33:117-22.
  42. Raychev R, Tatshima S, Rastogi S, Balgude A, Yafeh B, Saver JL, et al. Successful treatment of extensive cerebral venous sinus thrombosis using a combined approach with Penumbra aspiration system and Solitaire FR retrieval device. *J Neurointerv Surg* 2014;6:e32.
  43. Russell EJ, de Michaelis BJ, Wiet R, Meyer J. Objective pulse-synchronous "essential" tinnitus due to narrowing of the transverse dural venous sinus. *Int Tinnitus J* 1995;1:127-37.
  44. Sanchez TG, Murao M, de Medeiros IR, Kii M, Bento RF, Caldas JG, et al. A new therapeutic procedure for treatment of objective venous pulsatile tinnitus. *Int Tinnitus J* 2002;8:54-7.
  45. Schoeff S, Nicholas B, Mukherjee S, Kesser BW. Imaging prevalence of sigmoid sinus dehiscence among patients with and without pulsatile tinnitus. *Otolaryngol Head Neck Surg* 2014;150:841-6.
  46. Sonmez G, Baskim CC, Ozturk E, Gungor A, Kizilkaya E.

- Imaging of pulsatile tinnitus: A review of 74 patients. *Clin Imaging* 2007;31:102-8.
47. Starke RM, Wang T, Ding D, Durst CR, Crowley RW, Chalouhi N, *et al.* Endovascular treatment of venous sinus stenosis in idiopathic intracranial hypertension: Complications, neurological outcomes, and radiographic results. *Sci World J* 2015;2015:140408.
  48. Teleb MS, Cziep ME, Issa M, Lazzaro M, Asif K, Hong SH, *et al.* Stenting and angioplasty for idiopathic intracranial hypertension: A case series with clinical, angiographic, ophthalmological, complication, and pressure reporting. *J Neuroimaging* 2015;25:72-80.
  49. Teleb MS, Cziep ME, Lazzaro MA, Gheith A, Asif K, Remler B, *et al.* Idiopathic intracranial hypertension. A systematic analysis of transverse sinus stenting. *Interv Neurol* 2013;2:132-43.
  50. Trivelato FP, Araujo JF, dos Santos Silva R, Rezende MT, Ulhoa AC, Castro GD. Endovascular treatment of pulsatile tinnitus associated with transverse sigmoid sinus aneurysms and jugular bulb anomalies. *Interv Neuroradiol* 2015;21:548-51.
  51. Tsumoto T, Miyamoto T, Shimizu M, Inui Y, Nakakita K, Hayashi S, *et al.* Restenosis of the sigmoid sinus after stenting for treatment of intracranial venous hypertension: Case report. *Neuroradiology* 2003;45:911-5.
  52. Waldvogel D, Mattle HP, Sturzenegger M, Schroth G. Pulsatile tinnitus-a review of 84 patients. *J Neurol* 1998;245:137-42.
  53. Weissman JL, Hirsch BE. Imaging of tinnitus: A review. *Radiology* 2000;216:342-9.
  54. Xu K, Yu T, Yuan Y, Yu J. Current status of the application of intracranial venous sinus stenting. *Int J Med Sci* 2015;12:780-9.

**How to cite this article:** Fiani B, Kondilis A, Doan T, Runnels J, Fiani NJ, Sarno E. Venous sinus stenting for intractable pulsatile tinnitus: A review of indications and outcomes. *Surg Neurol Int* 2021;12:81.