



Case Report


Surgical management of a rare myxopapillary ependymoma of the gluteal region: A case report

Brian V. Lien^{1*}, Nolan J. Brown^{1*}, Alexander S. Himstead¹, Benjamin Z. Ball¹, Aileen Guillen¹, Nischal Acharya¹, Chen Yi Yang¹, Ronald Sahyouni², Mari Perez-Rosendahl³, Russell N. Stitzlein⁴, Frank P. K. Hsu¹

¹Department of Neurological Surgery, University of California, UCI Medical Center, Orange, ²Department of Neurosurgery, UC San Diego School of Medicine, La Jolla, Departments of ³Pathology, ⁴Orthopedic Surgery, University of California, UCI Medical Center, Orange, California, United States.

*These authors contributed equally to this work.

E-mail: Brian V. Lien - lienbv@hs.uci.edu; Nolan J. Brown - nolanb@hs.uci.edu; Alexander S. Himstead - ahimstea@hs.uci.edu Benjamin Z. Ball - ballb@hs.uci.edu; Aileen Guillen - aileengg@hs.uci.edu; Nischal Acharya - nischala@hs.uci.edu; *Chen Yi Yang - yangcy2@hs.uci.edu; Ronald Sahyouni - sahyouniron@gmail.com; Mari Perez-Rosendahl - mperezro@hs.uci.edu; Russell N. Stitzlein - rstitzle@uci.edu; Frank P. K. Hsu - fpkhsu@hs.uci.edu



*Corresponding author:

Frank P. K. Hsu, MD, PhD,
Department of Neurological
Surgery, University of
California, UCI Medical Center,
Orange, California, United
States.

fpkhsu@hs.uci.edu

Received : 27 October 2020

Accepted : 25 February 2021

Published : 30 March 2021

DOI

10.25259/SNI_768_2020

Quick Response Code:



ABSTRACT

Background: Ependymomas are rare tumors originating from neuroepithelial cells lining the wall of the ventricles or central canal of the spinal cord. While these tumors mainly occur within the central nervous system (CNS), there are occasional reports in children and young adult patients with a primary tumor occurrence outside of the CNS. Ependymomas of the sacrococcygeal region have been infrequently described in the literature with no standard of care established. We present a case report and review of the literature regarding this rare entity.

Case Description: A 24-year-old woman presented with right gluteal pain worsened by sitting and a palpable soft tissue mass of the sacrococcygeal region. Magnetic resonance imaging revealed a 3.7 cm cystic mass centered in the right gluteal region. She underwent a biopsy at an outside institution, with histology revealing myxopapillary ependymoma. The patient was referred to our hospital and underwent an interdisciplinary neurosurgical and orthopedic oncology en bloc resection of the ependymoma, which intraoperatively appeared to originate from the coccygeal nerve.

Conclusion: In the present report, the authors demonstrate that a myxopapillary ependymoma may present as an isolated gluteal mass attached to the coccygeal nerve, without frank CNS involvement. Furthermore, an interdisciplinary approach to surgical resection of this lesion appears to represent an effective treatment modality.

Keywords: Extra central nervous system ependymoma, Extraneural ependymoma, Gluteal ependymoma, Rare ependymoma case, Rare myxopapillary ependymoma

INTRODUCTION

Ependymomas occurring outside of the central nervous system (CNS), otherwise known as extra CNS ependymomas, are extremely uncommon and only occasionally described in the literature, with most reports featuring only one to two cases per institution.^[49] These tumors occur most often in children and young adults and have been described as arising from various locations including the lung, ovary, and sacrococcygeal region (the most common extra CNS site).^[49] Many of these extra CNS ependymomas are myxopapillary (Grade I) ependymomas that are thought to originate from the ependymal cell lining of the central canal of the spinal cord or the ependymal cell clusters of the filum terminale.^[36] Most patients with extra CNS ependymoma of the sacrococcygeal region,

This is an open-access article distributed under the terms of the Creative Commons Attribution-Non Commercial-Share Alike 4.0 License, which allows others to remix, tweak, and build upon the work non-commercially, as long as the author is credited and the new creations are licensed under the identical terms.

©2021 Published by Scientific Scholar on behalf of Surgical Neurology International

including the patient described in this case report, present with a palpable mass upon pelvic or rectal examination.^[48] Furthermore, many patients will exhibit symptoms due to sacral nerve damage, such as bladder dysfunction, bowel dysfunction, decrease ankle reflex, or decreased anal sphincter tone.^[48] Due to the rarity of extra CNS ependymomas, there is no standard of care established, though they are commonly treated with surgical excision and occasionally radiotherapy for recurrent lesions.^[2,49] Here, we present a surgical case report for an extra CNS myxopapillary ependymoma presenting as a gluteal mass and a systematic review of the literature.

METHODS

In January 2021, we performed a systematic review of three literature databases to identify previous reports of gluteal myxopapillary ependymoma. No time restriction was applied to allow for a comprehensive search. The following search terms were used: (gluteal myxopapillary ependymoma) OR (sacroccoccygeal myxopapillary ependymoma) OR (coccygeal myxopapillary ependymoma). There were a total of 302 publications: 131 from PubMed, 87 results from Scopus, and 84 results from Web of Science. There were 211 publications after deletion of duplicates. We included all cases of primary myxopapillary ependymoma presenting as a gluteal mass confirmed to have no association with the CNS. Studies were excluded if they were not in English or not journal articles (e.g., conference abstracts).

CASE REPORT

A 24-year-old, otherwise healthy female with a strong family history of cancer (including glioma) presented with gradually worsening right gluteal pain exacerbated by sitting and an enlarging gluteal mass. She denied any back pain, leg pain, focal motor weakness, paresthesias, or bowel/bladder dysfunction. Physical exam revealed no focal neurological deficits. Upon inspection of the buttocks, a mass was observable on the right intergluteal cleft and tender to palpation. The patient underwent a biopsy at an outside institution, which revealed myxopapillary ependymoma, before being referred to our hospital.

Work-up proceeded with full neuro-axis imaging including magnetic resonance imaging (MRI) of the brain and MRI/computed tomography myelograms of the cervical, thoracic, and lumbar spine, which were all unremarkable. Pelvic MRI demonstrated a T2 hyperintense cystic lesion with enhancing septa in the right paramedian gluteal region that measured 3.7 × 1.8 × 3.3 cm. The lesion extended from the posterior cortex of the second coccygeal segment body to the right gluteal cleft skin. There was no evidence of any intrinsic spinal cord component or definite CSF connection to the central canal [Figure 1].

An interdisciplinary neurosurgical and orthopedic oncology en bloc resection was planned. Intraoperatively, it was noted that the lesion was attached to the left coccygeal nerve. A 2.0 silk tie was secured around the base of the left coccygeal nerve, and it was coagulated and sharply divided ~5 mm proximal to the silk tie. Kerrison rongeurs were used to remove a portion of the coccyx which appeared to be infiltrated with tumor. Intraoperative frozen pathology was consistent with myxopapillary ependymoma with negative margins [Figure 2]. The patient had an uneventful postoperative clinical course. Her case was presented at a multidisciplinary tumor board wherein it was determined that the patient would not benefit from adjuvant treatment and instead should be monitored with serial imaging. At 6 months postoperative follow-up, repeat lumbosacral and pelvic MRIs did not reveal evidence of tumor recurrence or metastatic disease [Figure 3].

DISCUSSION

Ependymomas are distinct histopathological tumors of the CNS that affects both children and adults.^[37] These tumors are classified into the following subtypes based on the 2016 World Health Organization Classification of Tumors of the CNS:

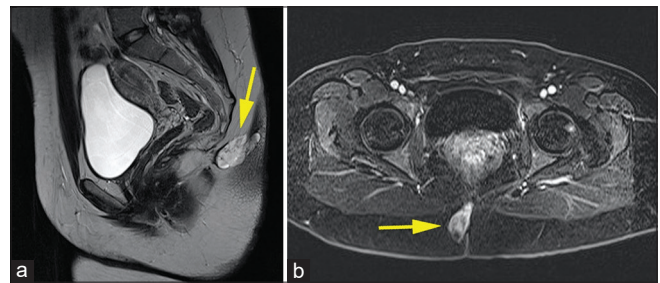


Figure 1: Preoperative magnetic resonance imaging (MRI) imaging. MRI of pelvis demonstrating soft tissue mass centered within the right hemigluteal region. Sagittal T2-weighted image (a) and axial T1-weighted postcontrast image (b) is shown with arrowheads indicating location of the mass.

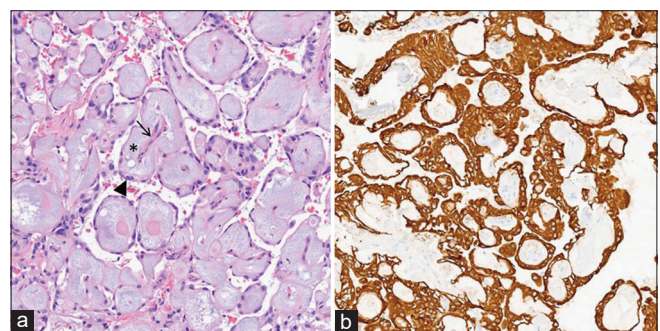


Figure 2: Myxopapillary ependymoma. The tumor is composed of many papillary structures formed by vessels (arrow) encircled by basophilic myxoid material (asterisk) and collars of cuboidal tumor cells (arrowhead) (a) which demonstrate strong GFAP positivity (b).

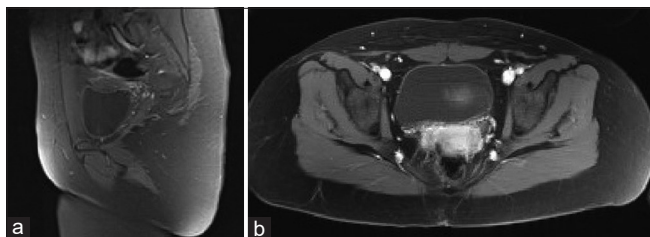


Figure 3: Postoperative magnetic resonance imaging (MRI) imaging. MRI of pelvis taken 6 months postoperative demonstrating no evidence of tumor recurrence or metastatic disease to the pelvis. Sagittal T1-weighted postcontrast image (a) and axial T1-weighted postcontrast image (b) shown above.

subependymoma (grade I), myxopapillary ependymoma (Grade I), ependymoma (Grade II), ependymoma RELA fusion positive (Grade II or III), and anaplastic ependymoma (Grade III).^[15] Ependymomas in adults most commonly occur in the spine (46%), whereas ependymomas in children are more likely to be found intracranially (90%), especially in the posterior fossa.^[16] Ependymomas of the brain and spinal cord are typically chemotherapy resistant, thus the current standard of care consists of resection and radiotherapy.^[32,37] These tumors may be found outside of the CNS as primary tumors or metastases, though both situations are rare.^[27,46] It has been hypothesized that ependymal cells in the filum terminale or heterotopic ependymal cell clusters may explain the occurrence of extra CNS ependymomas.^[28,36]

In our literature review, we found 38 studies that described 78 unique cases of myxopapillary ependymoma occurring in the sacrococcygeal region without extension into the CNS [Table 1]. These were comprised of 35 case reports involving 1 or 2 patients,^[1,3,4,6-14,17-19,21-26,28,31,33-35,38-41,43,45,47,48,50] and 3 case series involving 3–32 patients.^[5,20,42] There were no comparative trials. Four cases were recurrences and the remaining 74 were new-onset tumors. Excluding the case series by Helwig and Stern (which did not specify exact presentations of each patient),^[20] the most common presenting symptoms were as follows: painless mass (47.8%), enlarging mass (17.4%), painful enlarging mass (10.9%), sensory or motor neuropathy (8.7%), mass with discharge (6.5%), rectal tenesmus and constipation (4.3%), back and hip pain (2.2%), and perirectal discharge only with no mass (2.2%). One patient with a painful mass and purulent drainage presented with a large patch of darkened skin overlying the mass.^[50] While average age at diagnosis was 22 years old, the age ranged from 8 months to 54 years, which suggests this may be considered in the differential diagnosis of any gluteal mass in infants and older adults. Of the 78 patients whose gender was reported, 46 were female (59.0%).

As demonstrated by our literature review, the exact presentation of sacrococcygeal ependymomas is variable. Given their location and propensity for drainage, they are

frequently misdiagnosed as the more frequently encountered pilonidal cyst.^[35] Rectal tenesmus and constipation were reported in cases by Cappabianca *et al.* and Wani *et al.* due to compression of the distal rectum by the mass, which narrowed the rectal lumen.^[8,48] Quraishi *et al.* reported a case series of 6 total patients where myxopapillary ependymomas led to osteolytic destruction of the sacrum.^[38] Two of these cases were extra CNS lesions (while the other four originated from the spinal cord), and neurological deficits were reported in each case. Specifically, one patient experienced saddle anesthesia, mild weakness with right hip flexion, and dermatomal paresthesia over the right lower extremity, while the other sustained sensory loss below the bilateral knees.^[38] Cihangiroglu *et al.* and Gupta *et al.* also reported extra CNS lesions that invaded the sacrum and caused left lower extremity pain, weakness, and dermatomal paresthesias in one case, and progressive weakness in bilateral lower extremities with bowel and bladder incontinence in the other.^[11,19]

We identified 13 cases of recurrence or metastasis out of 78 total cases (16.7%) in the literature. Notably, this number may be artificially low as recurrence typically occurs up to 20 years after initial resection, and several studies reported follow-up of 6 months or less.^[13,22,23,31,39] Metastasis rate was previously estimated at up to 20%, and metastatic lesions have been reported in the lungs, pleura, bones, regional subcutaneous tissues, and inguinal lymph nodes.^[20,23,26,30] Metastatic and recurrent disease are associated with poor outcomes; a case series by Helwig and Stern reported the only three mortalities after resection (out of 23 patients with long-term follow-up) were caused by pulmonary and pleural metastatic disease or chemotherapy toxicity for aggressive treatment of intractable local disease recurrence and inguinal lymph node metastases.^[20] The fourth patient had recurrence ultimately leading to marked pulmonary, femoral, and pelvic metastases after a disease-free period of 10 years. One of these patients had pulmonary metastases at time of initial diagnosis. The authors did not identify any clinical or histopathological indications of recurrence or metastasis. These statistics highlight the importance of early detection and close imaging surveillance after surgery to evaluate for recurrent disease.

The primary means of management for sacrococcygeal myxopapillary ependymoma is complete surgical resection.^[19,31] This entails excision of the mass along with neighboring sacrum or coccyx if they are involved within the tumor. A case series by Aktuğ *et al.* suggests a role for coccygectomy to prevent recurrence.^[2] They report no recurrences in 4 patients who underwent excision with coccygectomy compared to 5 recurrences out of 7 in patients who underwent simple excision.^[2] Further evidence supporting coccygectomy is provided by Quraishi *et al.*, who reported no recurrences after resection with coccygectomy

Table 1: Extra CNS myxopapillary ependymomas presenting as gluteal mass.

Authors	Cases	Age(s)	Sex	Mass location	Recurrence (Yes/No)	Histological and genetic findings	Presenting symptoms	Physical exam findings	Treatment	Outcome	Complications	Further follow-up (months)
Kelly <i>et al.</i>	1	37	M	Intergluteal cleft	No	Subcutaneous sacrococcygeal myxopapillary ependymoma	Enlarging mass with periodical discharge	Swelling of superior aspect of right intergluteal cleft (ovoid and cystic in nature) measuring 4 cm	Surgery with coccygectomy	GTR	NA	16
Batich <i>et al.</i>	1	30	M	Intergluteal cleft (inferior coccyx)	No	Subcutaneous sacrococcygeal myxopapillary ependymoma/ GFAP+, EMA+, CDX-, CTNNA1 truncation	Asymptomatic without back pain, discomfort, gait instability, bladder, or bowel changes	NA	Surgery with coccygectomy	NA	Recurrence, metastasis to left lung and internal iliac lymph nodes	NA
Amin <i>et al.</i>	1	8	F	Intergluteal cleft (inferior dorsal aspect of coccyx)	No	Subcutaneous sacrococcygeal myxopapillary ependymoma/ GFAP+, EMA-, AE1/AE3-	Enlarging, painful tissue over coccyx	1 cm palpable mass in intergluteal cleft, normal alpha fetal protein, low lactate dehydrogenase	Surgery with coccygectomy	GTR	NA	6
Schiavello <i>et al.</i>	4	4	F	NA	No	Subcutaneous sacrococcygeal myxopapillary ependymoma	Mass	NA	Surgery with coccygectomy	GTR	Recurrence, neoplastic iliac thrombosis, lung, broad ligament, retroperitoneal/ mediastinal adenopathy	180
		16	M	NA	No	Subcutaneous sacrococcygeal myxopapillary ependymoma	Mass	NA	Surgery	Marginal	NA	132
		17	F	NA	No	Subcutaneous sacrococcygeal myxopapillary ependymoma	Mass	NA	Surgery	Marginal	Inguinal adenopathy	396
		17	F	Intergluteal cleft (inferior tip of coccyx)	Yes	Subcutaneous sacrococcygeal myxopapillary ependymoma	Severe back pain, severe hip pain	NA	Surgery	NA	Lymphadenopathy secondary to sacrococcygeal mass	180

(Contd...)

Table 1: (Continued)

Authors	Cases	Age(s)	Sex	Mass location	Recurrence (Yes/No)	Histological and genetic findings	Presenting symptoms	Physical exam findings	Treatment	Outcome	Complications	Furthest follow-up (months)
Roger et al.	1	12	F	Intergluteal cleft	No	Subcutaneous sacrococcygeal myxopapillary ependymoma	Painful mass while lying down	Unremarkable neurological exam	Surgery	NA	None	12
McEachron et al.	1	32	F	Intergluteal cleft	No	Subcutaneous sacrococcygeal myxopapillary ependymoma/ GFAP+, CD-99+, CD-56+	Mass	Area of swelling left to natal cleft measuring 4x4 cm, mild blanching erythema at the skin overlying the mass, no fluctuance or purulence, no pilonidal pits	Surgery	GTR	NA	NA
Dogan et al.	1	9	F	Intergluteal cleft (midline of sacrococcygeal region)	No	Subcutaneous sacrococcygeal myxopapillary ependymoma	Sacral mass	Palpable soft tissue mass, unremarkable neurological exam	Surgery	GTR	NA	6
Zaidi et al.	1	30	F	Left gluteus	No	Subcutaneous sacrococcygeal myxopapillary ependymoma/ GFAP+, S-100+, vimentin+, CAM5.2-, EMA-, 10x10 cm area carcinoembryonic antigen -, CD34-, black synaptophysin-	Enlarging mass for 2 years, pain and purulent discharge, overlying	NA	1: chemotherapy 2: surgery with coccygectomy	GTR	NA	NA
Alexiou et al.	1	13	F	Intergluteal Cleft (sacrum)	No	Subcutaneous sacrococcygeal myxopapillary ependymoma/ GFAP+, S-100+	Enlarging mass with periodical discharge	NA	Surgery + radiotherapy	GTR	NA	8

(Contd...)

Table 1: (Continued)

Authors	Cases	Age(s)	Sex	Mass location	Recurrence (Yes/No)	Histological and genetic findings	Presenting symptoms	Physical exam findings	Treatment	Outcome	Complications	Furthest follow-up (months)
Lee et al.	1	25	F	Intergluteal cleft	No	Subcutaneous sacrococcygeal myxopapillary ependymoma	Enlarging mass over 2 years that became tender over coccyx	Solid, mildly tender, mobile mass over coccyx measuring 2x3 cm, well circumscribed proximally but not distally on palpation, unremarkable neurological examination	Surgery	GTR	NA	24
Wani et al.	1	60	F	Intergluteal cleft (coccyx)	No	Subcutaneous sacrococcygeal myxopapillary ependymoma	Rectal tenesmus and constipation	Reduced rectal lumen, unremarkable neurological examination	Surgery	GTR	NA	NA
Johnson et al.	1	37	F	Intergluteal cleft (inferior portion of coccyx)	No	Subcutaneous sacrococcygeal myxopapillary ependymoma/GEAP+, S-100, epithelial and neural and neuroendocrine negative	Enlarging mass over 6 months, no incontinence	NA	1st: surgery 2nd: surgery + radiotherapy	GTR	Right iliac fossa pain, pelvic mass, enlarged right internal iliac lymph node	6
Akplot et al.	1	7	M	Intergluteal cleft (midline of coccyx)	No	Subcutaneous sacrococcygeal myxopapillary ependymoma/GEAP+, Vimentin +, keratin-, S-100-	2 month history of hyperemic change	Firm, subcutaneous, mobile, painless mass, no presacral extension detected with rectal examination, unremarkable neurologic exam	Surgery	GTR	NA	M

(Contd...)

Authors	Cases	Age(s)	Sex	Mass location	Recurrence (Yes/No)	Histological and genetic findings	Presenting symptoms	Physical exam findings	Treatment	Outcome	Complications	Furthest follow-up (months)
Rao <i>et al.</i>	1	1.25	F	Sacral region	Yes	Subcutaneous sacrococcygeal myxopapillary ependymoma/ GFAP+, S-100+, actin-, cytokeratin-, MIC-2-, synaptophysin-, chromogranin-	Large sacral mass	Mass posterior to anal verge extending into coccyx and lower sacral pieces measuring 8x10 cm, variegated consistency, mass felt in retrorectal region with rectal exam, upper mass could not be felt in retrorectal space, spinal exam normal, no involvement of CNS, or bony erosion of sacrum	1: chemotherapy 2: surgery + chemotherapy	GTR	NA	2
Grubnic <i>et al.</i>	1	8	M	Perianal region of left gluteus	No	Subcutaneous sacrococcygeal myxopapillary ependymoma	Left buttock lump and discomfort riding bicycle	Small mobile mass in the perianal region of left buttock with overlying erythema	Surgery with coccygectomy	GTR	NA	NA
Chung <i>et al.</i>	1	54	F	Intergluteal cleft	No	Subcutaneous sacrococcygeal myxopapillary ependymoma/ GFAP+	Enlarging painful mass and discomfort while sitting	NA	Surgery	GTR	NA	NA

(Contd...)

Table 1: (Continued)

Authors	Cases	Age(s)	Sex	Mass location	Recurrence (Yes/No)	Histological and genetic findings	Presenting symptoms	Physical exam findings	Treatment	Outcome	Complications	Furthest follow-up (months)
Sawyer <i>et al.</i>	1	13	F	Intergluteal cleft (posterior sacral region, right of midline)	No	Subcutaneous sacrococcygeal myxopapillary ependymoma/ GFAP+, Alcian blue+, S-100+, vimentin-	Enlarging mass over 4 days	Small tender mass, purplish color	Surgery	GTR	NA	NA
Ilhan <i>et al.</i>	1	8	M	Intergluteal cleft (coccyx)	No	Subcutaneous sacrococcygeal myxopapillary ependymoma/ GFAP+, S-100-	Enlarging mass over 3 months	Subcutaneous 3 cm mass over coccyx, unremarkable neurologic and physical exams	Surgery	GTR	NA	20
Kline <i>et al.</i>	2	0.67	F	Intergluteal cleft (posterior Sacrum)	No	Subcutaneous sacrococcygeal myxopapillary ependymoma	2 cm cyst-like spherical mass	Mass located in retrococcygeal region with attachment to coccyx. No attachment to vertebral canal thecal sac	Surgery	Death	Metastasis (bilateral inguinal lymph node excision, 2 years later peritoneum metastasis)	24
		32	F	Superior to intergluteal cleft	No	Subcutaneous sacrococcygeal myxopapillary ependymoma	2 cm small firm nodule	NA	Surgery	NA	Recurrence after 3 years (repeat excision), recurrence following surgery at 10 and 14 months	20
Botti <i>et al.</i>	1	10.42	NA	Left buttock	No	Subcutaneous sacrococcygeal myxopapillary ependymoma/ GFAP+, S-100+	7 cm mass	NA	Surgery	GTR	NA	NA

(Contd...)

Table 1: (Continued)

Authors	Cases	Age(s)	Sex	Mass location	Recurrence (Yes/No)	Histological and genetic findings	Presenting symptoms	Physical exam findings	Treatment	Outcome	Complications	Furthest follow-up (months)
Serour <i>et al.</i>	1	8	M	Intergluteal cleft (inferior portion of coccyx)	No	Subcutaneous sacrococcygeal myxopapillary ependymoma/ GFAP+, S-100-	Enlarging mass to 3 cm	No history of inflammation or drainage. Unremarkable neurologic, physical exam, and rectal exams	Surgery with partial coccygectomy	GTR	None	20
Inceoglu <i>et al.</i>	1	25	F	Intergluteal cleft	No	Subcutaneous sacrococcygeal myxopapillary ependymoma	Enlarging mass	Round, firm, nontender, mobile nodule 4cm in diameter in posterior to sacrum	Surgery	GTR	None	6
Domingues <i>et al.</i>	1	22	F	Intergluteal cleft	No	Subcutaneous sacrococcygeal myxopapillary ependymoma	Sharp pain	Unremarkable neurologic and physical exams, tenderness at coccyx, Anterior surface of coccyx smooth on rectal exam, lesion contacted dorsal surface of coccyx with no bone involvement	Surgery	GTR	None	NA
Chou <i>et al.</i>	1	16	F	Intergluteal cleft	No	Subcutaneous sacrococcygeal myxopapillary ependymoma	Mass	Midline sacral mass measuring 2×3 cm, firm consistency	Surgery	GTR	NA	NA
Ciraldo <i>et al.</i>	1	0.75	F	Intergluteal cleft (sacrococcygeal)	No	Subcutaneous sacrococcygeal myxopapillary ependymoma	Enlarging mass with no history of inflammation or drainage	Small area of puckering skin overlay 3 cm fluctuant mass. Unremarkable rectal exam	Surgery	GTR	Staphylococcal infection	72

(Contd...)

Table 1: (Continued)

Authors	Cases	Age(s)	Sex	Mass location	Recurrence (Yes/No)	Histological and genetic findings	Presenting symptoms	Physical exam findings	Treatment	Outcome	Complications	Furthest follow-up (months)
Matsuo et al.	1	11	F	Intergluteal cleft (coccyx)	No	Subcutaneous sacrococcygeal myxopapillary ependymoma	Enlarging mass	Mass in coccygeal region measuring 3 cm, otherwise physical and neurological exams were normal	Surgery	GTR	NA	8
Vagaiwala et al.	1	36	M	Intergluteal cleft (sacrococcygeal)	No	Subcutaneous sacrococcygeal myxopapillary ependymoma	Enlarging mass over 2 years	Firm mass of intergluteal cleft measuring 7 cm, unremarkable physical and neurological exams	1: surgery; 2: chemotherapy (following recurrence)	GTR	Metastasis with later recurrence	NA
Anderson et al.	5	8	F	Intergluteal cleft (sacrococcygeal)	NA	Subcutaneous sacrococcygeal myxopapillary ependymoma	Mass	NA	Surgery	GTR	NA	56
		16	F	Intergluteal cleft (sacrococcygeal)	NA	Subcutaneous sacrococcygeal myxopapillary ependymoma	Mass	NA	Surgery + Radiotherapy	NA	Recurrence	24
		32	F	Intergluteal cleft (sacrococcygeal)	NA	Subcutaneous sacrococcygeal myxopapillary ependymoma	Mass	NA	Surgery	GTR	NA	NA
		3	M	Intergluteal cleft (sacrococcygeal)	NA	Subcutaneous sacrococcygeal myxopapillary ependymoma	Mass	NA	Surgery + Radiotherapy	NA	Recurrence	NA
		34	M	Intergluteal cleft (sacrococcygeal)	NA	Subcutaneous sacrococcygeal myxopapillary ependymoma	Mass	NA	Surgery	GTR	NA	NA

(Contd...)

Table 1: (Continued)

Authors	Cases	Age(s)	Sex	Mass location	Recurrence (Yes/No)	Histological and genetic findings	Presenting symptoms	Physical exam findings	Treatment	Outcome	Complications	Furthest follow-up (months)
Cappabianca et al.	1	61	M	Ischioanal fossa	No	Ischioanal myxopapillary ependymoma	3-month history of rectal tenesmus and constipation	Reduced rectal lumen by palpable extrinsic compressor on the right rectal wall 2 cm above the anus	Surgery	NA	NA	NA
Ma et al.	1	37	F	Intergluteal cleft (base of coccyx)	No	Subcutaneous sacrococcygeal myxopapillary ependymoma with concurrent chondroma	Enlarging nodule at base of coccyx over 6 months	NA	Surgery	GTR	Right iliac lymph node metastasis s/p repeat resection	6
Vroobel and Thway	1	23	F	Intergluteal cleft (sacrococcygeal)	No	Extra CNS intrasacral myxopapillary ependymoma	Large sacrococcygeal mass	NA	Surgery	NA	NA	NA
Gupta et al.	1	42	M	Intrasacral	No	Extra CNS intrasacral myxopapillary ependymoma	Low back pain for 10 years, urinary and fecal incontinence for 6 years, progressive weakness in both lower limbs for last 10 months	Muscle wasting of bilateral calf and feet with reduced strength (2/5 ankles, 4/5 hips and knees) and L5 sensory deficit	Surgery	STR	Recurrence of weakness and backache 8 months postsurgery	NA
Cihangiroglu et al.	1	41	M	Intrasacral	Yes	Extra CNS intrasacral myxopapillary ependymoma	Left lower extremity pain, weakness, and tingling sensation	Paresthesia over multiple sacral dermatomes	Surgery + radiotherapy	NA	Tumor continued to enlarge	6
Quraishi et al.	2	21	M	Intrasacral	No	Extra CNS intrasacral myxopapillary ependymoma	Low back pain for 2 years, then saddle anesthesia and right leg weakness	Right hip extension 4/5. Dermatomal sensory loss RLE	Surgery + radiotherapy	STR	None	40

(Contd...)

Table 1: (Continued)

Authors	Cases	Age(s)	Sex	Mass location	Recurrence (Yes/No)	Histological and genetic findings	Presenting symptoms	Physical exam findings	Treatment	Outcome	Complications	Furtherest follow-up (months)
Quraishi et al.	2	20	M	Intrasacral	No	Extra CNS intrasacral myxopapillary ependymoma	Worsening LBP for 6 months, sensory loss from knee down bilaterally, no bowel/bladder symptoms	Bilateral loss of sensation to light touch below the knees	Surgery + radiotherapy	STR	None	52
Gupta et al.	1	9	M	Intergluteal cleft	No	Subcutaneous sacrococcygeal myxopapillary ependymoma	Natal cleft swelling	5×3 cm soft tissue swelling in the intergluteal cleft	Surgery	GTR	NA	18
Marc'Hadour et al.	1	14	F	Intergluteal cleft (base of coccyx)	No	Subcutaneous sacrococcygeal myxopapillary ependymoma	Mass	Mass 4 cm in diameter at base of coccyx	Surgery	GTR	NA	24
Kramer et al.	1	35	M	Intergluteal cleft (sacrococcygeal)	Yes	Subcutaneous sacrococcygeal myxopapillary ependymoma	Mobile mass	Mobile sacrococcygeal mass measuring 10×5×4.5 cm	Surgery + radiotherapy	GTR	NA	NA
Helwig et al.	32	Median 17 (range 10 months - 47 years)	17F, 15M	Intergluteal cleft	N	Subcutaneous sacrococcygeal myxopapillary ependymoma	Mass in intergluteal fold overlying the sacrum and coccyx (n=28), mass in buttock (n=4)	Median size 4 cm (range 1.7-12 cm)	Surgery	GTR	84% of patients had good outcomes without recurrences, while 17% of patients developed metastases	2-23 (years)
Chung et al.	1	54	F	Intergluteal cleft (sacrococcygeal)	N	Subcutaneous sacrococcygeal myxopapillary ependymoma	Sacrococcygeal swelling	Solid mobile mass in the coccygeal region and an intergluteal fold measuring 10×5 cm	Surgery	GTR	NA	NA

in 2 patients with extra CNS ependymomas that presented with osteolytic sacral extra CNS ependymomas.^[38] These two patients were treated with adjuvant radiotherapy, which is typically utilized in patients with metastatic disease or subtotal resection.^[23,26,31] However, two cases do report recurrence despite coccygectomy.^[6,42] In addition, any lymph nodes involved at time of surgery are removed and radiation therapy is considered as these cases seem to demonstrate a propensity for recurrence.^[31,44] However, when complete excision is achieved and no regional lymph node involvement is detected, radiotherapy is deferred to avoid adverse effects.^[29] In terms of excision type, a case series by Sonneland *et al.* found that en bloc resection was associated with a lower recurrence rate than piecewise resection (10% vs. 19%),^[44] likely due to less seeding of local structures by tumor cells. They also reported higher overall survival in gross total resection compared to subtotal (19 years vs. 14 years).^[44]

Management of subcutaneous sacrococcygeal myxopapillary ependymoma is multifaceted and not fully standardized due to rarity of the disease. Our case is unique in that it describes a myxopapillary ependymoma presenting as palpable gluteal mass adherent to the coccygeal nerve and was resected successfully en bloc with a multidisciplinary team. While palpable mass is the most common presenting complaint of this entity, we did not find any reports of extra CNS ependymomas attached to the coccygeal nerve. As the tumor did partially invade the coccyx, partial coccygectomy was performed in order to attain en bloc gross-total resection. No local lymph nodes were involved, and no distant metastases were detected on imaging, so radiotherapy was deferred for the time being. The patient remains without recurrence at 6 months and will continue with long-term surveillance.

Management of subcutaneous sacrococcygeal myxopapillary ependymoma is multifaceted and not fully standardized due to rarity of the disease, and we propose that early intervention by a multidisciplinary team involving neurosurgery, orthopedic surgery, and radiation oncology and long-term radiographic surveillance for disease recurrence is a reasonable treatment strategy.

CONCLUSION

We report a rare case of an extra CNS myxopapillary ependymoma in the gluteal region with attachment to the coccygeal nerve. Management of subcutaneous sacrococcygeal myxopapillary ependymoma is multifaceted and not fully standardized due to the rarity of the disease. We propose that early intervention by a multidisciplinary team involving neurosurgery, orthopedic surgery, and radiation oncology, along with long-term radiographic surveillance for disease recurrence is a reasonable treatment strategy.

Declaration of patient consent

Patient's consent not required as patients identity is not disclosed or compromised.

Financial support and sponsorship

Nil.

Conflicts of interest

There are no conflicts of interest.

REFERENCES

1. Akpolat N, Bozlak N, Kazez A, Köseoğullari AA. Sacrococcygeal extraspinal ependymoma: A case report. *Turk J Pediatr* 2003;45:276-9.
2. Aktuğ T, Hakgüder G, Sarioğlu S, Akgür FM, Olguner M, Pabuçcuoğlu U. Sacrococcygeal extraspinal ependymomas: The role of coccygectomy. *J Pediatr Surg* 2000;35:515-8.
3. Alexiou GA, Sfakianos G, Moschovi M, Athanasiadou S, Stefanaki K, Prodromou N. Myxopapillary ependymoma of the sacrococcygeal region presenting as a pilonidal sinus. *Pediatr Neurosurg* 2012;48:64-65.
4. Amin R, Berdan E, Knipstein J, Jarzembowski J, Siddiqui S. Extraspinal sacrococcygeal ependymoma masquerading as sacrococcygeal teratoma in the pediatric patient. *Pediatr Surg Int* 2018;34:109-12.
5. Anderson MS. Myxopapillary ependymomas presenting in the soft tissue over the sacrococcygeal region. *Cancer* 1966;19:585-90.
6. Batich KA, Riedel RF, Kirkpatrick JP, Tong BC, Eward WC, Tan CL, *et al.* Recurrent extradural myxopapillary ependymoma with oligometastatic spread. *Front Oncol* 2019;9:1322.
7. Botti G, Gravina A, Cremona F, Izzo F, Rigutini M, Picone A. Subcutaneous sacrococcygeal myxopapillary ependymoma: A case report. *Eur J Cancer* 1994;30a:570-1.
8. Cappabianca S, Barberi A, Grassi R, Lieto E, Fulciniti F, Galizia G. Myxopapillary ependymoma of the ischioanal fossa. *Br J Radiol* 2003;76:659-61.
9. Chou S, Soucy P, Carpenter B. Extraspinal ependymoma. *J Pediatr Surg* 1987;22:802-3.
10. Chung JY, Lee SK, Yang KH, Song MK. Subcutaneous sacrococcygeal myxopapillary ependymoma. *AJNR Am J Neuroradiol* 1999;20:344-6.
11. Cihangiroglu M, Hartker FW, Lee M, Sehgal V, Ramsey RG. Intraosseous sacral myxopapillary ependymoma and the differential diagnosis of sacral tumors. *J Neuroimaging* 2001;11:330-2.
12. Ciraldo AV, Platt MS, Agamanolis DP, Boeckman CR. Sacrococcygeal myxopapillary ependymomas and ependymal rests in infants and children. *J Pediatr Surg* 1986;21:49-52.
13. Dogan MS, Collins R, Wang J, Koral K. Subcutaneous sacrococcygeal ependymoma in a child. *Spine J* 2016;16:e513-4.
14. Domingues R, Mikulis D, Swearingen B, Tompkins R, Rosen B. Subcutaneous sacrococcygeal myxopapillary ependymoma: CT and MR findings. *Am J Neuroradiol* 1991;12:171-2.
15. Fukuoka K, Kanemura Y, Shofuda T, Fukushima S, Yamashita S, Narushima D, *et al.* Significance of molecular classification of

- ependymomas: C11orf95-RELA fusion-negative supratentorial ependymomas are a heterogeneous group of tumors. *Acta Neuropathol Commun* 2018;6:134.
16. Gerstner ER, Pajtler KW. Ependymoma. *Semin Neurol* 2018;38:104-11.
 17. Grubnic S, MacVicar D. A perianal problem. *Br J Radiol* 1999;72:1235-6.
 18. Gupta R, Rishi A, Suri V, Sharma MC, Gupta A, Garg A, *et al.* Sacral myxopapillary ependymoma with extensive osteolysis. *J Neurooncol* 2008;86:349-52.
 19. Gupta T, Patel V, El-Medani F, Gupta S. An unexpected diagnosis of paediatric subcutaneous sacrococcygeal extraspinal ependymoma: Lessons learnt and review of the literature. *J Surg Case Rep* 2020;2020:rjaa177.
 20. Helwig EB, Stern JB. Subcutaneous sacrococcygeal myxopapillary ependymoma. A clinicopathologic study of 32 cases. *Am J Clin Pathol* 1984;81:156-61.
 21. Ilhan I, Berberoglu S, Kutluay L, Maden HA. Subcutaneous sacrococcygeal myxopapillary ependymoma. *Med Pediatr Oncol* 1998;30:81-4.
 22. Inceoglu R, Ozer F, Pamir N, Küllü S. Extraplinal ependymoma presenting as a subcutaneous mass posterior to the sacrococcygeal region: Case report. *Paraplegia* 1993;31:800-2.
 23. Johnson JM, Jessurun J, Leonard A. Sacrococcygeal ependymoma: Case report and review of the literature. *J Pediatr Surg* 1999;34:1405-7.
 24. Kelly A, Nally D, Crowther S, Kavanagh D. Subcutaneous sacrococcygeal myxopapillary ependymoma misdiagnosed as pilonidal disease. *BMJ Case Rep* 2020;13:e231639.
 25. Kline MJ, Kays DW, Rojiani AM. Extradural myxopapillary ependymoma: Report of two cases and review of the literature. *Pediatr Pathol Lab Med* 1996;16:813-22.
 26. Kramer GW, Rutten E, Sloof J. Subcutaneous sacrococcygeal ependymoma with inguinal lymph node metastasis: Case report. *J Neurosurg* 1988;68:474-7.
 27. Kumar P, Rastogi N, Jain M, Chhabra P. Extraneural metastases in anaplastic ependymoma. *J Cancer Res Ther* 2007;3:102-4.
 28. Lee KJ, Min BW, Seo HJ, Cho CH. Subcutaneous sacrococcygeal myxopapillary ependymoma in asian female: A case report. *J Clin Med Res* 2012;4:61-3.
 29. Lemberger A, Stein M, Doron J, Fried G, Goldsher D, Feinsod M. Sacrococcygeal extradural ependymoma. *Cancer* 1989;64:1156-9.
 30. Lynch J, Kelly N, Fitzpatrick B, Regan P. A sacrococcygeal extraspinal ependymoma in a 67-year-old man: A case report and review of the literature. *Br J Plast Surg* 2002;55:80-2.
 31. Ma YT, Ramachandra P, Spooner D. Case report: Primary subcutaneous sacrococcygeal ependymoma: A case report and review of the literature. *Br J Radiol* 2006;79:445-7.
 32. Mack SC, Pajtler KW, Chavez L, Okonechnikov K, Bertrand KC, Wang X, *et al.* Therapeutic targeting of ependymoma as informed by oncogenic enhancer profiling. *Nature* 2018;553:101-5.
 33. Marc'Hadour FL, Pasquier B. Subcutaneous sacrococcygeal ependymoma with incidental glomus coccygeum. *Histopathology* 1991;18:570-2.
 34. Matsuo K, Kumagai K, Kawai K, Tsuchiyama H. Subcutaneous sacrococcygeal myxopapillary ependymoma: A case report and review of the literatures. *Pathol Int* 1985;35:925-31.
 35. McEachron KR, Gaertner WB. Extradural sacrococcygeal subcutaneous ependymoma misdiagnosed as pilonidal disease: Case report and review of the literature. *J Surg Case Rep* 2016;2016:261369.
 36. Morantz RA, Kepes JJ, Batnitzky S, Masterson BJ. Extraplinal ependymomas. Report of three cases. *J Neurosurg* 1979;51:383-91.
 37. Pajtler KW, Mack SC, Ramaswamy V, Smith CA, Witt H, Smith A, *et al.* The current consensus on the clinical management of intracranial ependymoma and its distinct molecular variants. *Acta Neuropathol* 2017;133:5-12.
 38. Quraishi NA, Wolinsky JP, Bydon A, Witham T, Gokaslan ZL. Giant destructive myxopapillary ependymomas of the sacrum. *J Neurosurg Spine* 2010;12:154-9.
 39. Rao IS, Kapila K, Aggarwal S, Ray R, Gupta AK, Verma K. Subcutaneous myxopapillary ependymoma presenting as a childhood sacrococcygeal tumor: A case report. *Diagn Cytopathol* 2002;27:303-7.
 40. Rogers S, Jones DT, Ireland A, Gottardo NG, Endersby R. Unusual paediatric spinal myxopapillary ependymomas: Unique molecular entities or pathological variations on a theme? *J Clin Neurosci* 2018;50:144-8.
 41. Sawyer JR, Miller JP, Ellison DA. Clonal telomeric fusions and chromosome instability in a subcutaneous sacrococcygeal myxopapillary ependymoma. *Cancer Genet Cytogenet* 1998;100:169-75.
 42. Schiavello E, Biassoni V, Antonelli M, Modena P, Cesaro S, Pierani P, *et al.* Pediatric extraspinal sacrococcygeal ependymoma (ESE): An Italian AIEOP experience of six cases and literature review. *Childs Nerv Syst* 2018;34:1291-8.
 43. Serour F, Gorenstein A, Finci Y, Zaidel L. Subcutaneous sacrococcygeal myxopapillary ependymoma. *Pediatr Surg Int* 1993;8:362-5.
 44. Sonneland PR, Scheithauer BW, Onofrio BM. Myxopapillary ependymoma. A clinicopathologic and immunocytochemical study of 77 cases. *Cancer* 1985;56:883-93.
 45. Vagaiwala MR, Robinson JS, Galicich JH, Gralla RJ, Helson L, Beattie EJ Jr. Metastasizing extradural ependymoma of the sacrococcygeal region: Case report and review of literature. *Cancer* 1979;44:326-33.
 46. Vega-Orozco R, Rembao-Bojórquez D, Salmerón-Mercado M, García-Marquez A, Tena-Suck ML. Inguinal lymph nodal metastasis of myxopapillary ependymoma confirmed by fine-needle aspiration cytology, biopsy, and immunohistochemistry: Case report. *Diagn Cytopathol* 2011;39:689-93.
 47. Vroobel K, Thway K. Synchronous sacrococcygeal myxopapillary ependymoma and chordoma. *Int J Surg Pathol* 2016;24:48-50.
 48. Wani NA, Mir F, Qayum A, Nazir P. Sacrococcygeal extraspinal ependymoma. *Acta Neurochir (Wien)* 2010;152:917-8.
 49. Yust Katz S, Cachia D, Kamiya-Matsuoka C, Olar A, Theeler B, Prado MP, *et al.* Ependymomas arising outside of the central nervous system: A case series and literature review. *J Clin Neurosci* 2018;47:202-7.
 50. Zaidi SN, Al-Khalidi H, Al-Rikabi AC. Myxopapillary ependymoma masquerading as subcutaneous sacrococcygeal non-healing ulcer: Case report. *Ann Saudi Med* 2014;34:262-4.

How to cite this article: Lien BV, Brown NJ, Himstead ASBall BZ, Guillen A, Acharya N, *et al.* Surgical management of a rare myxopapillary ependymoma of the gluteal region: A case report. *Surg Neurol Int* 2021;12:130.