



Case Report

# Aneurysmal subarachnoid hemorrhage, a presentation of metastatic carcinoma: A case report and review of the literature

Theresa A. Elder<sup>1</sup>, Joseph G. Adel<sup>2</sup>

<sup>1</sup>Department of Neurological Surgery, University Hospitals Cleveland Medical Center, Cleveland, Ohio, <sup>2</sup>Department of Neurosurgery, Ascension St Mary's Hospital, Saginaw, Michigan, United States.

E-mail: \*Theresa A. Elder - Theresa.Elder2@uhhospitals.org; Joseph G. Adel - joseph.adel@ascension.org



**\*Corresponding author:**

Theresa A. Elder,  
Department of Neurological  
Surgery, University Hospitals  
Cleveland Medical Center,  
Cleveland, Ohio, United States.

[Theresa.Elder2@uhhospitals.org](mailto:Theresa.Elder2@uhhospitals.org)

Received : 16 October 2020

Accepted : 10 March 2021

Published : 08 April 2021

**DOI**

10.25259/SNI\_732\_2020

**Quick Response Code:**



## ABSTRACT

**Background:** Neoplastic cerebral aneurysms related to metastatic processes are exceptionally rare and carry a dismal prognosis. Only four previous reports exist of neoplastic aneurysms secondary to metastatic adenocarcinoma, all of which were found to be lung cancer in origin. We present the fifth reported metastatic adenocarcinomatous cerebral aneurysm, and the first case is secondary to a non-lung cancer primary.

**Case Description:** The patient presented with complaining of headache and was found to have a large right-sided intraparenchymal hemorrhage and smaller left-sided hemorrhage on head CT, and CTA revealed a vascular pouch in the region of the hemorrhage. The patient showed sudden neurologic decline, and repeat imaging revealed enlargement of the hematoma with significant brain compression. The patient underwent emergent angiography revealing a distal cortical middle cerebral artery aneurysm, suspicious for mycotic etiology, which was treated through microsurgical excision at the time of hematoma evacuation. The aneurysm specimen was sent for cultures and pathology, revealing the diagnosis of metastatic non-small-cell carcinoma. Further inpatient workup did not reveal the primary neoplastic source.

**Conclusion:** Although diagnostic workup should search for more common pathologic mimics than metastatic neoplastic cerebral aneurysms, clinicians must be able to recognize and expeditiously treat this devastating lesion. Further investigation and analysis of treatment options are necessary to better understand this rare pathology and improve patient outcomes.

**Keywords:** Adenocarcinoma, Aneurysm, Case report, Intracranial hemorrhage, Metastatic

## INTRODUCTION

Cerebral aneurysms secondary to metastatic neoplastic processes are exceedingly rare, with less than 100 cases reported in the literature.<sup>[11]</sup> The majority of documented cases are secondary to cardiac myxoma, and the remainder related to choriocarcinoma, lymphoma, or occasionally to metastases of other origin.<sup>[10]</sup> There are only four documented cases of metastatic aneurysms with primary etiology of metastatic adenocarcinoma, and all four cases were associated with known primary lung cancer.<sup>[2,6,8,10]</sup>

This is an open-access article distributed under the terms of the Creative Commons Attribution-Non Commercial-Share Alike 4.0 License, which allows others to remix, tweak, and build upon the work non-commercially, as long as the author is credited and the new creations are licensed under the identical terms.

©2021 Published by Scientific Scholar on behalf of Surgical Neurology International

We present a patient with no known cancer history, who presented with aneurysmal hemorrhage, initially presumed to be mycotic in etiology due to the lesion's location and morphology. Intraoperative pathology, however, revealed non-small-cell adenocarcinoma. Imaging of the chest, abdomen, and pelvis did not reveal a culprit lesion, rendering lung adenocarcinoma an unlikely source and leaving breast adenocarcinoma as the leading primary diagnosis among adenocarcinoma of other distant sites. This case would represent the first reported case of metastatic aneurysm secondary to adenocarcinoma of the breast or of any non-lung origin.

## CASE SUMMARY

### Clinical presentation

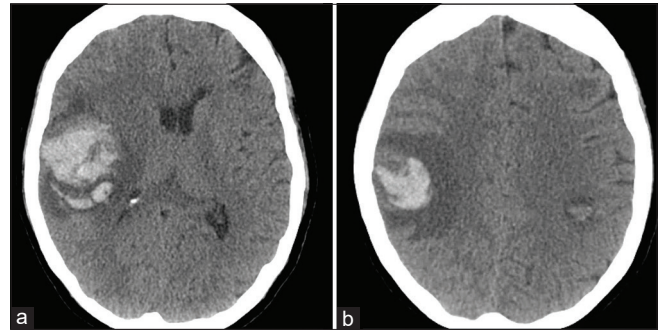
A 67-year-old right-handed female presented to the hospital with a headache which began the day prior. Head CT revealed a  $4.7 \times 3.8 \times 2.2$  cm right parietal intraparenchymal hemorrhage and 1 cm left parietal intraparenchymal hemorrhage [Figure 1]. The patient was neurologically intact upon initial presentation. Upon further workup, CTA revealed a spot sign with vascular pouch in the region of the right-sided hemorrhage, raising concern for mycotic aneurysm or a dural AV fistula [Figure 2], warranting the need for digital subtraction angiography. Shortly afterward, the patient suddenly became lethargic with facial asymmetry and left hemiparesis. Repeat head CT revealed enlargement of the right-sided hematoma to  $5.8 \times 5.5 \times 5.0$  cm with 1.3 cm brain compression and midline shift [Figure 3].

### Intraoperative course

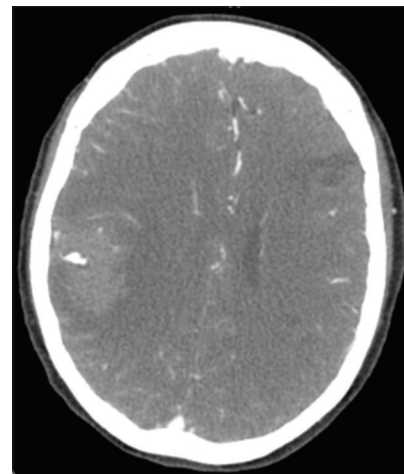
The patient was taken emergently for angiography with the intent to identify and treat the underlying vascular malformation if amenable to endovascular treatment, before craniotomy for hematoma evacuation. Angiogram revealed a distal cortical middle cerebral artery (MCA) fusiform aneurysm, raising suspicion for mycotic etiology given the location [Figure 4], and hence, it was decided to address the aneurysm during the hematoma evacuation. The patient underwent stereotactic right parietal minicraniotomy. After initial partial intraparenchymal hematoma evacuation, a pseudoaneurysm capsule was identified along the distal posterior parietal MCA branches with two clear superficial outflow vessels [Figure 5]. The aneurysm was isolated and excised, and the specimen was sent for pathology and cultures. Given the superficial location and small caliber arteries, bypass reconstruction was not contemplated.

### Histopathology and post-operative course

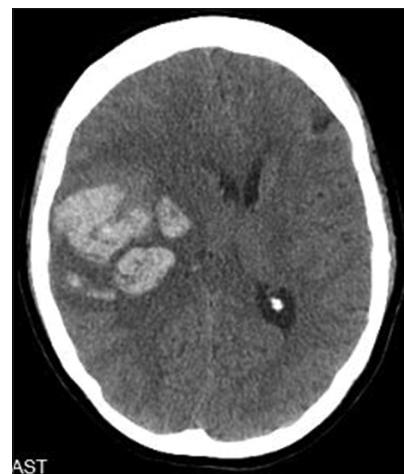Given the suspicion for mycotic aneurysm, a transesophageal echocardiogram was obtained and was negative for any evidence of endocarditis or atrial myxoma. Final intraoperative



**Figure 1:** Axial non-contrast head CT upon initial presentation. (a) Right parietal hemorrhage (b) left parietal hemorrhage.

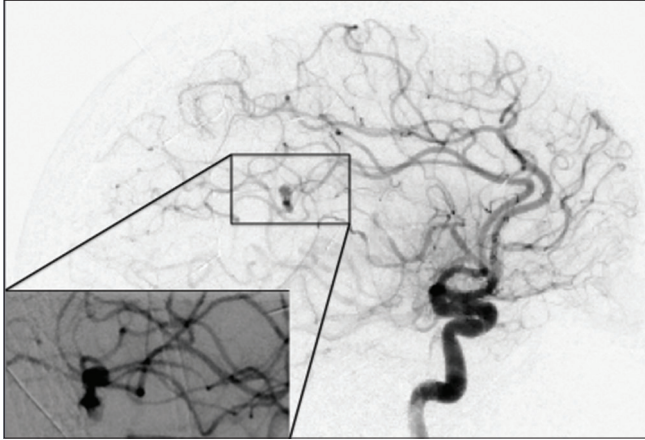


**Figure 2:** Axial CTA revealing the vascular lesion in the hematoma.

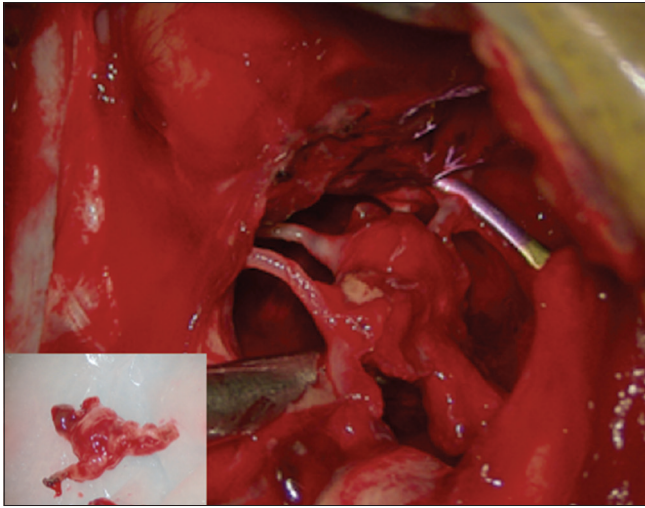


**Figure 3:** Axial non-contrast head CT revealing the expanding intraparenchymal hemorrhage pattern with mass effect.

cultures and blood cultures were negative for any infectious process. Head CTs demonstrated small contralateral hemorrhage without evidence of vascular pathology or metastatic disease on cerebral angiography or MRI.



**Figure 4:** Lateral right internal carotid artery angiography demonstrating the angioarchitecture of the offending aneurysm.



**Figure 5:** Intraoperative image demonstrating the afferent vessel (clip) as well as the two efferent vessels and the aneurysm specimen.

Pathology was consistent with metastatic non-small-cell adenocarcinoma within the aneurysmal wall, with immunohistochemistry staining positive for CK7 and negative for CK 5/6, CK 20, TTF-1, and p63. Given these findings, oncology was consulted, and CT of the chest, abdomen, and pelvis was obtained and was negative for a malignancy source. Further workup was planned once the patient improved clinically, including PET scan to determine the location of the underlying malignancy. The patient recovered neurologically; however, she developed pneumonia and sepsis 2 weeks later, and the family elected hospice care.

## DISCUSSION

Given the rarity of neoplastic cerebral aneurysms, there is an overall lack of understanding of the pathophysiology

involved in their formation. Multiple theories have been postulated regarding the cause of vessel damage that leads to the formation of such aneurysms.<sup>[11]</sup> Likely, a series of events must occur in sequence, beginning with the embolization of tumor particles. In one theory, the circulating tumor cells must invade the blood vessel endothelium, leading to growth and ultimately destruction of the arterial wall.<sup>[1,11]</sup> Another theory hypothesizes that tumor embolization leads to altered blood flow dynamics and a consequent predisposition to aneurysm formation.<sup>[8,9]</sup> The presence of the small contralateral bleed on our patient's head CT despite no identifiable lesions on angiography support the high likelihood of an underlying systemic pathology. There are only seven reported cases of metastatic cerebral aneurysms, and in three of these cases, a second remote hemorrhagic lesion was found [Table 1].

While lung and breast carcinoma are the most common sources of metastatic brain tumors, there are no reported cases of metastatic cerebral aneurysms secondary to breast cancer or any non-lung origin. Of the seven existing cases, secondary to lung cancer, four were confirmed on histopathology, and the remainder were presumed based on active lung cancer lesions.<sup>[2-6,8,10]</sup> All of these patients presented with intracerebral hemorrhage, and all but one died within 3 months of aneurysm diagnosis.<sup>[8]</sup> In our patient, histopathology was reviewed by multiple pathologists, with breast cancer determined as the most likely source of the adenocarcinomatous morphology, especially in the context of negative CT chest/abdomen/pelvis.

Given the trend toward poor outcomes, awareness and prompt recognition of this potential diagnosis are critical. Similar to mycotic aneurysms, neoplastic aneurysms are generally small, fusiform, and peripherally located. They are best detected on angiography but may only be identifiable by delayed contrast washout in the arterial phase and/or decreased flow in the venous phase.<sup>[7,11]</sup> In our patient, the pseudoaneurysm was detected angiographically based on the pattern of contrast stasis. Of note, although embolization of the harboring vessel was a treatment option, microsurgical resection was elected over endovascular treatment given the need for hematoma evacuation.

There is a shortage of data on the treatment and outcomes of these lesions, with a lacking consensus on optimal management. Of the seven reported neoplastic lung cancer aneurysms, only one patient achieved a good functional outcome (at 6 months).<sup>[2-6,8,10]</sup> This patient's cranial disease was treated as a solitary metastatic tumor, with stereotactic radiosurgery to the operative bed following initial trapping and excision of the aneurysm.<sup>[10]</sup> Three cases were treated with trapping and ligation without

**Table 1:** Reports of metastatic neoplastic cerebral aneurysms.

Author (year)	Patient Age	Aneurysm location	Additional ICH	Aneurysm histopathology	Treatment
Present case	67	Distal MCA	Yes	Non-small-cell adenocarcinoma, presumed breast	Microsurgical excision
Sokolowski <i>et al.</i> (2019) <sup>[10]</sup>	63	Distal MCA	No	Poorly differentiated non-small-cell lung adenocarcinoma	Microsurgical excision followed by stereotactic radiosurgery
Omofoye <i>et al.</i> (2018) <sup>[8]</sup>	41	PICA, SCA	Yes	Poorly differentiated non-small-cell lung adenocarcinoma	None
Nomura <i>et al.</i> (2009) <sup>[6]</sup>	61	Distal MCA	No	Lung adenocarcinoma	Microsurgical excision
Gliemroth <i>et al.</i> (1999) <sup>[2]</sup>	38	PICA, AICA	Yes	Lung adenocarcinoma	None
Murata <i>et al.</i> (1993) <sup>[5]</sup>	63	Distal PCA	No	Small-cell carcinoma	Microsurgical excision
Kochi <i>et al.</i> (1984) <sup>[4]</sup>	56	Distal MCA	Yes	Squamous cell carcinoma	Microsurgical excision
Ho (1982) <sup>[3]</sup>	69	Distal PCA	No	Bronchogenic carcinoma	None

AICA: Anterior inferior cerebellar artery, ICH: Intracerebral hemorrhage, MCA: Middle cerebral artery, PCA: Posterior cerebral artery, PICA: Posterior inferior cerebellar artery

further treatment to the brain, and the remaining three received no treatment.<sup>[4]</sup>

## CONCLUSION

Neoplastic cerebral aneurysms are rare but devastating lesions with the potential to rupture and carry significant morbidity and mortality risk. Clinicians must be aware of this potential aneurysm etiology and able to promptly conduct the appropriate diagnostic workup for such lesions as well as their pathologic mimics, especially when endovascular treatment is utilized which eliminates the benefit of pathology diagnosis. Further investigation of treatment options and outcomes will allow for better understanding of the underlying pathophysiology behind neoplastic aneurysm formation and may ultimately improve outcomes for these patients.

## Declaration of patient consent

The authors certify that they have obtained all appropriate patient consent.

## Financial support and sponsorship

Nil.

## Conflicts of interest

There are no conflicts of interest.

## REFERENCES

1. Ashalatha R, Moosa A, Gupta AK, Manohar SR, Sandhyamani S. Cerebral aneurysms in atrial myxoma: A delayed, rare manifestation. *Neurol India* 2005;53:216-8.
2. Gliemroth J, Nowak G, Kehler U, Arnold H, Gaebel C. Neoplastic cerebral aneurysm from metastatic lung adenocarcinoma associated with cerebral thrombosis and recurrent subarachnoid haemorrhage. *J Neurol Neurosurg Psychiatry* 1999;66:246-7.
3. Ho KL. Neoplastic aneurysm and intracranial hemorrhage. *Cancer* 1982;50:2935-40.
4. Kochi N, Tani E, Yokota M, Nakaya Y. Neoplastic cerebral aneurysm from lung cancer. Case report. *J Neurosurg* 1984;60:640-3.
5. Murata J, Sawamura Y, Takahashi A, Abe H, Saitoh H. Intracerebral hemorrhage caused by a neoplastic aneurysm from small-cell lung carcinoma: Case report. *Neurosurgery* 1993;32:124-6.
6. Nomura R, Yoshida D, Kim K, Kobayashi S, Teramoto A. Intracerebral hemorrhage caused by a neoplastic aneurysm from pleomorphic lung carcinoma. *Neurol Med Chir (Tokyo)* 2009;49:33-6.
7. Noterman J, Verhest A, Baleriaux D, Brotchi J. A ruptured cerebral aneurysm from choriocarcinomatous origin-a case report and a review. *Neurosurg Rev* 1989;12:71-4.
8. Omofoye OA, Barnett R, Lau W, Trembath D, Jordan JD, Sasaki-Adams DM. Neoplastic cerebral aneurysm from metastatic nonsmall cell lung carcinoma: Case report and literature review. *Neurosurgery* 2018;83:E221-5.
9. Radoi MP, Stefanescu F, Arsene D. Brain metastases and multiple cerebral aneurysms from cardiac myxoma: Case report

- and review of the literature. *Br J Neurosurg* 2012;26:893-5.
10. Sokolowski JD, Williams EL, Diaz M, Wildeman ME, Nguyen JH, Gish DS, *et al.* Neoplastic cerebral aneurysm from metastatic lung adenocarcinoma with neuroendocrine features. *World Neurosurg* 2019;122:155-60.
11. Zheng J, Zhang J. Neoplastic cerebral aneurysm from

metastatic tumor: A systematic review of clinical and treatment characteristics. *Clin Neurol Neurosurg* 2015;128:107-11.

**How to cite this article:** Elder TA, Adel JG. Aneurysmal subarachnoid hemorrhage, a presentation of metastatic carcinoma: A case report and review of the literature. *Surg Neurol Int* 2021;12:143.